

# Prosthodontic management of worn dentition in pediatric patient with complete overlay dentures: a case report

Prince Kumar<sup>1\*</sup>, MDS, Jyoti Rastogi<sup>2</sup>, MDS, Chandni Jain<sup>3</sup>, MDS, Harkanwal Preet Singh<sup>4</sup>, MDS

<sup>1</sup>Department of Prosthodontics, Shree Bankey Bihari Dental College and Research Centre, Ghaziabad, Uttar Pradesh, India

<sup>2</sup>Department of Prosthodontics, Dental College, Azamgarh, Uttar Pradesh, India

<sup>3</sup>Private Practitioner, Jabalpur, Madhya Pradesh, India

<sup>4</sup>Department of Oral Pathology, Swami Devi Dyal Hospital and Dental College, Panchkula, Haryana, India

Overlay complete dentures are simple, reversible and economical treatment modality for patients with congenital or acquired disorders that severely affect the tooth development. It satisfies both the esthetic and functional demands where the extraction of teeth is not generally indicated. In pediatric patients, the overlay dentures establish a relatively stable occlusion that improves patient's tolerance to the future treatment procedures for worn dentition. This clinical report highlights the imperative need of appropriate treatment strategy and application of maxillary and mandibular overlay dentures in a pediatric patient who suffered from congenitally mutilated and worn dentition. [J Adv Prosthodont 2012;4: 239-42]

**KEY WORDS:** Overlay dentures; Occlusal wear; Vertical dimension

## INTRODUCTION

Prolonged retention of tooth enhances the possibility that dentist may treat the patients with severe tooth wear without any invasive procedure. Tooth wear is generally considered as a result of natural physiological process. On average, the occlusal wear is estimated to be 29  $\mu\text{m}$  per year for molars and 15  $\mu\text{m}$  per year for premolars.<sup>1</sup> Some endogenous or exogenous factors (e.g.; tobacco chewing) accelerate the normal wear rate and results in pathologic tooth wear. Tooth wear as a result of parafunctional habits is anticipated to progress approximately 3 times faster than physiological tooth wear.<sup>2,3</sup> The etiologic factors include bruxism, gastroesophageal reflux disease and congenital anomalies such as Weyer's acrodental dysostosis and Dentinogenesis imperfecta.<sup>4,5</sup> Predicting a suitable differential diagnosis is difficult in such cases due to the possibility of combination of these processes in developing occlusal wear.<sup>6</sup>

Although 'full-mouth rehabilitation' is the treatment of

choice for generalized tooth wear, it is not always true applied to all clinical conditions. That is why a more comprehensive occlusal rehabilitation approach may be used to manage generalized tooth wear when the coronal tissues are moderately worn, and only some teeth require endodontic and restorative treatment. A prior endodontic restoration in worn dentition with an acceptable existing vertical dimension at occlusion and established occlusal relationships not only simplifies the treatment procedures but also makes it economically efficient. An overlay denture is partial or complete removable denture fabricated over retained roots or teeth that are not prepared with a coping to interfere with the denture.<sup>7</sup> Overlay dentures has part of their components that covers the occlusal surface of the abutment teeth to restore them into a functional occlusion.<sup>8-10</sup> The present article described an unique prosthodontic management of a pediatric patients suffering from rare hereditary disorders wherein the tooth development and morphology is severely impaired.

Corresponding author: Prince Kumar

Department of Prosthodontics, Shree Bankey Bihari Dental College and Research Centre, Masuri, Ghaziabad, Uttar Pradesh, 201302, India

Tel. 91 9412860201; e-mail, drprincegupta20032007@gmail.com

Received November 9, 2011 / Last Revision December 29, 2011 / Accepted January 16, 2012

© 2012 The Korean Academy of Prosthodontics

This is an Open Access article distributed under the terms of the Creative Commons Attribution Non-Commercial License (<http://creativecommons.org/licenses/by-nc/3.0>) which permits unrestricted non-commercial use, distribution, and reproduction in any medium, provided the original work is properly cited.

## Case selection and treatment planning considerations

In the present clinical report, the overall health of patient was good with no relevant medical and dental history that could contradict the proposed dental rehabilitation. Initial intraoral assessment revealed wear of the maxillary and mandibular dentition that compromised esthetics. To establish a sound treatment strategy, a meticulous and extensive evaluation was executed, including intraoral examination of the teeth, extraoral radiography (OPG: Orthopantomogram) to assess the endodontic treatment status of teeth and condition of supporting structures. The extraoral examination includes an analysis of occlusion, middle and lower facial height, vertical dimension at occlusion, esthetics and phonetics consideration. Oral hygiene status was also estimated to predict the treatment prognosis. Diagnostic casts were made and mounted in centric relation in a semi-adjustable articulator using face bow to estimate the interocclusal space and to select appropriate prosthesis. An outline of significant findings which determines the selection of future prosthesis (overlay complete denture) is presented in Table 1.

## Technique

Although the fabrication of overlay complete denture is similar to that of adult complete denture, certain imperative consideration should be taken into account while fabricating a pediatric overlay denture.

Primary and final impression procedures are completed similarly as in an adult denture. In younger children, the buccal and labial vestibule are relatively superficial which needs to be recorded carefully during border molding to ensure proper fit of the custom tray to the denture foundation tissues. The selection of denture teeth may be difficult because of patient's primary or mixed dentition and must be carried out in consultation with parents and patient's esthetics.

The maxillary central incisors are arranged in such a way that it touches the vermilion border of lower lip when fricative sounds are being pronounced.<sup>11,12</sup> The occluso-gingival length of

maxillary central incisors was estimated on the basis of golden proportion.<sup>13,14</sup> Dentures are processed, delivered and post insertion instructions are given. Follow-up period is deemed important and it includes recall appointment on regular basis for oral hygiene instructions, and minor denture adjustments. In caries-prone children, fluoride gel may be applied on the tissue surface of denture. Denture modifications can be done by adding acrylic to the area where teeth erupt or by making concavities into the dentures to accommodate the erupting teeth. In long-term denture usage (when child is grown up), it may be necessary to relin or rebase the denture or remake it due to the changes that occur in the alveolar ridge with the growth and development of the child.<sup>15</sup>

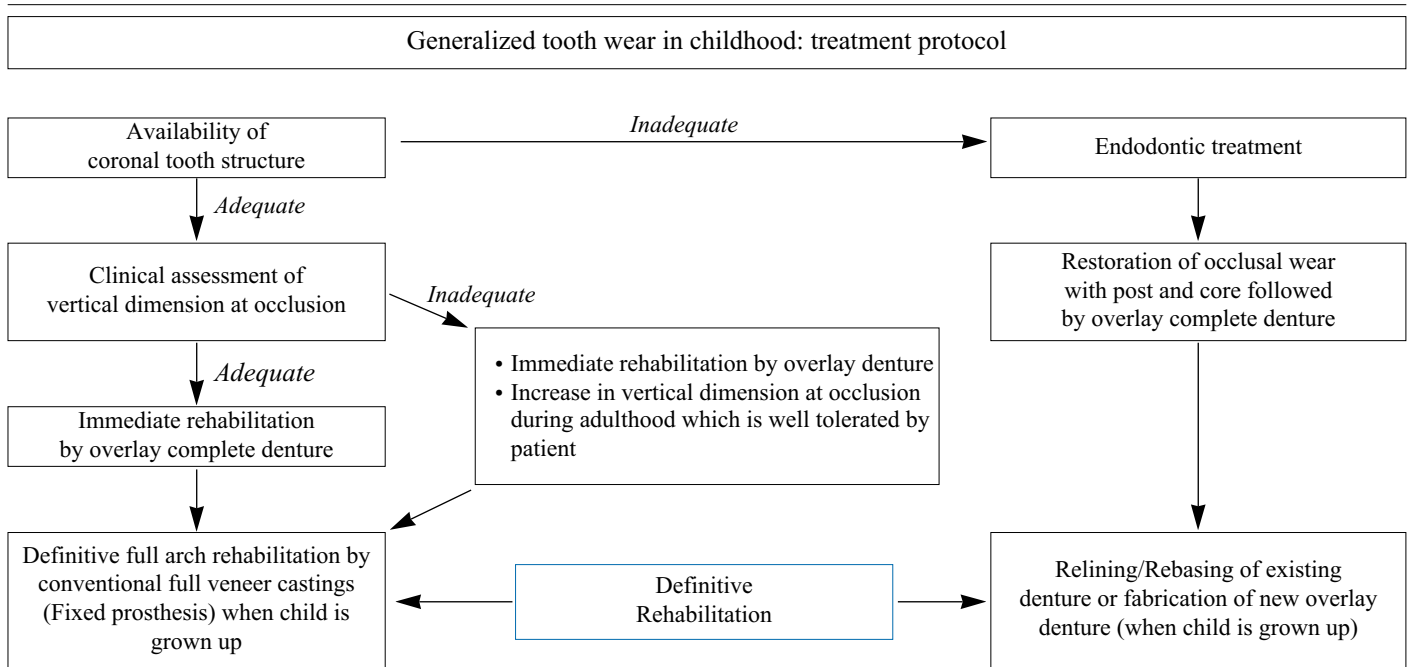
## Practical considerations of overlay dentures in pediatric patients

Dawson<sup>16</sup> suggested that in response to wear of teeth, adaptive remodeling processes occur in alveolar bone, compensating such tooth wear. Hence, it is always advised that patients with excessively worn dentitions, accurate assessment of vertical dimension at occlusion must be performed before the initiation of treatment. The use of overlay dentures to increase the vertical dimension at occlusion is very beneficial in the patients who require more comprehensive fixed prosthetic treatment in later stages.<sup>17</sup> Keeping in mind the possibility of fixed prosthetic treatment of pediatric patients in adulthood, it is advisable to make use of such prosthesis (overlay denture) which do not alter the dentition permanently during the period of assessment and accomplish patient's functional and esthetic demands.

The complete overlay denture has several advantages when applied to pediatric patient: enhanced masticatory efficiency, esthetics, improved speech and restored vertical dimension. Preservation of alveolar bone with its use may be confirmed in the comparative analysis of lateral cephalograms of pre- and post-treatment phases. Also the retained natural teeth with their periodontal ligament offers ample of proprioception compared to a complete denture that is fabricated over an edentulous

**Table 1.** Outline of significant findings in early evaluation phase

Intraoral assessment	Extraoral assessment	Esthetics and smile	Speech assessment
Lack of posterior occlusion	Decrease in vertical dimension at occlusion and lower facial height	Not esteemed due to absence of incisors	S sound production with relative paucity due to reduced vertical dimension at occlusion and absence of incisors
Adequate gingival and bone support Undue loss of tooth structure due to wear process	Moderate interocclusal freeway space of 3 to 4 mm	Moderate buccal vestibular space	Obliterated F and V sound pronunciation as the relation and position of maxillary incisor to lower lip cannot be established

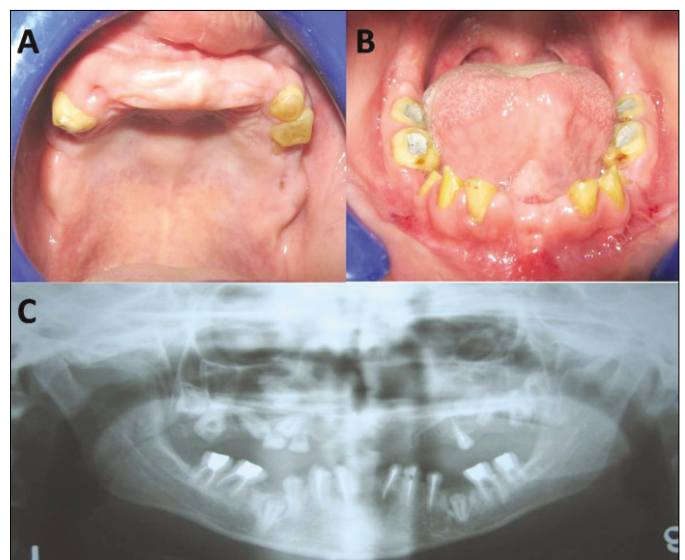


**Fig. 1.** Flow chart depicting the treatment protocol of generalized tooth wear in child patient.<sup>15,20</sup>

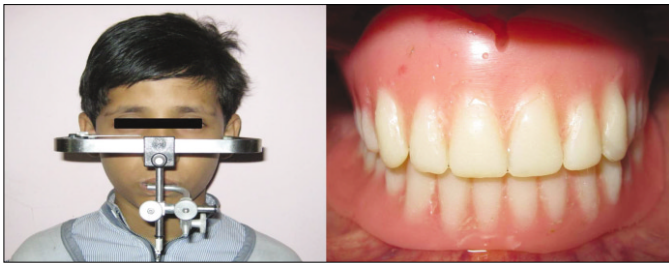ridge.<sup>18,19</sup> The overall management and treatment approach for generalized tooth wear in pediatric patient may be summarized as in flow chart shown in Fig. 1.

## CASE REPORT

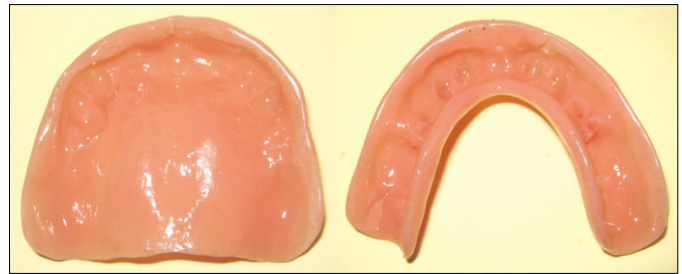
A 13-year-old male with a known history of Weyer's acrocentric dysostosis reported to the dental clinic with the chief complaint of difficulty in eating and poor esthetics of the existing denture. History revealed that a denture had been fabricated 2.5 years ago, but no longer fitted. Intraoral examination showed extensive tooth wear extending to the cemento-enamel junction in most areas of the teeth. Additionally, several findings related to the syndrome were noticed like partial ankyloglossia, widely spaced teeth, discolored malformed dentition, oligodontia, large pulp chambers, and collapsed bite (Figs. 2A and 2B). Radiographic finding includes multiple impacted teeth, multiple missing permanent tooth germs, retained teeth, short roots and enlarged and open pulp chambers (Fig. 2C). The fabrication of overlay denture was planned to restore the lost vertical dimension of occlusion and to improve the associated class III facial profile (Figs. 3-5). Most evidently, the patient's attitude, self-confidence and quality of life had enhanced (Fig. 6). As the available tooth structure is insufficient for future fixed prosthodontic treatment, relining/rebasing of existing denture or fabrication of new overlay denture is planned for long-term usage.



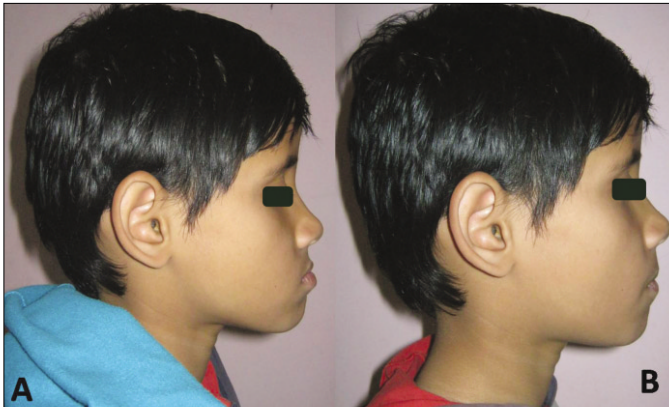**Fig. 2.** A: Maxillary arch showing multiple missing teeth and malformed remaining teeth, B: Mandibular arch showing partial ankyloglossia, oligodontia, widely spaced and discolored teeth, C: Radiographic presentation of Weyer's acrocentric dysostosis. Note the multiple impacted, unerupted, partially erupted with large pulp chambers.



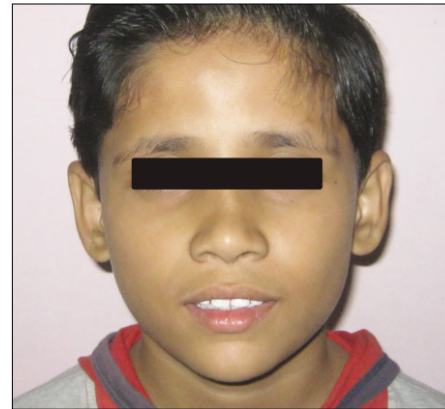**Fig. 3.** Face bow recording and processed overlay denture in mouth.



**Fig. 4.** Tissue surface of overlay denture showing indentations that fit over the patient's retained teeth.



**Fig. 5.** A: Pre- treatment view, B: Post- treatment view. Note the increase in lower facial height and marked improvement in esthetic.



**Fig. 6.** Post treatment frontal view.

## CONCLUSION

Complete overlay dentures are comparatively simple to fabricate and render satisfactory results as in present case report where the pediatric patient had an excellent treatment outcome. The major advantages include: low treatment cost, short chair time, reversibility, alterability, maintenance of alveolar bone and preserved proprioception, and excellent retention and stability. Most outstandingly, there is also a great deal of psychological benefit to the child patient.

## REFERENCES

1. Lambrechts P, Braem M, Vuylsteke WM, Vanherle G. Quantitative in vivo wear of human enamel. *J Dent Res* 1989;68:1752-4.
2. Verrett RG. Analyzing the etiology of an extremely worn dentition. *J Prosthodont* 2001;10:224-33.
3. Xhonga FA. Bruxism and its effect on the teeth. *J Oral Rehabil* 1977;4:65-76.
4. Smith BG, Knight JK. A comparison of patterns of tooth wear with aetiological factors. *Br Dent J* 1984;157:16-9.
5. Watts A, Addy M. Tooth discolouration and staining: a review of the literature. *Br Dent J* 2001;190:309-16.
6. Turner KA, Missirlilian DM. Restoration of the extremely worn dentition. *J Prosthet Dent* 1984;52:467-74.
7. Brewer AA, Fenton AH. The overdenture. *Dent Clin North Am* 1973;17:723-46.
8. Farmer JB, Connelly ME. Treatment of open occlusions with on-

- lay and overlay removable partial dentures. *J Prosthet Dent* 1984;51:300-3.
9. Gankerseer EJ. Case report: a new technique for the treatment of the severely worn dentition. *Restorative Dent* 1987;3:13-4.
10. Johnson A, Winstanley RB. Use of simple overdentures in the treatment of young patients with developmental anomalies. *Quintessence Dent Technol* 1987;11:27-33.
11. Fayz F, Eslami A, Graser GN. Use of anterior teeth measurements in determining occlusal vertical dimension. *J Prosthet Dent* 1987;58:317-22.
12. Heinlein WD. Anterior teeth: esthetics and function. *J Prosthet Dent* 1980;44:389-93.
13. Levin EI. Dental esthetics and the golden proportion. *J Prosthet Dent* 1978;40:244-52.
14. Ricketts RM. The golden divider. *J Clin Orthod* 1981;15:752-9.
15. Johnson A, Winstanley RB. Use of simple overdentures in the treatment of young patients with developmental anomalies. *Quintessence Dent Technol* 1987;11:27-33.
16. Dawson P. Evaluation, diagnosis, and treatment of occlusal problems. 2nd ed. St. Louis: CV Mosby; 1989. p. 56-71, 500-10.
17. Fayz F, Eslami A. Determination of occlusal vertical dimension: a literature review. *J Prosthet Dent* 1988;59:321-3.
18. Loiselle RJ, Crum RJ, Rooney GE Jr, Stuever CH Jr. The physiologic basis for the overlay denture. *J Prosthet Dent* 1972;28:4-12.
19. Schneidman E, Wilson S, Spuller RL. Complete overlay dentures for the pediatric patient: case reports. *Pediatr Dent* 1988;10:222-5.
20. Chu FC, Siu AS, Newsome PR, Chow TW, Smales RJ. Restorative management of the worn dentition: 4. Generalized toothwear. *Dent Update* 2002;29:318-24.