

Treatment of syncope in tongue cancer with palliative chemotherapy in the intensive care unit

A case report

Chongkai Fang, MM^a, Liting Yang, MM^a, Guangbi Zeng, MM^a, Ruilin Huang, MM^a, Wei Fang, MM^b, Yao Chen, MM^c, Jieshan Guan, MD^c, Peng Li, MD^c, Xuewu Huang, MM^{c,*}, Lizhu Lin, MD^{c,*}

Abstract

Rationale: Syncope caused by head and neck cancer (HNC) is rare. However, syncope caused by tongue cancer (TC) is even rarer. In TC, syncope is caused by tumor-mediated compression of the carotid sinus and stimulation of the glossopharyngeal nerve.

Patient concerns: In this study, we report the case of a 48-year-old male patient who was diagnosed with advanced TC and bilateral cervical lymph node metastasis. On the third day of admission, the patient experienced recurrent syncope with hypotension and bradycardia.

Diagnoses: The patient was diagnosed with a well-differentiated squamous cell carcinoma of the tongue along with massive cervical lymph node metastasis and carotid sinus syndrome.

Interventions: Initially, symptomatic treatment of syncope boosted the blood pressure and increased the heart rate. Thereafter, a temporary pacemaker was implanted. Finally, chemotherapy was used to control the tumor and relieve syncope.

Outcomes: After chemotherapy, the tongue ulcers and cervical lymph node reduced in size; syncope did not recur.

Lessons: This case shows that chemotherapy may be a valid treatment option in patients with cancer-related syncope; however, the choice of chemotherapeutic drugs is critical. Intensive care provides life support to patients and creates opportunities for further treatment.

Abbreviations: CT = computed tomography, EGFR = epidermal growth factor receptor, HNC = head and neck cancer, HNSCC = head and neck squamous cell carcinoma, ICU = intensive care unit, PET-CT = positron emission tomography-computed tomography, TC = tongue cancer.

Keywords: carotid sinus syndrome, chemotherapy, intensive care unit, syncope, tongue cancer

1. Introduction

Oral cancer is a common malignant tumor in head and neck cancer (HNC). A tumor located in the two-third of the tongue is defined as tongue cancer (TC). Stage III and IV TCs are mainly

treated with surgery in combination with radiotherapy and chemotherapy.^[1] With the development of comprehensive treatment, the overall 5-year survival rate of TC has reached approximately 60% to 65%.^[2] Although regional lymph node metastasis is frequently observed in TC, syncope caused by an advanced TC with cervical lymph node metastasis is rare. Cancer-related syncope mainly derives from HNC. Its mechanism is caused by mechanical compression of the carotid sinus or tumor-induced stimulation of the glossopharyngeal nerve.^[3,4] The role of chemotherapy in the treatment of syncope caused by HNC has rarely been reported. In this case report, we describe the case of a 48-year-old man who was diagnosed with advanced TC and experienced recurrent syncopal episodes during hospitalization due to tumor-mediated compression of the carotid sinus. Initially a temporary pacemaker was implanted; however, it failed to relieve the symptoms. The patient was then successfully treated with chemotherapy in the intensive care unit (ICU). Thereafter, the patient did not experience syncope and his vital signs recovered smoothly.

2. Case presentation

A 48-year-old man was presented with symptoms of dizziness, fatigue, and swollen and aching tongue and neck for the last 4 months. The patient did not experience headache or glossopharyngeal ache. The patient underwent positron emission tomography (PET-CT); a hypermetabolic lesion was detected in the left side of the tongue and hypermetabolic masses were detected in

Editor: N/A.

The patient signed an informed consent to publish the case report. Ethical approval was not applicable.

This study was supported by grants from the National Natural Science Foundation of China (Grant no. 81573780), Science and Technology Project of Guangzhou (Grant no. 201707010299).

The authors have no conflicts of interests to disclose.

^a First Clinical Medical College, Guangzhou University of Chinese Medicine,

^b Department of Oral and Maxillofacial Surgery, Stomatological Hospital, Southern Medical University, ^c Cancer center, First Affiliated Hospital of Guangzhou University of Chinese Medicine, Guangzhou, China.

* Correspondence: Lizhu Lin, Xuewu Huang, The First Affiliated Hospital of Guangzhou University of Chinese Medicine, Guangzhou, Guangdong, China (e-mails: lizhu26@yahoo.com, drhuangxw@163.com).

Copyright © 2019 the Author(s). Published by Wolters Kluwer Health, Inc. This is an open access article distributed under the terms of the Creative Commons Attribution-Non Commercial-No Derivatives License 4.0 (CCBY-NC-ND), where it is permissible to download and share the work provided it is properly cited. The work cannot be changed in any way or used commercially without permission from the journal.

Medicine (2019) 98:35(e16998)

Received: 14 March 2019 / Received in final form: 27 June 2019 / Accepted: 7 August 2019

<http://dx.doi.org/10.1097/MD.00000000000016998>

multiple lymph nodes in the left neck and left submandibular area. A tongue biopsy was performed and the pathological report indicated well-differentiated tongue squamous cell carcinoma, cT4N2M0, at stage IV. Therefore, the patient received 1 cycle of preoperative induction chemotherapy with PCF (cisplatin 30 mg D1-3, leucovorin 300 mg D1-4, fluorouracil 750 mg D1-3). Chemotherapy provided partial relief; however, the patient refused to undergo surgery. Subsequently, the patient received another 2 cycles chemotherapy in 2 different hospitals. The first TP chemotherapy was given in September of 2016 (cisplatin 120 mg D2-4, paclitaxel liposome 210 mg D2, cetuximab 500 mg D1). The second DPF chemotherapy was given in October of 2016 (docetaxel 135 mg D1, cisplatin 135 mg D1, fluorouracil 1350 mg D2-4). There was no radiographic evaluation following treatment.

Upon physical examination, a mass with the dimension of 60 mm × 40 mm was found in the left side of the tongue. The boundary was unclear while the surface was ulcerated with yellow fiber and covered with a pseudo-membrane. A touchable swollen lymph node, 60 mm × 70 mm, was identified in the left lower jaw. A second touchable swollen lymph node, 15 mm × 10 mm, was noticed in the right lower jaw. The heart rate of the patient was 76 beats/min, blood pressure was 120/84 mmHg, respiratory rate was 20 breaths/min, and blood oxygen saturation was 97% while he was breathing ambient air. The neurological and physical examinations were unremarkable. Computed tomography (CT) scan showed an abnormal shadow on the left tongue; the dimension was 18 mm × 31 mm. The left neck mass was 61 mm × 62 mm, while the large mass on the right side was 18 mm × 28 mm; it was diagnosed as a well-differentiated tongue squamous cell carcinoma, cT4N3M0, at stage IV. The past medical record of the patient showed no hypertension or coronary heart disease.

After the patient was hospitalized, he underwent a magnetic resonance imaging examination of the head, which revealed no hemorrhagic brain damage and no brain tumors. On the third day of hospitalization, the patient experienced sudden syncope with the following vital signs: heart rate was 65 beats/minute, blood pressure was 54/35 mmHg, and blood oxygen saturation was 92%. Physical examination showed equally large and round pupils with a diameter of about 4 mm, a slow reflection of light, low heart sound, and regular heart rhythm. The neurologic examination was unremarkable. Atropine and dopamine were given immediately. Thereafter, the patient regained consciousness; heart rate was 54 beats/min, blood pressure was 175/90 mmHg, blood oxygen saturation was 100%. Subsequently, the patient experienced syncope several times. After consulting with a cardiologist, sinus bradycardia was diagnosed, and a temporary pacemaker was implanted.

After implantation of the pacemaker, the patient still experienced recurrent syncope with heart rate being 101 beats/minute, blood pressure 55/25 mmHg, respiratory rate 9 breaths/minute, and blood oxygen saturation 72%. Then the patient was transferred to the ICU and dopamine was continuously pumped. It was presumed that syncope was due to the compression generated by the mass in the neck; it stimulated the carotid sinus, which hyperactivated the vagus nerve. Therefore, the medical team decided to provide reduced-dose chemotherapy and monitor the patient closely.

The patient received 1 cycle of chemotherapy (nanoparticle albumin-bound paclitaxel 300 mg vd D1, nedaplatin 40 mg vd D1-3, nimotuzumab 200 mg vd qw), after which he felt

comfortable. Blood test and liver and kidney function tests were normal. However, the patient still experienced syncopal attacks from 3 to 4 times per day. When syncope occurred, blood pressure dropped and the heart rate was driven by the temporary pacemaker; in addition to the basal dose of dopamine, 0.25 mg adrenaline was required to increase his blood pressure to 100/60 mmHg. After 1 cycle of chemotherapy, the episodes of syncope reduced. Since the patient refused to continue treatment in the ICU, he was transferred to the general ward for subsequent treatment. Later, the patient underwent 3 cycles of chemotherapy (nanoparticle albumin-bound paclitaxel 300 mg vd D1, cisplatin mg vd D1-3, nimotuzumab 200 mg vd qw). A follow-up CT scan after the last chemotherapy revealed a shadow of a mass of soft tissue on the left side of the tongue; the size of the mass was smaller than before, the dimensions being about 10 mm × 13 mm (originally, 18 mm × 31 mm). The mass in the left neck was reduced to around 63 mm × 25 mm (originally, 61 mm × 62 mm). (Figs. 1 and 2) The larger mass on the right side was about 15 mm × 22 mm (originally, 18 mm × 28 mm). After the end of the chemotherapy, the tumors in the tongue and the neck were significantly reduced and syncope did not recur. Three months after diagnosis and treatment, we learned that the patient had a “left-sided tongue resection and bilateral cervical lymph node dissection” in another hospital and the postoperative recovery was good.

3. Discussion

According to the guidelines of the European Society of Cardiology, 2018, syncope is mainly divided into three categories:

- (1) reflex syncope, which includes vasovagal, situational, and carotid sinus syndrome;

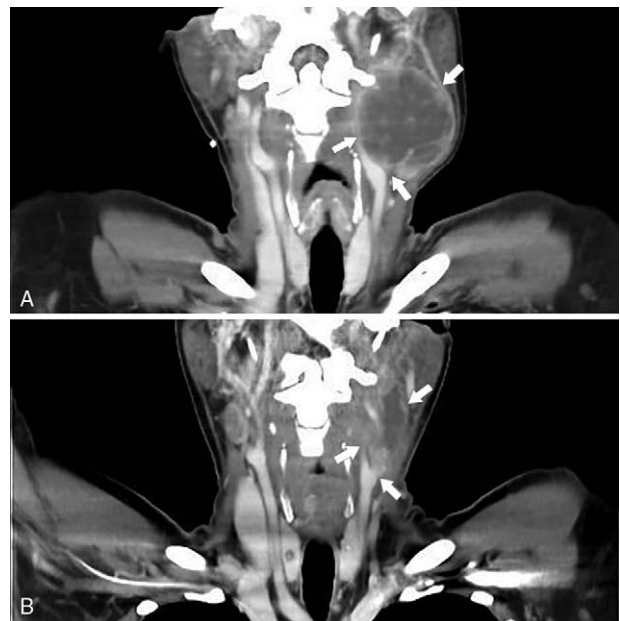


Figure 1. CT scans showing the left cervical lymph node which compressed the carotid sinus (A) before and (B) after chemotherapy. CT=computed tomography.

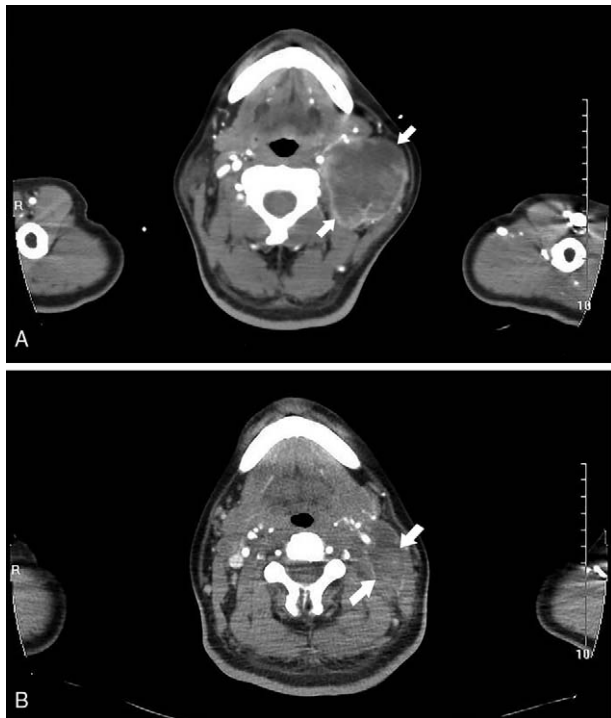


Figure 2. CT scans showing the lymph node shrinkage on the (A) left side before and (B) after chemotherapy. CT=computed tomography.

- (2) orthostatic hypotension syncope, which includes primary or secondary autonomic failure, drug-induced orthostatic hypotension, and volume depletion;
- (3) cardiac syncope, which includes arrhythmia and structural cardiac disease.^[5]

At present, the mechanism of cancer-related syncope is primarily due to the stimulation of the carotid sinus and glossopharyngeal nerve.^[3,4]

The carotid sinus is the dilated part of the bifurcation of the common carotid artery. Along with the carotid sinus reflex arc, the baroreceptors of the carotid sinus play a role in controlling the blood pressure. The afferent nerve of the reflex arc arises from the baroreceptors of the carotid sinus and terminates in the cardiac inhibitory center and vascular motion center of the medulla oblongata. The efferent nerve, consisting of the vagal nerve and the sympathetic nerve, helps regulating the heart and peripheral blood vessels. Some studies found that cervical tumor metastasis could suppress the carotid sinus. It could continue to excite the glossopharyngeal nerve and stimulate the medullary vascular region, thus increasing the vagal tone (bradycardia) and reducing the sympathetic tone (vasodilation). This results in a reduced cardiac output and venous return, which eventually leads to syncope.^[3,6] In our case, the CT images showed that the left lymph node invaded the carotid sinus area. The patient had no past medical history of cardiovascular disease. Thus, the sudden appearance of syncope was considered the result of carotid sinus compression.

There are 3 types of carotid sinus syndrome, namely, cardioinhibitory type (cardiac arrest for 3 seconds, bradycardia with or without hypotension), vasodepressor type (fall in systolic blood pressure below 50mmHg), mixed type (cardiac arrest for >3seconds and fall in systolic blood pressure below

50 mmHg).^[7,8] In this study, as the patient experienced syncope with bradycardia and hypotension; the carotid sinus syndrome of the patient can be categorized as a mixed type.

In addition to the use of cholinergic receptor blockers and vasoactive drugs, there are currently several treatment options for syncope caused by HNC. This includes radiotherapy, chemotherapy, installation of pacemakers, and glossopharyngeal and vagal neurectomy.^[9,10] Lin et al reported that a patient with advanced TC and a mass in the neck^[10] underwent glossopharyngeal and limited vagal neurectomy; during the 8-month follow-up period the syncope did not recur. Vallurupalli et al reported that a patient with nasopharyngeal carcinoma and lymphadenopathy experienced syncope.^[11] Even after installation of a temporary pacemaker and treatment with radiotherapy and chemotherapy, the patient still experienced syncope. However, following treatment with theophylline, the syncope did not recur.

In this study, the patient had a series of symptoms, such as repeated loss of consciousness, persistent bradycardia (heart rate <40 beats/min), sinus arrest, and long R-R interval. Some studies have supported the therapeutic benefits of implantation of permanent cardiac pacemaker in patients with cardiac suppression or mixed carotid sinus syndrome.^[12] In this study, the patient was treated with atropine to relieve cardiac suppression. As the symptom persisted, implantation of a temporary pacemaker was required; thereafter, heart rate was maintained at 80 beats/minute while the electrocardiograph prompted the pacemaker rhythm. To treat hypotension and stabilize blood pressure, we chose to administrate dopamine.

The abovementioned treatment strategies were only symptomatic. Surgery, radiotherapy, and chemotherapy can be chosen to control the development of the disease. In terms of surgery, excision of the glossopharyngeal nerve can reduce the frequency of syncope. However, patients may suffer the sequelae of surgery.^[13] In this study, as the vital signs of the patient was unstable and the tumor was large, surgery was not performed. Radiotherapy was required to be conducted in a separate closed room. As syncope occurred frequently, there was a risk that the patient could not be rescued during radiotherapy. Therefore, we considered starting palliative chemotherapy in the ICU to control the growth of tumors and reduce the frequency of syncope. There are few studies on treating HNC or TC with chemotherapy alone.^[14,15] In this case, syncope frequently occurred with hypotension and bradycardia. Therefore, chemotherapy was the primary choice.

Currently, the most active drugs for chemotherapy in HNC are cisplatin, paclitaxel, docetaxel, 5-FU, cetuximab, and nimotuzumab. Cisplatin causes a severe gastrointestinal reaction. Nedaplatin, a second-generation platinum drug with mechanism of action similar to that of cisplatin, has comparatively lower adverse reactions. As the condition of the patient was severe in the ICU, we chose nedaplatin instead of cisplatin for a single cycle of chemotherapy. In the next three cycles, the vital signs of the patient became stable; thereafter, we treated the patient with cisplatin. In a previous clinical study, taxanes played an important role in the treatment of HNC.^[16] However, albumin-bound paclitaxel is more effective and less toxic than other taxanes.^[17] The epidermal growth factor receptor (EGFR) is highly expressed in head and neck squamous cell carcinoma (HNSCC). Studies have shown that palliative chemotherapy combined with anti-EGFR targeted therapy for HNSCC could effectively increase the sensitivity of chemotherapy and control the progression of the disease.^[18,19] Nimotuzumab is a

humanized monoclonal antibody that specifically binds to EGFR with 95% homology. Although nimotuzumab has a mechanism of action similar to that of cetuximab, it shows less adverse reactions (namely skin mucosal reaction and allergic reactions) than cetuximab. Therefore, we gave nedaplatin, nanoparticle albumin-bound paclitaxel, and nimotuzumab to the patient.

The patient still had syncopal attacks during chemotherapy in the ICU. However, after 1 cycle of palliative chemotherapy, the occurrence of syncope was significantly reduced. In the meantime, the vital signs were stabilized. Therefore, we considered transferring the patient to the general ward to continue subsequent treatment. A study revealed that the ICU plays a key role in helping cancer patients to pass through critical health conditions and improve their prognosis.^[20]

After 4 cycles of chemotherapy, CT scan indicated that the size of the primary tumor in the tongue and the lymph nodes of the neck was reduced. Tumor lesions were partially relieved, and syncope did not recur.

4. Conclusion

A patient with advanced TC experiencing syncope and adverse vital signs showed improvement following palliative chemotherapy in the ICU. After 4 cycles of chemotherapy, his heart rate and blood pressure returned to normal and vital signs were stabilized. Tumor lesions were also significantly relieved. Chemotherapy may be a valid treatment for patients with cancer-related syncope and adverse vital signs. However, the choice of chemotherapeutic drugs is critical.

Acknowledgments

The authors thank Editage (www.editage.com) for English language editing.

Author contributions

Conceptualization: Wei Fang.

Data curation: Wei Fang, Peng Li.

Project administration: Jieshan Guan, Xuewu Huang.

Writing – original draft: ChongKai Fang, Liting Yang, Yao Chen.

Writing – review & editing: ChongKai Fang, Guangbi Zeng, Ruilin Huang, Lizhu Lin.

Lizhu Lin orcid: 0000-0001-8283-6554.

References

- [1] Chi AC, Day TA, Neville BW. Oral cavity and oropharyngeal squamous cell carcinoma—an update. *CA Cancer J Clin* 2015;65:401–21.
- [2] Miller KD, Siegel RL, Lin CC, et al. Cancer treatment and survivorship statistics, 2016. *CA Cancer J Clin* 2016;66:271–89.
- [3] Macdonald DR, Strong E, Nielsen S, et al. Syncope from head and neck cancer. *J Neurooncol* 1983;1:257–67.
- [4] Lin RH, Teng MM, Wang SJ, et al. Syncope as the presenting symptom of nasopharyngeal carcinoma. *Clin Neurol Neurosurg* 1994;96:152–5.
- [5] Brignole M, Moya A, de Lange FJ, et al. 2018 ESC Guidelines for the diagnosis and management of syncope. *Kardiol Pol* 2018;76:1119–98.
- [6] Barbash GI, Keren G, Korczyn AD, et al. Mechanisms of syncope in glossopharyngeal neuralgia. *Electroencephalogr Clin Neurophysiol* 1986;63:231–5.
- [7] Weiss S, Baker JP. The carotid sinus reflex in health and disease: its role in the causation of fainting and convulsions. *Medicine* 1933;12:297–354.
- [8] Brignole M, Alboni P, Benditt DG, et al. Guidelines on management (diagnosis and treatment) of syncope—update 2004. Executive Summary. *Eur Heart J* 2004;25:2054–72.
- [9] Almqvist A, Gornick C, Benson WJr, et al. Carotid sinus hypersensitivity: evaluation of the vasodepressor component. *Circulation* 1985;71:927–36.
- [10] Lin HW, Rho MB, Amin-Hanjani S, et al. Glossopharyngeal and limited vagal neurectomy for cancer-related carotid sinus syncope. *Skull Base* 2009;19:369–73.
- [11] Vallurupalli S, Aggarwal C, Sewani A, et al. Oral theophylline as temporizing treatment of neck mass induced carotid sinus syncope. *Int J Cardiol* 2013;167:e79–80.
- [12] Shen W-K, Sheldon RS, Benditt DG, et al. 2017 ACC/AHA/HRS guideline for the evaluation and management of patients with syncope: a report of the American College of Cardiology/American Heart Association Task Force on Clinical Practice Guidelines, and the Heart Rhythm Society. *J Am Coll Cardiol* 2017;70:e39–110.
- [13] Papay FA, Roberts JK, Wegryn TL, et al. Evaluation of syncope from head and neck cancer. *Laryngoscope* 1989;99:382–8.
- [14] Ju JH, Kang MH, Kim HG, et al. Successful treatment of syncope with chemotherapy irresponsive to cardiac pacemaker in head and neck cancer. *Yonsei Med J* 2009;50:725–8.
- [15] Choi YM, Mafee MF, Feldman LE. Successful treatment of syncope in head and neck cancer with induction chemotherapy. *J Clin Oncol* 2006;24:5332–3.
- [16] Narveson L, Kathol E, Rockey M, et al. Evaluation of weekly paclitaxel, carboplatin, and cetuximab in head and neck cancer patients with incurable disease. *Med Oncol* 2016;33:107.
- [17] Gradishar WJ. Albumin-bound paclitaxel: a next-generation taxane. *Expert Opin Pharmacother* 2006;7:1041–53.
- [18] Vermorken JB, Mesia R, Rivera F, et al. Platinum-based chemotherapy plus cetuximab in head and neck cancer. *New Engl J Med* 2008;359:1116–27.
- [19] Xu SP, Suzarte MR, Bai XH, et al. Treatment outcome of nimotuzumab plus chemotherapy in advanced cancer patients: a single institute experience. *Oncotarget* 2016;7:33391–407.
- [20] Soubani AO. Critical care prognosis and outcomes in patients with cancer. *Clin Chest Med* 2017;38:333–53.