

Rectal Lipoma Associated with Genital Prolapse

Krishnan P, Adlekha S¹, Chadha T², Babu AK³

Departments of Surgical Gastroenterology, ¹Pathology, ²Microbiology, Sree Narayana Institute of Medical Sciences, ³Dermatology and Venereology, Sunrise Hospital, Ernakulam, Kerala, India

Address for correspondence:

Dr. Shashikant Adlekha,
Department of Pathology, Sree
Narayana Institute of Medical
Sciences, Chalakka - 683 594,
Dist. Ernakulam, Kerala, India.
E-mail: shuntyad@yahoo.co.in

Abstract

Lipomas are the tumors of mature lipocytes with its occurrence most often on the torso, neck, upper thighs, upper arms, and armpits, but they can occur almost anywhere in the body. They are the rare tumors of intestine, more frequently located in large intestine compared to small intestine. We present the case of a 58-year-old post-menopausal lady presenting with rectal bleeding and utero-vaginal prolapse. The prolapsing mass was excised, and histopathological examination diagnosed the lesion to be a lipoma.

Keywords: Mature adipocytes, Rectal bleeding, Rectal lipoma, Utero-vaginal prolapse

Introduction

Lipomas are rare but well-recognized tumors of intestine, being more common in cecum and ascending colon.^[1] Majority of these lesions arise from sub-mucosa, and they can protrude into the lumen. Ulceration of mucosa and bleeding events are particularly common manifestations of colonic lipoma. Most of these lesions are diagnosed after resection; however, deeper endoscopic biopsies can also lead to diagnosis. Microscopically, they are composed of lobules of mature adipose tissue separated by delicate fibrous septa. Areas of necrosis and hemorrhage are seen in larger lesions.

Case Report

A 58-year-old post-menopausal woman presented with six months history of hematochezia, tenesmus, constipation, loss of appetite, and vaginal mass prolapsed. On general examination, patient was thin and pale. Abdominal examination was unremarkable. Rectal examination revealed a soft swelling in the anterior wall of rectum measuring approximately 3 × 3 cm and 6 cm above the anal verge. Speculum examination showed second-degree utero-vaginal prolapse, cystocele, and rectocele. In vaginal examination, uterus appeared to be atrophic and retroverted. There were no signs of tumor infiltration into

foreskins. Recto-vaginal examination showed mass in rectum/recto-vaginal septum with atrophic perineal body. Findings were confirmed by colonoscopy and contrast-enhanced CT scan [Figure 1] of the abdomen, showing a sub-mucosal rectal mass. She underwent vaginal hysterectomy with pelvic floor repair. This was followed by transrectal excision of the rectal mass [Figure 2]. The macroscopic appearance of excised mass was suggestive of lipoma. Histopathological examination confirmed the diagnosis of lipoma and revealed ulceration of the overlying rectal mucosa [Figure 3].

Discussion

Lipomas of the large intestine are relatively uncommon in clinical practice. Most of them are incidentally detected during

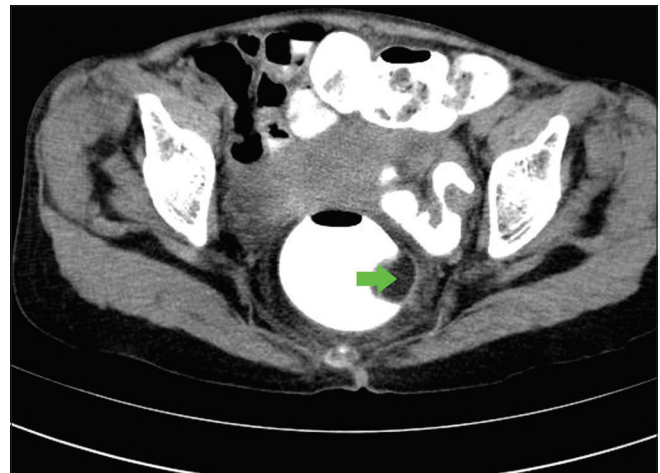


Figure 1: Contrast CT of abdomen showing a sub-mucosal rectal mass (green arrow)

Access this article online

Quick Response Code:



Website: www.amhsr.org

DOI:
10.4103/2141-9248.121212

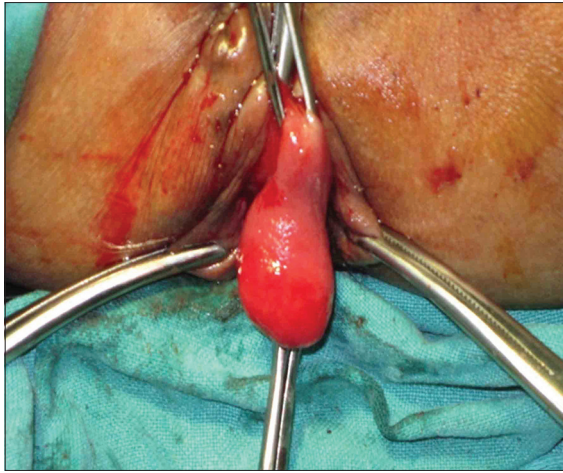


Figure 2: Excision of rectal mass, grossly appearing as smooth polypoidal mass

a routine endoscopic examination. Usual occurrence is in sixth decade of life with an incidence of 0.2% to 4.4%.^[1,2] Some authors have reported a female predominance while others found nearly equal incidences in males and females.^[3]

The most common site of origin of lipoma in gastrointestinal tract is cecum and ascending colon.^[1] There is no explanation for the predilection of lipomas of the large bowel to occur in the right side. Lipomas of the rectum are quite rare with less than 15 cases reported in literature.^[4] In multiple case series published, rectal lipoma was only seen in nine of 227 colorectal lipoma cases (3.9%).^[4] Lesions are sessile or polypoidal and are sub-mucosal in 90% of cases and rest being located in sub-serosal plane.^[4]

Vast majority of colonic lipoma cases (< 2 cm in size) are asymptomatic. Colonic lipomas of size greater than 2 cm may cause symptoms such as constipation, diarrhea, and abdominal pain. Rectal lipomas manifest as intussusception, ulceration leading to hemorrhage, intestinal obstruction, prolapse, and rectal bleeding.^[4] In present case, the patient presented with rectal bleeding and partial rectal prolapse. Spontaneous expulsion of a sigmoid lipoma has been reported.^[5] The prolapse of a rectal lipoma through the anus is a rare event, and only few cases are reported in the literature.^[6] The most important clinical impact of lipoma is its potential to be confused with colonic malignancy because of its similarity in symptomatology.^[7] Female genital prolapse as seen in present case can be associated with rectal lesions. Urinary bladder, uterus, and rectum can lose their support and can protrude into the vagina as prolapse. Prolapse can vary from mild, with a feeling of vaginal discomfort; to moderate, with tissue protruding from the vagina on straining; to severe, with tissue permanently protruding from the vagina. Multiple non-surgical and surgical options are available to treat female genital prolapse. In the present case, as the patient

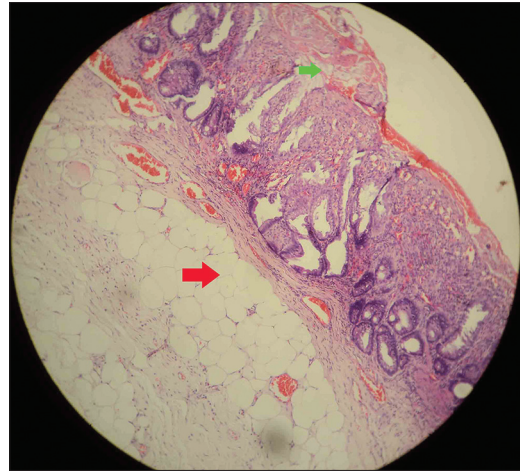


Figure 3: Histopathological examination of excised mass revealing a lesion composed of lobules of mature adipocytes (red arrow) and ulcerated rectal mucosa (green arrow). (H and E, $\times 100$)

is post-menopausal and with co-existing partial rectal prolapse, vaginal hysterectomy was carried out.

Diagnostic approaches usually include endoscopy, contrast-enhanced CT scan of the abdomen, and barium enema. Endoscopic biopsies usually fail to diagnose the lesion, as the lipomas are situated below the normal mucosa. Management depends on the location and presentation of the lipoma. Endoscopic removal has been reported for lipomas up to a size of 2 cm; however, larger lesions carry the risk of hemorrhage and perforation.^[8,9] Surgical procedures include laparotomy enucleation, colostomy, and excision of lipoma and segmental colonic resection. In case of rectal lipomas, trans-anal excision can be done for lower third lesions. Laparoscopic procedures can be done in selected cases.^[9]

In conclusion, rectal lipomas are very rare and often pose a diagnostic challenge. Therapeutic options depend on the size of the lesion and associated complications.

References

1. Rogy MA, Mirza D, Berlakovich G, Winkelbauer F, Rauhs R. Submucous large-bowel lipomas: Presentation and management. An 18-year study. *Eur J Surg* 1991;157:51-5.
2. Vecchio R, Ferrara M, Mosca F, Ignoto A, Latteri F. Lipomas of the large bowel. *Eur J Surg* 1996;162:915-9.
3. Creasy TS, Baker RA, Talbot IC, Veitch PS. Symptomatic submucosal lipoma of the large bowel. *Br J Surg* 1987;74:984-6.
4. Manickavasagam K, Chandramohan S, Lakshmi JS, Vairavan K, Madhusudhanan J. Intussuscepting Rectal Lipoma: A case report and review of literature. *Int J Gastroenterol* 2012;11. Available from: <http://www.ispub.com/journal/the-internet-journal-of-gastroenterology/volume-11-number-1/intussuscepting-rectal-lipoma-a-case-report-and-review-of-literature.html#sthash.IGVjUgJu.dpuf> [Last accessed on 2012].
5. Michowitz M, Lazebnik N, Noy S, Lazebnik R. Lipoma of the colon. A report of 22 cases. *Am Surg* 1985;51:449-54.

6. Ryan J, Martin JE, Pollock DJ. Fatty tumours of the large intestine: A clinicopathological review of 13 cases. *Br J Surg* 1989;76:793-6.
7. Tascilar O, Cakmak GK, Gun BD, Uçan BH, Balbaloglu H, Cesur A, *et al.* Clinical evaluation of submucosal colonic lipomas: Decision making. *World J Gastroenterol* 2006;12:5075-7.
8. Tamura S, Yokoyama Y, Morita T, Tadokoro T, Higashidani Y, Onishi S. "Giant" colon lipoma: What kind of findings are necessary for the indication of endoscopic resection? *Am J Gastroenterol* 2001;96:1944-6.
9. Ladurner R, Mussack T, Hohenbleicher F, Folwaczny C, Siebeck M, Hallfeld K. Laparoscopic-assisted resection of giant sigmoid lipoma under colonoscopic guidance. *Surg Endosc* 2003;17:160.

How to cite this article: Krishnan P, Adlekha S, Chadha T, Babu AK. Rectal lipoma associated with genital prolapse. *Ann Med Health Sci Res* 2013;3:S18-20.

Source of Support: Nil. **Conflict of Interest:** None declared.