

Five-step Correction of Congenital Symmastia

Stephen J. Poteet, MD*
 Amanda Carraher, PA*
 Ibrahim H. Amjad, MD†
 Rajiv Chandawarkar, MD*

Summary: Congenital symmastia is distressing and difficult to treat, and traditional surgical modalities have met with limited success. We present a novel approach for a patient that failed all traditional surgical options. The anatomic deformity is analyzed using a modified version of Blondeel's 3-step analysis (conus, footprint, and skin envelope, to which we added a fourth element "intermammary web"). Combining operative principles from breast cancer reconstruction, we describe 5 operative steps that help correct the deformity, followed by a new postoperative splinting regimen that addresses the common pitfalls that could lead to recurrence. (*Plast Reconstr Surg Glob Open* 2015;3:e335; doi: 10.1097/GOX.000000000000293; Published online 23 March 2015.)

Symmastia is the "medial confluence of the breasts."¹ Two types have been described: congenital, developmentally aberrant proliferation of mammary tissue resulting in an intermammary web crossing the sternal midline,^{2,3} and acquired, an iatrogenic complication from breast reconstruction/augmentation wherein medial overdissection violates the sternum midline.^{4,5} Treatment of congenital symmastia is challenging, and published articles are few and traditional surgical options (breast reduction with/without liposuction and intermammary quilting) do not help address the root causes of the anatomic deformity. In sharp contrast, iatrogenic symmastia is easier to correct: capsulorrhaphy, neosubpectoral pocket dissection, and acellular dermal matrices are effective options.⁶⁻⁹ Here, we present a novel approach for a patient that failed all traditional surgical options. First, we characterize the anatomic deformity using a modified version of

Blondeel's 3-step analysis (conus, footprint, and skin envelope, to which we added a fourth element "intermammary web"). Second, our surgical approach combines operative principles from breast cancer reconstruction^{2,10} with the traditional approach to deliver "the best of both worlds." Last, we describe a new postoperative splinting regimen that addresses the common pitfalls that could lead to recurrence.

CASE

A 27-year-old white woman presented with congenital symmastia having previously failed bilateral reduction mammoplasty, presternal liposuction, and placement of quilting sutures in the intermammary web (Fig. 1).

Operative Details

Four main anatomic features of the symmastia breast were defined and marked out preoperatively—our surgical plan aimed to stepwise address each of these anatomic structures:

1. Conus: crescent-shaped resection of medial breast tissue;
2. Footprint: bilateral medial fixation using Strattice dermal matrix;
3. Intermammary web: direct resection of intermammary tissue and pexy;
4. Skin envelope: redraping and fixation of the medial border.

From the *Department of Plastic Surgery, Ohio State University, Columbus, Ohio; and †Amjad Plastic and Reconstructive Surgery, Miami, Fla.

Received for publication December 6, 2014; accepted January 27, 2015.

Copyright © 2015 The Authors. Published by Wolters Kluwer Health, Inc. on behalf of The American Society of Plastic Surgeons. All rights reserved. This is an open-access article distributed under the terms of the Creative Commons Attribution-NonCommercial-NoDerivatives 3.0 License, where it is permissible to download and share the work provided it is properly cited. The work cannot be changed in any way or used commercially.

DOI: 10.1097/GOX.000000000000293

Disclosure: The authors have no financial interest to declare in relation to the content of this article. The Article Processing Charge was paid for by the authors.

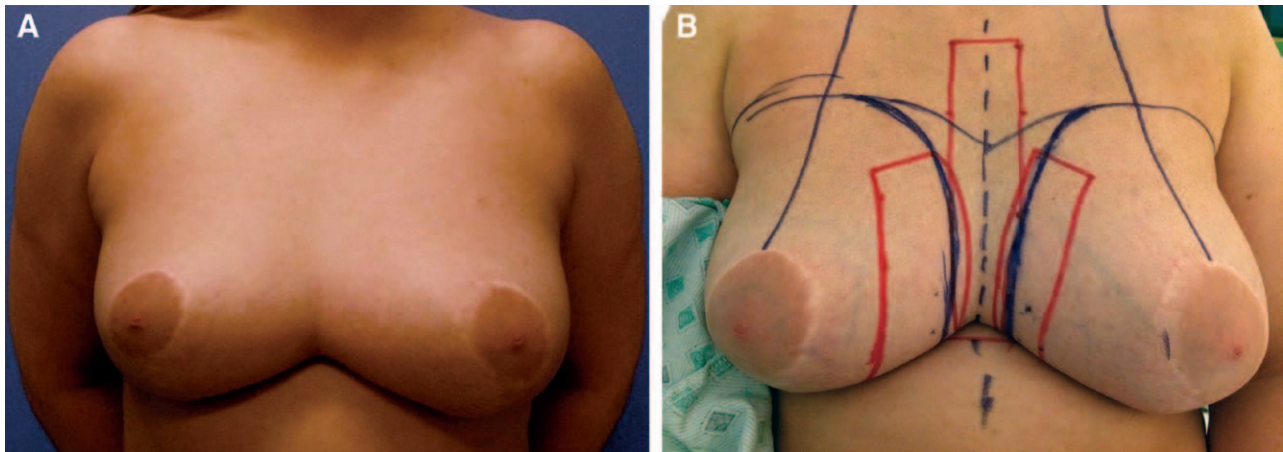


Fig. 1. A, Preoperative photograph. B, Preoperative markings.

Preoperative Markings

With the patient in a standing position, the midline and breast median were marked (Fig. 1B). Subsequently, a rectangular zone, 4-cm wide, was marked parallel to the midline (red lines). This marked the zone where the resection would be performed and where the 3 rows of presternal quilting sutures would be placed (described in a later section). Using the lateral edge of this rectangle as a guide, a curved line was marked where it met the breast tissue, symmetrically to delineate the new medial edge of the footprint (black lines). In turn, this also determined the lateral border of the intermammary tissue that would need resection. Lateral to this footprint, a rectangular area was marked to show where the Strattice would be affixed (red lines).

At the start of the operation, using a 30-gauge needle and methylene blue, the desired extent of the medial footprint of each breast was tattoo-marked to serve as future landmarks to obliterate the presternal space and re-position the medial footprint of the breast. This step is critical; these landmarks are lost once the skin envelope is opened.

An 8 cm inferior-medially placed inframammary incision was then made bilaterally, and flaps were raised to expose both the medial quadrant of each breast and presternal tissues. With all 3 pockets communicating and widely open, correction of the 4 anatomic units was undertaken: (1) a crescent-shaped area of glandular tissue in the medial quadrant (left, 69g; right, 64g) was resected to restore the medial aspect of the conus (Fig. 2); (2) presternal tissue was excised down to the medial pectoral fascia (laterally) and sternal periosteum (midline) [note that the shape of this excised fibroadipose tissue is a scalloped-rectangle—ensuring that the superior portion of the web is adequately resected]; this dissection must be performed carefully, preferably with

a lighted retractor, in a subcutaneous plane—if the skin is too thin, one could devascularize it. Use cautery judiciously. (3) Medial footprint of the breast and intermammary sulcus was restored by using acellular dermal matrix: 2 contoured pieces of Strattice (LifeCell: Strattice Reconstructive Tissue Matrix, Branchburg, N.J.) were tailored 3.5 cm × 18 cm (Fig. 3) and draped along the medial portion of the breast and secured medially to the pectoralis fascia and laterally to the breast parenchyma (this limited medial excursion of the breast into the presternal

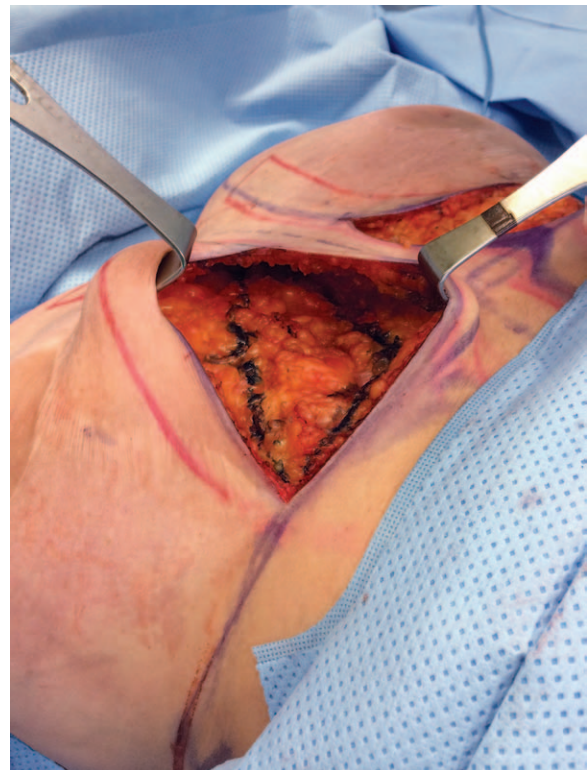


Fig. 2. Tissue resected to restore the medial aspect of the conus.

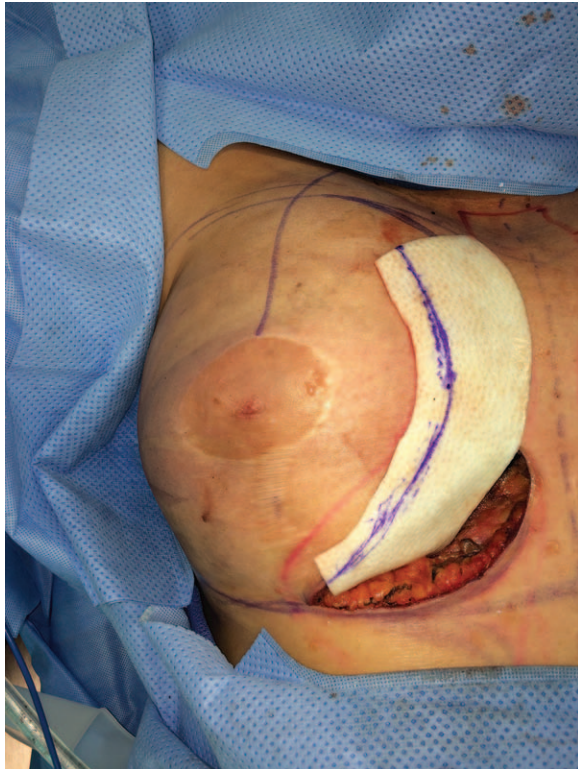

Fig. 3. Fixation of the Strattice.

space); (4) the intermammary web space was closed using 3 vertical columns of a continuous 2-0 Maxon suture (Covidien Corp, Minneapolis, Minn.): deep dermal tissue of the presternal skin flaps was secured onto the sternal periosteum (midline column) and pectoralis fascia (2 lateral columns). Preoperative marking with the needle dipped in methylene blue assumed particular importance by ensuring that each fixation stitch of this column hitched the dermis to a more superior position on the sternum, thus obliterating the entire intermammary web down-up. In addition, Tisseel (fibrin sealant; Baxter Healthcare, Deerfield, Ill.) was sprayed onto the presternal space to further enhance the adherence of this skin to the underlying sternum; (5) the medial border of the footprint (again corresponding to methylene blue needle marks) was secured down to the medial edge of the Strattice to redefine the footprint.

The incisions were closed over 2 drains tunneled along the medial border of each breast.

Postoperative Splinting Regimen

Immediately postoperatively, an external bolster dressing made of soft foam tape, designed to facilitate presternal skin adhesion, was used—in addition to a postsurgical bra (Veronique Style #455-V; Design-Veronique, Richmond, Calif.) with an extension flap to create compression in this area. This bra created

presternal compression and, through its ability to provide full-coverage support laterally, ensured that the breasts would not fall laterally (and lift off the presternal fixation like a tent) when the patient is supine. This was continued for 6 weeks. Thereafter, the presternal compression was stopped and 3 weeks of a standard push-up bra was used—again to prevent lateral pull and tenting medially.

DISCUSSION

The failure of traditional surgical options for treating congenital symmastia is not surprising: breast reduction alone is insufficient because large breasts by themselves are not the primary cause for the deformity in the first place—large-breasted women have well-defined cleavage, not symmastia. Reduction does not sufficiently address the 2 main structural issues that frame congenital symmastia—the blunted inframammary fold and intermammary webbing; liposuction alone, admittedly simple, relies too heavily on inflammatory responses to adhere presternal skin to the periosteum and could result in unwanted presternal hypertrophic scars; presternal quilting through transdermal incisions is effective, but is not enough by itself and recurrences are problematic.

The patient described in our report failed these traditional approaches. This operation described for the first time avoids the pitfalls of the traditional approaches in the following ways:

- To address the *conus*, we resected the medial crescent of the breast tissue to further enhance the shape of the medial pole of the breast. It is also important to reemphasize that this step is not a “reduction” in the classical sense—only a few grams of tissue were removed.
- Direct excision of the presternal tissues is sure-footed compared with liposuction, avoids a central scar, creates a clear plane for adhesions, and allows for placement of quilting sutures subdermally instead of needing transdermal bolster fixation.
- Approach through an *inframammary incision* concealed well, avoided disruption of the nipple (as compared to a periareolar approach), and most importantly allowed excellent exposure.
- *Biologic mesh* is a well-established safe adjunct in postcancer reconstruction and served as a powerful barrier to medial migration of the breast, defining the medial footprint sharply.
- *Presternal and medial skin plication* to a more superior position restored the intermammary space, redraped the medial skin envelope, and corrected the blunted inframammary folds. In our opinion, patients with congenital symmastia *do not have an*

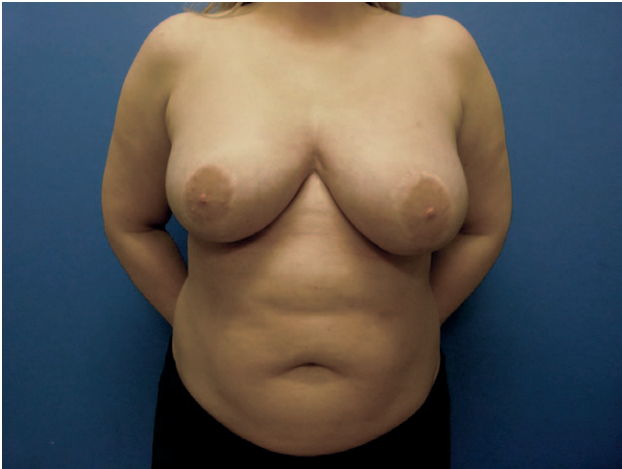

Fig. 4. 3-Month postoperative photograph.

excess skin envelope. Keeping this principle in mind, regarding our patient, we merely redraped the envelope and did not resect it.

- *Postoperative taping and compression:* 3 steps helped avoid the lateral pull on the breast when supine and prevented a tenting deformity in the intermammary web space. In the immediate postop phase, the presternal splint with lateral support of the breasts was critical—using the thong bra does not support the breasts laterally and is inadequate. Using a push-up bra seems counterintuitive because it is pushing the breasts inward, seeming to obliterate the presternal space, but it is extremely important to help avoid lateral deflection of the breasts that would distract the presternal skin from the deeper tissue. It also creates a zone of zero tension medially allowing robust healing. The 3-month result is shown in Figure 4.

CONCLUSION

Surgical correction of symmastia requires a step-wise operative strategy that combines fundamentals from both post mastectomy breast reconstruction techniques and the essentials of cosmetic surgery.

Rajiv Chandawarkar, MD

Department of Plastic Surgery, The Ohio State University
915 Olentangy River Road
Suite 2140, Columbus, OH 43212
E-mail: rajiv.chandawarkar@osumc.edu

REFERENCES

1. Spence RJ, Feldman JJ, Ryan JJ. Symmastia: the problem of medial confluence of the breasts. *Plast Reconstr Surg.* 1984;73:261–269.
2. Sillesen NH, Hölmich LR, Siensen HE, et al. Congenital symmastia revisited. *J Plast Reconstr Aesthet Surg.* 2012;65:1607–1613
3. Fallon SC, Hatef DA, McKnight AJ, et al. Congenital symmastia with concurrent fibroadenomas in a pediatric patient. *J Pediatr Surg.* 2013;48:255–257.
4. Selvaggi G, Giordano S, Ishak L. Symmastia: prevention and correction. *Ann Plast Surg.* 2010;65:455–461.
5. Foustanos A, Zavrdes H. Surgical reconstruction of iatrogenic symmastia. *Plast Reconstr Surg.* 2008;121:143e–144e.
6. Chasen PE, Cameron FS. Breast capsulorrhaphy revisited: a simple technique for complex problem. *Plast Reconstr Surg.* 2005;115:296–301.
7. Parsa FD, Parsa AA, Koehler SM, et al. Surgical correction of symmastia. *Plast Reconstr Surg.* 2010;125:1577–1579.
8. Spear SL, Dayan JH, Bogue D, et al. The “neosubpectoral” pocket for the correction of symmastia. *Plast Reconstr Surg.* 2009;124:695–703.
9. Nahabedian MY, Spear SL. Acellular dermal matrix for secondary procedures following prosthetic breast reconstruction. *Aesthet Surg J.* 2011;31(7 Suppl):38S–50S.
10. Blondeel PN, Hijjawi J, Depypere H, et al. Shaping the breast in aesthetic and reconstructive breast surgery: an easy three-step principle. *Plast Reconstr Surg.* 2009;123:455–462.