

Generalized acquired cutis laxa and urticarial dermatosis associated with κ -chain IgA micromolecular myeloma

Gaia Moretta, Francesco Moro, Luca Fania, Biagio Didona

IDI-IRCCS, Dermatological Research Hospital, Rome, Italy

Cutis laxa (CL) is a group of rare cutaneous disease, inherited or acquired, characterized by inelastic, redundant, wrinkled, loose skin, with loss of elasticity and features of premature aging. Genetic CL can be inherited with variable transmission: recessive, dominant and X-linked.^{1,2} The clinical outcome and life expectancy are variable and depend on the disease severity and systemic involvement: localized CL guarantees normal life expectancy while generalized forms can be fatal. Acquired CL (ACL) is a rare subtype which usually occurs in the adulthood. There are two main forms of ACL, type 1 and type 2. In Type 1 ACL, which can be either localized or generalized with systemic involvement, the elastin damage can occur in both inflammatory and non-inflammatory areas. Type 2 is a localized form where the elastin damage is restricted to the inflammatory area without systemic involvement.^{3,4} ACL has been associated with many different diseases: hematological disorders (such as heavy chain deposition disease, light chain deposition disease, multiple myeloma and monoclonal gammopathy of undetermined significance), infections (such as toxocara canis, borrelia burgdorferi, treponema pallidum and onchocerca volvulus), inflammatory diseases (including urticaria, systemic lupus erythematosus, dermatitis herpetiformis), renal alterations, connective tissue diseases, alpha-1 antitrypsin deficiency, amyloidosis and mastocytosis.⁵ Some forms of ACL can be induced also by drugs such as isoniazid and penicillin or by arthropod bite reactions.¹ In patients with ACL low lysyl oxidase activity, high cathepsin G levels, and reduced alpha-1-antitrypsin have been demonstrated: these factors presumably can determine a decrease in cutaneous elastin.⁶ Mutations in some inherited CL genes, which may increase susceptibility to inflammatory destruction of elastic fibers, have been reported in patients with ACL. Histologically, in ACL elastic fibers are reduced, especially in the papillary dermis.¹ As concerns therapeutic management of ACL, up to now a lot of drugs have been used such as antihistamines, corticosteroids, cyclosporine, azathioprine and dapsone

with controversial results. Early plastic surgical procedures are recommended to improve the progressive aging and wrinkled skin.

We report a case of a 39-year-old woman, who came to our attention for a chronic urticarial itching dermatosis associated with a progressive aging of the skin occurred from approximately one year. She has undergone multiple treatments as antihistamines, corticosteroids (prednisone 25 mg/day for three months) and cyclosporine (250 mg/day for four months), without any improvement. The physical examination showed anelastic and wrinkled skin on the face, arms, trunk and back, associated with urticarial lesions and an "orange peel" aspect of the paraumbilical area (Figure 1). We considered as differential diagnosis anethoderma, mid-dermal elastolysis, ACL, Ehlers-Danlos syndrome and pseudo-xanthoma elasticum. The patient underwent eye examination, total body CT, screening for chronic urticaria and immunological screening for connective tissue diseases (rheumatoid factors, anti-nuclear and anti-ENA antibodies), which returned normal findings. Therefore, a biopsy was performed for histological and ultrastructural examination and direct immunofluorescence. Microscopic aspects showed clustered or fragmented elastic fibers and inflammatory infiltrate in collagen (Figure 2). The electron microscopy examination revealed fragmented elastic fibers with residual fragments of electron dense materia filled in a macrophage (Figure 2). Direct immunofluorescence did not reveal any fluorescence. Therefore, the clinical, histological and electron microscopy results were suggestive for the diagnosis of generalized ACL. Considering that dapsone has been proved to be one of the most effective therapeutic option to reduce protease release of neutrophils, we decided to start a therapy with Dapsone 100 mg/day. After one month, the patient showed a complete disappearance of the urticarial lesions but she developed a fast alteration in renal function that lead to acute renal failure in two weeks (creatinine value: 3.6 mg/dl). A renal biopsy was then performed and histological examination revealed a proliferative extracapillary, focal necrotizing glomerulonephritis and cast-type tubulopathy nephropathy (myeloma kidney). Further evaluation revealed Bence-Jones proteinuria. Consequently, the patient underwent a bone medullary biopsy with immunofixation which showed a κ -chain IgA micromolecular myeloma. Thereafter, the patient started dialysis, and underwent chemotherapy with bortezomib (an anti-CD38 antibody therapy utilized in multiple myeloma) and dexam-

Correspondence: Luca Fania, IDI-IRCCS, via dei Monti di Creta 104, 00167, Rome, Italy.
E-mail: l.fania@idi.it

Key words: Cutis laxa, urticarial dermatoses, myeloma, rare cutaneous disease.

Contributions: GM and FM contributed equally to the work.

Conflict of interest: The authors declare no potential conflict of interest.

Funding: This article was partially supported by the "Progetto Ricerca Corrente - 2020" of the Italian Ministry of Health, Rome, Italy.

Please cite this article as: Moretta G, Moro F, Fania L, Didona B. Generalized acquired cutis laxa and urticarial dermatosis associated with κ -chain IgA micromolecular myeloma. *Dermatol Rep* 2021;13:9146.

Received for publication: 20 March 2021.
Revision received: 22 April 2021.
Accepted for publication: 22 April 2021.

This work is licensed under a Creative Commons Attribution-NonCommercial 4.0 International License (CC BY-NC 4.0).

©Copyright: the Author(s), 2021
Licensee PAGEPress, Italy
Dermatology Reports 2021; 13:9146
doi:10.4081/dr.2021.9146

ethasone (4 mg/day) for 4 months, followed by bone marrow transplantation. After one year the patient was in general good health but unfortunately presented only a mild improvement of the cutaneous disease.

In literature there are only a few cases of ACL associated to myeloma and generally dermatological symptoms occurs after the development of hematological alterations. Very recently Shalhout proposed the term Monoclonal Gammopathy Of Dermatological Significance (MGODS) to underline the cutaneous aspects of paraproteinemia.⁵ The recognition of skin lesions could suggest the progression from gammopathy to myeloma. As regards the pathogenesis, myeloma-associated immunoglobulin deposition is thought to result in a cell-mediated immune response and promotes phagocytic destruction of elastic fiber. As occurred in our patient, systemic treatment of myeloma is not effective to resolve ACL.

In conclusion, we reported an usual case of ACL and chronic urticarial dermatosis associated with κ -chain IgA micromolecular myeloma. Our case highlights the importance to evaluate an underlying plasma cell dyscrasias in all patients with cutaneous features of ACL.

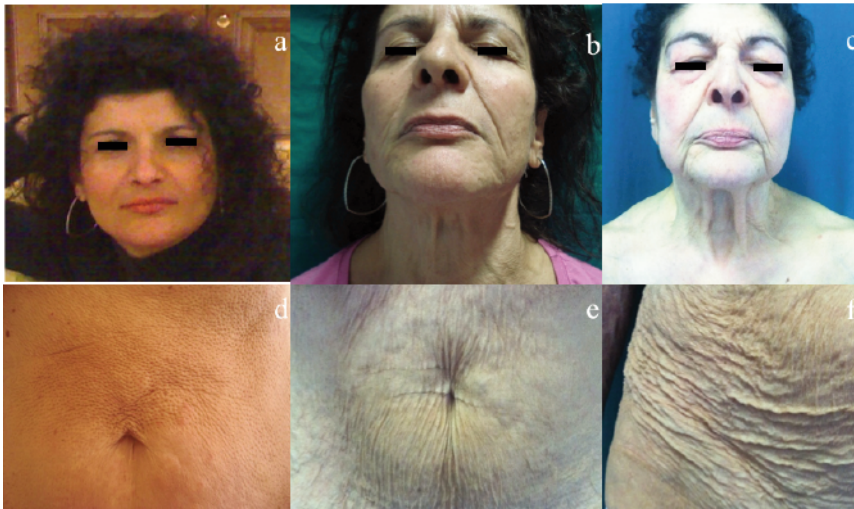

Figure 1. a) The patient before developing ACL; b) The patient after 12 months: aging of the face and the neck with wrinkled skin and increase of naso-labial folds; c) The patient after 18 months: progressive aging of the face with periocular wrinkles; d) Urticarial rash with “orange peel” skin; e-f) Loosening and wrinkles of periumbilical area.

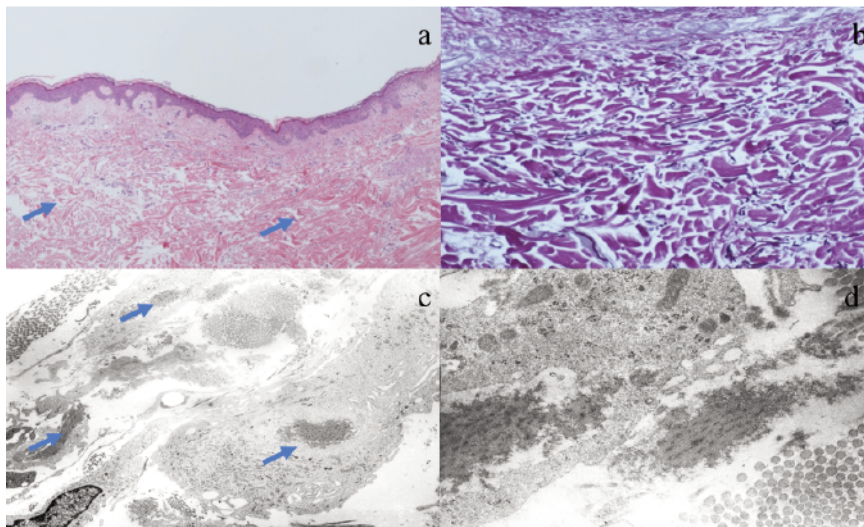


Figure 2. a,b) Histological examination: decreased elasticity of dermal tissue with clustered or fragmented elastic fibers; c,d) Electron microscopy examination: fragmented elastic fibers with residual fragments of electron dense materia filled in a macrophage.

References

1. Berk DR, Bentley DD, Bayliss SJ, et al. Cutis laxa: a review. *J Am Acad Dermatol* 2012;66:842.e1-17.
2. Mohamed M, Voet M, Gardeitchik T, Morava E. Cutis Laxa. *Adv Exp Med Biol* 2014;802:161-84.
3. Jain A. Acquired Cutis Laxa. *Turk J Haematol* 2020;37:212-3.
4. Nabatanz A, Da S, Male M, et al. Type II acquired cutis laxa associated with recurrent urticarial vasculitis: brief report. *Allergy Asthma Clin Immunol* 2020;16:1
5. Shalhout SZ, Nahas MR, Drews RE, Miller DM. Generalized Acquired Cutis Laxa Associated with Monoclonal Gammopathy of Dermatological Significance. *Case Rep Dermatol Med* 2020;2020:7480607.
6. Fornieri C, Quaglino D, Lungarella G, et al. Elastin production and degradation in cutis laxa acquisita. *J Invest Dermatol* 1994;103:583-8.