

Micturation related swelling of the scrotum

R. G. Regensburg · S. Klinkhamer ·
N. P. H. van Adrichem · A. Kooistra ·
I. A. M. J. Broeders

Received: 25 August 2010 / Accepted: 22 October 2010 / Published online: 10 November 2010
© The Author(s) 2010. This article is published with open access at Springerlink.com

Abstract Unlike small inguinal and femoral bladder hernias, massive bladder hernias into the scrotum, also named scrotal cystoceles, are rare. We describe and discuss the clinical appearance and management of a patient with a micturation related unilateral swelling of the scrotum.

Keywords Bladder · Scrotum · Cystocele · Hernia

Introduction

Unlike small inguinal and femoral bladder hernias, massive bladder hernias into the scrotum, also named scrotal cystoceles, are rare. We describe and discuss the clinical appearance and management of a patient with a micturation related unilateral swelling of the scrotum.

Case report

A 54-year-old man, without a significant medical history was seen in our outpatient clinic because of an intermittent right-sided scrotal swelling. At physical examination an apparently healthy, obese man was seen without further abnormalities. An ultrasound of the scrotum was scheduled for further evaluation. One week later he visited the emergency department with a sudden progression of the scrotal swelling. History revealed the swelling increased and decreased in size related to micturation, but was progressive

for the last couple of days and caused significant mechanical complaints. Physical examination showed a massive swelling of the right hemiscrotum, which was painful at palpation. After voiding, however, the swelling dramatically decreased in size. Filling the bladder with normal saline using a transurethral catheter again resulted in an increased swelling of the scrotum (Fig. 1). Ultrasound of the scrotum and lower abdomen showed herniation of the bladder into the right hemiscrotum. A computed tomography (CT) scan performed with contrast in the bladder showed a massive fluid collection in the right hemiscrotum (11.7 × 4.4 cm) in continuity with the bladder through a small hole (1.1 cm) in the groin. These images revealed that more than 70% of the total volume of the bladder was herniated into the scrotum through the medial canal (Fig. 2). A laparotomy was performed. A wide external inguinal annulus was seen with bladder herniation into the scrotum (Fig. 3). After preparation and repositioning, a Lichtenstein mesh repair was performed. The right testicle could be preserved during the procedure. Postoperative outcome was uneventful and the patient was discharged on the first postoperative day. At the outpatient clinic he presented in good condition without any complaints.

Discussion

The differential diagnosis of a painless unilateral scrotal swelling includes a hydrocele, spermatocele, varicocele (usually left sided), epididymal cyst, tumour, intestinal or omental hernia. This case report reminds us that if scrotal swelling is not apparent during examination it can be difficult to identify a scrotal cystocele. Although mostly asymptomatic, larger hernias can cause voiding complaints

R. G. Regensburg (✉) · S. Klinkhamer ·
N. P. H. van Adrichem · A. Kooistra · I. A. M. J. Broeders
Meander Medical Center, Amersfoort, Utrechtseweg 160,
3818 ES Amersfoort, The Netherlands
e-mail: rgregensburg@gmail.com

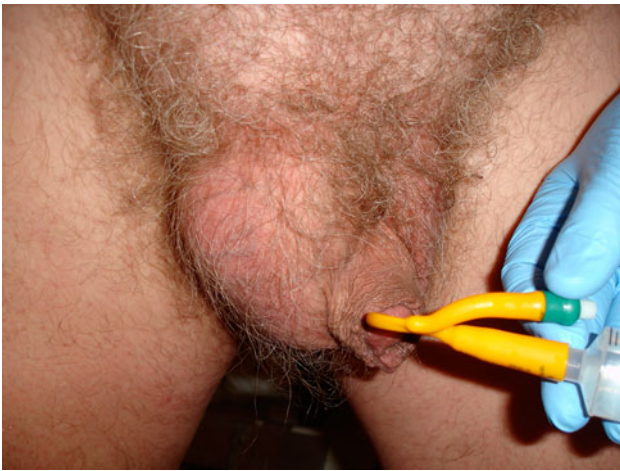

Fig. 1 Unilateral scrotal swelling after filling the bladder with saline

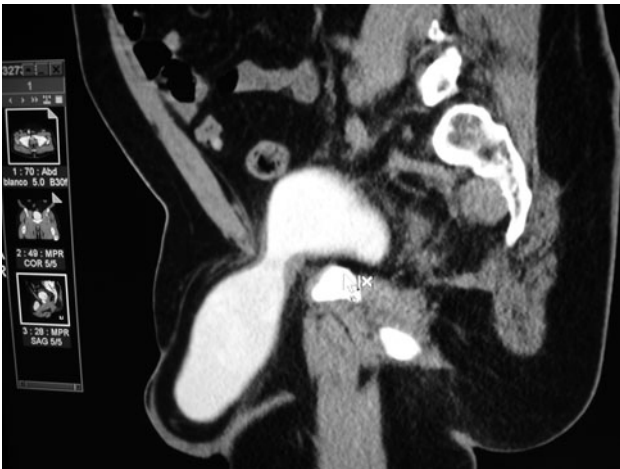

Fig. 2 Saggital computed tomography (CT) image with contrast in the bladder demonstrates bladder herniation

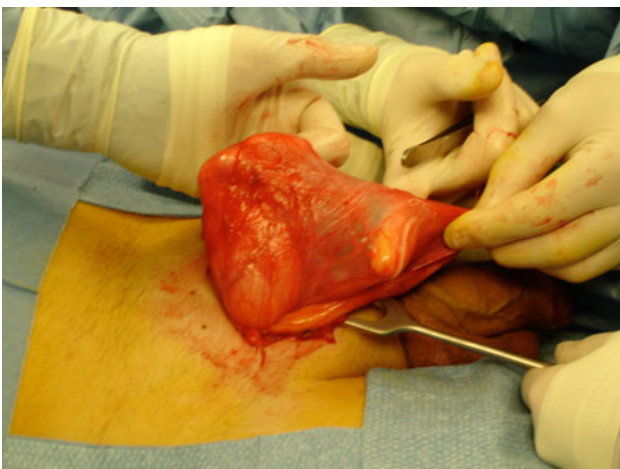


Fig. 3 Hernia sac during operation

related to bladder outlet obstruction and swelling of one side of the scrotum before micturation [1]. Patients frequently describe the need to manually compress the scrotum to empty the bladder [2]. This is an almost pathognomonic sign of a cystocele. Additional diagnostic tools to detect this condition are ultrasound, which features further differential diagnosis from other extratesticular cystic abnormalities [3, 4]. CT scan is also described as an important aid in diagnosing and outlining the anatomy of the affected area [5, 6]. Typically this condition affects obese men over 50 years of age. Pathophysiological causes include decreasing bladder tonus or increasing laxity of the surrounding tissue in combination with bladder outlet obstruction. Increased abdominal pressure due to obesity is an important factor [1, 7, 8]. If there is a true hernia of the bladder, patients can have uni- or bilateral hydronephrosis, and renal failure can even occur [9–13]. Other complications described are the formation of calculi in the herniated part of the bladder [14–16], bladder tumour [11], urosepsis [16], vesicocutaneous fistula [17] and bilateral vesico-ureteral reflux [12]. There are several treatment options, such as repositioning the protruded part of the bladder into the pelvis, or excising the affected part of the bladder. The latter should be done in case of a diverticula or tumour [10], but in other cases the best treatment option remains debatable. With a lower abdominal transverse incision, good exposure of the bladder and the inguinal area can be obtained at the same time [18]. Different methods of repairing the inguinal floor have been described. In this case report we used a Lichtenstein procedure, which has been shown to be effective [13]. In summary, when confronted with a case of a painless unilateral scrotal swelling, include a scrotal cystocele in the differential diagnosis. To identify this condition at physical examination the patient should be evaluated with and without a full bladder.

Open Access This article is distributed under the terms of the Creative Commons Attribution Noncommercial License which permits any noncommercial use, distribution, and reproduction in any medium, provided the original author(s) and source are credited.

References

1. Hisamatsu E, Sekido N, Tsutsumi M, Ishikawa S (2005) A case of a large inguinoscrotal bladder hernia secondary to benign prostatic obstruction. *Hinyokika Kyo* 51(6):393–397
2. Bell ED, Witherington R (1980) Bladder hernias. *Urology* 15(2):127–130
3. Catalano O (1997) US evaluation of inguinoscrotal bladder hernias: report of three cases. *Clin Imaging* 21(2):126–128
4. Weingardt JP, Russ PD, Ch'en IY, Robb LD, Pomerantz H (1996) Scrotal cystocele detected by sonography. *J Ultrasound Med* 15(7):539–542
5. Catalano O (1995) Computed tomography findings in scrotal cystocele. *Eur J Radiol* 15 21(2):126–127

6. Andaç N, Baltacıoğlu F, Tüney D, Cımsıt NC, Ekinci G, Biren T (2002) Inguinoscrotal bladder herniation: is CT a useful tool in diagnosis? *Clin Imaging* 26(5):347–348
7. Gomella LG, Spires SM, Burton JM, Ram MD, Flanigan RC (1985) The surgical implications of herniation of the urinary bladder. *Arch Surg* 120(8):964–7
8. Croushore JH, Black RB (1979) Scrotal cystocele. *J Urol* 121(4):541–542
9. Neulander EZ, Kaneti J, Klain J, Mizrahi S (2007) Obstructive uropathy secondary to inguinal bladder hernia: case report and review of the literature. *Can J Urol* 14(6):3761–3763
10. Thompson JE Jr, Taylor JB, Nazarian N, Bennion RS (1986) Massive inguinal scrotal bladder hernias: a review of the literature with 2 new cases. *J Urol* 136(6):1299–1301
11. Barquin OP, Madsen PO (1967) Scrotal herniation of the lower urinary tract. *J Urol* 98(4):508–511
12. Markewitz M, Badlani G (1983) Massive scrotal herniation of bladder with torsion of trigone. *Urology* 22(4):441–443
13. Wagner AA, Arcand P, Bamberger MH (2004) Acute renal failure resulting from huge inguinal bladder hernia. *Urology* 64(1):156–157
14. Ng AC, Leung AK, Robson WL (2007) Urinary bladder calculi in a sliding vesical-inguinal-scrotal hernia diagnosed preoperatively by plain abdominal radiography. *Adv Ther* 24(5):1016–1019
15. Ptochos A, Iosifidis N (2002) Lithiasic inguinoscrotal herniation of the bladder secondary to prostate enlargement. *Acta Radiol* 43(5):543–544
16. Postma MP, Smith R (1986) Scrotal cystocele with bladder calculi (case report). *AJR Am J Roentgenol* 147(2):287–288
17. Manikandan R, Burke Y, Srirangam SJ, Collins GN (2003) Vesicocutaneous fistula: an unusual complication of inguinoscrotal hernia. *Int J Urol* 10(12):667–668
18. Redman JF, Williams EW, Meacham KR, Scriber LJ (1973) The treatment of massive scrotal herniation of the bladder. *J Urol* 110(1):59–61