

Treatment Effect of Combined Surgical Maxillary Expansion and Mandibular Setback in Skeletal Class III

Abstract

The purpose of this case report is to describe and discuss a combined surgical and orthodontic technique for the management of transverse maxillary deficiency and mandibular prognathism in the treatment of skeletal Class III malocclusion in a mature patient. Skeletal Class III malocclusion can present with maxillary deficiency or retrognathism, mandibular excess or prognathism, or a combination. The maxillary arch is narrow and often requires expansion. A 25-year-old patient presented with a constricted maxilla, a skeletal Class III malocclusion with a large mandible, Angle's Class III malocclusion, retroclined lower incisors, proclined upper incisors, crowding of maxillary and mandibular teeth, and bilateral posterior crossbite. The case report shows that an adult patient with Class III malocclusion (constricted maxilla and large mandible) can be treated with rapid maxillary expansion accompanied by bilateral maxillary osteotomies, followed by a reduction bilateral sagittal split osteotomy (BSSO). As the patient was 25 years old with a bilateral crossbite, a surgically assisted rapid maxillary expansion procedure was performed. As the diastema space was available at the end of expansion, it proved to be beneficial for the presurgical decompensation of Class III, thus creating a negative overjet, followed by which a BSSO setback was done.

Keywords: *Class III malocclusion, mandibular prognathism, mandibular setback, surgically assisted palatal expansion, transverse maxillary deficiency*

Introduction

Class III skeletal malocclusion may result from mandibular prognathism, maxillary retrusion, or a combination of both.^[1] Maxillary deficiency is more frequent, accounting for 60%–63% of the causes of this type of malocclusion.^[2] Maxillary skeletal deficiency can also be associated with deficiency of the middle third of the face, confirmed by the contour of the zygomatic bone, orbital ridge, and subpupillary area.^[3] Intraoral examination reveals increased axial inclination of the maxillary incisors and decreased axial inclination of the mandibular incisors in an attempt to mask the real maxillomandibular discrepancy. Bone discrepancy is reflected in the facial soft tissues, causing an unfavorable esthetic impact, which may be aggravated by the facial asymmetry present in most cases.^[4,5] Patients with these disharmonies are usually treated with a combination of orthodontic and orthognathic surgical procedures to improve occlusion and facial esthetics.^[6]

This is an open access journal, and articles are distributed under the terms of the Creative Commons Attribution-NonCommercial-ShareAlike 4.0 License, which allows others to remix, tweak, and build upon the work non-commercially, as long as appropriate credit is given and the new creations are licensed under the identical terms.

For reprints contact: WKHLRPMedknow_reprints@wolterskluwer.com

This report presents the treatment of a Class III skeletal malocclusion with a transverse and sagittal discrepancy, with a severity that demanded an orthodontic and surgical treatment for the establishment of normal occlusion and adequate facial esthetics.

Case Report

A male patient aged 25 years came to the Department of Orthodontics, SDM College of Dental Sciences, a constituent unit of Shri Dharmasthala Manjunatheshwara University, Dharwad, India, with a chief complaint of irregular teeth. Clinical examination revealed Angle's Class III subdivision malocclusion with a narrow maxilla, posterior crossbite, deviation of the mandibular midline to the right, and mild crowding in the mandibular anterior region, with proclination of the maxillary anteriors [Figure 1].

On a lateral cephalogram analysis, the patient presented with a Class III skeletal pattern with an ANB value of -5° and a Wits appraisal value of -10 mm. The patient had an orthognathic maxilla with a

How to cite this article: Pradhan T, Gowda AR, Jayade V, Gopalkrishnan K, Patil AK. Treatment effect of combined surgical maxillary expansion and mandibular setback in skeletal class III. *Contemp Clin Dent* 2021;12:169-73.

**Tejashri Pradhan,
Ajith R. Gowda¹,
Vijay Jayade²,
K. Gopalkrishnan³,
Anand K. Patil²**

Department of Orthodontics, KLE VK Institute of Dental Sciences, Belgaum, ¹Dental Sense, Mysore, Departments of ²Orthodontics and ³Oral Surgery, SDM College of Dental Sciences, Constituent Unit of Shri Dharmasthala Manjunatheshwara University, Dharwad, Karnataka, India

Submitted : 13-Apr-2020

Revised : 11-Jun-2020

Accepted : 22-Jul-2020

Published : 14-Jun-2021

Address for correspondence:

*Dr. Tejashri Pradhan,
Department of Orthodontics,
KLE VK Institute of Dental
Sciences, Belgaum, Karnataka,
India.*

E-mail: drtejashri73@gmail.com

Access this article online

Website:

www.contempclindent.org

DOI: 10.4103/ccd.ccd_290_20

Quick Response Code:



SNA value of 83° and a prognathic mandible with a SNB of 88°. The upper incisors were proclined with a UI-SN value of 122°, and the lower incisors were retroclined with a LI to MP value of 80°; hence, a typical Class III natural compensation was seen [Figure 2 and Table 1].

The analysis of plaster models confirmed a narrow maxilla with a bilateral posterior crossbite, negative dentoalveolar discrepancy in both the arches, an overjet of 1.0 mm, and an overbite of 1.0 mm.

The main goals of the orthodontic-surgical treatment were to achieve maxillary expansion and a mandibular setback for the correction of the Class III skeletal and dental malocclusion [Figure 3]. Surgical maxillary expansion with the creation of a midline diastema and retroclination of the maxillary incisors, while maintaining the anchorage with the use of modified transpalatal arch [Figure 4], was the decided treatment plan. In the mandibular arch, proclination of the mandibular incisors by increasing their axial inclination was carried out, which accentuated the negative overjet, thus permitting more amount of skeletal correction. The presurgical decompensation procedure created a negative overjet of -4 mm. Initially, surgery was performed to split the mid-palatine raphe, and a Hyrax expander was placed immediately after the surgery to promote the rapid expansion of the maxilla with two activations per day. The placement of buccal corticotomies decreased the resistance offered by the maxilla during expansion [Figure 5].

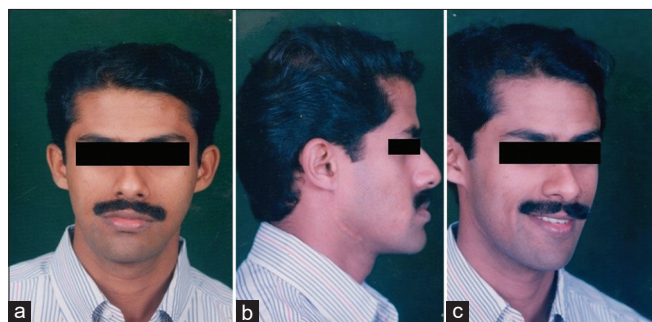


Figure 1: (a-c) Extraoral pictures

After a 10 mm of diastema was achieved following the maximally expansion, fixed mechanotherapy (straight wire appliance with Roth prescription slot 0.022" × 0.28") was started. A sequence of 0.014" to 0.021 × 0.025" NiTi and stainless steel wires were placed [Figure 4].

Subsequently, retraction of the maxillary incisors was performed, maintaining the anchorage with a modified transpalatal arch (with premolar extensions) [Figure 6]. The intercuspation was checked by occluding the

Table 1: Cephalometric values

Measurements	Norm	Pretreatment	Posttreatment
ANB	2°	-5°	-1°
A \perp -B \perp -L	-1	-10	-3
Wits	0	-10 (B ahead)	-6 (B ahead)
Harvold		42	36
Vertical			
SN-GoGn	32°	30°	27°
FH-GoMe	25°	24	20
Maxillary			
SNA	82°	83°	83°
A \perp -N \perp -L	1	2 ahead	2 ahead
Mandibular			
SNB	80°	88°	84°
B \perp -N \perp -L		12(B ahead)	5 (B ahead)
GoPog	83.7	85	76
Saddle angle		123°	123°
Dental			
UI to SN	102±2	122°	116°
UI to NA	22/4	40°/13	39°/10
UI to APog		28°/9	28°/7
LI to MP	90°	80°	87°
LI to NB	25/4	20°/4	20°/3.5
LI to APog		27°/7	26°/3
Interincisal angle	130±5	125°	127°
Soft tissue			
E line	U=-4, L=-2	U=4, L=1	U=4, L=1
H line		L=3	L=2
S line	U=0, L=0	U=4, L=1	U=2.5, L=0
Nasolabial angle	102±8	120°	108°

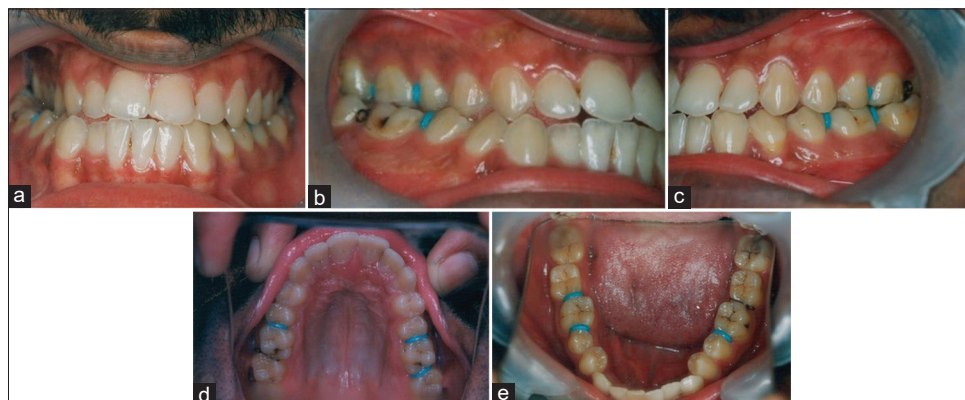


Figure 2: (a-e) Intraoral pictures

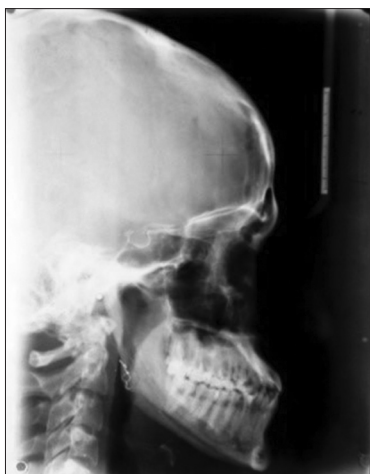

Figure 3: Pretreatment lateral cephalogram

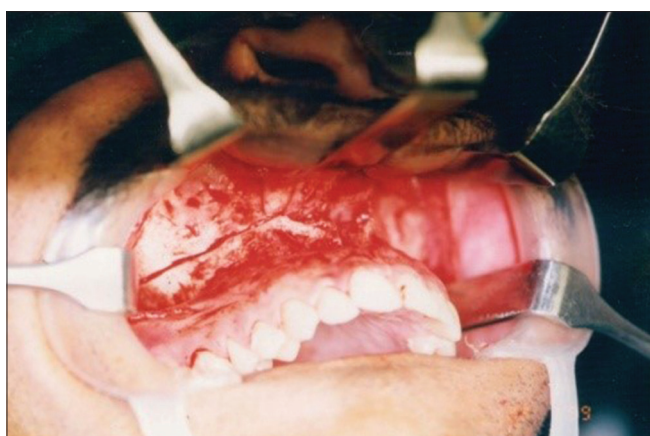

Figure 4: Osteotomy cuts

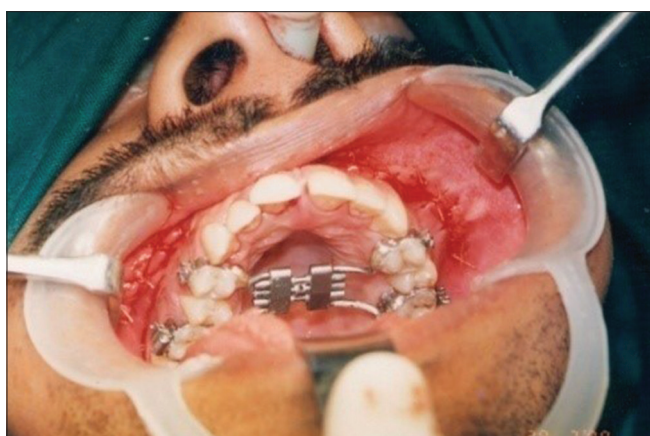

Figure 5: Surgical expansion

plaster models that were obtained periodically until satisfactory occlusion was attained for performing the surgery [Figure 7]. Presurgical intraoral preparation was done by the placement of crimpable hooks in the interbracket spans between all the teeth for intermaxillary fixation during the surgical process [Figure 8].

Surgery was planned according to facial analysis, predictive cephalometric tracing, and preparation of the surgical splint. Postsurgical orthodontics was carried out after the surgery, in order to achieve a Class I molar and canine relationship normal overjet and overbite and coincident midlines. After the active treatment phase, a wraparound-type retention plate was used in the maxillary arch and a stainless steel 3 × 3 lingual canine-to-canine retainer was placed in the mandibular arch.

At the end of treatment, a functional occlusion, normal overjet and overbite, adequate intercuspation, with a Class I molar and canine relationship, coincident midlines, and normal lateral and protrusive excursions were achieved. Mandibular prognathism was eliminated and facial esthetics considerably improved [Figures 9-11].

Discussion

Achieving planned results is a challenging process when the malocclusion is of a skeletal origin. Hence, a multidisciplinary approach is required in such cases. The surgical decompensation should also be carried out by keeping the final result in mind.

This case showed features of a typical Class III malocclusion with a prognathic mandible and a constricted maxillary arch. As the upper incisor proclination was increased, it was necessary to correct its angulation and create a proper negative overjet so that the prognathic mandible could be set back.

When the discrepancy is severe, extractions are planned to align and/or correct the molar relation or incisor proclination. Because of the need for correction of bilateral posterior crossbite and improving the incisor angulation, expansion of the constricted maxillary arch was needed.^[7] A surgical approach was chosen as the discrepancy was severe and more skeletal correction was required than dental. This was done using the surgically assisted rapid palatal expansion (SARPE) procedure. The wide range of variation (15–27 years)^[8] for closure of the mid-palatal suture underlines the futility of being dogmatic over an upper age limit for RME before having recourse to surgery. As the patient was 25-year-old, a surgically assisted rapid maxillary expansion procedure was done. The suggested procedures for surgically assisted RME are as follows: palatal osteotomy (midline or side of the midline), bilateral palatal osteotomies, lateral maxillary osteotomies, and anterior maxillary osteotomies.^[9] Later, the incisor proclination was corrected, and a negative overjet was created utilizing the diastema space as a part of presurgical decompensation. Furthermore, the retroclined lower incisors were made upright on the basal bone, and a bilateral sagittal split osteotomy was carried to position the mandible back.

On comparative cephalometric analysis, the ANB angle improved from -5° to -1° , proving an improvement in profile posttreatment. The upper incisor proclination improved from 122° to 116° showing a favorable

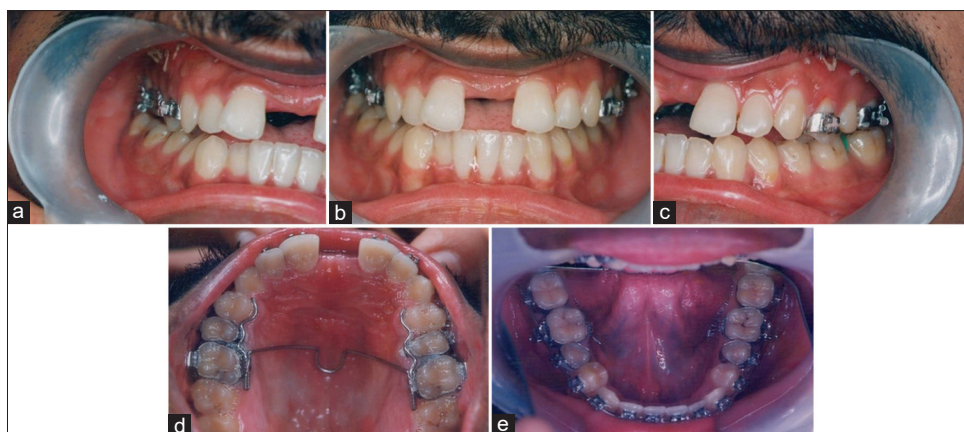


Figure 6: (a-e) Postexpansion

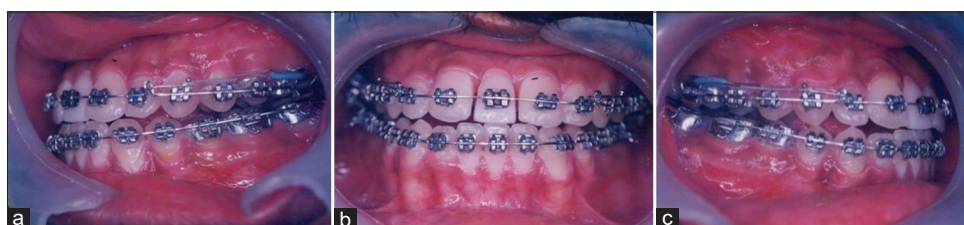


Figure 7: (a-c) Decompensation

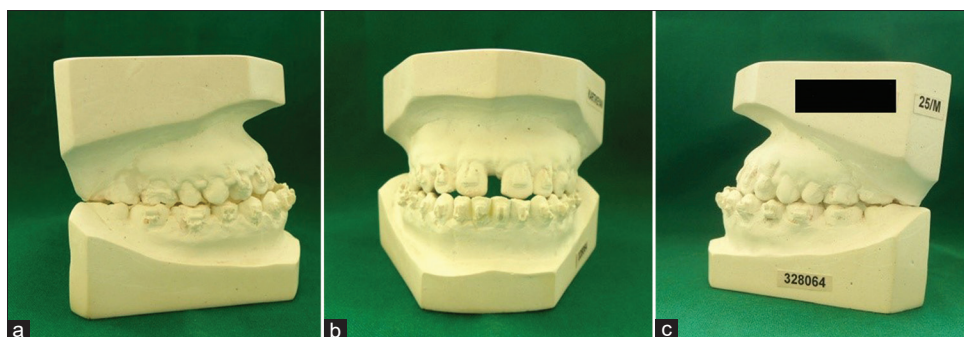


Figure 8: (a-c) Decompensation casts

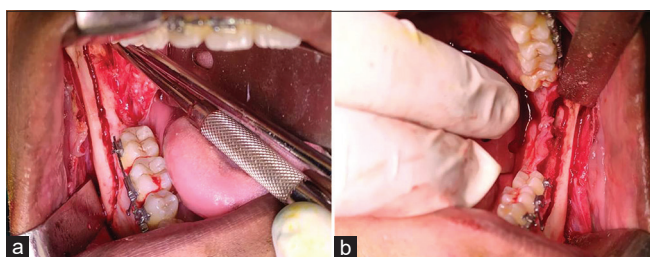


Figure 9: (a and b) Bilateral sagittal split osteotomy

posttreatment outcome. The posttreatment interincisal angle came to a more ideal value of 127° . The posttreatment L1-MP angle improved from 80° to 87° , which according to Tweed's is ideal for a stable treatment result. The nasolabial angle improved to a near ideal 108° .

It is evident from the superimposition on the cranial base that there was a bodily setback of the mandibular

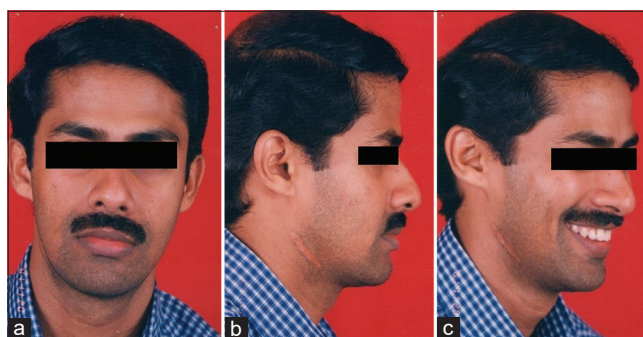


Figure 10: (a-c) Post-treatment extraoral photographs

skeletal base achieving ideal positive overjet. Furthermore, the expansion of the maxilla and the meticulous management of the expansion space for decompensation also improved the final upper incisor position and angulation [Figures 12 and 13].

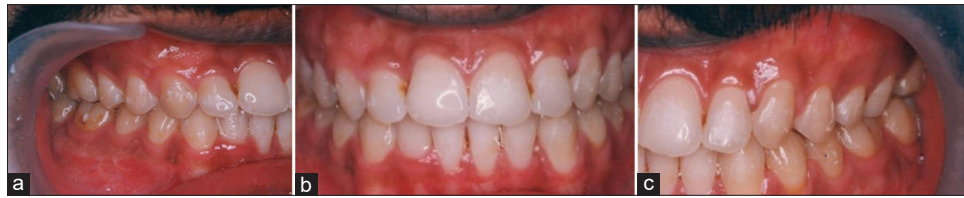

Figure 11: (a-c) Postintraoral photographs

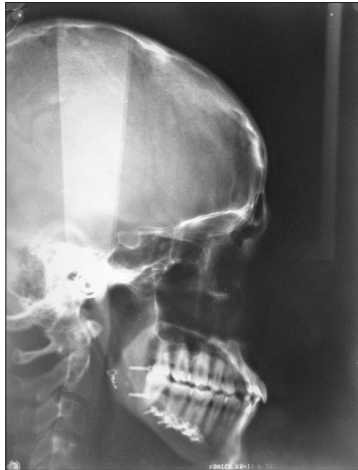

Figure 12: Postlateral cephalogram

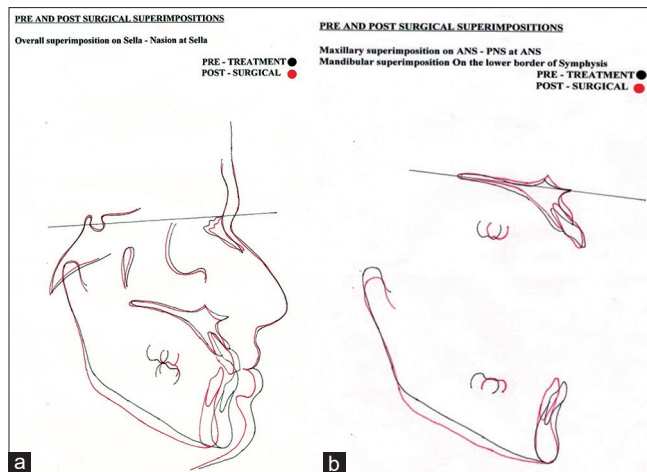


Figure 13: (a and b) Superimposition

The total treatment duration required for completion of the treatment was 2 years and 4 months.

Conclusion

In the present case report, the management of the adult Class III patient with constricted maxilla and a prognathic mandible is shown. We first initiated the surgical orthodontic procedure for the correction of crossbite by SARPE, where the decompensation of the maxillary dentition was achieved by utilizing the space obtained by expansion, creating a negative overjet. Such an approach should be used when a skeletal maxillary constriction is present rather than performing extractions.

The mandibular setback procedure was performed post the surgical expansion to correct the sagittal discrepancy. This new approach achieved ideal skeletal, soft tissue, and dental outcomes which will aid in the long-term stability of orthodontic treatment.

Declaration of patient consent

The authors certify that they have obtained all appropriate patient consent forms. In the form the patient(s) has/have given his/her/their consent for his/her/their images and other clinical information to be reported in the journal. The patients understand that their names and initials will not be published and due efforts will be made to conceal their identity, but anonymity cannot be guaranteed.

Financial support and sponsorship

Nil.

Conflicts of interest

There are no conflicts of interest.

References

1. Tavares CA, Orth D, Scheffer M. Surgically assisted rapid palatal expansion (SARPE) prior to combined Le Fort I and sagittal osteotomies: A case report. *Int J Adult Orthod Orthognath Surg* 2001;16:200-6.
2. Potnis SS, Betigiri A, Patni V. Surgically assisted rapid palatal expansion and bilateral sagittal split osteotomy in an adult patient with class III malocclusion. *J Dent Allied Sci* 2012;1:34-6.
3. Takeuchi M, Tanaka E, Nonoyama D, Aoyama J, Tanne K. An adult case of skeletal open bite with a severely narrowed maxillary dental arch. *Angle Orthod* 2002;72:362-70.
4. Bergamo AZ, Andruccioli MC, Romano FL, Ferreira JD, Matsumoto MA. Orthodontic-surgical treatment of class III malocclusion with mandibular asymmetry. *Braz Dent J* 2011;22:151-6.
5. Thiesen G, Gribel BF, Freitas MP. Facial asymmetry: A current review. *Dental Press J Orthod* 2015;20:110-25.
6. Jose Cherackal G, Thomas E, Prathap A. Combined Orthodontic and Surgical Approach in the Correction of a Class III Skeletal Malocclusion with Mandibular Prognathism and Vertical Maxillary Excess Using Bimaxillary Osteotomy. *Case Rep Dent* 2013;2013:797846.
7. Gujar A, Rani MS, Durgekar SG. Combination of expansion and orthognathic surgery in a severe hyperdivergent skeletal Class III malocclusion. *APOS Trends Orthod* 2016;6:312-8.
8. Persson M, Thilander B. Palatal suture closure in man from 15-35 years of age. *Am J Orthod* 1977;72:42-52.
9. Timms DJ. *Rapid Maxillary Expansion*. Chicago: Quintessence; 1981. p. 105-7.