

CASE REPORT

A child with mastocytosis and lymphomatoid papulosis

Henriette Juel Lange¹, Lone Agertoft², Michael Boe Møller³, Ole Clemmensen³, Thomas Kristensen³, Hanne Vestergaard⁴, Charlotte G. Mørtz¹, Carsten Bindslev-Jensen¹ & Sigurd Broesby-Olsen¹ on behalf of Mastocytosis Centre Odense University Hospital (MastOUH)

¹Department of Dermatology and Allergy Centre, Odense University Hospital, Sdr. Boulevard 29, 5000 Odense C, Denmark

²Hans Christian Andersen Children's Hospital, Odense University Hospital, Sdr. Boulevard 29, 5000 Odense C, Denmark

³Department of Pathology, Odense University Hospital, Sdr. Boulevard 29, 5000 Odense C, Denmark

⁴Department of Haematology, Odense University Hospital, Sdr. Boulevard 29, 5000 Odense C, Denmark

Correspondence

Sigurd Broesby-Olsen, Mastocytosis Centre Odense University Hospital – MastOUH, Department of Dermatology and Allergy Centre, Odense University Hospital, Sdr. Boulevard 29, 5000 Odense C, Denmark. Tel: +45 66113333; Fax: +45 66123819; E-mail: sigurd.broesby-olsen@rsyd.dk

Funding Information

No sources of funding were declared for this study.

Received: 20 October 2015; Revised: 6

January 2016; Accepted: 9 March 2016

Clinical Case Reports 2016; 4(5): 517–519

doi: 10.1002/ccr3.551

Key Clinical Message

A change in clinical behavior of a disease should prompt search for differential diagnoses. Here, the appearance of ulcerated skin nodules in a preexisting cutaneous mastocytosis revealed a concurrent lymphomatoid papulosis – a CD30+ lymphoproliferative skin disease with histological features of a malignant lymphoma, but with a benign self-healing course.

Keywords

Lymphomatoid papulosis, mastocytosis, urticaria pigmentosa.

A 10-year-old boy presented at the age of 12 months with a gradual onset of small, brown elements on the trunk and extremities (Fig. 1A). Rubbing of the lesions resulted in a wheal and flare reaction (Darier's sign) and the diagnosis of maculopapular cutaneous mastocytosis was confirmed histologically by the demonstration of infiltrates of tryptase-positive MCs in lesional skin. The KIT D816V mutation was not detectable in blood or skin. Routine laboratory investigations were normal including a low basal serum-tryptase (3.0 µg/L). During the course symptoms have been mild, and treatment not necessary. A gradual fading of skin lesions has been observed. In addition to mastocytosis the child also had an early history of milk and egg allergy, atopic dermatitis, and mild asthma.

From the age of 9 years a new type of skin lesions appeared, consisting of 3–5 mm symmetrically distributed, scaly papules mainly on the extremities (Fig. 1B). Some of the elements were ulcerated with crust formation. Physical examination was unremarkable and complete blood cell count, creatinine, liver function tests and serum-tryptase

were all normal. A punch biopsy from lesional skin showed a pleomorphic CD30-positive T-cell lymphocytic infiltrate with hardly any MCs (Fig. 2). A T-cell receptor gene rearrangement (TCR) analysis showed clonality, whereas as the KIT D816V mutation was not detectable in these skin lesions. These features confirmed the diagnosis lymphomatoid papulosis (LyP). Treatment with potent topical steroid was initiated with a slow response. After the initial outbreak, recurrent crops of skin lesions were seen, however, lesions were fewer, smaller, and occurred less frequently. Over 1 year a significant improvement has been observed and the child is thriving well. Hematologic parameters and objective exams have been unremarkable. Treatment with methotrexate has been considered but so far not found indicated.

Discussion

To our knowledge, this is the first report on concomitant LyP and mastocytosis. Even though both diseases are rare

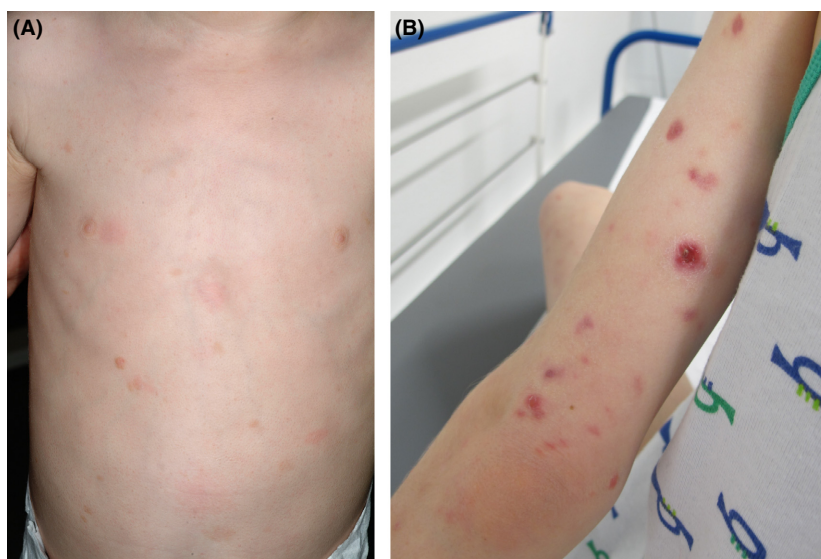


Figure 1. A: Discrete mastocytosis skin lesions (urticaria pigmentosa) with small reddish-brown elements distributed over the trunk at the age of 2 years. B: Lymphomatoid papulosis lesions with ulceration and crusting on the patients right arm at the age of 9 years.

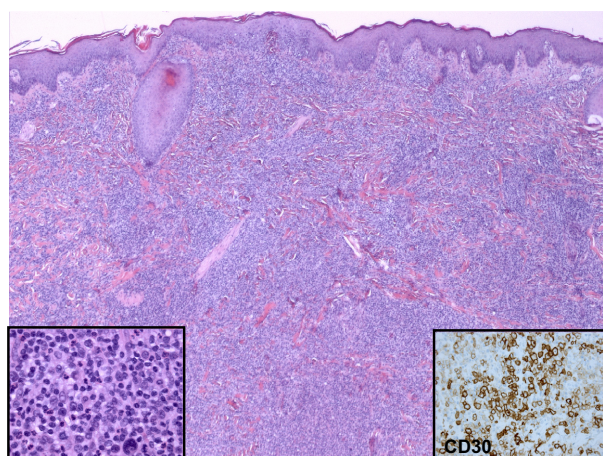


Figure 2. Punch biopsy from the arm of the patient. Throughout the dermis there is a diffuse, dense lymphocytic infiltrate of large cells with pleomorphic nuclei and prominent nucleoli (close up, left inset). The large cells are CD30 positive T lymphocytes (right inset). The epidermis is uninvolved.

and may display features of clonality, it is possible that the present concurrence should be regarded as fortuitous.

The true prevalence of pediatric mastocytosis is not known, but estimated to be similar to adult mastocytosis and around 10 in 100,000 [1]. Whereas adult mastocytosis is almost always a systemic disease with a clonal proliferation of neoplastic MCs caused by the somatic KIT D816V mutation, pediatric mastocytosis is mostly limited to the skin and 80–90% of affected children exhibit a spontaneous remission before puberty [2]. The KIT

D816V mutation can only be detected in 25–35% of affected children [3], however, mutations in KIT outside exon 17 are reportedly prevalent, indicating that pediatric mastocytosis in many cases is a clonal disease associated with somatic mutations in KIT [4].

LyP is classified among CD30+ cutaneous lymphoproliferative diseases [5]. The prevalence of LyP have been estimated to be 1.2–1.9 per million in adults [6]. Pediatric cases have rarely been described and reportedly associated with atopy in up to 60% [7], as also found in the present case. Clinically it is characterized by recurrent crops of erythematous papules and nodules that resolve after weeks to months, leaving atrophic scars.

Potential differential diagnoses in childhood include insect bites, pityriasis lichenoides (PL), and CD30-positive, anaplastic large T-cell lymphoma among others. Differentiating LyP from skin lesions caused by insects is usually straightforward clinically as well as histologically. Skin lesions in PL are usually smaller and of shorter duration than LyP and histologically, lichenoid infiltrates without CD30-positive T lymphocytes are usually seen, but in atypical cases a clear distinction between LyP and PL may be difficult to make. An important and sometimes difficult differential diagnosis of LyP, type C is CD30-positive anaplastic large T-cell lymphoma, and in rare cases the histological distinction is impossible and clinical course decisive.

In adult patients a malignant transformation has been described with mycosis fungoides, Hodgkin lymphoma and CD30 positive large-cell lymphoma being most common. In pediatric LyP the absolute risk for

transformation is estimated to be very low, however, has rarely been reported, for example, by Nijsten and colleagues who described development of non-Hodgkin lymphoma in 3 of 35 children with LyP [7]. Thus, a follow-up in line with adults is recommended [5].

In the present case we did not detect evidence of associations between the pre-existing mastocytosis and development of LyP. Cellular lineages involved differ, and we did not detect histologic signs of MC infiltration in the LyP skin lesions.

In summary, we report a unique case of a child with concomitant LyP and cutaneous mastocytosis. Both diseases are rare and have to our knowledge not been reported together before. Even though it seems probable that the two conditions occurred together by chance further studies are needed to elucidate if any associations between LyP and mastocytosis exist.

Conflict of interest disclosures

None declared.

References

1. Cohen, S. S., S. Skovbo, H. Vestergaard, T. Kristensen, M. Moller, C. Bindslev-Jensen, et al. 2014. Epidemiology of systemic mastocytosis in Denmark. *Br. J. Haematol.* 166:521–528.
2. Uzzaman, A., I. Maric, P. Noel, B. V. Kettelhut, D. D. Metcalfe, and M. C. Carter. 2009. Pediatric-onset mastocytosis: a long term clinical follow-up and correlation with bone marrow histopathology. *Pediatr. Blood Cancer* 53:629–634.
3. Meni, C., J. Bruneau, S. Geogin-Lavialle, L. Le Sache de Peuffeilhoux, G. Damaj, et al. 2015. Paediatric mastocytosis: a systematic review of 1747 cases. *Br. J. Dermatol.* 172: 642–651.
4. Bodemer, C., O. Hermine, F. Palmerini, Y. Yang, C. Grandpeix-Guyodo, P. S. Leventhal, et al. 2010. Pediatric mastocytosis is a clonal disease associated with (DV)-V-816 and other activating c-KIT mutations. *J. Invest. Dermatol.* 130:804–815.
5. Kempf, W., K. Pfaltz, M. H. Vermeer, A. Cozzio, P. L. Ortiz-Romero, M. Bagot, et al. 2011. EORTC, ISCL, and USCLC consensus recommendations for the treatment of primary cutaneous CD30-positive lymphoproliferative disorders: lymphomatoid papulosis and primary cutaneous anaplastic large-cell lymphoma. *Blood* 118:4024–4035.
6. Wang, H. H., L. Lach, and M. E. Kadin. 1992. Epidemiology of lymphomatoid papulosis. *Cancer* 70:2951–2957.
7. Nijsten, T., C. Curiel-Lewandrowski, and M. E. Kadin. 2004. Lymphomatoid papulosis in children: a retrospective cohort study of 35 cases. *Arch. Dermatol.* 140:306–312.