

Hemipelvectomy- only a salvage therapy?

Christian Wedemeyer,¹
Max Daniel Kauther²

¹Department of Orthopedic Surgery,
University Duisburg-Essen, Essen;

²Department of Trauma Surgery,
University Duisburg-Essen, Essen,
Germany

Abstract

After the first hemipelvectomy in 1891 significant advances have been made in the fields of preoperative diagnosis, surgical technique and adjuvant treatment in patients with pelvic tumors. The challenging surgical removal of these rare malignant bone or soft tissue tumors accompanied by interdisciplinary therapy is mostly the only chance of cure, but bares the risk of intensive bleeding and infection. The reconstruction after hemipelvectomy is of importance for the later outcome and quality of life for the patient. Here, plastic surgery with microvascular free flaps or local rotational flaps improved the reconstruction and reduced infection rates. Average local recurrence rates of 14% demonstrate good surgical results, but 5 year survival rates of only 50% are described for some tumor entities, showing the importance of a multimodal collaboration. On a basis of a selective literature review the history, indications, treatment options and outcome of hemipelvectomies are presented.

Introduction

The first hemipelvectomy was performed by Billroth in 1891. The patient survived only a few hours. In 1893, Jabulay operated on a patient who died immediately after the procedure. The first successful hemipelvectomy in terms of survival was performed by Girard in 1895. In 1902, there were reports on 13 hemipelvectomies with a mortality rate of 60%.^{1,2} The most common indications for hemipelvectomy are malignant or locally aggressive/ destructive bone and soft tissue tumors of the pelvis and the adjacent muscles, especially osteosarcoma, chondrosarcoma and Ewing's sarcoma. In some rare cases hemipelvectomy is also necessary because of trauma³ or osteomyelitis.⁴ The overall prognosis for patients with malignant bone tumors is poor.^{5,6} Due to the location and extension of these lesions but also to the complex anatomy and the aim to achieve a good functional outcome, these tumors are difficult

to resect. Therefore, pelvic tumors present a great challenge for orthopedic surgeons. Basically, hemipelvectomy is divided into external hemipelvectomy (amputation) and internal hemipelvectomy with preservation of the lower extremity. For many years external hemipelvectomy was the standard method of treatment for locally aggressive and malignant bone tumors in the pelvis. Today, internal hemipelvectomy presents an alternative in the struggle against pelvic tumors.^{7,8} Since an adequate and tumor free resection margin is of great importance for the long-term oncological outcome, hemipelvectomy remains as a curative approach.⁹⁻¹¹ It is evident that not only surgical technique but relevant development on non-orthopaedic fields such as early diagnosis and follow-ups by imaging, new chemotherapy and/or radiation regimes, and innovative implants or bioengineering have lead to significant improvement in the management and success of hemipelvectomy. Modern imaging techniques allow early and accurate preoperative staging.¹² Inoperable neoplasms become operable by neoadjuvant chemotherapy and preoperative irradiation aiming to reduce the tumor mass and increasing the chance to preserve the lower extremity.¹³ With adequate management internal hemipelvectomies do not implement higher recurrence rates compared to amputations by external hemipelvectomy¹⁴ and, in contrast, lead to better functional results in many cases.¹⁵ For reconstruction of the hip and the hemipelvis after tumor resections various techniques have been developed to obtain a functional and cosmetically acceptable outcome, especially to prevent from highshortening of the limb even after a wide resection.¹⁶

First, there is the possibility of solely resecting the bone. In this procedure, fresh frozen allografts¹⁷ or autografts are frequently used for bony reconstruction. Here, also re-implantation of devitalized autogenous bone¹⁸ was reported. There are also options for reconstruction by means of allograft or autograft interposition in combination with a total hip^{15,18,19} or even pelvis prosthesis,²⁰ by transposition of the hip joint or by arthrodesis^{21,22} and hindfoot rotationplasty. Furthermore, there has been an attempt to reconstruct the pelvis with polymethylmethacrylate (PMMA) combined with screws or nails.²³ However, the latter techniques only appropriate for palliative situations or temporary reconstruction. There is no standard procedure and little information is available about the results although many different options exist for reconstruction after internal hemipelvectomy. It is also much debate about which approach is appropriate for each single patient.^{12,24} The decision regarding surgical strategy takes into account the age of the patient,¹⁵ the required extent of resection and the experience of the surgeons.^{12,25} This

Correspondence: Priv.-Doz. Dr. med Christian Wedemeyer, Department of Orthopaedic Surgery, University of Duisburg-Essen, Hufelandstraße 55, 45147 Essen, Germany.
Tel. 49.201.723.3181 - Fax: +49.201.4089.2722.
E-mail: christian.wedemeyer@uni-due.de

Key words: hemipelvectomy, bone tumors, reconstruction, oncological outcome.

Acknowledgement: the authors would like to thank Kaye Schreyer, Dr. Anja Wedemeyer and Dr. Cordula Kauther for editorial assistance with the manuscript.

Conflict of interest: the authors report no conflicts of interest.

Received for publication: 15 February 2011.
Revision received: 3 March 2011.
Accepted for publication: 4 March 2011.

This work is licensed under a Creative Commons Attribution 3.0 License (by-nc 3.0).

©Copyright C. Wedemeyer and M.D.Kauther, 2011
Licensee PAGEPress, Italy
Orthopedic Reviews 2011; 3:e4
doi:10.4081/or.2011.e4

review presents the literature on the outcome after hemipelvectomy in dependency of defined reconstruction techniques during the last thirty years.

Entities

Bone tumors can develop in all types of bone tissue and associated bone marrow cells. A tumor that originates in bone is called primary bone cancer. Primary bone tumors only account for 1% of all solid tumors, and mostly affect patients under 20 years and between 40 - 50 years.²⁶ The tumors most commonly occurring in the pelvis are chondrosarcoma, Ewing sarcoma, plasmocytoma and osteosarcoma. In rare cases, histiocytoma, lymphoma, rhabdomyosarcoma and fibrosarcoma are located in the pelvis.²⁷ Osteosarcomas are considered to be the most common primary malignant bone tumors with 150 cases per year in Germany.²⁸ While this tumor type is mainly located in the metaphysis of long bones, the incidence rate in the pelvis is only 6.4-8% of all osteosarcomas and thus comparatively rare.²⁹ Chondrosarcomas are the second most common malignant bone tumors.³⁰ They are usually located close to the trunk and the pelvic skeleton. This differs from the osteosarcoma, which is found in the pelvis only in exceptional cases.^{30,31} Chondrosarcomas have to be treated primarily by surgical therapy, because chemotherapy and radiation therapy are mostly not effective.⁸ Here, a wide surgical resection margin is crucial for successful treatment. A further 10% of malignant bone tumors are

Ewing sarcomas with an annual incidence of 0.6/million in the population.³⁰ In children and young adults they are the second most common primary bone tumors.³⁰ Recent studies suggested that Ewing sarcomas probably originate from undifferentiated mesenchymal cells of the bone marrow and are mainly located in the metaphysis and diaphysis and in the pelvis. Other authors believed that Ewing sarcomas belong to the primitive neuroectodermal tumors, derived from the neural crest and are characterized by *ews/ets* translocation. However, the exact origin of Ewing sarcoma family is unknown.^{32,33} Seven percent of all bone tumors are primary non-Hodgkin's lymphoma.³⁴ Like the Ewing sarcoma, this rare tumor affects the metaphysis of long bones and the pelvis.³⁴

Indications for hemipelvectomy

Tumors of the pelvis are often recognized at a late stage because they can extend without inducing local symptoms. At the time of diagnosis they often have a high tumor mass and are located close to vessels or nerves. The greatest problem involved in resection is the need for oncological radicalism on the one hand, while aiming to obtain a good functional outcome on the other. Limb-saving surgery should only be conducted if the tumor can be completely removed or if an external hemipelvectomy does not allow more radical oncological results.³⁵ It is essential for the surgeon to have detailed knowledge of the anatomical location of the tumor including the involvement of surrounding anatomical structures in order to plan a specific surgical and individually procedure.¹⁷ To determine the true extent of the tumor, it is therefore essential that comprehensive preoperative radiographic staging including bone x-rays, chest and abdominal computer-tomography (CT), magnetic resonance imaging (MRI) for soft tissue imaging and an angiography are carried out. In addition, bone scans may detect additional skip lesions or unknown metastasis. Regarding the extent of the tumor, the sacroiliac joint, the symphysis, the peritoneum and the bladder are critical areas. Although adequate oncological resections in these areas are surgical demanding, amputation is not always required for curative treatment.³⁶ However, a limb preserving tumor resection must preserve the femoral nerve, artery and vein and the external iliac artery and vein.^{18,35} Extensive infiltration of the psoas muscle and an incautious biopsy can make resection or an internal hemipelvectomy impossible. The decision regarding surgical procedure and choice of adequate reconstruction method should take into account the patient's age, his personal expectations, the demands on the function of the extremity but also the experiences of the surgeon.¹⁷ Since reconstruction after tumor

removal is often quite technical difficult and embare a high complication risk, these operations should not be performed as a purely palliative procedure.³⁷ Indications for palliative radical amputation are the involvement of nerve structures in the pelvis causing uncontrollable pain and failed local control of metastatic disease. However, such cases are rare. Severe trauma³⁸ or osteomyelitis⁴ of the pelvis may also indicate hemipelvectomy in defined cases. Amputation is recommended if the tumor has infiltrated the sciatic nerve and therefore relevant function of the lower extremity is not to be expected.³⁹

Surgical, anatomical and patient related aspects of hemipelvectomy

Detailed descriptions of surgical approaches are found in literature.⁴⁰ Prior to biopsy the surgeon needs to have detailed information of tumor's extent and, in case of malignancy, of the tumor resection to be performed later in order to avoid contamination of tumor-free tissue. Resection should be performed according to the usual standard oncological-surgical methods.^{41,43} There is general consent that the resection margin should be 3-5 cm but not smaller. Tumor resections are classified into four categories:⁴³ i) Intralesional tumor removal: The tumor mass is resected macroscopically with contaminated margins in histological evaluation. For primary malignant tumors this resection must be regarded as unacceptable; ii) marginal resection is a resection in the reactive zone of the tumor. Microscopically reactive tissue or micro-satellites can be detected; iii) an intra-compartmental resection margin is a resection outside the reactive zone in normal tissue. Therefore, it is called wide resection. Skip lesions are occasionally detected; iv) a radical surgical (extra-compartmental resection) procedure is a complete removal of the affected compartments and the resection margin is in healthy tissue.⁴¹ Enneking and Dunham proposed a classification scheme for description of various subtypes of pelvic resections (Figure 1).⁴¹

When reconstructing bone defects, it is always important to ensure sufficient muscular coverage.^{17,18,35,45-47} This coverage lowers the infection risk and is crucial for the success of the reconstruction procedure. Advances in microvascular free flaps, as in local rotational flaps, have extended the indications of limb-sparing surgery and reduced local wound healing problems. Finally, careful hemostasis and drainage should be carried out to avoid poor wound healing.^{45,47} Bednar *et al.* assessed the efficacy of tranexamic acid in decreasing operative blood loss and the need for intraoperative transfusion in metastatic spine surgery but could not show any benefit of this prophylaxis.⁴⁸ It has been observed that limb-saving sur-

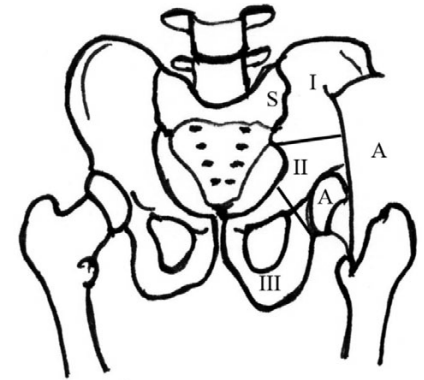


Figure 1. Subtypes of hemipelvic resection methods, Enneking and Dunham 1978, Figure redrawn.⁴⁴ Type I: resection includes only the ilium. Type IA: resection of the ilium and the gluteal muscles. Type I/S: Resection of the ilium with a portion of the sacrum. Type II: Resection of the periacetabular region. Type IIA: Resection of the periacetabular region including the hip joint. Type III: Resection of parts or the complete ischium and pubis.

gery result in a better functional outcome compared with conditions after amputation.⁴⁹ Pring described a good functional result of 77% according to the Musculoskeletal Tumor Society Score (MSTS) after chondrosarcoma resection⁵⁰ and limb-saving surgery. Karaharju⁵¹ emphasized the psychological advantage for the patient after internal hemipelvectomy. Furthermore, phantom pain and extensive intraoperative blood loss are typical complications of amputations.^{52,53} The postoperative course after external hemipelvectomy may be complicated by wound healing disorders, bladder, sexual and bowel dysfunction.

Functional outcome in pelvic reconstructions

Once the decision has been made for limb-saving surgery, the choice of the appropriate pelvic reconstruction needs to be made: if the tumor is in the area of the pubis, the ischium or the peripheral iliac wing without interruption of the pelvic ring, no bony reconstruction is essential.^{54,55} After tumor resection, patients with a stable bony pelvis can expect a much better postoperative function. Even without reconstruction of the acetabulum, a satisfying functional result can be obtained.⁵⁶ After a total internal hemipelvectomy without reconstruction, a *flail hip* (unusually mobile joint) or a floating hip can be the result. It is an alternative to amputation, but it leads to instability and leg shortening^{51,55} and is thus associated with poor function.⁵⁷ This negative effect can be avoided by an appropriate fusion between the femoral head and left pelvic bones.¹⁵

Allografts in pelvic reconstruction

Allografts are usually used to bridge bony defects after resection of parts of the iliac bone with interruption of the pelvic ring (Type I resection), after resection of the acetabulum (Type II resection)⁵⁸ or after resection of the anterior pelvic ring (Type III resection).^{59,60} The appropriate grafts can be calculated by CT scans while allografts provide an excellent tool to reconstruct almost a normal pelvic anatomy.^{46,58} Here the graft can be modified surgically to fulfill into the complex geometry of the corresponding osseous defect.²² Depending on the surgical technique, an intercalary allograft with or without arthrodesis, a composite allograft or an osteochondral allograft reconstruction can be used. The allograft allows bony ingrowth of the recipient bone marrow cells^{46,51} and also reattachment of the muscles is quiet easier compared to metal implants.⁵⁴ However, the disadvantages of this technique are the high risk of bone infections non-unions and allograft fractures.⁶⁰ In a comprehensive study with 945 patients the factors influencing the incorporation of the allograft were investigated. The non-union rate in their patient population amounts to 17.3%.⁶² Aho *et al.* described best functional results using knee osteoarticular allografts and clinical rejection did not occur.⁶³ Some authors emphasize the lack of bone ingrowth of allografts.^{41,46,55,61,62} Furthermore, the reconstruction type has a high impact on the outcome after pelvic reconstruction: non-unions were more frequently seen when an allograft was applied for bone fusion compared to osteoarticular, intercalary, or composite allografts. Moreover, adjuvant chemotherapy treatment increased the rate of non-union.⁶⁴ To prevent infection and non-union, allografts should only be used in areas with adequate soft tissue coverage.⁶⁵ Malignant bone tumors, however, often complicate this condition because the surrounding tissue has to be resected widely in order to maintain the necessary safety distance.⁶³ The overall infection rate of allografts used in general treatment of malignant or aggressive lesions was only 10%.⁴⁶ However, other studies reported higher infection rates (25% and 33%).^{58,66} To reduce the risk for infection, Windhager²⁵ proposed that allografts should be avoided in patients receiving high-dose chemotherapy.

Nevertheless, it cannot be assumed that allografts guarantee a good functional outcome as indicated by some authors.^{58,63} Aho⁶³ rated the overall function as 57% only. O'Connor⁶⁷ achieved good to very good results in successful sacro-iliac arthrodesis. However, non-solid fusion leads to limited and poor results. Puget⁶⁸ described fair results after reconstructing autogenous proximal femurs combined with total hip replacement. If no biological reconstruction can be achieved sockets may be fixed by

cementing with or without an allograft⁶⁹ as indicated by Langlais *et al.*³⁴ In their series, none of the patients suffered a relapse; all were pain-free and mobile without any walking devices six months postoperatively.

The use of autografts

After completion of the pelvic tumor resection reconstruction with autogenous grafts is in order to establish a support between the acetabulum and the sacral bone.²¹ Grafts of iliac crest bone and the vascularized or non-vascularized fibula graft are commonly used to fill defects.⁷⁰ Nagoya⁷¹ reported successful incorporations of vascularized fibulae in four patients after extensive periacetabular resection. These patients were free of pain and none required walking aids. A drawback in the use of autografts is mainly based on the limited availability of the graft.¹⁶ In some centers the tumor bone is excised, freed as far as possible from the tumor, autoclaved for twenty minutes and re-implanted.⁷² In weight bearing transplantation sites this approach is only recommended if the affected bone presents sufficient biomechanical properties.¹⁶

Reconstruction using arthroplasties

Proximal femoral megaprotheses can be used for the reconstruction of critical bone defects after resection of the acetabular region^{18,22,73} as well as after internal partial or total hemipelvectomy. Based on the limited number of patients and the high complication rate after hemipelvectomy, a standard for reconstruction with arthroplasties has not been established yet. Modular designs, custom-made prostheses or conventional prostheses are available.^{74,75} A solid and stable fixation of the endoprosthesis within the remaining bone is a prerequisite for clinical success.¹⁸ The advantages of prostheses are that they are available in a wide range of sizes. In addition, cemented fixation allows immediately stability and early mobilization of the patients. Regardless, megaendoprosthesis are associated with several complications. Material failure rates such as increased wear or fractures are more frequently seen than in primary joint replacement based on osteoarthritis. Also, the reattachment of muscles is difficult leading to high dislocation rates. Especially in cases of limited or poor soft tissue coverage and immunosuppressed patients, there is a high risk of deep infection. In addition, total joint replacement may not appropriate in children before the age of skeletal maturity.²¹ Here growing systems have been applied as an alternative to achieve adequate limb length.

Hemipelvic and saddle prostheses

In severe acetabular bone defects leading to pelvic discontinuity hemipelvic prostheses have been successful applied for reconstruc-

tion. A study by Abudu *et al.* 1997⁷⁶ describes excellent to good results in 65% and satisfactory to poor results in 35% of the patients. The complication rate was 60% (26% infections, 15% dislocations, 6% bleeding, and 3% other). Especially the fixation of these implants is technical demanding. Screw breakages or loosening are frequently seen. Therefore, reconstruction of the pelvic ring by a metallic implant only remains not useful. In contrast, a stable fixation within the sacrum and/or ilium is recommended. Furthermore, an artificial pelvis is not appropriate after resection of the gluteal muscles.⁷⁷

The clinical results after implantation of saddle prosthesis are disappointing. Aboulatia *et al.* describe that 70% of their patients required crutches, three patients were immobile and the infection rate was high. Other authors report that saddle prostheses do not allow a sufficient range of motion. The lack in bony integration and anchorage was also described by O'Connor.¹⁵ In contrast, Van der Lei¹⁹ reported on two patients significant benefit after saddle prosthesis was implanted. If sufficient bony integration can be achieved the saddle endoprosthesis allows full weight-bearing minimizing comorbidity associated by immobilization. Moreover, patients can commence rehabilitation or postoperative chemotherapy earlier.^{19,78}

Transposition of the remaining acetabulum

In the past twenty years, the transposition of the remaining acetabulum for hip reconstruction became popular. This method is especially indicated after limited resection of the iliac bone and/or smaller parts of the cranial acetabulum. However, it is necessary that most parts of the acetabulum are still intact. One advantage is the good applicability in growing children. In such cases, the Y-shaped growth plate acts as a biological barrier for intra-osseous tumor growth.^{21,79} Acetabular transposition also allows covering bony defect by muscles including the gluteus maximus in particular, but also parts of the gluteus medius and the gluteus minimus. Furthermore, it is possible to reattach the abdominal and trunk muscles firmly to the rest of the acetabulum or an interposed allograft.²² One disadvantage especially in children and adolescents is a relevant leg length discrepancy⁶⁶ and associated scoliosis.^{50,80}

Pseudarthrosis and arthrodesis after pelvic reconstruction

The treatment of pseudarthrosis caused by surgical resection of relevant pelvic bone and pelvic reconstruction remains challenging. Therefore arthrodesis is an alternative treatment option. In a two-stage procedure, Hamdi⁸¹ fixed the femoral head transient to the rest of the acetabulum and the iliac bone

and described good functional and oncological results. In a second procedure a neo-acetabulum with sufficient stability is recommended. A similar method was presented by Kusuzaki.⁸² He attached the femoral head to the iliac bone with an external fixator.

Sacro-iliac arthrodeses can be performed to bridge short distances between the sacrum and the remaining part of the ilium after Type I resection.⁸³ If the continuity of the pelvic ring is sufficient, a sacro-iliac arthrodesis using an allograft in between the sacrum and ilium is recommended.^{8,15,41} Arthrodesis of the femoral head with the remaining acetabulum is described as a reconstructive option after complete resection of the iliac bone.^{41,72} If the inferior and medial parts of the acetabulum are still intact to allow fixation of the femoral head, a hip arthrodesis with autogenous fibula or an allograft interposition can be applied. This method provides good stability with no significant leg-length difference.⁵⁵ For reconstruction after resection of Type I and Type II, a pubo-femoral⁴¹ or ischio-femoral arthrodesis has been suggested,² while after resection of Type II and Type III, an ilio-femoral arthrodesis is recommended.^{2,41} This results in complete immobility of the hip joint, which is, however, opposed to a good stability without pain.²² Van der Lei¹⁹ observed leg shortening and an impaired gait pattern in his patients after ilio-femoral arthrodesis. In contrast, Enneking⁴¹ showed that there was no significant leg-length discrepancy. O'Connor^{15,83} favors ilio-femoral arthrodesis with direct attachment of the femoral head to the iliac bone. He recommended this technique for young and active patients. A disadvantage of the ilio-femoral and ischio-femoral arthrodesis is the mobility of the symphysis with subsequent instability of the pelvic ring and femur abduction.^{41,55}

Femoral and hindfoot rotationplasty

Winkelmann distinguishes different types of rotationplasty. Pelvic tumors require not only the resection of the pelvic site but also to some extent the proximal femur. One option to achieve fair function is to rotate the remaining femur of 180° and fix it to the ilium. If the femur needs to be completely resected, e.g. in children, the lateral tibial plateau can articulate in the remaining hip socket and gradually re-forms into a replacement femoral head. However, if the ankle joint acts as the new knee, the lower leg is replaced by a prosthesis. In adults, total femur replacement including the knee joint is an alternative to rotationplasty. The advantages of this procedure are excellent function and preserved proprioception. In addition, no further surgery is required. The disadvantage is the psychological burden imposed on the patient by the external appearance and cosmetic issues.⁸⁴ Kong *et al.* presented a new reconstruction method after

external hemipelvectomy using the hindfoot rotationplasty with calcaneo-sacral fixation and described good functional results.⁸⁵

Amputation and hemicorporectomy

Amputation is indicated if the tumor has destroyed biomechanical relevant areas, reconstruction techniques have failed, or in other patient related factors (Table 1).

But the indication for external hemipelvectomy should be strict and considered with care. After external hemipelvectomy the stump can be covered by an anterior or a posterior gluteal flap and sutured with the inguinal ligament.⁸⁷ A pelvic prosthesis basket can be used to enable patients to stand, sit and move after unilateral amputation. But surgeons should be aware using this kind of mutilating surgery because the technique is ambitious and the complication rate is very high. It should be known that this surgery is an extensive procedure. Due to the shorter convalescence time, this method is more likely to be chosen for elderly patients.⁸⁶ Complications of this method often appear later. These include shoulder pain from walking with sticks, scoliosis due to tilting of the pelvis or arthrosis in the hip or knee of the contralateral leg.⁸⁸

Hemicorporectomy involves amputation of the pelvis and the lower extremities by dysarticulation through the lumbar spine. Barnett *et al.* stated that this extensive procedure is well tolerable in paraplegic patients with disseminated pelvic tumors or pelvis osteomyelitis and improves greatly the quality of life of these carefully selected patients.⁸⁹

Oncological results

In addition to the tumor entity and the preoperative stage, three factors play a specific role for the prognosis of pelvic bone tumors: the tumor location, the tumor size and the resection margin.⁵

An important factor for the local recurrence rate is the location of the primary tumor. Some authors found higher recurrence rates for tumors in the periacetabular region and in the pubic bone.^{15,76} Other authors reported recurrence rates of 50% after sacro-iliac resections and 15-24% after acetabular resection.^{43,90} For Ewing sarcoma Hoffmann⁹¹ observed a survival rate of 45% after resection of the infiltrated sacrum, 43% survival rate after resection of the iliac bone and 51% after resection of the acetabulum. In the sacrum or ilium there is apparently a high risk of leaving contaminated R1 or R2 resection margins. If a wide resection cannot be achieved and the tumor is irradiation-sensitive, perioperative radiotherapy should be applied to reduce the tumor volume. Micrometastases at the resection margins may also be eliminated by postoperative irradiation.^{91,92} Furthermore, intraoperative brachytherapy has shown promising results in terms

Table 1. Indications for external hemipelvectomy.

Indications for external hemipelvectomy
Destroyed biomechanics
Failed reconstruction of the pelvis (non-union, prosthetic loosening, prosthetic infection)
Failed neoadjuvant therapy
Severe deep infection
Infiltration of the sciatic nerve and the femoravessels
Local recurrence of the tumor
Improvement of the resection margin
Life saving procedure
Palliative situation

of achieving a good survivorship in limb saving surgery.^{90,93} The second prognostic factor is tumor size. The negative influence of large tumor mass (>200 mL) is documented for Ewing sarcoma and osteosarcoma.^{6,91,94,95} Metastatic sarcomas are known to have a significantly worse prognosis than localized disease.^{91,96} The third important factor for survivorship and functional outcome is the resection margin. In a study by O'Connor *et al.*, the general local recurrence rate of all cases after R0 resection was 17%. This occurs in 47% of patients after marginal resection, but only in 8% after wide resection. Wide resection allows a satisfactory surgical procedure without positive microscopic resection margin.⁸³ Tomeno showed a local recurrence rate after inadequate (combination of marginal and intraleisional resection) resection of 67%, after wide resection the rate was only 4%.⁹⁷ Some authors^{25,78,98} emphasize the technical difficulty to achieve a wide surgical margin (33%, 65%, 22%) in the pelvis. Since the real tumor extent is often underestimated⁹⁸ and intraleisional and marginal tumor removal should be avoided a correct staging including MRI and CT scans, a preoperative planning, as well as intraoperative histology of soft tissue is essential. Besides different vessels, the bladder, the peritoneum and the ilio-sacral joint are critical areas. Especial in tumors next to the symphysis, the real extent of the tumor is underestimated quiet often and technical demanding.⁹⁹

Metastases and recurrence rate of the entities and survival after treatment

Sheth *et al.* described distant metastases rates of between 60% and 75% in Grade 2-3 chondrosarcomas.¹⁰⁰ Overall, the general distant metastases rate ranges from 13.3-28%.^{41,50,57,106} The local recurrence rate after resection of malignant pelvic tumors range approximately from 4-50 % (5, 41, 50, 67, 76, 77, 97, 100, 101, 102, 103, 104, 105, 106, 107 is shown in Table

2. However, the overall survival rate in Ewing's sarcoma patients is still significantly lower (57% in 3.7 years) than in patients with osteo- or chondrosarcoma.^{2,100} The effectiveness of surgical treatment for Ewing's sarcoma of the pelvis is higher compared to chemotherapy and/or radiotherapy. The data on survival in Ewing's sarcoma vary between 39% and 52% in five years, 44% in ten, and 32% in twelve years.^{5,91,108} Uchida⁷⁷ describes a five-year survival rate of only 50% after resection of acetabular tumors; Abudu⁷⁶ reported a postoperative survival rate of 43% within seven years. In the study by Kawai,⁵ 55% of the patients are still alive after 5 years and 87% were in complete remission. Likewise, Uchida reported a five-year survival rate of 50%.⁷⁶ The prognosis depends also on the differentiation stage of a tumor describing the degree of malignancy. With highly malignant bone tumors, it is difficult to achieve both local and also systemic control of the disease. According to general opinion, simple resection of highly malignant bone tumors should only be addressed after careful preoperative staging, interdisciplinary workup and critical assessment of the effectiveness of the procedure. However, simple resection may be considered in aggressively benign and low-malignant bone tumors.¹⁰⁸

Conclusions

The prognosis of primary malignant bone tumors in the pelvis is significantly worse than that in affected limbs.⁹² The primary objective of surgery is to ensure the survival of the patient. Restoration of function and the cosmetic aspect are only of secondary importance. In recent years, significant advances have been made in the fields of preoperative diagnosis, surgical technique and adjuvant treatment in patients with pelvic tumors. Therefore, the therapy should be performed in specialized centers with close cooperation between oncologists, radiation therapists, anesthesiologists, psychologists and specialized surgeons. Four aspects are particularly interesting and should be done in interdepartmental cooperation: first, there is the question of recurrence and the metastases rate. Second, it is of great importance to achieve an adequate reconstruction with the lowest possible complication rate.²⁵ Third, limb-saving surgery should result in an appropriate functional outcome. Fourth, patients adjust best if they are fully informed and participate in the decision process. Clinical studies indicate that external hemipelvectomy usually does not automatically improve the resection margin compared with internal hemipelvectomy. Furthermore internal hemipelvectomy allows reconstruction techniques, which may lead to a satisfactory functional outcome.

Table 2. Local recidivism rate after hemipelvectomy of different entities.

Authors	Year	Entity	Total (%)	Type I ⁴ (%)	Type II (%)	Type II (%)
Eneking <i>et al.</i> ⁴¹	1978	Primary neoplasms of the pelvis	28			
Tomeno ⁹⁷	1987	Malignant tumors of the iliac bone	21	21		
O'Connor <i>et al.</i> ⁶⁷	1989	Malignant pelvic tumors	17	11 (38)	8	20
Guest <i>et al.</i> ¹⁰¹	1990	Bone sarcomas	30			
Dunst <i>et al.</i> ¹⁰²	1991	Ewing sarcomas	50			
Donati <i>et al.</i> ¹⁰³	1993	Malignant pelvic tumors	24		24	
Shin <i>et al.</i> ¹⁰⁴	1994	Bone sarcomas	4			
Abudu <i>et al.</i> ⁷⁶	1997		24		24	
Cannon <i>et al.</i> ¹⁰⁵	1995	Primary bone tumors of the ilium	24	24		
Sheth <i>et al.</i> ¹⁰⁰	1996	Chondrosarcoma	28			
COSS-96 ²⁸	1996	Osteosarcoma	4-10			
Uchida <i>et al.</i> ⁷⁷	1997	Malignant bone tumors	30			30
Kawai <i>et al.</i> ⁵	1998	Osteosarcoma	32			
Bjornsson <i>et al.</i> ¹⁰⁶	1998	Chondrosarcoma	19.7			
Pring <i>et al.</i> ⁵⁰	2001	Chondrosarcoma	19			
Donati <i>et al.</i> ¹⁰⁷	2009	Chondrosarcoma	17-41			

References

1. Apffelstaedt JP, Driscoll DL, Spellmann JE, et al. Complications and Outcome of external hemipelvectomy in the management of pelvic tumors. *Ann Surg Oncol* 1996;3:304-9.
2. Capanna R, Van Horn, Guernelli N, et al. Complications of Pelvis Resections. *Arch Orthop Trauma Surg* 1987;106:71-7.
3. Lasurt S, Combalia-Aleu A. Complete traumatic hemipelvectomy: Report of a case after 19 years of follow-up. *Injury* 2010;41:874-82.
4. Ziran BH, Smith WR, Rao N. Hemipelvic amputations for recalcitrant pelvic osteomyelitis. *Injury* 2008;39:411-8.
5. Kawai A, Huvos AG, Meyers PA, Healey JH. Osteosarcoma of the Pelvis. Oncologic results of 40 Patients. *Clin Orthop* 1998; 348:196-207.
6. Ham SJ, Kroon HM, Koops HS, Hoekstra HJ. Osteosarcoma of the pelvis - oncological results of 40 patients registered by The Netherland Committee on Bone Tumors. *Eur J Surg Oncol* 2000;1:53-60.
7. Asavamongkolkul A, Pimolsanti R, Waikakul S, Kiatseevee P. Periacetabular limb salvage for malignant bone tumours. *J Orthop Surg* 2005;13:2739.
8. Mankin HJ, Hornicek FJ. Internal hemipelvectomy for the management of pelvic sarcomas. *Surg Oncol Clin N Am* 2005;14:381-96.
9. Kane JM 3rd, Kraybill WG. Radical operations for soft tissue sarcomas. *Surg Oncol Clin N Am* 2005;14:633-48.
10. Ozaki T, Hillmann A, Lindner N. Chondrosarcoma of the Pelvis. *Clin Orthop Rel Res* 1997;226-39.
11. Carter SR, Eastwood DM, Grimer RJ, Sneath RS. Hindquarter Amputation for Tumors of the Musculoskeletal System. *J Bone Joint Surg* 1990;72:490-3.
12. Shih LY, Chen TS, Lo WH. Limb Salvage Surgery for Locally Aggressive and Malignant Bone Tumors. *J Surg Oncol* 1993;53:154-60.
13. Bielack S, Kempf-Bielack B, Heise U, et al. Combined Modality Treatment for Osteosarcoma Occuring as a Second Malignant Disease. *J Clin Oncol* 1999;17: 1164-74.
14. Guo W, Li D, Tang X, Ji T. Surgical treatment of pelvic chondrosarcoma involving periacetabulum. *J Surg Oncol* 2010;101: 160-5.
15. O'Connor MI. Malignant Pelvic Tumors: Limb-Sparing Resection and Reconstruction. *Semin Surg Oncol* 1997; 13:49-54.
16. Harrington KD. The Use of Hemipelvic Allografts or Autoclaved Grafts for Reconstruction after Wide Resection of Malignant Tumors of the Pelvis. *J Bone Joint Surg* 1992;74:331-41.
17. Yasko AW, Johnson ME. Surgical management of primary bone sarcomas. *Hematol Oncol Clin North Am* 1995;9:719-31.
18. Gradinger R, Rechl H, Ascherl R, et al. Endoprothetischer Teilersatz des Beckens bei malignen Tumoren. *Orthopäde* 1993;22:167-73.

19. Van der Lei B, Hoekstra HJ, Veth RP, et al. The Use of the Saddle Prosthesis for Reconstruction of the Hip Joint after Tumor Resection of the Pelvis. *J Surg Oncol* 1992;50: 216-19.
20. Mulier M, Jaecques SV, Raaijmakers M, et al. Early periprosthetic bone remodeling around cemented and uncemented custom-made femoral components and their uncemented acetabular cups. *Arch Orthop Trauma Surg* 2011; Epub ahead of print].
21. Ozaki T, Hillmann A, Winkelmann W. Treatment Outcome of Pelvic Sarcomas in Young Children: Orthopaedic and Oncologic Analysis. *J Pediatr Orthop* 1998;18:350-5.
22. Winkelmann W. Knochen- und Weichteiltumoren. In: Bauer R, Kerschbaum K, Poisel S (Hrsg), *Orthopädische Operationslehre: Becken und untere Extremität*, Bd. II/2 New York: Thieme Stuttgart; 1995. p. 251-354.
23. Johnson JTH. Reconstruction of the pelvic ring following tumor resection. *J Bone Joint Surg* 1978;60:259-64.
24. Bell RS, Davis AM, Wunder JS, et al. Allograft Reconstruction of the Acetabulum after Resection of Stage-II B Sarcoma. *J Bone Joint Surg* 1997;74:1663-73.
25. Windhager R, Karner J, Kutschera HP, et al. Limb Salvage in Periacetabular Sarcomas. *Clin Orthop* 1996;265-76.
26. Fornasier VL. Classification of Bone Tumors. In: *Current Concepts of Diagnosis and Treatment of Bone and Soft Tissue Tumors*. Berlin: Springer; 1984. p 23-27.
27. Grading R, Rechl H, Scheyerer M, Hipp E. Nicht-radikale Operationen von malignen Beckentumoren. *Z Orthop* 1989;420-3.
28. Cooperative Osteosarkomstudie COSS-96. Therapieprotokoll der Gesellschaft für pädiatrische Onkologie und Hämatologie, 1.
29. Huvos AG. Osteogenic sarcoma. In: Huvos AG (Hrsg.) *Bone tumors*. Philadelphia, London, Toronto: Sanders; 1991. p. 85-177.
30. Weber U. Knochentumoren. In: Zilal, Weber (Hrsg.), de Gruyter. *Lehrbuch für Orthopädie*, 1988.
31. Huang M, Lucas K. Current therapeutic approaches in metastatic and recurrent Ewing sarcoma. *Sarcoma* 2011;2011: 863210.
32. Hense HW, Ahrens S, Paulussen M, et al. Factors associated with tumor volume and primary metastases in Ewing tumors: results from the (E)CESS studies. *Ann Oncol* 1999;10:1073-7.
33. Lin PP, Wang Y, Lozano G. Mesenchymal Stem Cells and the Origin of Ewing's Sarcoma. *Sarcoma* 2011; Epub 2010 Oct 5.
34. Burri C. Aktuelle Probleme in Chirurgie und Orthopädie. In: *Knochentumoren*, Bd 5 Hans Huber, Bern, Stuttgart, Wien: Verlag; p. 54-55.
35. Mittelmeier W, Rechl H, Peters P, et al. Erfahrungen mit Becken-Tumorendoprothesen. In: *Maligne Knochentumoren. Aktueller Stand der Diagnostik und Therapie*. Berlin: Logos; 1997. p. 131-139.
36. Saab R, Rao BN, Rodriguez-Galindo C, et al. Osteosarcoma of the pelvis in children and young adults: The St. Jude Children's Research Hospital experience. *Cancer* 2005;103:1468-74.
37. Becker W. Knochentumoren, Kapitel 9. In: Witt A.V, Rettig H, Schlegel K.F, Hackenbroich, Hupfauer W. (Hrsg), *Orthopädie in Praxis und Klinik*, 2. Aufl, Bd. VII Spezielle Orthopädie, Teil 1: Hüftgelenk und untere Extremität. Stuttgart, New York: 1987.
38. Heineck J, Seifert J, Rammelt S, et al. Traumatic hemipelvectomy. *Unfallchirurg* 2006;109:411-6.
39. Huth JF, Jeffrey J, Pignatti G, Eilber FR. Resection of Malignant Tumors of the Pelvic Girdle Without Extremity Amputation. *Arch Surg* 1988;123:1121-4.
40. Carnesale PG. Amputations of the Hip and the Pelvis. In: Canale T, editor. *Campbell's Operative Orthopedics* Amsterdam: Elsevier; 2006. p. 587-95.
41. Enneking WF, Dunham WK. Resection and Reconstruction for Primary Neoplasms Involving the Innominate Bone. *J Bone Joint Surg* 1978;60:731-46.
42. Enneking WF. A System for the Functional Evaluation of Reconstructive Procedures after Surgical Treatment of Tumors of the Muskuloskeletal System. *Clin Orthop Rel Res* 1993;241-6.
43. Enneking WF. Staging of Muskuloskeletal Neoplasms. In: *Current Concepts of Diagnosis and Treatment of Bone and Soft Tissue Tumors*. Berlin: Springer; 1984. p. 1-21.
44. Hugate R Jr, Sim FH. Pelvic reconstruction techniques. *Orthop Clin North Am* 2006;37:85-97.
45. Gordley K, Marco R, Klebuc M. Supercharged internal hemipelvectomy that enhances flap perfusion and decreases wound-healing complications. *Orthopedics* 2008;31.
46. Dick HM, Strauch RJ. Infection of Massive Bone Allografts. *Clin Orthop Rel Res* 1994;46-53.
47. Wuisman P, Sugihara S. Allograft-Rekonstruktion nach Resektion muskuloskeletaler Tumoren. In: *Maligne Knochentumoren, Aktueller Stand der Diagnostik & Therapie*, Berlin: Logos Verlag; 1997. p. 93-100.
48. Bednar DA, Bednar VA, Chaudhary A, Farrokhhyar F. Tranexamic acid for hemostasis in the surgical treatment of metastatic tumors of the spine. *Spine* 2006;31:954-7.
49. Apffelstaedt JP, Driscoll LD, Karakousis CP. Partial and complete internal hemipelvectomy: Complications and long-term follow-up. *J Am Coll Surg* 1995; 181:43-8.
50. Pring ME, Weber KL, Unni KK, Sim FH. Chondrosarcoma of the pelvis. A review of sixty-four cases. *J Bone Joint Surg Am* 2001;83:1630-42.
51. Karaharju EO, Korkala O. Resection of large tumors of the anterior pelvic ring while preserving functional stability of the hip. *Clin Orthop and Rel Res* 1985; 270-4.
52. Masterson EL, Davic AM, Wunder JS, Bell RS. Hindquarter amputation for pelvis tumors. The importance of patient selection. *Clin Orthop* 1998;187-94.
53. Zeifang F, Buchner M, Zahlten-Hinguranage A, et al. Complications following operative treatment of primary malignant bone tumours in the pelvis. *Eur J Surg Oncol* 2004;30:893-9.
54. Langlais F, Vielpeau C. Allografts of the hemipelvis after tumor resection. Technical aspects of four cases. *J Bone Joint Surg* 1989;71:58-62.
55. Campanacci M, Capanna R. Pelvic Resections: The Rizzoli Institute Experience. *Orthop Clin North* 1991;22: 65-86.
56. Stephenson RB, Kaufer H, Hankin FM. Partial Pelvic Resection as an alternative to hindquarter amputation for skeletal neoplasms. *Clin Orthop* 1989;201-11.
57. Sim FH, Bowman WE. Limb Salvage in Pelvic Tumors. *Current Concepts of Diagnosis and Treatment of Bone and Soft Tissue Tumors*. Berlin, Heidelberg: Springer; 1984. p. 367-72.
58. Yoshida Y, Osaka S, Tokuhashi Y. Analysis of limb function after various reconstruction methods according to tumor location following resection of pediatric malignant bone tumors. *World J Surg Oncol* 2010; 19:39.
59. Mutschler W, Burri C. Die chirurgische Therapie von Beckentumoren. *Der Chirurg* 1987;58:724-31.
60. Winkler K, Bieling P, Bielack S. Die Chemotherapie des Osteosarkoms. *Z Orthop* 1992;285-9.
61. Mankin HJ, Gebhart MC, Jennings LC, et al. Long-Term Results of Allograft Replacement in the Management of Bone Tumors. *Clin Orthop Rel Res* 1996;86-97.
62. Hornicek FJ, Gebhart MC, Tomford WW,

- et al. Factors Affecting Nonunion of the Allograft-Host Junction. *Clin Orthop Rel Res* 2001;87-98.
63. Aho AJ, Ekfors T, Dean PB, et al. Incorporation and Clinical Results of large Allografts of the Extremities and Pelvis. *Clin Orthop Rel Res* 1994;200-13.
 64. Donati D, Giacomini S, Gozzi E, et al. Osteosarcoma of the pelvis. *Eur J Surg Oncol* 2004;30:332-40.
 65. Alma BA, De Bari A, Krajbich JI. Massive allografts in the treatment of osteosarcoma and Ewing sarcoma in children and adolescents. *J Bone Joint Surg Am* 1995; 77:54-64.
 66. Hillmann A, Hoffmann C, Gosheger G, et al. Tumors of the pelvis: complications after reconstruction. *Arch Orthop Trauma Surg* 2003;123:340-4.
 67. O'Connor MI, Sim FH. Salvage of the Limb in the Treatment of Malignant Pelvic Tumors. *J Bone Joint Surg* 1989; 71:481-94.
 68. Puget J, Utzeza G. Reconstruction de l'os iliaque a l'aide du fémur homolatéral après résection pour tumeur pelvienne. *Revue de Chirurgie Orthopédique* 1986;72:151-5.
 69. Bramer JA, Taminiou AH. Reconstruction of the pelvic ring with an autograft after hindquarter amputation: improvement of sitting stability and prosthesis support. *Acta Orthop* 2005;76:453-4.
 70. Chang DW, Fortin AJ, Oates SD, Lewis VO. Reconstruction of the pelvic ring with vascularized double-strut fibular flap following internal hemipelvectomy. *Plast Reconstr Surg* 2008;121:1993-2000.
 71. Nagoya S, Usui M, Wada T, Yamashita T, Ishii S. Reconstruction and limb salvage using a free vascularised fibular graft for periacetabular malignant bone tumours. *J Bone Joint Surg Br* 2000;82:1121-4.
 72. Enneking WF. *Surgical Technique. In: Muskuloskeletal Tumor Surgery. Vol I.* New York, London, Edinburgh, Melbourne: Churchill Livingstone; 1983.
 73. Schwartz AJ, Kiatisevi P, Eilber FC, et al. The Friedman-Eilber resection arthroplasty of the pelvis. *Clin Orthop Relat Res* 2009;467:2825-30.
 74. Aljassir F, Beadel GP, Turcotte RE, et al. Outcome after pelvic sarcoma resection reconstructed with saddle prosthesis. *Clin Orthop Relat Res* 2005;438:36-41.
 75. Müller PE, Dürr HR, Wegener B, et al. Internal hemipelvectomy and reconstruction with a megaprosthesis. *Int Orthop* 2002;26:76-9.
 76. Abudu A, Grimer RJ, Cannon SR, et al. Reconstruction of the hemipelvis after the excision of malignant tumors. Complications and functional outcome of prostheses. *J Bone Joint Surg* 1997;79:773-9.
 77. Uchida A, Myoui A, Araki N, et al. Prosthetic Reconstruction for Periacetabular Malignant Tumors. *Clin Orthop* 1996;326:238-45.
 78. Gradinger R, Rechl H, Hipp E. Pelvic Osteosarcoma. Resection, Reconstruction, Local Control, and Survival Statistics. *Clin Orthop* 1991;149-58.
 79. Winkelmann W. Eine neue Operationsmethode bei malignen Tumoren des Darmbeins. *Z Orthop* 1988;126:671-4.
 80. Catagani MA, Ottaviani G. Ilizarov method to correct limb length discrepancy after limb-sparing hemipelvectomy. *J Pediatr Orthop B* 2008;17:293-8.
 81. Hamdi M, Gebhart M, Recloux P. Internal Hemipelvectomy. *Europ J Surg Oncol* 1996;158-61.
 82. Kusuzaki K, Shinjo H, Kim W, et al. Resection hip arthroplasty for malignant pelvic tumor. *Acta Orthop Scand* 1998; 69:617-21.
 83. O'Connor MI, Sim FH. Resection of pelvic sarcomas. Reconstruction techniques without use of endoprotheses. *Orthopäde* 1993;22:174-8.
 84. Donati D, Benedetti MG, Catani F, et al. [Gait analysis after rotationplasty hip surgery for malignant tumor of the proximal femur]. *Rev ChirOrthop Reparatrice Appar Mot* 2004;90:561-8.
 85. Kong GY, Rudiger HA, Ek ET, et al. Reconstruction after external hemipelvectomy using tibia-hindfoot rotationplasty with calcaneo-sacral fixation. *Int Semin Surg Oncol* 2008;21:1.
 86. Senchenkov A, Moran SL, Petty PM, et al. Predictors of complications and outcomes of external hemipelvectomy wounds: account of 160 consecutive cases. *Ann Surg Oncol* 2008;15:355-63.
 87. Bhattacharya S, Biswas S. Post hemipelvectomy incisional hernia. *Hernia* 2009;13:435-7.
 88. Tunn PU, Fehlberg S, Andreou D, Kettelhack C. Endoprosthesis in the operative treatment of bone tumours of the pelvis. *Z Orthop Unfall* 2007;145:753-9.
 89. Barnett CC, Ahmad J, Janis JE, et al. Hemicorporectomy: back to front. *Am J Surg* 2008; 196:1000-2.
 90. Hoekstra HJ, Sindelar WF, Kinsella TJ. Surgery with intraoperative radiotherapy for sarcomas of the pelvic girdle: a pilot experience. *Int J Radiat Oncol Biol Phys* 1988;15:1013-6.
 91. Hoffmann C, Ahrens S, Dunst J, Hillmann A, Winkelmann W, Craft A, Göbel U, Rube C, Voute PA, Harms D, Jürgens H. Pelvic Ewing Sarcoma. A Retrospective Analysis of 241 Cases. *Am Cancer Society* 1999; 869-77.
 92. Fuchs B, Hoekzema N, Larson DR, et al. Osteosarcoma of the pelvis: outcome analysis of surgical treatment. *Clin Orthop Relat Res* 2009;467:510-8.
 93. Hillmann A, Ozaki T, Rube Ch, Rödl R, Hein M, Hoffmann Ch, Blasius S, Jürgens H, Winkelmann W. The impact of intraoperative brachytherapy on surgery of Ewing's sarcoma. *J Cancer Res Clin Oncol* 1997;123:53-6.
 94. Paulussen M, Ahrens S, Dunst J, et al. Localized Ewing tumor of bone: final results of the cooperative Ewing's Sarcoma Study CESS 86. *J Clin Oncol* 2001;19:1818-29.
 95. Ahrens S, Hoffmann C, Jabar S, et al. Evaluation of prognostic factors in a tumor volume-adapted treatment strategy for localized Ewing sarcoma of bone: the CESS 86 experience. *Cooperative Ewing Sarcoma Study. Med Pediatr Oncol* 1999;32:186-95.
 96. Fiorenza F, Abudu A, Grimer RJ, et al. Risk factors for survival and local control in chondrosarcoma of bone. *J Bone Joint Surg Br* 2002;84:93-9.
 97. Tomeno B. Les résection dans le tumeurs du bassin: VIII- Procédés de reconstruction après résection totale ou partielle d'un hémibassin dans le traitement des tumeurs malignes de l'os iliaque. *SO.F.C.O.T. 61 e Réunion Annuelle.* 1987; p. 95-98.
 98. Fahey M, Spanier SS, Vander Griend RA. Osteosarcoma of the Pelvis. *J Bone Joint Surg* 1992;74:321-30.
 99. Gavrankapetanovic I, Gavrankapetanovic F, Becirbegovic S, et al. Hemipelvectomy, constant surgical dilemma. *Rozhl Chir* 2007;86:661-5.
 100. Sheth DS, Yasko AW, Johnson M, et al. Chondrosarcoma of the pelvis. Prognostic factors for 67 patients treated with definitive surgery. *Cancer* 1996;778:745-50.
 101. Guest CB, Bell RS, Davis A, et al. Allograft Implant composite reconstruction following periacetabular sarcoma resection. *J Arthroplasty* 1990;5:25-34.
 102. Dunst J, Sauer R, Burgers JM, et al. Radiation therapy as local treatment in Ewing's sarcoma. Results of the Cooperative Ewing's Sarcoma Studies CESS 81 and CESS 86. *Cancer* 1991;67:2818-25.
 103. Donati DCR, Caldora P, Martini A, et al. Internal hemipelvectomy of the acetabulum area using different methods of reconstruction. *Proceedings of the 7th Symposium on Limb Salvage, 1993, Singapore.*
 104. Shin KH, Rougraff BT, Simon MA. Oncologic outcomes of primary bone sarcomas of the pelvis. *Clin Orthop* 1994; 304:207-17.

105. Cannon TR Sr, Grimer RJ, Carter SR, Sneath RS. Treatment of primary bone tumors of the ilium by local resection and fibular strut graft. Proceedings of 8th International Symposium on Limb Salvage, 1995, Florence, p. 77.
106. Bjornsson J, McLeod RA, Unni KK, et al. Primary chondrosarcoma of long bones limb girdles. *Cancer* 1998;83:2105-19.
107. Donati D, El Ghoneimy A, Bertoni Fet al. Surgical treatment and outcome of conventional pelvic chondrosarcoma. *J Bone Joint Surg Br* 2005;87:1527-30.
108. Unni KK, Dahlin DC, Beabout JW, Sim FH. Chondrosarcoma: clear-ell variant. A report of sixteen cases. *J Bone Joint Surg* 1976;58:676-83.