

This is an Open Access article licensed under the terms of the Creative Commons Attribution-NonCommercial-NoDerivs 3.0 License (www.karger.com/OA-license), applicable to the online version of the article only. Distribution for non-commercial purposes only.

Primary Yolk Sac Tumor of the Omentum: A Case Report and Literature Review

Kenichi Harano^a Masashi Ando^c Yuko Sasajima^b
Mayu Yunokawa^a Kan Yonemori^a Chikako Shimizu^a
Kenji Tamura^a Noriyuki Katsumata^a Hitoshi Tsuda^b
Yasuhiro Fujiwara^a

^aBreast and Medical Oncology Division and ^bPathology and Clinical Laboratory Division, National Cancer Center Hospital, Tokyo, and ^cDepartment of Clinical Oncology, Aichi Cancer Center Hospital, Nagoya, Japan

Key Words

Germ cell tumor · Yolk sac tumor · Omentum · Immunohistochemistry

Abstract

Yolk sac tumor (YST) is a rare malignant tumor originating from germ cells. YST normally originates from the gonads, rarely occurring in extragonadal sites. We report a 35-year-old man with YST arising in the omentum, which is the first reported case of a primary YST of the omentum in an adult male. The patient presented to the community hospital with abdominal distension. A CT scan showed thickening of the omentum with ascites. The patient underwent open biopsy of the omental mass. The Pathology Department of the hospital could not make a definitive diagnosis at that time, and the tumor was considered a cancer of unknown primary (CUP) origin with features of primary colorectal cancer based on the immunohistochemistry (IHC) findings of the biopsy specimen (CK7–/CK20+ and CDX-2+). He was then referred to our hospital. We found that serum α -fetoprotein was abnormally elevated to 7,144 ng/ml (normal <10.0), and reevaluation of the biopsy specimen revealed microcystic or reticular patterns of tumor cells with Schiller-Duval bodies typical of YST. The present case suggests that IHC is a very useful diagnostic tool for subtyping CUP but should be interpreted in the context of clinical and morphological findings.

Introduction

Yolk sac tumor (YST) is a rare malignant germ cell tumor (GCT) which usually arises in the gonads, such as the testis or ovary. YST stimulates the yolk sac and produces α -

fetoprotein (AFP). Whereas most YST occur in the gonads, about 10–20% of the cases arise in extragonadal sites, including the mediastinum, sacrococcygeal region, retroperitoneum, cervix, vulva, pelvis, lung, head and neck, and stomach [1–5].

We report a case of primary YST of the omentum, which is an extremely rare location for this tumor, in a 35-year-old male, and discuss the clinical, morphological, and immunohistochemical (IHC) features.

Case Report

A 35-year-old man presented to the community hospital with progressive abdominal distension. The patient had been well until 1 month before, when abdominal distension and anorexia developed. A CT scan showed thickening of the omentum with ascites (fig. 1). Upper and lower endoscopies revealed no abnormal lesions in the digestive tract. The patient underwent open biopsy of the omental mass. Histological evaluation of the specimen revealed tumor cells with vacuolated cytoplasm forming a sheeted, honeycomb-like structure. IHC staining of the tumor showed the following profile: AE1+/AE3+, cytokeratin (CK)7–, CK20+, epithelial membrane antigen (EMA)+, vimentin+, S-100–, desmin–, α -smooth muscle actin (α -SMA)–, prostate-specific antigen (PSA)–, TTF-1–, carcinoembryonic antigen (CEA)–, AFP+, and CDX-2+. The Pathology Department of the hospital could not make a definitive diagnosis at that time, but the IHC findings of the biopsy specimen (CK7–/CK20+ and CDX-2+) suggested that the tumor was of colorectal origin. The tumor was therefore considered a cancer of unknown primary (CUP) origin with features of primary colorectal cancer. The patient received 2 courses of mFOLFOX6. He was then referred to the Breast and Medical Oncology Division, National Cancer Center Hospital, for further assessment and treatment.

A CT scan revealed that the tumor was slightly smaller than it had been before treatment. Tumor marker screening for CUP was carried out and the results were evaluated. Serum AFP was abnormally elevated to 7,144 ng/ml (normal <10.0). No elevations were observed in CEA, CA 19-9, β -human chorionic gonadotropin (β -HCG), or protein induced by vitamin K absence or antagonist-II. Reevaluation of the biopsy specimen revealed microcystic or reticular patterns of tumor cells with Schiller-Duval bodies typical of YST (fig. 2). IHC showed the following profile: AE1+/AE3+, CK7–, CK20+, EMA+, vimentin+, S-100–, desmin–, α -SMA–, PSA–, TTF-1–, CEA–, CA125+, AFP+, β -HCG–, PLAP–, glypican-3+, and CDX-2+. A CT scan and ultrasonography confirmed that there were no masses in the mediastinum, retroperitoneum, or testes. The final diagnosis of the patient's disease was primary YST of the omentum. The patient underwent chemotherapy with bleomycin (30 mg on days 1, 8, and 15), etoposide (75 mg/m² on days 1–5), and cisplatin (20 mg/m² on days 1–5) (BEP chemotherapy) every 3 weeks for 4 cycles. After completion of the fourth cycle, his AFP level had decreased to 11.2 ng/ml, and he underwent surgery. Several whitish nodules were observed in the omentum, retroperitoneum, and mesentery of the small bowel. A frozen biopsy from a retroperitoneal nodule showed fibrous tissue with granulation. An omentectomy was subsequently performed, and nodules larger than 5 mm were removed. Pathological evaluation of the surgical specimens revealed that most of the nodules were necrotic, and only a small number of viable cells were detected in the omentum. A follow-up CT scan obtained 6 months after surgery did not show any indications of recurrence. The AFP levels were also within the normal range.

Discussion

YST is a rare malignant tumor originating from germ cells. YST normally originates from the gonads, rarely occurring in extragonadal sites [1]. Its distribution varies widely and includes the mediastinum, sacrococcygeal region, retroperitoneum, cervix, vulva, pelvis, lung, head and neck, and stomach [1–5]. The histogenesis of extragonadal YST remains controversial. Two main theories have been proposed to explain extragonadal GCT [6]. According to the first theory, the tumor originates from the aberrant differentiation of somatic cells. This might explain the cases of YST occurring

in the stomach or lung. The second theory proposes that the tumor originates from germ cells that have been misplaced or arrested in their embryonic migration. During embryogenesis, the primitive gonadal ridge extends from the cranial cavity to the external genitals. A remnant of germ cells may exist along the pathway of migration, and malignant transformation of these misplaced cells may become primary GCT at these sites. According to this theory, the misplacement of germ cells during migration through the bowel wall and omentum would explain the location of the YST in the present case. To our knowledge, this is only the fifth case of primary YST of the omentum reported in the literature, and the first one in an adult male [6–9].

In the present case, the patient's disease had initially been considered a 'CUP of the omentum with features of a colorectal primary cancer'. We found that AFP was abnormally elevated by serum tumor marker screening tests for CUP, and this finding led us to suspect the possibility of another primary tumor. Finally, we were able to reach the definitive diagnosis of YST. The IHC staining patterns seen in this case, such as CK7–, CK20+, and CDX-2+, made diagnosis very tricky. Cytokeratins are widely used to determine tumor origins, and CK7 and CK20 are used to subtype carcinomas [10]. CK7 is widely expressed in simple glandular epithelium such as in the breast, pancreas, biliary tract, lung, and transitional epithelium. CK20 is expressed in the gastrointestinal epithelium, especially the colon, transitional epithelium, and Merkel neuroendocrine cells of the skin. The expression of CK7–/CK20+ is typically interpreted as carcinoma of the colorectum, stomach, ovarian mucinous tumor, or Merkel cell-type neuroendocrine tumor. More than 90% of colorectal adenocarcinomas exhibit the CK7–/CK20+ phenotype [10]. CDX-2 is a mammalian homeobox protein that plays a role in the development of the small and large intestine and in the differentiation of intestinal epithelial cells [11]. CDX-2 is useful in establishing the gastrointestinal origin of metastatic tumors and is a helpful addition to the standard IHC panel for CUP. The expression of CDX-2 is, however, not exclusive to intestinal carcinomas. CDX-2 is also expressed in mucinous ovarian adenocarcinomas and adenocarcinomas from the urinary bladder, stomach, esophagus, pancreas, and biliary tree [12]. There are only a few reports of CDX-2 expression in YST; the reason for CDX-2 expression in YST remains to be determined [13]. The present case teaches us that IHC is a very useful diagnostic tool for subtyping CUP; however, it should be interpreted in the context of clinical and morphological findings.

The mainstay of treatment for advanced GCT is chemotherapy. The International Germ Cell Cancer Collaborative Group (IGCCCG) classification is widely used to assess the risk of disease and the management of previously untreated patients in order to choose the appropriate chemotherapy [14]. This system classifies patients as being at good, intermediate, or high risk based on the primary site, pretreatment tumor marker levels (AFP and β -HCG), serum LDH level, and the extent of the disease. In the present case, our patient was considered to be at intermediate risk. Four cycles of BEP chemotherapy and surgical resection of residual disease after chemotherapy is the standard treatment given to patients with intermediate-risk GCT [15].

In conclusion, we report the case of a 35-year-old man with an extremely rare primary YST of the omentum; he was treated successfully with BEP chemotherapy and subsequent surgery.

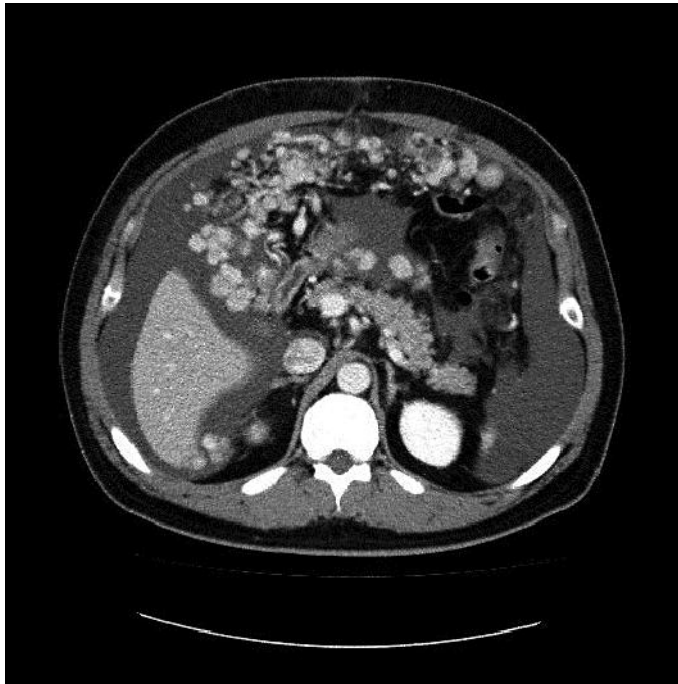

Fig. 1. A CT scan of the abdomen shows multiple nodules in the omentum, with a large amount of ascites.

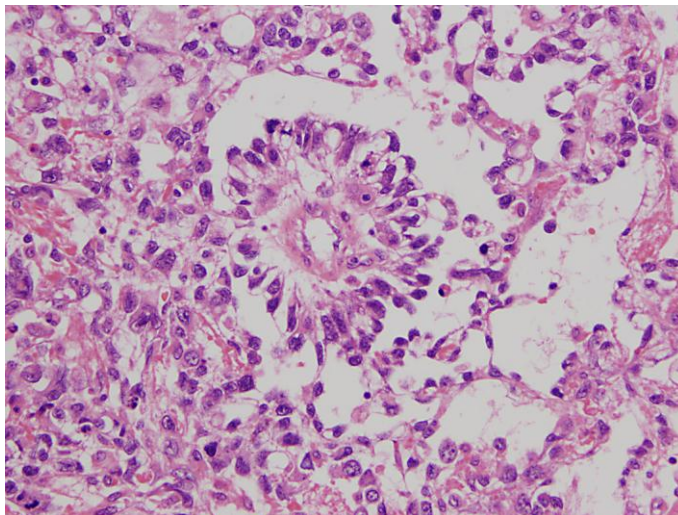


Fig. 2. Microscopic examination shows a Schiller-Duval body, which is characterized by the presence of a central vessel, surrounded by epithelial tumor cells and fibrous tissue.

References

- 1 McKenney JK, Heerema-McKenney A, Rouse RV: Extragonadal germ cell tumors: a review with emphasis on pathologic features, clinical prognostic variables, and differential diagnostic considerations. *Adv Anat Pathol* 2007;14:69–92.
- 2 Monig SP, Schmidt R, Krug B: Yolk sac tumor of the anterior mediastinum: the role of palliative surgery. *Am Surg* 1997;63:948–950.
- 3 Pelosi G, Petrella F, Sandri MT, et al: A primary pure yolk sac tumor of the lung exhibiting CDX-2 immunoreactivity and increased serum levels of alkaline phosphatase intestinal isoenzyme. *Int J Surg Pathol* 2006;14:247–251.
- 4 Filho BC, McHugh JB, Carrau RL, Kassam AB: Yolk sac tumor in the nasal cavity. *Am J Otolaryngol* 2008;29:250–254.
- 5 Singh M, Arya M, Anand S, Sandar N: Gastric adenocarcinoma with features of endodermal sinus tumor. *World J Gastroenterol* 2007;13:4781–4783.
- 6 Kim SW, Park JH, Lim MC, et al: Primary yolk sac tumor of the omentum: a case report and review of the literature. *Arch Gynecol Obstet* 2009;279:189–192.
- 7 Geminiani ML, Panetta A, Pajetta V, Bacci F, Negri L, Maccaferri R, Virzi S, Ventrucci M: Endodermal sinus tumor of the omentum: case report. *Tumori* 2005;91:563–566.
- 8 Xinghui Y, Jing H, Mingju L, Weizhong G: Endodermal sinus tumour of the omentum in a child. *Pediatr Radiol* 2004;34:985–987.
- 9 Park NH, Ryu SY, Park IA, et al: Primary endodermal sinus tumor of the omentum. *Gynecol Oncol* 1999;72:427–430.
- 10 Oien KA: Pathologic evaluation of unknown primary cancer. *Semin Oncol* 2009;36:8–37.
- 11 Li MK, Folpe AL: CDX-2, a new marker for adenocarcinoma of gastrointestinal origin. *Adv Anat Pathol* 2004;11:101–105.
- 12 Werling RW, Yaziji H, Bacchi CE, Gown AM: CDX2, a highly sensitive and specific marker of adenocarcinomas of intestinal origin: an immunohistochemical survey of 476 primary and metastatic carcinomas. *Am J Surg Pathol* 2003;27:303–310.
- 13 Moskaluk CA, Zhang H, Powell SM, et al: Cdx2 protein expression in normal and malignant human tissues: an immunohistochemical survey using tissue microarrays. *Mod Pathol* 2003;16:913–919.
- 14 International Germ Cell Consensus Classification: a prognostic factor-based staging system for metastatic germ cell cancers. International Germ Cell Cancer Collaborative Group. *J Clin Oncol* 1997;15:594–603.
- 15 Kondagunta GV, Motzer RJ: Chemotherapy for advanced germ cell tumors. *J Clin Oncol* 2006;24:5493–5502.