

Correction of lower limb deformities in children with renal osteodystrophy by guided growth technique

C. Gigante¹
A. Borgo¹
M. Corradin²

Abstract

Purpose Renal osteodystrophy (ROD) may cause severe lower limb deformities in children. The purpose of this study is to evaluate the efficacy of the temporary hemiepiphysiodesis for the correction of lower limb deformities in children with ROD.

Methods Guided growth correction by hemiepiphysiodesis has been performed in skeletally immature patients with deformities of the lower limbs caused by ROD. The correction of the mechanical axes of the lower limbs and its correction speed have been evaluated.

Results A total of seven patients with ROD, five males and two females, were treated with the above technique. The average age of the patients at their first surgery was 7.8 years (2.9 to 13.6). The average follow-up time 5.2 years (2.3 to 8). There were 13 valgus deformities and one varus deformity of the knee. The measure of the lower limb angular deformity was in the range of 10° to 47°. Restoration of normal mechanical axis was achieved in all patients at the final follow-up. Three patients relapsed and required further hemiepiphysiodesis. The average time for correction was 20 months (7 to 30). The average speed of correction was 0.49° per month for a tibia and 1.73° per month for a femur. There were two minor complications: a screw mobilisation and a screw breakage occurred during removal.

Conclusion Guided growth technique by hemiepiphysiodesis is a mini-invasive surgical procedure that has been found to be effective for the correction of misalignment due to ROD in skeletally immature patients. The method has allowed progressive correction of the deformities at any age in childhood. These patients are predisposed to relapse to their deformities, thus a strict follow-up is required.

Cite this article: Gigante C, Borgo A, Corradin M. Correction of lower limb deformities in children with renal osteodystrophy by guided growth technique. *J Child Orthop* 2017;11:79-84. DOI 10.1302/1863-2548.11.160172

Keywords: renal osteodystrophy; windswept deformity; chronic kidney disease; limb deformity; hemiepiphysiodesis

Introduction

Congenital and acquired chronic kidney diseases may lead to a disorder regulation of mineral metabolism with subsequent alteration of bone remodelling and growth. The term renal osteodystrophy (ROD) refers to a large spectrum of abnormalities of skeletal homeostasis related to chronic renal failure. These include: growth disturbances, angular deformities, avascular necrosis, slipped epiphysis, scoliosis, osteochondritis dissecans and brown tumours.¹⁻⁶ Current treatment paradigms advocate the use of 1,25(OH)₂ vitamin D and its derivatives to control the secondary hyperparathyroidism. Nevertheless, these agents are not enough to correct defective skeletal mineralisation; hence, these patients may develop limb deformities that require surgical correction. Despite medical treatment and functioning renal graft, this pathology persists and affects bone metabolism, particularly during the growing age.⁷⁻¹⁰ Bar-On et al has found that 7/146 children (4.8%) with end-stage renal failure were referred to an orthopaedic unit due to deformity of the lower limb.¹ This deformity may occur either in the femur, tibia or in both, and it is more frequent in valgus; however, varus deformities may also occasionally occur.¹¹⁻¹³ Valgus deformities exceeding an angle of 10° may be the cause of anterior knee pain, circumduction gait and, occasionally, patellofemoral instability. Varus deformities may result in lateral thrust, ligamentous laxity and a waddling gait.¹⁴ Most of the studies regarding the corrective osteotomies performed at the end of growth in order to avoid relapse are generally directed to the severe deformities.¹⁵ There have been many studies looking at patients treated with guided growth technique by temporary hemiepiphysiodesis for the correction of ROD deformities in childhood.^{14,16-18} Nevertheless, these studies combine the results of corrections between idiopathic and pathological physis cases and, moreover, they involve a different method of correction. The main feature of this technique consists of a temporary and reversible interruption of skeletal growth on the side of the physis and allows growth on the opposed side.

¹ Paediatric Orthopaedic Unit, Padua General Hospital, Italy

² Orthopaedic and Trauma Clinic, University Hospital of Padua, Italy

This technique allows a progressive correction of the angular deformity and is also minimally invasive. In fact, only a shallow surgical incision of few centimetres is required, which allows the patient to be immediately mobilised and the surgery is minimal compared with an osteotomy.¹⁴

The aim of this study is to evaluate the efficacy of a guided growth technique by hemiepiphyodesis in skeletally immature patients with ROD for the treatment of angular deformities of the lower limbs.

Patients and Methods

We have retrospectively evaluated all skeletally immature patients with ROD and treated them for lower limb deformities in our institution between 2006 and 2012. Only those patients with a valgus or varus deformity of the lower limbs above 2 standard deviations (SD) were considered eligible for surgery. The following data were collected for each patient: age at first surgery; gender; renal disease; and anatomical site of the hemiepiphyodesis. For each surgical procedure, the speed of correction was calculated by taking the ratio between the angular deformity correction and time, in months, needed for correction. Coefficient of correction was calculated as the ratio between the time required for correction in patients with ROD and the time predicted by The Multiplier (Version 5.1, copyright 2015, Rubin Institute for Advanced Orthopedics, Sinai Hospital of Baltimore).¹⁹

All the patients' parents were informed and gave oral and written consent for this specific treatment. All the procedures complied with the ethical standards of the responsible committee and with the Declaration of Helsinki 1975, as revised in 2000. The hemiepiphyodesis was performed using the titanium Eight-Plate (Orthofix Srl, Verona, Italy) and amagnetic steel Peditplate (OrthoPediatrics, Warsaw, Indiana, USA). All surgeries were performed with local and regional anaesthesia and sedation. The post-operative protocol included 24 hours of antibiotic therapy with cefazolin with different dosages based on both the patients' weight and renal function. Weight-bearing was allowed the day after surgery with the aid of crutches.

Results

Of the 120 children affected by chronic or congenital renal diseases treated at the Pediatric Nephrology Service in our Hospital between 2006 and 2012, a total of seven patients (5.8%), five males and two females, underwent surgical correction of their lower limb deformities by guided growth technique. As per our institutional criteria, the other 113 patients did not require surgical correction as the deformity of their lower limbs was below 2 sd. The average age at first surgery was 7.8 years (2.9 to 13.6). Only four patients had congenital renal disease and three patients had an acquired renal disease. One patient was on haemodialysis whereas four patients had functioning kidney grafts and two patients had normalisation of renal function after several years of disease (Table 1). The average follow-up was 5.2 years (2.3 to 8). A valgus knee was present in 13 limbs and one presented with varus deformity. The pre-operative coronal deformity, which is measured as the difference between the femoral and tibial mechanical axis, was in the range of 10° to 47°. Overall, 23 eight-plates were implanted (Table 2). The restoration of the normal mechanical axis was achieved in all patients (with the residual deformities less than 5°) and there were no clinical rotation deformities of the lower limbs. One patient, affected by a very severe valgus of the left knee due to delayed observation, had an additional osteotomy of the tibia along with a guided growth in order to achieve an immediate and partial correction of this serious deformity (Figs 1 to 3). This osteotomy healed in six weeks without complications. Implant and removal of the plates were the two standard procedures applied to four patients for this type of surgery. One patient required several surgical procedures in order to correct relapse and a windswept deformity. At his final follow-up, this patient presented concomitant osteonecrosis of the distal femoral epiphysis that was due to the massive steroid treatment required by his renal transplantation. The average time required to obtain the angular correction was 20 months (7 to 30). The speed correction was evaluated in six patients. However, a patient with windswept deformity was excluded because of the complexity of the simultaneous surgical

Table 1. Patient demographics

Patient	Gender	Renal disease	Age of onset	Renal status at surgery
1	F	Bilateral kidney dysplasia, vescicourethral reflux	Congenital	Chronic kidney disease after first kidney transplant from cadaver (at 3 years of age)
2	M	Congenital anomolysis of kidneys and urinary tract	Congenital	First kidney transplant from cadaver (at 1 year of age)
3	M	Nefrosic syndrome	6 months	Previous haemodialysis. Normal renal function, negativisation of proteinuria after 1 year of age
4	F	Congenital anomolysis of kidney and urinary tract and right kidney agenesis	Congenital	First kidney transplant reject (at 2 years of age); second kidney transplant (at 11 years of age)
5	M	Tubolointerstitial nephritis	8 years	Haemodialysis
6	M	Nefrosic syndrome	1 year	Previous haemodialysis. Normal renal function and proteinuria after 1.5 years of age
7	M	Congenital anomolysis of kidneys and urinary tract	Congenital	First kidney transplant from cadaver (at 1 year of age)

Table 2. Description of patient's surgeries and radiological evaluations

No.	Age at surgery	Site of implant	Pre-operative coronal deformities	Alignment at removal	Time with implant	Control time	Coefficient (ROD/control)	Speed of correction (°/month)	Age at final follow-up	Follow-up alignment degrees
1A	7 yrs 9 mths	(1) Medial distal RF	21° valgus right 4° valgus left	0° right 4° left	17 mths	cRF 16 mths	RF 1.06	RF 1.24		
1B	10 yrs 4 mths	(2) Medial proximal RT (3) Medial distal LF	5° valgus right 12° valgus left	0° right 0° left	11 mths	cLF 9 mths cRT 6 mths	LF 1.22 RT 1.83	RT 0.4 LF 1.09	15 yrs 2 mths	5° valgus right 5° valgus left
2A	8 yrs	Lateral distal LF	33° varus left	0° left	30 mths	cLF 35 mths	LF 0.85	LF 1.1		
2B	13 yrs	(1) Lateral distal LF (2) Medial proximal LT (3) Medial distal RT (4) Lateral proximal RT	16° valgus right 16° varus left	20° valgus right 11° varus left	(1) (3) (4) 4 mths (2) 19 mths					
2C	13 yrs 4 mths	Removal of device in the lateral distal RT and implant in the (5) medial distal RT	20° valgus right 11° varus left	7° valgus right 13° varus left	(5) 11 mths					
2D	14 yrs 7 mths	Removal of device in proximal RT and implant (6) in the lateral LF	4° valgus right 14° varus left	4° valgus right 4° varus left	(6) 7 mths				16 yrs	5° valgus right 5° varus left
3A	2 yrs 11 mths	(1) Medial distal LF (2) Medial distal RF (+) additional osteotomy and sampling of LT	14° valgus right 47° valgus left	9° varus right 8° valgus left	(2) 9 mths	cRF 8 mths	RF 1.12	RF 2.5		
3B	3 yrs 8 mths	Removal of device and implants in (3) medial proximal LT	9° varus right 8° valgus left	5° varus right 0° left	15 mths	cLT 5 mths	LT 3	LT 0.53	8 yrs	2° valgus right 2° valgus left
4	13 yrs 4 mths	Medial proximal LT and RT	11° valgus right 15° valgus left	0° right 5° valgus left	30 mths	Not available	Not available	LT 0.36 RT 0.33	16 yrs	0° right 5° valgus left
5	13 yrs 7 mths	Medial proximal and distal RT and LT	10° valgus right 10° valgus left	0° right 0° left	15 mths	cLT 13 mths cRT 13 mths	LT 0.87 RT 0.87	LT 0.66 RT 0.66	16 yrs	0° right 0° left
6	5 yrs	Medial distal RF and LF	13° valgus right 15° valgus left	0° right 0° left	8 mths	cRF 9 mths cLF 11 mths	RF 0.89 LF 0.73	LF 1.8 RF 1.62	11 yrs	0° right 0° left
7	4 yrs 2 mths	Medial distal RF and LF	14° valgus right 14° valgus left	0° right 0° left	7 mths	cRF 7 mths cLF 7 mths	RF 1 LF 1	LF 2 RF 2	10 yrs	0° right 0° left

RT = right tibia; LT = left tibia; RF = right femur; RT = right tibia; c = control; control time = time predicted by The Multiplier.

procedures. The mean speed correction of the tibia was 0.49° per month (0.33° to 0.66°) and the average speed correction of the femur was 1.73° per month (1.02° to 2°). The mean of the coefficient for the femur was 0.98 (0.73 to 1.22) and the mean for the tibia was 1.64 (0.87 to 3). If we exclude the patient with the coefficient for the tibia that previously underwent tibial osteotomy, the coefficient is 1.19 (0.87 to 1.83). There were only two minor complications in the post-operative period: a screw mobilisation after four months that required its replacement and a screw

rupture at removal with a mild haematoma that resolved spontaneously without affecting the clinical outcome. A patient with ROD also affected by a bilateral slipped capital femoral epiphysis was treated by screw fixation.

Discussion

The surgical treatment of lower limb deformities secondary to ROD is a challenge. The traditional corrective osteotomies present some risks and limitations.¹ In fact, children

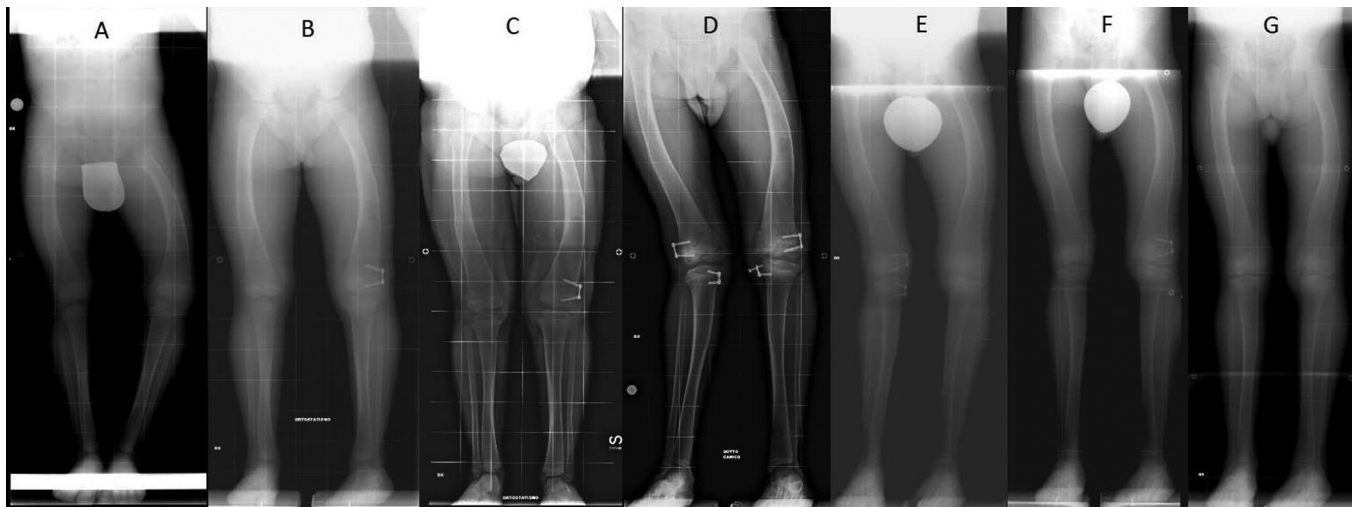


Fig. 1 Patient radiograph evaluation: (a) at eight years of age; (b-f) periodic follow-up of the patient with development of windswept deformity and subsequently correction by guided growth technique; (g) at final follow-up at 16 years of age.

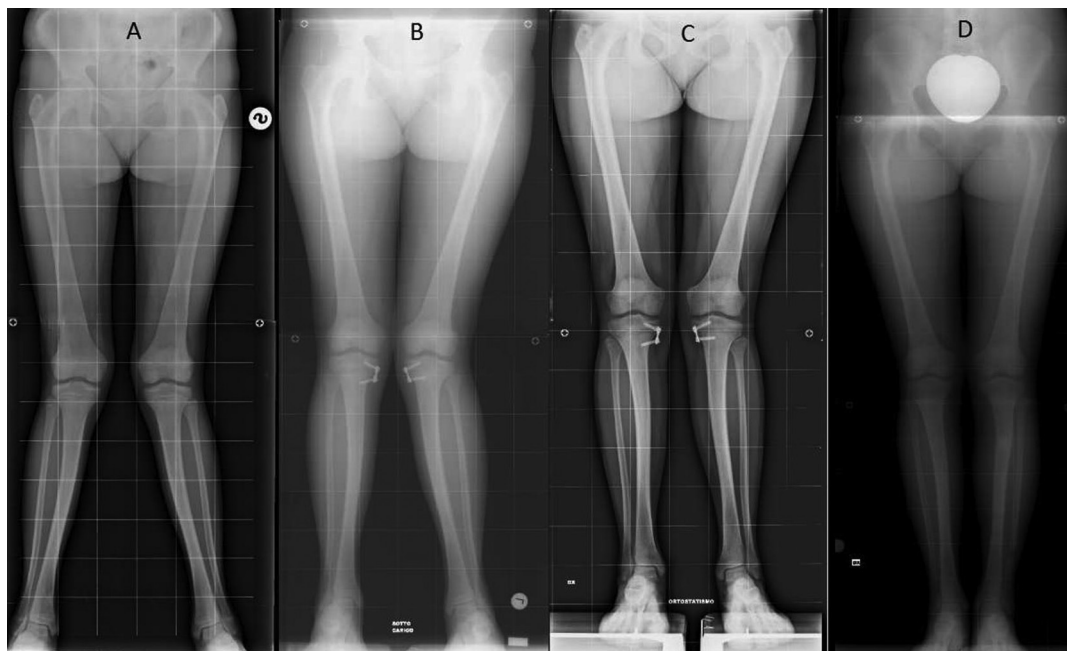


Fig. 2 Patient radiograph evaluation: (a) pre-operatively, at 13 years of age; (b, c) periodic follow-up of the patient after surgery; (d) at final follow-up at 16 years of age.

with reduced immunocompetence caused by either the uremic state or by steroid, and immunosuppressive therapy are at higher risk of wound and bone infections.² Moreover, a poor bone stock, due to osteomalacia and osteoporosis, may predispose to nonunion, stress fractures and failure of internal fixation. Osteosynthesis by crossed Steinmann pins, plates and external fixators is reported in the literature.^{11,17-21} Each of these solutions has its own advantages and limitations; however, all of them require an open osteotomy followed by a consolidation period during which weight-bearing is not allowed. The patients' age and their

metabolic state may affect the surgical decision. The site of the osteotomy needs accurate pre-operative planning to choose the best site and the best surgical technique.^{1,7} In our study, all patients presenting relevant osteodystrophic lower limb deformities achieved a good correction as a consequence of using the 'guided growth' technique. This method has many advantages in comparison with the classical corrective osteotomy; in fact, it is a minimally invasive procedure and the risk of post-operative infection is minimal, the hemiepiphysiodesis may be performed at multiple levels and can be repeated without problem every time

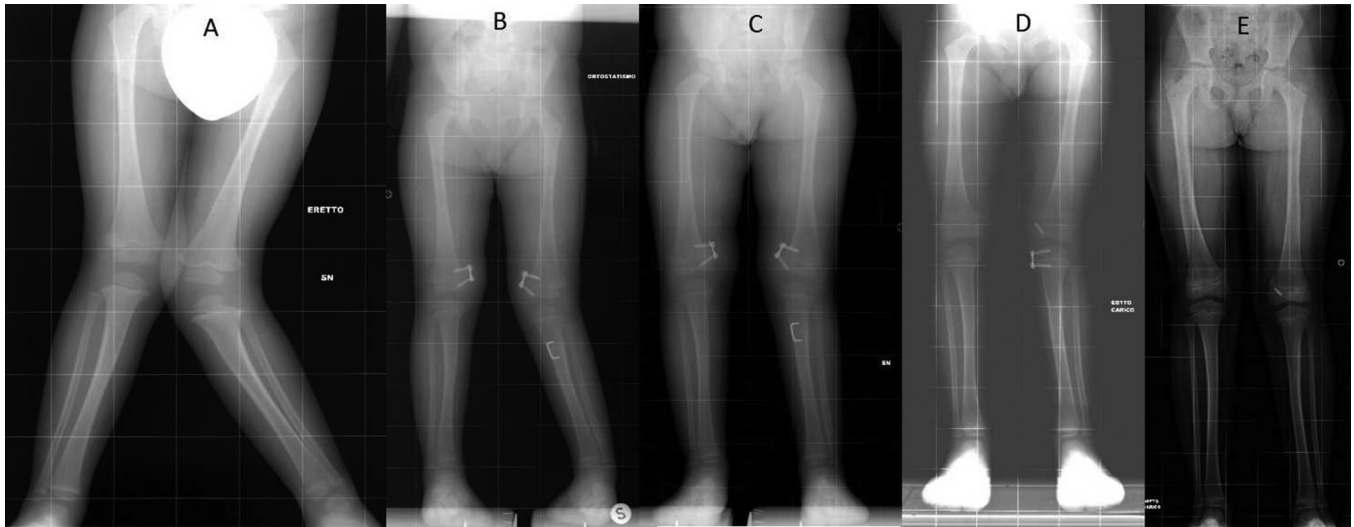


Fig. 3 Patient radiograph evaluation: (a) pre-operatively at age two years 11 months; (b-d) periodic follow-up after surgery; (e) at final follow-up at eight years of age.

the deformity relapses. The precarious metabolic status of the patient does not contraindicate the surgical procedure as there is no risk of delayed consolidation nor pseudoarthrosis. Although predisposition to infections of patients with renal failure is well-known, no infections or signs of inflammation were observed during the follow-up of our patients. The time needed to obtain the correction of the angular deformity was in the range of 7 to 30 months and this depends on the site, femoral, tibial or both, and on the amount the deformity. The correction is progressive and its speed, according to the different growth rate of each bone, is more rapid in the femur (1.73° per month) than in the tibia (0.49° per month). The time needed for the correction of femoral deformities was very close to the one predicted by the Multiplier Application as the coefficient of femoral correction which was 0.98 (0.73 to 1.22) (correction time observed / correction time estimated by Multiplier Application). On the other hand, the time required for the correction of the tibial deformity was much longer, as the coefficient of tibial correction was 1.68, and this fact was particularly evident with patients who underwent concomitant tibial osteotomy. In our opinion, the slowest correction of this last severe tibial deformity might be interpreted as expression of focal depression of the metabolism of the physis on its lateral side (overloaded by the severe and prolonged valgus deformity). If we exclude the patient with the coefficient for the tibia that previously underwent tibial osteotomy, the coefficient is 1.19 (0.87 to 1.83). In general, the speed of angular correction of lower limb deformities in ROD children does not seem easy to predict due to the lack of reliable data needed to assess and estimate the impact of renal disease on bone growth and metabolism. Nevertheless, our preliminary results suggest that the correction time predicted by the Multiplier for the femur substantially

corresponds to the time observed in our patients. With regard to the tibial speed of correction, we are unable to give reliable and useful information to predict the time required to obtain correction due to the relative low number of surgeries performed on this site.

It is commonly known that renal disease tends to persist chronically and to affect the physis during the whole growing period. Thus, it leads to some risk of deformity relapse. In our study, four out of seven patients relapsed and their deformity progress went in the opposite direction. A similar tendency in relapsing is reported in patients treated with guided growth technique for deformities of the lower limbs present in other dismetabolic conditions that affect the physis, as in mucopolysaccharidosis and X-linked hypophosphatemic rickets.^{18,21}

For the most successful anatomical and biomechanical outcome, the guided growth technique should be performed early. In fact, while in early manifestations the centre of the angular deformity is located on the metaphyseal-diaphyseal part of the femur or tibia, very close to the physis, in later presentations the centre of deformity is located closer to the centre of the diaphysis. A hemiepiphyseal performed at that time may guarantee the restoration of the mechanical axis of the lower limb but not the restoration of the anatomical shape of the single bone. Moreover, very severe angular deformities may suggest the opportunity to associate an osteotomy in order to shorten the time of correction, as it seemed opportune in one of our patients. A criticism concerning the use of hemiepiphyseal in the correction of ROD deformities is that guided growth gives a mono planar correction (on the frontal plane) while these deformities are multiplanar. However, rotational deformities were never clinically relevant in our patients. In the same way, the typical osteodystrophic procurvature of the

distal femur was never severe enough to justify a corrective osteotomy. The data from this study should encourage paediatricians to refer these patients to the attention of paediatric orthopaedic surgeons early in order to avoid serious progressive and disabling deformities.

The limitations of this study are the relatively small amount of cases, and this is due to the rarity of these deformities (5.8% of children with congenital or chronic renal diseases), and a short-medium follow-up period. Due to the retrospective nature of this study, it was not possible to correlate renal function and efficacy of guided growth and to identify specific metabolic factors or parameters at risk for recurrence.

In conclusion, the guided growth technique by hemiepiphyodesis was found to be safe and effective for correction of malalignment due to ROD. This method is able to correct deformities during a child's growth in multiple segments of the lower limb in order to achieve the optimal restoration of the mechanical axis. Short follow-up is required, particularly during correction of the femoral axis. As children with ROD may develop progressive deformities up to the end of their growth, and these deformities are prone to relapse, the patients must be monitored until adulthood. However, hemiepiphyodesis may be repeated without complications in relapsing cases.

Received 21 August 2017; accepted after revision 9 January 2017.

COMPLIANCE WITH ETHICAL STANDARDS

FUNDING STATEMENT

No benefits in any form have been received or will be received from a commercial party related directly or indirectly to the subject of this article.

OA LICENCE TEXT

This article is distributed under the terms of the Creative Commons Attribution-Non Commercial 4.0 International (CC BY-NC 4.0) licence (<https://creativecommons.org/licenses/by-nc/4.0/>) which permits non-commercial use, reproduction and distribution of the work without further permission provided the original work is attributed.

ETHICAL STATEMENT

All procedures performed in studies involving human participants were in accordance with the ethical standards of the institutional and/or national research committee and with the 1964 Helsinki declaration and its later amendments or comparable ethical standards.

Informed consent: Informed consent was obtained from all individual participants included in the study.

REFERENCES

1. **Bar-On E, Horesh Z, Katz K, et al.** Correction of lower limb deformities in children with renal osteodystrophy by the Ilizarov method. *J Pediatr Orthop* 2008;28:747-751.
2. **Langman CB.** Renal osteodystrophy: a pediatric perspective, 2005. *Growth Horm IGF Res* 2005;15:42-47.
3. **Wesseling-Perry K, Pereira RC, Tseng CH, et al.** Early skeletal and biochemical alterations in pediatric chronic kidney disease. *Clin J Am Soc Nephrol* 2012;7:146-152.
4. **Groothoff JW, Offringa M, Van Eck-Smit BL, et al.** Severe bone disease and low bone mineral density after juvenile renal failure. *Kidney Int* 2003;63:266-275.
5. **Bakkaloglu SA, Wesseling-Perry K, Pereira RC, et al.** Value of the new bone classification system in pediatric renal osteodystrophy. *Clin J Am Soc Nephrol* 2010;5:1860-1866.
6. **Oppenheim WL, Bowen RE, McDonough PW, Funahashi TT, Salusky IB.** Outcome of slipped capital femoral epiphysis in renal osteodystrophy. *J Pediatr Orthop* 2003;23:169-174.
7. **Wesseling-Perry K.** Defective skeletal mineralization in pediatric CKD. *Curr Osteoporos Rep* 2015;13:98-105.
8. **Wesseling-Perry K.** Bone disease in pediatric chronic kidney disease. *Pediatr Nephrol* 2013;28:569-576.
9. **Carvalho C, Magalhães J, Pereira L, et al.** Evolution of bone disease after kidney transplantation: A prospective histomorphometric analysis of trabecular and cortical bone. *Nephrology (Carlton)* 2016;21:55-61.
10. **Seifert ME, Hruska KA.** The kidney-vascular-bone axis in the chronic kidney disease-mineral bone disorder. *Transplantation* 2016;100:497-505.
11. **Dauids JR, Fisher R, Lum G, Von Glinski S.** Angular deformity of the lower extremity in children with renal osteodystrophy. *J Pediatr Orthop* 1992;12:291-299.
12. **Oppenheim WL, Shayestehfar BS, Salusky IB.** Tibial physeal changes in renal osteodystrophy: lateral Blount's disease. *J Pediatr Orthop* 1992;12:774-779.
13. **Oppenheim WL, Fischer SR, Salusky IB.** Surgical correction of angular deformity of the knee in children with renal osteodystrophy. *J Pediatr Orthop* 1997;17:41-49.
14. **Boero S, Michelis MB, Riganti S.** Use of the eight-plate for angular correction of knee deformities due to idiopathic and pathologic physis: initiating treatment according to etiology. *J Child Orthop* 2011;5:209-216.
15. **Stanitski DF.** Treatment of deformity secondary to metabolic bone disease with the Ilizarov technique. *Clin Orthop Relat Res* 1994;301:38-41.
16. **Stevens PM, Klatt JB.** Guided growth for pathological physes: radiographic improvement during realignment. *J Pediatr Orthop* 2008;28:632-639.
17. **Novais E, Stevens PM.** Hypophosphatemic rickets: the role of hemiepiphyodesis. *J Pediatr Orthop* 2006;26:238-244.
18. **Sharkey MS, Grunseich K, Carpenter TO.** Contemporary medical and surgical management of X-linked hypophosphatemic rickets. *J Am Acad Orthop Surg* 2015;23:433-442.
19. **Aguilar JA, Paley D, Paley J, et al.** Clinical validation of the multiplier method for predicting limb length discrepancy and outcome of epiphysiodesis, part II. *J Pediatr Orthop* 2005;25:192-196.
20. **Eralp L, Kocaoglu M, Cakmak M, Ozden VE.** A correction of windswept deformity by fixator assisted nailing. A report of two cases. *J Bone Joint Surg [Br]* 2004;86-B:1065-1068.
21. **Ashby E, Eastwood D.** Characterization of knee alignment in children with mucopolysaccharidosis types I and II and outcome of treatment with guided growth. *J Child Orthop* 2015;9:227-233.