

Difficulty in tracheal extubation followed by tracheal collapse after balloon dilatation for tracheal stenosis therapy

A case report

Nana Li, MM, Linjia Zhu, MM, Jie Sun, PhD, MD, Yinbing Pan, MD, Mei Gao, PhD, MD*

Abstract

Rationale: Tracheobronchomalacia (TBM) refers to the weakening trachea or the trachea loss of structural integrity of airway cartilaginous structures. It causes tracheal stenosis, resulting in significantly high rates of mortality. Bronchoplasty by high-pressure balloon dilatation under general anesthesia is a simple but effective and safe method to treat tracheobronchial stenosis. However, recurrent postoperative dyspnea after extubation due to tracheal collapse is still a challenge for anesthetists.

Patient concerns: A 52-year-old man weighing 72kg was scheduled for balloon dilatation surgery under general anesthesia because of breathing difficulties caused by tracheal stenosis. His previous medical history included rheumatoid arthritis, obstructive sleep apnea syndrome (OSAS), chronic bronchitis and a history of tracheal intubation. Laryngeal computerized tomography confirmed the stenosis at the level of thyroid gland.

Diagnosis: The tracheal collapse after balloon dilatation for tracheal stenosis therapy.

Interventions: Postoperatively, the patient presented with more serious and repetitive symptoms of dyspnea after extubation when compared to that before treatment. So, we had to re-insert the laryngeal mask airway (LMA), and exclude some anesthesia-associated factors, such as laryngospasm, bronchospasm and so on. After a series of treatments, we ultimately found the cause in time (the airway collapsed), and succeeded in tracheal extubation after the stent was inserted.

Outcomes: The patient recovered well and reported high satisfaction with anesthesia management.

Lessons: In such an emergency even, the anesthesiologist should take valuable treatments to ensure the patient's effective ventilation. If the anesthesia-related factors can be eliminated, tracheomalacia or airway collapse should be considered whenever dyspnea occurs in the patients who unexpectedly fail to be extubated.

Abbreviations: BMI = body mass index, BP = blood pressure, CPAP = continuous positive airway pressure, OSAS = obstructive sleep apnea syndrome, PATM = atmospheric pressure, PLUM = intraluminal pressure, PTM = transmural pressure, SpO₂ = pulse oximetry, TM = tracheomalacia.

Keywords: difficulty in extubation, tracheal collapse, tracheal stenosis

1. Introduction

Difficulty in breathing caused by tracheal stenosis is a life-threatening clinical emergency with a high mortality rate. The most common etiology includes tracheal tumors, foreign bodies, tracheal compression due to mediastinal goiter, tracheobronchomalacia or inappropriate endotracheal intubation and so on.^[1,2] In the past, surgical intervention was an efficient

technique for tracheal stenosis, however, with the rapid development of interventional treatment, the use of fiberoptic bronchoscopic balloon dilatation and place stents now provides a more convenient and less invasive alternative.^[3,4] This paper is a case report of a patient with tracheal stenosis who underwent balloon dilatation under general anesthesia and presented with breathing difficulties after the procedure due to tracheal collapse. After a series of treatments, we succeeded in tracheal extubation after the stent was inserted.

Editor: N/A.

NL is the first author.

The authors have no conflicts of interest to disclose.

Department of Anesthesiology, The First Affiliated Hospital of Nanjing Medical University, Nanjing, Jiangsu, PR China.

* Correspondence: Mei Gao, Department of Anesthesiology, the First Affiliated Hospital of Nanjing Medical University, Nanjing, PR China (e-mail: drgaomei@njmu.edu.cn).

Copyright © 2018 the Author(s). Published by Wolters Kluwer Health, Inc. This is an open access article distributed under the Creative Commons Attribution-NoDerivatives License 4.0, which allows for redistribution, commercial and non-commercial, as long as it is passed along unchanged and in whole, with credit to the author.

Medicine (2018) 97:22(e10907)

Received: 2 January 2018 / Accepted: 7 May 2018

<http://dx.doi.org/10.1097/MD.00000000000010907>

2. Methods

We report a case of difficulty in tracheal extubation followed by tracheal collapse. The ethics committee considered that an approval to conduct this single case study was not necessary. Informed consent to publication was obtained from the patient.

3. Case presentation

3.1. Medical history

A 52-year old male patient (weight 75 kg, height 165 cm) was admitted to our hospital with complaints of difficulty in breathing for more than 20 days. On July 19, 2017, he was treated for shock induced by diarrhea, and underwent mechanical

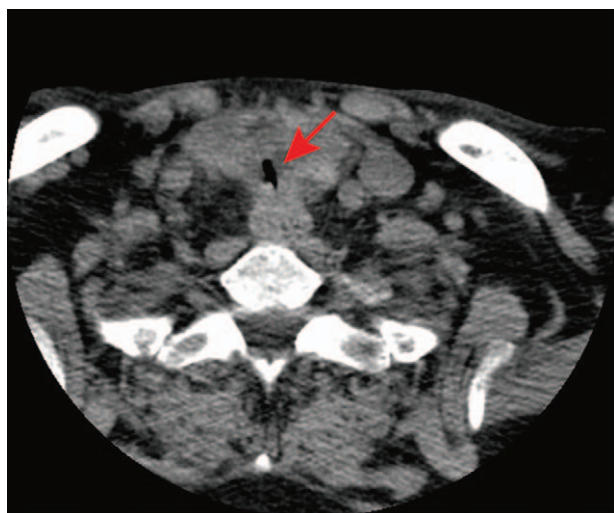


Figure 1. Computerized tomography scan images of the patient. The arrow refers to the narrowed segment.

ventilation after endotracheal intubation, while receiving continuous renal replacement therapy, etc. The patient began experiencing breathing difficulties on the 7th day after extubation (August 3, 2017), and chest computed tomography revealed primary tracheal stenosis. Initially, dyspnea was relieved after treatment (the specific treatment is unknown). However, on August 24, 2017, the patient returned to our hospital because of the progressive aggravation of dyspnea, accompanied with cough and yellow phlegm. Laryngeal computerized tomography confirmed stenosis at the level of the thyroid gland (Fig. 1). His medical history included rheumatoid arthritis for 10 years, treated with oral medication including meloxicam capsules, alfacalcidol, tripterygium glycosides and prednisone, as well as obstructive sleep apnea syndrome (OSAS) and chronic bronchitis. Moreover, the patient had no documented allergies or history of surgery. The physical examination revealed a blood pressure (BP) of 145/89 mm Hg, with a heart rate of 100 beats per minute and respiratory rate of 24 breaths per minute. Preoperative electrocardiography and laboratory examinations revealed no abnormalities. In addition, arterial blood gas analysis showed: pH 7.44, PCO_2 45 and PO_2 81 mm Hg.

3.2. Anesthetic regimen

The patient presented with orthopnea combined with laryngeal stridor when inhaling, and received no sedative premedication. Invasive BP monitoring was established in the right radial artery. The baseline vital signs of the patient were: BP 142/71 mm Hg, heart rate 100 beats per minute, respiratory rate 24 breaths per minute, pulse oximetry (SpO_2) 98% with air. The arterial blood gas analysis results were: pH 7.44, PCO_2 41 mm Hg, PO_2 78 mm Hg. Routine monitoring, including electrocardiogram, BP, SPO_2 and end-tidal carbon dioxide, was performed before anesthesia. Given his obesity (BMI 27.5), Mallampati IV and history of OSAS, the planned anesthetic management included minimal to moderate sedation under strict monitoring. Multiple typical instruments for managing difficult airways were prepared before the induction, such as laryngeal mask, fiberoptic bronchoscope, and endotracheal tube with hard stylet. The tracheal stenosis was located beneath the isthmus thyroid. When emergency difficulties with the mask ventilation occur after the administration of anesthesia, the probability of a successful tracheotomy is lowered. In that case, tracheal intubation should be attempted by inserting the endotracheal tube across the narrow place.

The patient received full preoxygenation before induction, 150 mg propofol for sedation, 10 mg dexamethasone to prevent laryngeal edema, and 0.5 mg atropine to decrease oropharyngeal secretions. Subsequently, an inner diameter 7.5 mm nasopharyngeal airway was inserted and, fortunately, mask ventilation proceeded effectively. The patient then received 70 mg rocuronium and 0.2 mg fentanyl, followed by 400 mg h^{-1} propofol and $800\text{ }\mu\text{g h}^{-1}$ remifentanyl as maintenance. The respiratory physician attempted to use an open-tube rigid bronchoscope for 5 minutes, until the oxygen saturation declined to 95%, and failed. Then, an original 4-sized laryngeal mask was placed for both controlled mechanical ventilation and fiberoptic bronchoscopic operation. The peak inspiratory pressure was 26 or 28 cm H_2O , with 500 ml tidal volume and an inspiratory to expiratory ratio of 1:1.5. The bronchoscopy revealed that the severe tracheal stenosis was about 2 cm distant from the subglottic, the narrowest tracheal diameter was 3 mm, and the cartilage ring had a suspicious fracture at the 2 o'clock direction at the narrow place (Fig. 2). Balloon dilation was subsequently performed, and the narrowest tracheal diameter improved to 9 mm after expansion. The bronchoscope passed through the

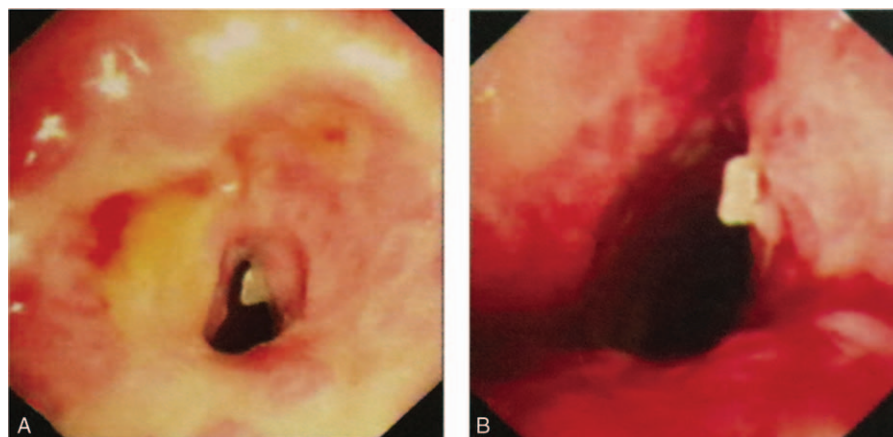


Figure 2. Bronchoscopic view demonstrating the tracheal stenosis and suspicious cartilage ring fracture. Received balloon dilatation before (A) and after (B).

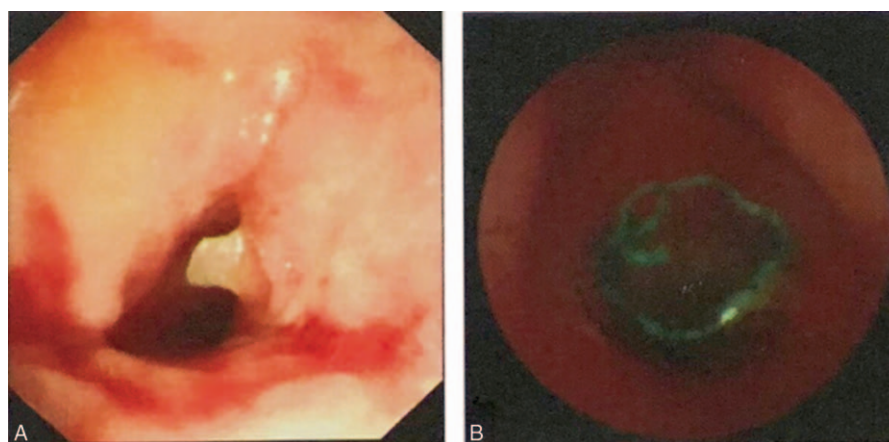


Figure 3. Repeat bronchoscopic view, the representative bronchoscopic images before (A) and after airway stent placements (B).

narrow place and revealed that the lower trachea presented a scabbar sample change, was unobstructed, and the tracheal carina was sharp. The ventilation settings remained unchanged and the peak was 20 to 22 cm H₂O, with propofol sedation until respiratory recovery. Intravenous 2mg neostigmine and 1mg atropine were used for antagonizing rocuronium bromide, the sputum was suctioned, and the laryngeal mask was pulled out after the patient regained consciousness. Unexpectedly, the patient experienced dyspnea with laryngeal stridor and dysphoria immediately after extubation. The movement of the thoracic cavity was strengthened, but there were no breathing sounds on auscultation, indicating that the procedure failed to maintain effective ventilation. Subsequently, the oxygen saturation of the patient dropped below 80% with a progressively rapid heartbeat, resulting in the development of cyanotic lips. Under such circumstance, we attempted to use pressurized facemask ventilation, but the patient was restless and uncooperative, thus the oxygen saturation did not increase significantly. Therefore, we administered 100mg propofol intravenous injection prior to pressurized facemask ventilation to regulate his breathing. Finally, the oxygen saturation increased to 95% with 6 L min⁻¹ O₂. After approximately 5 minutes, the patient regained consciousness. The patient's chest continued to rise, but still no breathing sounds were detected by auscultation. Consequently, the oxygen saturation exhibited a decreasing trend. Hence, the patient was again supplemented with propofol and remifentanyl followed by laryngeal mask airway insertion. At this point, the vital signs were stable, the peak inspiratory pressure was maintained at 22 to 24 cmH₂O, and the oxygen saturation was 99% with 2 L min⁻¹ O₂. Approximately 20 minutes later, the patient suffered similar breathing difficulties and dysphoria after extubation. Consequently, we had to administer propofol and remifentanyl intravenously prior to inserting the laryngeal mask airway. Meanwhile, we called back the respiratory physician, and discussed with them to find a feasible solution. After the respiratory physician checked the airway again with a fiberoptic bronchoscope and inserted a stent (Fig. 3), the patient was gradually relieved from respiratory distress after extubation. At last, as his vital signs stabilized, the patient was sent back to the ward.

4. Discussion

The first dyspnea episode appeared after extubation and could be explained by the following: laryngospasm; upper airway

obstruction induced by glossoptosis; bronchospasm; and airway collapse. After neostigmine intravenous injection, the peak inspiratory pressure was equal to the level after balloon dilatation under positive pressure ventilation, about 22 cmH₂O. As the patient had no history of asthma and airway hyperresponsiveness, bronchospasms were ruled out for the moment. In general, difficult breathing caused by stenosis should be improved significantly by successful balloon dilatation. During the operation, it was observed that the tracheal stenosis was considerably relieved. Therefore, airway collapse or restenosis were not considered at first. As the patient began breathing with difficulty, experiencing laryngeal stridor after extubation, acute obstruction of upper respiratory tract induced by laryngospasms or glossocoma was considered (the patient was obese, with a short neck, and had history of OSAS). In addition, the 3 processes of recovery from anesthesia were similar, the patient exhibiting paradoxical respiratory movements and no effective spontaneous ventilation, even when the nasopharyngeal airway was inserted. When administering propofol for sedation, effective artificial ventilation could be implemented via facemask. In patients experiencing laryngeal spasms, pressurized facemask ventilation with 100% oxygen is recommended, as this can ameliorate most mild cases, whereas serious cases can be relieved aided by propofol. However, this patient experienced dyspnea repeatedly after multiple extubations, and could not be stabilized through conventional methods. Therefore, laryngospasms or glossocoma were excluded. At last, upon reviewing the procedure, a suspicious cartilage ring fracture was identified, which could have resulted in airway collapse after balloon dilation. This was confirmed by the application of the covered stent, which ultimately rescued the patient.

A review of the entire process of this rescue suggested that the meticulous management of anesthesia played a key role in preventing unnecessary interventions and treatments. First, tracheomalacia (TM) and collapse resulting from the enlargement of the thyroid gland is more common than a broken cartilage ring. Therefore, we did not pay enough attention to "the suspicious tracheal cartilage ring fracture" at the beginning. TM, which has also been referred to as tracheobronchial collapse, refers to a weakening of the trachea, or to the loss of structural integrity of airway cartilaginous structures.^[5] Thus, the airway becomes softer and more susceptible to collapse. The symptoms of TM may be misdiagnosed as asthma or chronic cough, due to a lack of specific pathognomonic history and clinical findings.

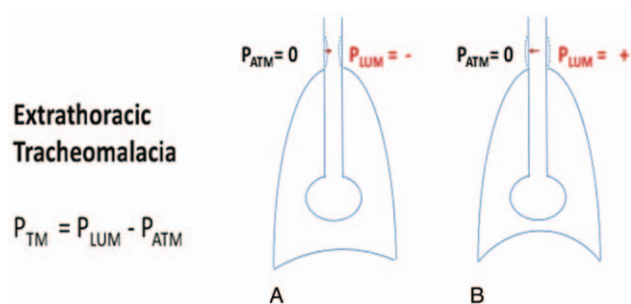


Figure 4. (A) During inspiration, PLUM is less than PATM, creating a negative extrathoracic PTM and extrathoracic airway collapse. (B) During exhalation, PLUM exceeds PATM, creating a positive extrathoracic PTM and a patent extrathoracic airway. Reproduced from Hysinger EB, Panitch HB: Paediatric Tracheomalacia. *Paediatr Respir Rev* 2016, 17:9–15. PATM=atmospheric pressure, PLUM=intraluminal pressure, PTM=transmural pressure.

Nowadays, flexible fiberoptic bronchoscopic visualization of dynamic tracheal or bronchial collapse is considered as the “gold standard” for diagnosing TM.^[5] TM may be caused by recurrent airway irritation, which can occur with tracheobronchitis, smoking, chronic obstructive pulmonary disease, asthma, or may be acquired due to mechanical factors, such as trauma, and intubation.^[6,7] In this patient, stenosis was detected at the level of the thyroid gland, between the glottis and sternal notch, which can indicate extrathoracic TM. Extrathoracic TM involves the dynamic collapse of the airway, which occurs during inhalation rather than exhalation. In addition to the rigidity of the airway, other factors, such as the magnitude of pressure applied across it, or the transmural pressure (PTM) across the tracheal wall, determine the presence and extent of central airway collapse. PTM is defined as the intraluminal pressure (PLUM) minus the pressure outside the trachea. The outside pressure is equal to the atmospheric pressure (PATM), which is considered to be zero in the extrathoracic trachea ($PTM = PLUM - PATM$). During inspiration, when PLUM is negative, the PTM is also negative, increasing the degree of narrowing. Meanwhile, negative intrapleural pressures are transmitted to the extrathoracic trachea due to pleural reflections, which may cause the upper airway to collapse. Conversely, during exhalation, PTM is positive, causing the extrathoracic trachea to expand (Fig. 4).^[8]

At a resting state, the normal trachea can resist the swings in pressure with minimal deformity, benefiting from the small magnitude of changes in PTM. However, some forceful respiratory maneuvers, such as coughing or exertion, can increase transmural pressures, leading to dynamic airway collapse.^[9] Besides, in TM patients, the increased turbulent flow combined with the excessive airway narrowing contribute to enhancing the airway resistance, which requires greater transpulmonary pressures to maintain the expiratory airflow. Treatment of TM depends on the etiology and severity of the airway collapse. Previous studies have shown that continuous positive airway pressure (CPAP) can not only decrease the pulmonary resistance and improve airflow in patients with expiratory airflow obstruction, but also reduces the elevated inspiratory transpulmonary pressures required to initiate airflow, thereby decreasing the inspiratory work of breathing.^[10] CPAP acts as a pneumatic stent and prevents airway collapse throughout the respiratory cycle. This management also applies to laryngospasms. Consequently, the presence of TM or airway collapse should be considered first at the onset of dyspnea in

patients who unexpectedly fail extubation.^[11] In such cases, appropriate treatment options are needed, such as temporizing with positive pressure ventilation and supportive care until the respiratory stressors are corrected. In the presented case, we did not communicate with the surgeon in a timely and effective manner. Balloon dilatation through flexible fiberoptic bronchoscopy is a simple but effective method for treating proximal benign tracheobronchial stenosis. However, this method does not appear to work as well in patients with inflammatory stenosis, TM, or external compressive stricture. Nevertheless, tracheal stenting has showed promising results in dilating and supporting softer airways. As, in our patient, a “suspicious tracheal cartilage ring fracture” was observed during surgery, balloon expansion may not be the most suitable intervention. The absence of cartilage crescents or “rings” has been speculatively suggested as a cause for segmental tracheal collapse.^[9] Therefore, the reason for dyspnea after the first tracheal extubation could have been tracheal collapse. The existing research has found that stenting can be a valuable definitive treatment in patients with several previous unsuccessful attempts at tracheal reconstruction.^[12] Placement of a silicon stent is recommended for the treatment of severe cases of TM. Due to the life-threatening complications resulting from the rapid development of tracheal collapse, it is necessary to judge and resolve this condition in a timely and effective manner. Based on the reflection and discussion about the rescue process, we have a more comprehensive understanding of the patient’s condition and dynamic changes, and have gained valuable experience for future work.

5. Conclusion

The presence of TM or airway collapse should be considered at the onset of dyspnea in patients who unexpectedly fail extubation. Subsequent careful preoperative assessment and effective communication with the surgeons are essential to achieve the best outcome.

Author contributions

Resources: Nana Li.

Supervision: Linjia Zhu, Jie Sun, Yinbing Pan.

Writing – original draft: Nana Li.

Writing – review & editing: Mei Gao.

References

- [1] Cosano PA, Munoz CL, Cosano PF, et al. Endoscopic treatment of central airway stenosis: five years’ experience. *Arch Bronconeumol* 2005;41:322–7.
- [2] Thornton RH, Gordon RL, Kerlan RK, et al. Outcomes of tracheobronchial stent placement for benign disease. *Radiology* 2006;240:273–82.
- [3] Maeda K, Ono S, Tazuke Y, et al. Long-term outcomes of congenital tracheal stenosis treated by metallic airway stenting. *J Pediatr Surg* 2013;48:293–6.
- [4] Rahman NA, Fruchter O, Shitrit D, et al. Flexible bronchoscopic management of benign tracheal stenosis: long term follow-up of 115 patients. *J Cardiothorac Surg* 2010;5:2.
- [5] Carden KA, Boiselle PM, Waltz DA, et al. Tracheomalacia and tracheobronchomalacia in children and adults: an in-depth review. *Chest* 2005;127:984–1005.
- [6] McNamara VM, Crabbe DC. Tracheomalacia. *Paediatr Respir Rev* 2004;5:147–54.
- [7] Murgu SD, Colt HG. Tracheobronchomalacia and excessive dynamic airway collapse. *Respirology* 2006;11:388–406.
- [8] Hysinger EB, Panitch HB. Paediatric tracheomalacia. *Paediatr Respir Rev* 2016;17:9–15.

- [9] Wittenborg MH, Gyepes MT, Crocker D. Tracheal dynamics in infants with respiratory distress, stridor, and collapsing trachea. *Radiology* 1967;88:653–62.
- [10] Martin JG, Shore S, Engel LA. Effect of continuous positive airway pressure on respiratory mechanics and pattern of breathing in induced asthma. *Am Rev Respir Dis* 1982;126:812–7.
- [11] Collard P, Freitag L, Reynaert MS, et al. Respiratory failure due to tracheobronchomalacia. *Thorax* 1996;51:224–6.
- [12] Schmidt B, Olze H, Borges AC, et al. Endotracheal balloon dilatation and stent implantation in benign stenoses. *Ann Thorac Surg* 2001; 71:1630–4.