



Live birth after treatment of a spontaneous ovarian heterotopic pregnancy: A case report

Inês Ramalho¹, Iolanda Ferreira^{*,1}, João Paulo Marques, Maria João Carvalho, António Lobo, Teresa Rebelo, José Paulo Moura, Fernanda Águas

Obstetrics and Gynecology Department, Centro Hospitalar e Universitário de Coimbra, Maternidade Doutor Daniel de Matos, R. Miguel Torga, 3030-165, Coimbra, Portugal

ARTICLE INFO

Article history:

Received 24 August 2019
Received in revised form 8 September 2019
Accepted 10 September 2019

Keywords:

Heterotopic pregnancy
Ovarian pregnancy
Laparoscopic management

ABSTRACT

Spontaneous heterotopic pregnancies occur in about 1/30000 pregnancies, with the ovarian subtype comprising 2.3% of the total.

We report the case of a healthy 32-year-old woman, gravida 4, para 3, who presented to the emergency room with severe abdominal pain. Two weeks earlier, pelvic ultrasound had revealed a 6-week intrauterine pregnancy. She was hemodynamically stable, but had rebound tenderness on the right iliac fossa. Transvaginal ultrasound revealed an evolutive intrauterine pregnancy with a gestational age (GA) of 8 weeks, with a synchronous evolutive adnexal pregnancy of the same GA and some free fluid in the pouch of Douglas. She underwent an urgent laparoscopy which showed an intact gestational sac containing an embryo on the right ovary associated with mild hemoperitoneum. An ovarian wedge resection was performed to preserve ovarian tissue. The intrauterine pregnancy had no complications and the patient delivered vaginally at term.

Heterotopic pregnancy is potentially life-threatening. Despite being extremely rare after natural conception, and even more so in the absence of major risk factors, it should be considered in any pregnant woman with abdominal pain. A high index of suspicion is important for a prompt diagnosis, selection of the appropriate surgical treatment and successful obstetric outcomes.

© 2019 The Authors. Published by Elsevier B.V. This is an open access article under the CC BY-NC-ND license (<http://creativecommons.org/licenses/by-nc-nd/4.0/>).

1. Introduction

A heterotopic pregnancy (HP) is defined as the simultaneous presence of two or more implantations in different places, usually one intra- and another extrauterine [1–3]. Spontaneous HP occurs in about 1/30000 pregnancies [4–6]. The diagnosis has become more frequent with the advent of assisted reproductive techniques (ART), with an estimated incidence of up to 1 in 100 such pregnancies [7–9].

The most common extrauterine site for HP is the fallopian tube (95–97%), but it can be found less frequently in the cervix, ovary or abdomen [1]. An ovarian HP comprises 2.3% of all heterotopic pregnancies [10]. The live birth rate of intra-uterine pregnancies is 70% after in vitro fertilization [11]. Other authors state that in two-thirds of intrauterine pregnancies delivery is at term [6].

2. Case presentation

A healthy 32-year-old woman, gravida 4, para 3, presented to the emergency room with severe abdominal pain in the right lower quadrant, of sudden onset. Two weeks before, ultrasound had revealed a 6-week intrauterine pregnancy and no adnexal pathology was reported. She had no complaints of vaginal bleeding but had anorexia and was feeling faint. On clinical examination she was hemodynamically stable, but had rebound tenderness on the right iliac fossa. Transvaginal ultrasound revealed an evolutive 8-week gestational age (GA) intrauterine pregnancy, along with a synchronous adnexal pregnancy with the same GA and some free fluid in the pouch of Douglas (Figs. 1 and 2). She underwent an urgent laparoscopy which showed an intact gestational sac containing an embryo with cardiac activity lying on the surface of the right ovary, as well as active bleeding from the adherent gestational sac, resulting in mild hemoperitoneum (Fig. 3). An ovarian wedge resection was performed using a bipolar cautery device and scissors in order to preserve ovarian tissue. Estimated blood loss was approximately 200 mL. She was discharged two days. The post-operative period and evolutive intrauterine gestation were both

* Corresponding author at: Av. Calouste Gulbenkian, n.º 63 s.ºt.º, 3000-092, Coimbra, Portugal.

E-mail address: iolandafferreira04@gmail.com (I. Ferreira).

¹ The authors intend to be recognized as "joint authors" of this article.

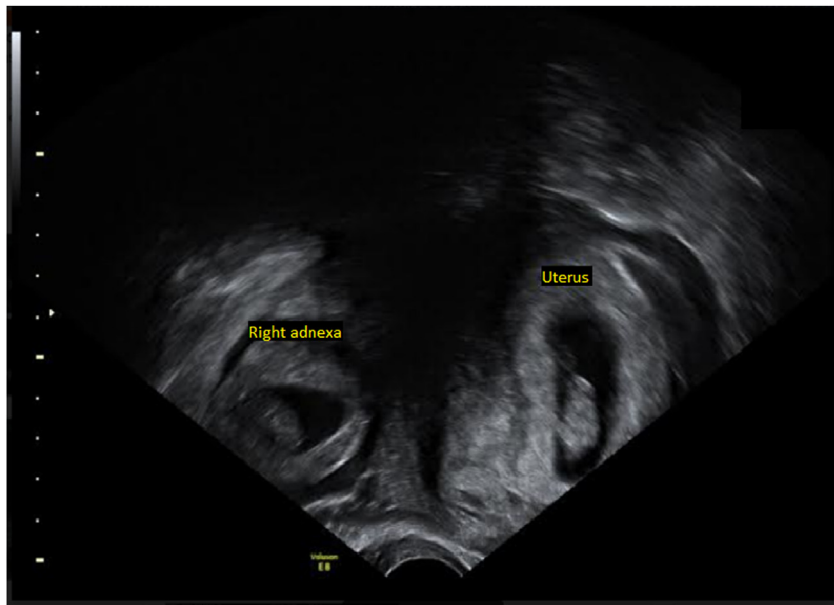

Fig. 1. Confirmation of heterotopic pregnancy on vaginal ultrasound. An intra-uterine and right adnexal gestational sac with a live embryo can be seen.

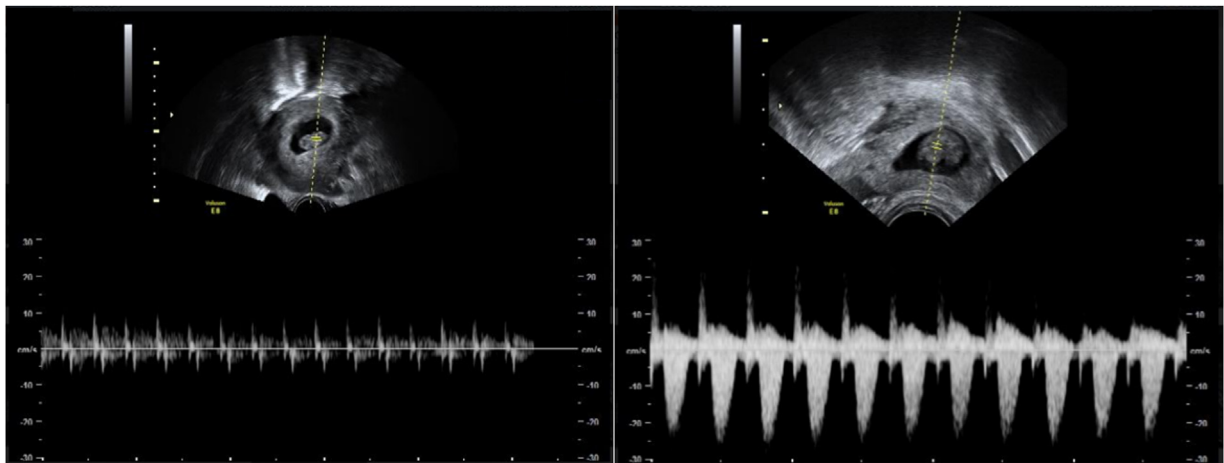


Fig. 2. Presence of cardiac activity on both embryos confirmed on ultrasound.

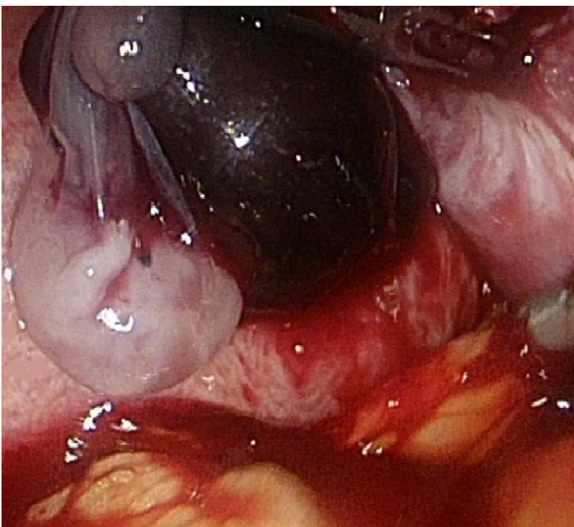


Fig. 3. Image of embryo and trophoblastic tissue attached to the right ovary on laparoscopy.

uneventful. Histology of the ovarian tissue confirmed an ectopic pregnancy. The intrauterine pregnancy had no complications and the patient delivered vaginally at term.

3. Discussion

The majority of HPs are located in the fallopian tubes and are mainly (70%) diagnosed between 5 and 8 weeks of gestation [6,12]. The diagnosis is made less frequently as gestational age increases, with about 20% of diagnoses between 9 and 11 weeks, and less than 10% after 11 weeks [3,7].

3.1. Diagnosis

The diagnosis of HP at an early stage can be problematic due to the absence of symptoms [13]. This situation frequently occurs where there is no blood loss [3,8]. Our patient, however, was feeling faint and reported continuous abdominal pain in the right lower quadrant, of sudden onset, as well as anorexia. Indeed, abdominal pain and/or vaginal bleeding are the most common symptoms of HP [8,9]. On gynaecological examination, an adnexal mass was

described, as well as peritoneal irritation [12,14]. Taking the challenge regarding the diagnosis of HP into account, Reece et al. identified abdominal pain, enlarged uterus, peritoneal irritation, and adnexal masses as signs that should raise suspicion of this diagnosis [3]. The most common differential diagnoses in the context of severe abdominal pain in early pregnancy are miscarriage, ectopic pregnancy, intrauterine pregnancy with haemorrhagic corpus luteum, ovarian hyperstimulation syndrome after in vitro fertilisation and adnexal torsion. Non-gynaecological causes, such as appendicitis, cholecystitis, bowel obstruction or pancreatitis, should also be excluded [9,12].

The above-mentioned symptoms associated with increased serum chorionic gonadotropin (β -hCG) concentration without an intrauterine pregnancy can lead to an early diagnosis of ectopic pregnancy [3]. Nevertheless, the intrauterine pregnancy also causes an increase in serum β -hCG concentration, which leads to difficulty in diagnosing HP. Also, monitoring of doubling rates does not aid HP diagnosis, as up to 17% of ectopic pregnancies have normal doubling rates. Measuring progesterone levels is also not recommended because low progesterone levels cannot distinguish between non-viable intrauterine and ectopic pregnancies, and high levels cannot exclude the presence of an ectopic or heterotopic pregnancy [12].

The mainstay of appropriate diagnosis of HP is a high index of suspicion plus the thoughtful use of transvaginal sonography with systematic evaluation of the adnexa early in the first trimester [15,16]. Although the evaluation of an early gestation should include the adnexa, the diagnosis of an intrauterine pregnancy often leads incorrectly to the exclusion of the hypothesis of a concomitant ectopic pregnancy [3,7].

Therefore, some authors have shown that ultrasound has low sensitivity in diagnosing HP, and that in up to 33% of cases ultrasound reports a normal intrauterine pregnancy and so gives false reassurance [1]. Ultrasound identification of an ectopic gestation has a sensitivity and specificity of 71%–100% and 41%–99%, respectively [13]. Another study confirmed this by reporting that, despite the fact that combined quantitative β -human chorionic gonadotropin (β -hCG) assay and colour Doppler ultrasonography significantly improve diagnostic sensitivity, the definitive diagnosis of HP is made by laparoscopy/laparotomy in 74% of cases [9,12].

3.2. Risk factors

Although our patient had no risk factors for ectopic pregnancy, there are several to take into account. The most common risk factors associated with HP are previous history of ectopic pregnancy, pelvic inflammatory disease (PID), abdominal adhesions, tubal surgery and use of ART [17–19]. Due to the high risk of HP in an ART scenario, single-embryo transfer and ultrasound monitoring of early gestation are practised in many fertility clinics [17]. In fact, these patients should always be evaluated for ectopic pregnancy despite the presence of an intrauterine gestation [18]. Less frequent risk factors for ectopic and heterotopic pregnancy are increasing maternal age, smoking, endometriosis, in utero diethylstilbestrol exposure and use of an intrauterine device [7,15]. However, as in our case, HP can occur in the absence of any risk factors [13]. A systematic review stated that about 29% of HP cases had no risk factors, 71% had at least one risk factor and 10% had three or more risk factors, emphasizing the importance of imaging for HP diagnosis [20].

3.3. Treatment

The main goal of HP treatment is to preserve the intrauterine pregnancy while removing the extrauterine pregnancy and the risks associated with it [7]. We can split these treatment options into medical and surgical modalities [2,13]. The chosen treatment

modalities have to be tailored for each patient, depending on various factors, such as the patient's clinical status (namely haemodynamic stability), gestational age at diagnosis and patient choice [1].

Considering haemodynamically stable patients, non-surgical options can be considered [2]. When there is a wish to maintain the intrauterine pregnancy, the most appropriate course of action is to selectively reduce the ectopic pregnancy with an ultrasound-guided injection of potassium chloride or hyperosmolar solution. This can be effective even in ectopic pregnancies located in the uterine cervix or a scar from a previous caesarean section [8]. A systemic injection of methotrexate can be considered only if the patient does not want to maintain the intrauterine pregnancy [2,7].

Surgical treatment of HP is required when there is accompanying hemoperitoneum or when conservative treatment fails [8]. The laparotomic or laparoscopic approaches are valid options; however, whenever possible, the laparoscopic approach offers many advantages over the laparotomic [7]. It offers the surgeon better operative field exposure, involves minimal manipulation of the uterus, and is associated with faster recovery and less postoperative pain compared with laparotomy [2,3]. Concern has been raised about the potential teratogenesis and risk of miscarriage caused by general anaesthetic drugs and carbon dioxide pneumoperitoneum on the foetus [3,13]. However, recent evidence suggests that laparoscopic surgery is safe in the first trimester of pregnancy if the operating time is less than 60 min and the intraperitoneal pressure is maintained below 10–12 mmHg [1]. It is also known that there is no increase in congenital malformations associated with surgery during the first trimester [2].

In the reported case, the patient underwent a laparoscopic ovarian wedge resection in order to remove the HP that was attached to the ovary. The uterus was not manipulated, in order to preserve the intrauterine pregnancy. This is considered the safest treatment option by most gynaecologists [1].

3.4. Prognosis

Heterotopic pregnancy is associated with a considerable risk of maternal morbidity and mortality, due to the risk of the rupture of the ectopic pregnancy [12]. The maternal mortality rate is 0.50 per 100 000 live births [8]. This is mostly due to hypovolemic shock, which can also affect the foetus and lead to its death [2]. Nevertheless, it is known that in surgically managed HP, about two-thirds of intrauterine pregnancies lead to live delivery, while the other third end in an abortion [3,12,16].

4. Conclusions

The fallopian tube is the most common site of HP and the involvement of other pelvic structures such as the ovary is extremely rare. Consequently, there are no treatment guidelines for clinicians dealing with this type of HP. This is one of the reasons why case reports on this subject are so important. To our knowledge, this case report of a patient with HP is the first to describe the normal evolution of the intrauterine pregnancy, with a live birth at term, after surgical treatment with laparoscopic wedge resection of the ectopic pregnancy. The management of HP with preservation of the intrauterine pregnancy is still an obstetric challenge.

Heterotopic pregnancy is potentially life-threatening. Despite being extremely rare following natural conception, and even more so in the absence of major risk factors, it should always be considered in any patient with severe abdominal pain. This case shows that rare and unlikely medical cases do occur, and thus a high index of suspicion is important for a prompt diagnosis, the selection of appropriate surgical treatment and successful obstetric outcomes.

Contributors

Inês Ramalho contributed to the conception and design of the study, acquisition of data, analysis and interpretation of data, and the drafting of the article.

Iolanda Ferreira contributed to the conception and design of the study, acquisition of data, analysis and interpretation of data, and the drafting of the article.

João Paulo Marques participated in the acquisition of data, analysis and interpretation of data, the drafting of the article, its critical revision for important intellectual content and the final approval of the version to be submitted.

Maria João Carvalho participated in the acquisition of data, analysis and interpretation of data, the drafting of the article, its critical revision for important intellectual content and the final approval of the version to be submitted.

António Lobo participated in the acquisition of data, analysis and interpretation of data, the drafting of the article, its critical revision for important intellectual content and the final approval of the version to be submitted.

Teresa Rebelo participated in the acquisition of data, analysis and interpretation of data, the drafting of the article, its critical revision for important intellectual content and the final approval of the version to be submitted.

José Paulo Moura participated on the critical revision for important intellectual content and the final approval of the version to be submitted.

Fernanda Águas participated on the critical revision for important intellectual content and the final approval of the version to be submitted.

Declaration of Competing Interest

The authors declare that they have no conflict of interest regarding the publication of this case report.

Funding

No specific grant from funding agencies in the public, commercial or not-for-profit sectors was received in relation to this case report.

Patient consent

Written informed consent was obtained from the patient for publication of this case report and accompanying images.

Provenance and peer review

This case report was peer reviewed.

References

- [1] K.R. Gibson, A.W. Horne, Ruptured heterotopic pregnancy: an unusual presentation of an uncommon clinical problem, *BMJ Case Rep.* 2012 (2012).
- [2] J.M. Eom, J.S. Choi, J.H. Ko, J.H. Lee, S.H. Park, J.H. Hong, et al., Surgical and obstetric outcomes of laparoscopic management for women with heterotopic pregnancy, *J. Obstet. Gynaecol. Res.* 39 (12) (2013) 1580–1586.
- [3] Y. Guan, C. Ma, Clinical outcomes of patients with heterotopic pregnancy after surgical treatment, *J. Minim. Invasive Gynecol.* 24 (7) (2017) 1111–1115.
- [4] E. Tingi, J. Rowland, L. Hanna, A case of heterotopic pregnancy following spontaneous conception, *J. Obstet. Gynaecol.* 35 (4) (2015) 430–431.
- [5] A. Chadee, S. Rezaei, C. Kirby, E. Chadwick, S. Gottimukkala, A. Hamaoui, et al., Spontaneous heterotopic pregnancy: dual case report and review of literature, *Case Rep. Obstet. Gynecol.* 2016 (2016) 2145937.
- [6] F. Uysal, A. Uysal, Spontaneous heterotopic cervical pregnancy and successful pregnancy outcome, *J. Ultrasound Med.* 32 (2) (2013) 375–376.
- [7] G.C. Pratilas, P. Chatzis, N. Panteleris, K. Chatzistamatiou, L. Zeipiridis, K. Dinas, Concealed heterotopic pregnancy at 12 weeks, with no coexisting risk factors: lessons to be learned, *J. Obstet. Gynaecol. Res.* 43 (1) (2017) 228–231.
- [8] E. Altıntaş, B. Yuksel, S. Tok, H. Hatipoglu, F. Aslan, Heterotopic pregnancy identified in the postpartum period, *Int. J. Gynaecol. Obstet.* 130 (3) (2015) 287–288.
- [9] Y. Yu, W. Xu, Z. Xie, Q. Huang, S. Li, Management and outcome of 25 heterotopic pregnancies in Zhejiang, China, *Eur. J. Obstet. Gynecol. Reprod. Biol.* 180 (2014) 157–161.
- [10] M.S. Kamath, T.K. Aleyamma, K. Muthukumar, R.M. Kumar, K. George, A rare case report: ovarian heterotopic pregnancy after in vitro fertilization, *Fertil. Steril.* 94 (5) (2010) e9–11, 1910.
- [11] Y. Xu, Y. Lu, H. Chen, D. Li, J. Zhang, L. Zheng, Heterotopic pregnancy after in vitro fertilization and embryo transfer after bilateral total salpingectomy/tubal ligation: case report and literature review, *J. Minim. Invasive Gynecol.* 23 (3) (2016) 338–345.
- [12] A.J. Chan, L.B. Day, R. Vairavanathan, Tale of 2 pregnancies: heterotopic pregnancy in a spontaneous cycle, *Can. Fam. Physician* 62 (7) (2016) 565–567.
- [13] V. Mihmanli, A. Kilickaya, N. Cetiinkaya, G. Karahisar, H. Uctas, Spontaneous heterotopic pregnancy presenting with hemoperitoneum, *J. Emerg. Med.* 50 (1) (2016) 44–46.
- [14] Q. Shehab, H. Kamali, S. Glew, Ruptured heterotopic tube secondary to a spontaneous heterotopic pregnancy in a parous woman with a previous vaginal delivery and history of rare renal anomaly, *J. Obstet. Gynaecol.* 36 (4) (2016) 538–539.
- [15] M. Ezzati, A.A. Shamshirsaz, S. Haeri, Undiagnosed heterotopic pregnancy, maternal hemorrhagic shock, and ischemic stroke in the intrauterine fetus, *Prenat. Diagn.* 35 (9) (2015) 926–927.
- [16] E. Ikechukwu, M. Adeleni, Heterotopic pregnancy with live infant, *Ann. Afr. Med.* 12 (1) (2013) 43–45.
- [17] W. Dendas, J.C. Schobbens, G. Mestdagh, L. Meylaerts, G. Verswijvel, C. Van Holsbeke, Management and outcome of heterotopic interstitial pregnancy: case report and review of literature, *Ultrasound* 25 (3) (2017) 134–142.
- [18] N.C. Avitabile, N.L. Kaban, S.D. Siadecki, R.E. Lewiss, T. Saul, Two cases of heterotopic pregnancy: review of the literature and sonographic diagnosis in the emergency department, *J. Ultrasound Med.* 34 (3) (2015) 527–530.
- [19] K. Talbot, R. Simpson, N. Price, S.R. Jackson, Heterotopic pregnancy, *J. Obstet. Gynaecol.* 31 (1) (2011) 7–12.
- [20] A. Nargund, S. Majumdar, I. Stokes, Heterotopic pregnancy after spontaneous conception, *J. Obstet. Gynaecol.* 33 (4) (2013) 425.