

Biologically Augmented Quadriceps Tendon Autograft With Platelet-Rich Plasma for Anterior Cruciate Ligament Reconstruction



Jorge Chahla, M.D., Ph.D., Mark E. Cinque, M.D., and Bert R. Mandelbaum, M.D., D.H.L., (hon.)

Abstract: Anterior cruciate ligament (ACL) reconstruction is one of the most common procedures studied in the orthopaedic literature. In this regard, graft preparation is a key factor for successful outcomes. Although current methods to reconstruct the ACL are generally perceived to be successful, recent studies indicate that normal structure and function of the knee are fully restored in less than half of the patients. Therefore, biologically augmenting these scaffolds could provide a potential solution for improving healing times and biomechanical properties of the graft. The purpose of this Technical Note is to describe our preferred technique for an ACL graft preparation (quadriceps tendon) augmented with platelet-rich plasma.

Although anterior cruciate ligament (ACL) reconstruction (ACLR) is the 6th most common orthopaedic procedure performed in the United States, with over 100,000 ACLRs each year,¹ few advances have been made to reduce the healing time of the ACL graft and the subsequent development of degenerative joint disease.²⁻⁵ Unlike total joint replacements where rehabilitation has dramatically improved, allowing arthroplasty to become an outpatient surgery,⁶ return to activities after an ACLR have progressively increased to reduce failure rates (from 6 months to 1 year postoperatively).⁷ Moreover, ACLR quantitative imaging studies have shown that knee homeostasis is not reestablished until 2 years after surgery.⁸ In addition, 1 in 4 young athletic patients who sustain an ACL injury and return to high-risk sports have been reported

to sustain another ACL injury early in the return-to-play period.⁹

Disruption of the ACL leads to altered knee joint function and significantly increases the risk for knee osteoarthritis (OA), with 60% to 90% of patients demonstrating evidence of knee OA 10 years after ACLR.¹⁰⁻¹⁵ While current methods to reconstruct the ACL are generally perceived to be successful, a recent meta-analysis study indicated that normal structure and function of the knee is fully restored in only 37% of patients.¹⁶ More concerning is that ACLRs do not reduce the risk of OA, since 42% to 90% have radiographic evidence of OA within 7 to 12 years after ACL surgery.¹⁷⁻²² For the above-mentioned reasons, there is a critical need to determine a faster and more effective approach of healing the ACL graft after reconstruction.

Although several graft preparation techniques have been reported, the body of literature regarding graft augmentation with platelet-rich plasma (PRP) is limited. Therefore, the purpose of this Technical Note is to describe our preferred technique for an ACL graft preparation (quadriceps tendon) augmented with PRP. This Technical Note provides important pearls for performing a reproducible biologically augmented quadriceps tendon graft.

Technique

The advantages and disadvantages of the quadriceps tendon autograft are presented in [Table 1](#), and a step-by-step approach with pearls for each part of the

From the Cedars Sinai Kerlan Jobe Institute (J.C., B.R.M.), Santa Monica, California; and Steadman Philippon Research Institute (M.E.C.), Vail, Colorado, U.S.A.

The authors report the following potential conflicts of interest or sources of funding: B.R.M is a paid consultant for Arthrex, Deputy, Exactech, and Regen Biologics. Full ICMJE author disclosure forms are available for this article online, as [supplementary material](#).

Received April 30, 2018; accepted June 26, 2018.

Address correspondence to Jorge Chahla, M.D., Ph.D., 2020 Santa Monica Blvd, Ste 400, Santa Monica, CA 90404, U.S.A. E-mail: jachahla@msn.com

© 2018 by the Arthroscopy Association of North America. Published by Elsevier. This is an open access article under the CC BY-NC-ND license (<http://creativecommons.org/licenses/by-nc-nd/4.0/>).

2212-6287/18527

<https://doi.org/10.1016/j.eats.2018.06.011>

Table 1. Advantages and Disadvantages of Quadriceps Tendon-Bone Autograft

Advantages	Disadvantages
<ul style="list-style-type: none"> • Less harvest site morbidity compared with patella tendon autograft. • Harvest of quadriceps tendon allows for larger graft cross-sectional area. • Avoids disruption of extensor mechanism. 	<ul style="list-style-type: none"> • Potential for suprapatellar pouch injury during quad tendon harvest. • Insufficient graft strength can occur if graft is not properly tensioned. • Can further weaken quadriceps strength in patient with quad strength deficiency.

procedure is presented in [Table 2](#). A graft preparation case example is demonstrated in [Video 1](#).

Patient Positioning and Anesthesia

The patient is placed in the supine position on the operating table. After induction of general anesthesia, a bilateral knee examination is performed to evaluate for any concurrent ligamentous instability and to assess range of motion. A well-padded high-thigh tourniquet is subsequently placed on the operative leg. A small bump can be placed underneath the knee to maintain 20° to 30° of flexion. After the approach has been completed and before harvesting the quadriceps, the distal aspect of the table can be dropped to reach 90° of knee flexion.

Graft Harvest

With the knee flexed to 90°, an approximately 3 cm long longitudinal incision is made centered on the superior pole of the patella ([Fig 1](#)). Dissection is carried through the subcutaneous tissue to the quadriceps tendon paratenon layer with a 15 mm blade. A quadriceps harvest knife (Arthrex, Naples, FL) is used for graft harvest. The blade limits the depth of the cut to 7 mm ([Fig 2](#)). A “push” technique is performed from the superior pole of the patella proximally to the quadriceps tendon. Then the graft length is measured with the marks provided in the handle, from the proximal pole of the patella. A no. 15 blade knife is used to connect the 2 proximal vertical incisions just off the superior pole of the patella. It is important to identify a thin fat layer underlying the quadriceps tendon to avoid capsular damage and therefore fluid leakage.

A bovie electrocautery is then used to mark the periosteum for a 20 mm long by 10 mm wide bone plug from the superior pole of the patella. A small oscillating saw (Stryker, Kalamazoo, MI) with a 10 mm wide blade is then used to score the cortex. Care must be taken to angle the longitudinal cuts 30° toward the midline of the patella, thereby forming a trapezoidal bone plug while avoiding damage to the patellar chondral surface and avoiding a patellar

fracture ([Fig 3](#)). Then the proximal horizontal cut is made by aiming the saw blade 45° obliquely toward either of the longitudinal cuts, to avoid cutting beyond the longitudinal cuts, thus reducing the risk of creating a potential stress riser in the patella. If sufficient saw cuts have been made, the patellar plug should be easily removable ([Figs 4 and 5](#)). The graft is then carefully removed from the knee and brought to the back table for preparation.

Graft Preparation

Although several preparation techniques are available, most of the grafts are prepared so that they easily pass through a 10 mm sizer. The patellar bone plug should be approximately 20 mm in length and 9 mm wide. It should be trimmed to the appropriate size using any combination of a saw, rongeur, and scissors. Excess bone is now saved for grafting into the bone plug harvest site and the tibial tunnel at the end of the case. A 1.6 mm K-wire is used to drill a hole in the cancellous part of the plug, parallel to the cortical surface, followed by shuttling a no. 1 PDS Suture (Ethicon, Somerville, NJ). The bone-tendon junction of the femoral bone plug is marked with a sterile marking pen, which will assist with graft orientation during graft passage and fixation. The tibial end of the graft is then whipstitched with the no. 2 FiberWire (Arthrex) with a Krackow locking technique ([Fig 6](#)).

Biological Augmentation of the Graft

The graft is then augmented with PRP at 7% (Angel System, Arthrex). The graft is first injected with calcium chloride and fibrin as a sealant on the surface and then intrasubstance throughout the tendon. Next, the PRP is injected in the same manner (surface and intratendon) with a 22 G needle. Lastly, the tendon is tubularized with a no. 2 FiberWire (Arthrex) to maintain the PRP within the tendon. For this purpose, continuous nonlocking sutures are used from the patellar bone block to the distal aspect of the graft ([Fig 7](#)). The graft is then resized to ensure that the volume of the graft is still acceptable for the size of the reconstruction tunnels.

Rehabilitation Protocol

Following surgery, patients were allowed to bear weight immediately and there were no restrictions on range of motion. Crutches were used as needed for the first 2 weeks postoperatively or until the patient was comfortable walking without assistance. A supervised physical therapy program was prescribed for 3 months following the concepts of periodization (range of motion, muscular endurance, strength, and power phases could be developed based on the patients’ return to play timelines). For the first phase, after suture removal (1 week), patients transitioned to a stationary

Table 2. Step-by-Step Process

Step	Pearls
Patient Positioning <ul style="list-style-type: none"> • Patient is placed in the supine position on the operating table. • Bilateral knee examination is performed to evaluate for any concurrent ligamentous instability and to assess range of motion. • A well-padded high-thigh tourniquet is subsequently placed on the operative leg, which is then placed into a leg holder. • The foot of the operating table is then lowered, allowing the surgeon to freely manipulate the knee as needed. 	<ul style="list-style-type: none"> • The leg holder should be placed proximal enough to allow for femoral tunnel guide pin passage, exposure for an inside-out meniscal repair, or other concomitant open procedures.
Graft Harvest <ul style="list-style-type: none"> • With the knee flexed to 90°, an approximately 3 cm long longitudinal incision is made centered on the superior pole of the patella. • A quadriceps harvest knife (Arthrex) is used for graft harvest. • Graft length is measured with the marks provided in the handle, from the proximal pole of the patella. • Bovie electrocautery is then used to mark the periosteum for a 20 mm long by 10 mm wide bone plug from the superior pole of the patella. • A small oscillating saw (Stryker) with a 10 mm wide blade is then used to score the cortex. • If sufficient saw cuts have been made, the patellar plug should be easily removable. The graft is then carefully removed from the knee and brought to the back table for preparation. 	<ul style="list-style-type: none"> • It is important to identify a thin fat layer underlying the quadriceps tendon to avoid capsular damage and therefore fluid leakage. • Care must be taken to angle the longitudinal cuts 30° toward the midline of the patella, thereby forming a trapezoidal bone plug while avoiding damage to the patellar chondral surface and avoiding a patellar fracture. • The proximal horizontal cut is made by aiming the saw blade 45° obliquely toward either of the longitudinal cuts, to avoid cutting beyond the longitudinal cuts, thus reducing the risk of creating a potential stress riser in the patella.
Graft Preparation <ul style="list-style-type: none"> • In general, grafts are prepared so that they easily pass through a 10 mm sizer. • The patellar bone plug should be approximately 20 mm in length and 9 mm wide. It should be trimmed to the appropriate size using any combination of a saw, rongeur, and scissors. • A 1.6 mm K-wire is used to drill a hole in the cancellous part of the plug, parallel to the cortical surface, followed by shuttling a suture to facilitate graft passage. • The bone-tendon junction of the femoral bone plug is marked with a sterile marking pen, which will assist with graft orientation during graft passage and fixation. • The tibial end of the graft is then whipstitched with the no. 2 FiberWire (Arthrex) with a Krackow locking technique. 	<ul style="list-style-type: none"> • Save excess bone for grafting into the bone plug harvest site and the tibial tunnel at the end of the case.
Biological Augmentation <ul style="list-style-type: none"> • Whole blood from the patient is placed into centrifuge tube. Care must be taken to not contaminate the sample during transfer from the 60 mL syringe to the centrifuge tube. For PRP to be augmented in a unilateral procedure, 60 mL of blood is drawn from a peripheral vein in the arm. • The whole blood sample is taken to the centrifuge and centrifuged in the Angel system set up at 7%. • The final preparation of 5-6 mL of diluted PRP is loaded automatically in a sterile syringe. • A syringe is then used to inject the calcium chloride and the PRP into the quad tendon graft 	<ul style="list-style-type: none"> • PRP should be injected along the entire length of the graft and should be injected into multiple depths of the graft. • The PRP should be activated with calcium chloride during the injection. Two milliliters of calcium chloride injected into the conical tube of final PRP product is sufficient for activation.

PRP, platelet-rich plasma.

bike. Starting with 10 minutes per day with no resistance and slowly increasing the time (by 1-2 minutes). Once the patient reached 30 minutes of continuous biking, he/she was allowed to increase resistance every 2 days.

The length of each subsequent phase depended on the time frame of the rehabilitation program

but was no shorter than 6 weeks. With range of motion restored, the treatment emphasized at week 8 shifted to the development of a muscular endurance base. A transition in training emphasis to the development of muscular strength was made at week 15 before muscular power developed at week 21.

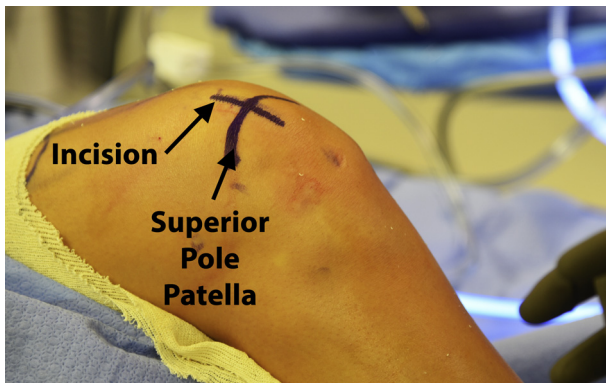


Fig 1. Following standard sterile patient prepping and draping, an approximately 2.5 cm incision centered over the superior pole of the patella should be marked (right knee).

Discussion

This Technical Note describes our preferred method for quadriceps tendon autografts, biologically augmented with PRP for ACLRs. Graft selection for ACLR is primarily based on surgeon experience and patient factors, such as gender, age, patient size, and activity level. Quadriceps, patellar tendon, and hamstring autografts for ACLR have been supported in the literature with good functional outcomes and low graft rupture rates.²³

In a recent systematic review by Kurz et al.²⁴ reporting on the credibility and quality of meta-analyses addressing graft choice in ACLR, the investigator reported limited credibility of some of the included studies, with a trend toward earlier studies having limited methodological “rigor.” More high-quality studies are needed to evaluate graft choice in ACLRs and improve surgical techniques, coupled with biological approaches to ultimately improve the return to activities of the patients. Historically, most knee

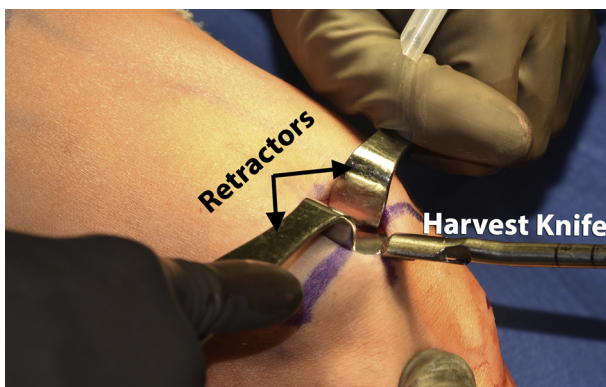


Fig 2. The surgical assistant should use 2 retractors (army navys) to allow the surgeon to visualize the trajectory of the quadriceps tendon on a right knee. The surgeon then uses the graft harvester to push proximally along the tendon until the desired graft length is achieved. Note that the blade limits the depth of the cut to 7 mm.

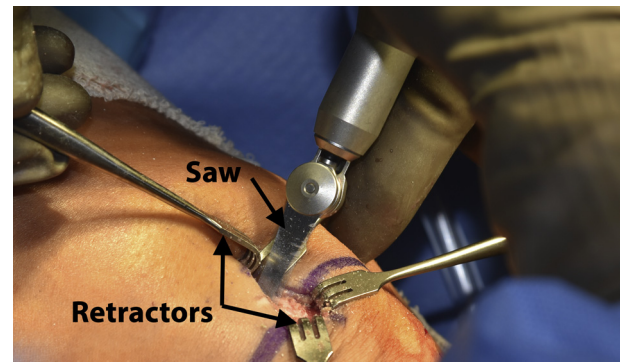


Fig 3. Senn retractors are used to retract along the inferior aspect of the inferior aspect of the right knee while the surgeon uses the 10 mm oscillating saw to make the initial graft harvesting cuts. Care must be taken to angle the longitudinal cuts 30° toward the midline of the patella, thereby forming a trapezoidal bone plug while avoiding damage to the patellar chondral surface and avoiding a patellar fracture. Then the proximal horizontal cut is made by aiming the saw blade 45° obliquely toward either of the longitudinal cuts, to avoid cutting beyond the longitudinal cuts, thus reducing the risk of creating a potential stress riser in the patella.

arthroscopists debated the indications and benefits of patellar tendon and hamstring autografts. In this regard, in a systematic review of 22 studies comparing ACLR grafts, patellar tendon autografts had superior rotational stability but a higher complication rate when compared with quadrupled hamstring autografts.²⁵ Webster et al.²⁶ performed a randomized controlled study evaluating outcomes following hamstring autograft versus patellar tendon autografts in ACLR. They reported no difference in graft failure rate; however, more patients who received patellar autografts were able to return to biweekly sport. Currently, a recent hype for the use of quadriceps tendon autograft has promoted further research into this graft. Belk et al.²⁷ reported that patients undergoing primary ACLR

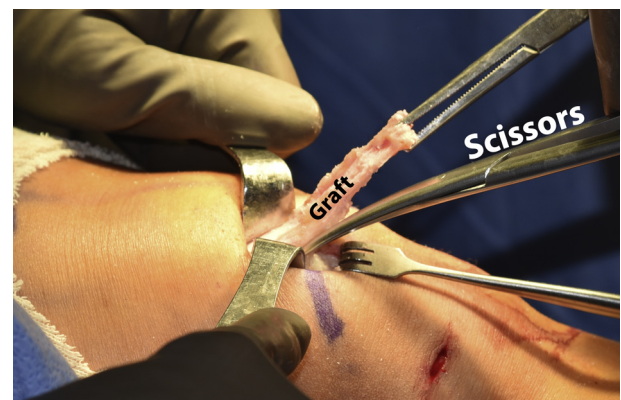


Fig 4. A Kocher clamp is used to pull tension on the graft to allow the surgeon to further free the proximal aspect of the graft from the medial and lateral aspects of the tendon. The desired length of the graft is usually 9 cm.

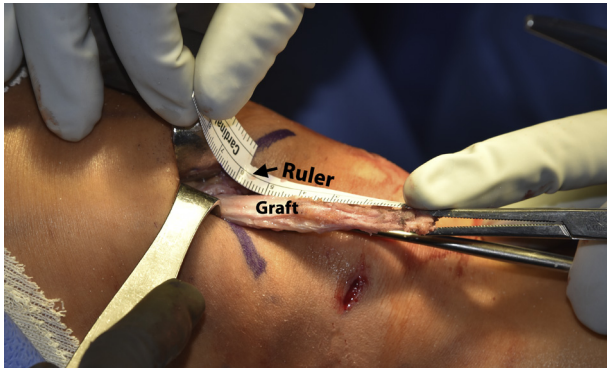


Fig 5. Prior to cutting the quad tendon graft from the remainder of the tendon, a sterile ruler should be used to ensure that the graft is of appropriate length (9 cm). If the graft is short it may not be able to be properly passed into the tibial and femoral tunnels.

with either a quadriceps tendon, bone–patellar tendon–bone, or hamstring autograft experience improvement in clinical outcomes. QT patients experienced less knee laxity postoperatively compared with HT patients, although no significant differences were found in graft failure rate between groups.

While current methods to reconstruct the ACL are generally perceived to be successful, a recent meta-analysis study indicated that normal structure and function of the knee is fully restored in only 37% of patients.¹⁶ More concerning is that ACLRs do not reduce the risk of OA, since 42% to 90% have radiographic evidence of OA within 7 to 12 years after ACL surgery.¹⁷⁻²² All these factors has led to an increased interest in discovering methods to augment the biological responsiveness of cartilage and ligamentous cells in ACL surgery, assuming that the success of ACLR depends heavily on biological processes that could improve the outcomes and ensure optimal

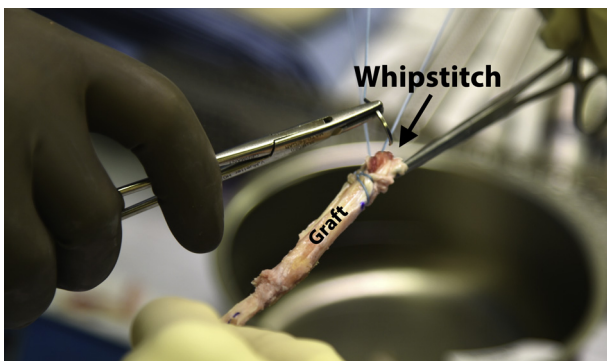


Fig 6. The bone-tendon junction of the femoral bone plug is marked with a sterile marking pen, which will assist with graft orientation during graft passage and fixation. The tibial end of the graft is then whipstitched with the no. 2 FiberWire (Arthrex) with a Krackow locking technique. Care should be taken to ensure the suture is well fixed into the graft so that proper tension can be applied during fixation.

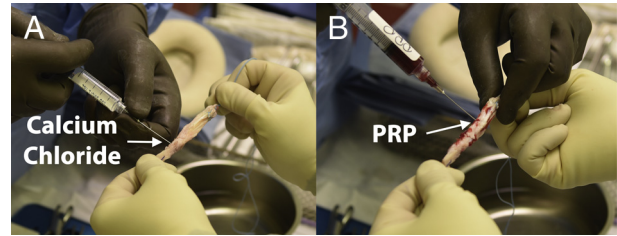


Fig 7. (A) Two milliliters of calcium chloride are first injected into the graft, which will activate the platelet-rich plasma. Calcium chloride should be injected along the entire length of the graft. (B) Five to six milliliters of platelet-rich plasma are injected along the entire length of the graft, at varying depths within the graft.

clinical results. One promising regenerative approach is the use of PRP,^{28,29} and therefore the body of literature is exponentially increasing to determine factors that can help improve the results of this procedure.³⁰⁻³²

PRP contains various growth factors, including transforming growth factor β -1, fibroblast growth factor-2, insulin-like growth factor, epidermal growth factor, platelet-derived growth factor (PDGF), and vascular endothelial growth factor, that have demonstrated positive effects on cell proliferation, cell migration, angiogenesis, and extracellular matrix production in numerous cell types both in vivo and in vitro models.³³ The primary cell in the ACL is the fibroblast. The fibroblast has receptors for many of the growth factors released by platelets, including PDGF, transforming growth factor β , and fibroblast growth factor. PDGF stimulates fibroblast growth, migration, and biosynthetic activity.³⁴ In light of such potential, the possibility of applying this biological product (which has all these growth factors) to enhance ACL reconstructive surgery appears attractive: PRP might not only promote a better and faster ligamentization of the graft used for ACLR and reduce the proinflammatory factors released immediately after surgery, but also might contribute to a better integration of the graft within the bone tunnels, thus avoiding their enlargement and failure over time.³⁵

Regarding ACL graft maturation, there is some promising evidence that the addition of PRP to the graft or tunnels could be a synergic factor in acquiring maturity more quickly than grafts with no PRP.³⁶⁻³⁸ Previous literature suggested a tendency toward this outcome, but the small sample size numbers probably made it difficult to obtain statistically significant differences between the groups.^{39,40} Radice et al.³⁷ performed a study using magnetic resonance imaging (MRI) and also found that the use of a $9\times$ platelet concentrate reduced the average time to achieve a normal MRI signal intensity value from 369 to 177 days. Qualitatively, it has been observed that grafts treated with concentrated platelets ($3\times$) showed higher

arthroscopic ratings for synovial coverage, graft width, and graft tension in the platelet-treated group when compared with the controls.³⁸ Histology revealed that the ligament maturity index⁴¹ was significantly greater in the platelet-treated grafts.³⁸ Other studies have found no differences between the grafts treated with platelets versus untreated grafts in any outcome measures.^{39,40,42} In an animal model it was also observed that PRP was able to produce superior biomechanical properties such as a higher tensile load and linear stiffness of the graft.³⁵ The majority of studies evaluating graft-bone healing have found no improvements in healing at the graft-bone junction.^{36,39,43} A review of the literature suggested that the use of platelet concentrate may improve the rate at which grafts achieve low-signal intensity on MRI or an improved ligament maturity index on histology³⁶⁻³⁸; however, none of them showed an improvement of clinical or patient-oriented outcome even at 2 years^{29,36,40} or significantly improved bone-tendon healing.^{36,39,43} Ventura et al.⁴⁴ reported a difference in MRI signal density in ACL grafts augmented with growth factors intraoperatively 6 months following hamstring autograft reconstruction compared with controls. Similarly, Vogrin et al.⁴⁵ suggested a positive effect of PRP application to ACL hamstring autografts on anterior laxity measures at 3 and 6 months following reconstruction.

In conclusion, augmented quadriceps tendon graft with PRP constitutes a safe procedure that has shown good short-term outcomes. Well randomized clinical trials, adequately powered with longer follow-up, are needed to determine the real effect of the difference of biologically augmented grafts for ACLR surgery.

References

- Garrett WE Jr, Swiontkowski MF, Weinstein JN, et al. Research Committee of the American Board of Orthopaedic Surgery. The orthopaedic forum: American Board of Orthopaedic Surgery Practice of the Orthopaedic Surgeon: Part-II, Certification examination case mix. *J Bone Joint Surg Am* 2006;88:660-667.
- Brown CH Jr, Carson EW. Revision anterior cruciate ligament surgery. *Clin Sports Med* 1999;18:109-171.
- Gottlob CA, Baker CL Jr, Pellissier JM, Colvin L. Cost effectiveness of anterior cruciate ligament reconstruction in young adults. *Clin Orthop Relat Res* 1999;272-282.
- Spindler KP, Wright RW. Anterior cruciate ligament tear. *N Engl J Med* 2008;359:2135-2142.
- Kim S, Bosque J, Meehan JP, Jamali A, Marder R. Increase in outpatient knee arthroscopy in the United States: A comparison of National Surveys of Ambulatory Surgery, 1996 and 2006. *J Bone Joint Surg Am* 2011;93:994-1000.
- Berger RA, Cross MB, Sanders S. Outpatient hip and knee replacement: The experience from the first 15 years. *Instr Course Lect* 2016;65:547-554.
- Ardern CL, Taylor NF, Feller JA, Whitehead TS, Webster KE. Sports participation 2 years after anterior cruciate ligament reconstruction in athletes who had not returned to sport at 1 year: A prospective follow-up of physical function and psychological factors in 122 athletes. *Am J Sports Med* 2015;43:848-856.
- Chu CR, Williams AA, West RV, et al. Quantitative magnetic resonance imaging UTE-T2* mapping of cartilage and meniscus healing after anatomic anterior cruciate ligament reconstruction. *Am J Sports Med* 2014;42:1847-1856.
- Wiggins AJ, Grandhi RK, Schneider DK, Stanfield D, Webster KE, Myer GD. Risk of secondary injury in younger athletes after anterior cruciate ligament reconstruction: A systematic review and meta-analysis. *Am J Sports Med* 2016;44:1861-1876.
- Kannus P, Järvinen M. Conservatively treated tears of the anterior cruciate ligament. Long-term results. *J Bone Joint Surg Am* 1987;69:1007-1012.
- McDaniel WJ, Dameron TB Jr. The untreated anterior cruciate ligament rupture. *Clin Orthop Relat Res* 1983;172:158-163.
- Neyret P, Donell ST, Dejour D, Dejour H. Partial meniscectomy and anterior cruciate ligament rupture in soccer players: A study with a minimum 20-year followup. *Am J Sports Med* 1993;21:455-460.
- Noyes FR, Mooar PA, Matthews DS, Butler DL. The symptomatic anterior cruciate-deficient knee. Part I: the long term functional disability in athletically active individuals. *J Bone Joint Surg Am* 1983;65:154-162.
- Sherman MF, Warren RF, Marshall JL, Savatsky GJ. A clinical and radiographical analysis of 127 anterior cruciate insufficient knees. *Clin Orthop Relat Res* 1988;227:229-237.
- Sommerlath K, Lyshom J, Gillquist J. The long-term course after treatment of acute anterior cruciate ligament ruptures: A 9 to 16 year followup. *Am J Sports Med* 1991;19:156-162.
- Biau DJ, Tournoux C, Katsahian S, Schranz P, Nizard R. ACL reconstruction: A meta-analysis of functional scores. *Clin Orthop Relat Res* 2007;458:180-187.
- Cohen M, Amaro JT, Ejnisman B, et al. Anterior cruciate ligament reconstruction after 10 to 15 years: Association between meniscectomy and osteoarthritis. *Arthroscopy* 2007;23:629-634.
- Fithian DC, Paxton EW, Stone ML, Luetzow WFCRP, Daniel DM. Prospective trial of a treatment algorithm for the management of the anterior cruciate ligament-injured knee. *Am J Sports Med* 2005;33:335-346.
- Jomha NM, Borton DC, Clingeffer AJ, Pinczewski LA. Long-term osteoarthritic changes in anterior cruciate ligament reconstructed knees. *Clin Orthop Relat Res* 1999:188-193.
- Kessler MA, Behrend H, Henz S, et al. Function, osteoarthritis and activity after ACL-rupture: 11 years follow-up results of conservative versus reconstructive treatment. *Knee Surg Sports Traumatol Arthrosc* 2008;16:442-448.
- Lohmander LS, Stenberg A, Englund M, Roos H. High prevalence of knee osteoarthritis, pain, and functional limitations in female soccer players twelve years after

- anterior cruciate ligament injury. *Arthritis Rheum* 2004;50:3145-3152.
22. Seon JK, Song EK, Park SJ. Osteoarthritis after anterior cruciate ligament reconstruction using a patellar tendon autograft. *Int Orthop* 2006;30:94-98.
 23. Gabler CM, Jacobs CA, Howard JS, Mattacola CG, Johnson DL. Comparison of graft failure rate between autografts placed via an anatomic anterior cruciate ligament reconstruction technique: A systematic review, meta-analysis, and meta-regression. *Am J Sports Med* 2016;44:1069-1079.
 24. Kurz A, Evaniew N, Yeung M, Samuelsson K, Peterson D, Ayeni OR. Credibility and quality of meta-analyses addressing graft choice in anterior cruciate ligament reconstruction: A systematic review. *Knee Surg Sports Traumatol Arthrosc* 2017;25:538-551.
 25. Xie X, Liu X, Chen Z, Yu Y, Peng S, Li Q. A meta-analysis of bone-patellar tendon-bone autograft versus four-strand hamstring tendon autograft for anterior cruciate ligament reconstruction. *Knee* 2015;22:100-110.
 26. Webster KE, Feller JA, Hartnett N, Leigh WB, Richmond AK. Comparison of patellar tendon and hamstring tendon anterior cruciate ligament reconstruction: A 15-year follow-up of a randomized controlled trial. *Am J Sports Med* 2016;44:83-90.
 27. Belk JW, Kraeutler MJ, Marshall HA, Goodrich JA, McCarty EC. Quadriceps tendon autograft for primary anterior cruciate ligament reconstruction: A systematic review of comparative studies with minimum two-year follow-up. *Arthroscopy* 2018;34:1699-1707.
 28. Sheth U, Simunovic N, Klein G, et al. Efficacy of autologous platelet-rich plasma use for orthopaedic indications: A meta-analysis. *J Bone Joint Surg Am* 2012;94:298-307.
 29. Vavken P, Sadoghi P, Murray MM. The effect of platelet concentrates on graft maturation and graft-bone interface healing in anterior cruciate ligament reconstruction in human patients: A systematic review of controlled trials. *Arthroscopy* 2011;27:1573-1583.
 30. Figueroa D, Figueroa F, Calvo R, Vaisman A, Ahumada X, Arellano S. Platelet-rich plasma use in anterior cruciate ligament surgery: Systematic review of the literature. *Arthroscopy* 2015;31:981-988.
 31. Hall MP, Band PA, Meislin RJ, Jazrawi LM, Cardone DA. Platelet-rich plasma: Current concepts and application in sports medicine. *J Am Acad Orthop Surg* 2009;17:602-608.
 32. Sanchez M, Anitua E, Orive G, Mujika I, Andia I. Platelet-rich therapies in the treatment of orthopaedic sport injuries. *Sports Med* 2009;39:345-354.
 33. Hutchinson ID, Rodeo SA, Perrone GS, Murray MM. Can platelet-rich plasma enhance anterior cruciate ligament and meniscal repair? *J Knee Surg* 2015;28:19-28.
 34. Molloy T, Wang Y, Murrell G. The roles of growth factors in tendon and ligament healing. *Sports Med* 2003;33:381-394.
 35. Andriolo L, Di Matteo B, Kon E, Filardo G, Venieri G, Marcacci M. PRP augmentation for ACL reconstruction. *Biomed Res Int* 2015;2015:371746.
 36. Orrego M, Larrain C, Rosales J, et al. Effects of platelet concentrate and a bone plug on the healing of hamstring tendons in a bone tunnel. *Arthroscopy* 2008;24:1373-1380.
 37. Radice F, Yanez R, Gutierrez V, Rosales J, Pinedo M, Coda S. Comparison of magnetic resonance imaging findings in anterior cruciate ligament grafts with and without autologous platelet-derived growth factors. *Arthroscopy* 2010;26:50-57.
 38. Sanchez M, Anitua E, Azofra J, Prado R, Muruzabal F, Andia I. Ligamentization of tendon grafts treated with an endogenous preparation rich in growth factors: Gross morphology and histology. *Arthroscopy* 2010;26:470-480.
 39. Figueroa D, Melean P, Calvo R, et al. Magnetic resonance imaging evaluation of the integration and maturation of semitendinosus-gracilis graft in anterior cruciate ligament reconstruction using autologous platelet concentrate. *Arthroscopy* 2010;26:1318-1325.
 40. Nin JR, Gasque GM, Azcarate AV, Beola JD, Gonzalez MH. Has platelet-rich plasma any role in anterior cruciate ligament allograft healing? *Arthroscopy* 2009;25:1206-1213.
 41. Murray MM, Spindler KP, Ballard P, Welch TP, Zurakowski D, Nannery LB. Enhanced histologic repair in a central wound in the anterior cruciate ligament with a collagen-platelet-rich plasma scaffold. *J Orthop Res* 2007;25:1007-1017.
 42. Vogrin M, Ruppreht M, Dinevski D, et al. Effects of a platelet gel on early graft revascularization after anterior cruciate ligament reconstruction: A prospective, randomized, double-blind, clinical trial. *Eur Surg Res* 2010;45:77-85.
 43. Silva A, Sampaio R. Anatomic ACL reconstruction: Does the platelet-rich plasma accelerate tendon healing? *Knee Surg Sports Traumatol Arthrosc* 2009;17:676-682.
 44. Ventura A, Terzaghi C, Borgo E, Verdoia C, Gallazzi M, Failoni S. Use of growth factors in ACL surgery: Preliminary study. *J Orthop Traumatol* 2005;6:76-79.
 45. Vogrin M, Ruppreht M, Crnjac A, Dinevski D, Krajnc Z, Recnik G. The effect of platelet-derived growth factors on knee stability after anterior cruciate ligament reconstruction: A prospective randomized clinical study. *Wien Klin Wochenschr* 2010;122:91-95 (suppl 2).