

# Efficacy and Versatility of Intraoral Monoplanar Distractors in the Correction of Extreme Mandibular Deformities and Severe Facial Asymmetries - A Retrospective Study

Priya Jeyaraj

Commanding Officer, Military Dental Centre (Gough Lines), Secunderabad, Telangana, India

## Abstract

**Introduction:** Distraction osteogenesis, has emerged as a revolutionary concept and an effective means to treat extensive craniomaxillofacial defects and malformations. In cases of mandibular distraction for patients with extreme acquired mandibular deformities, there is so far, no recorded literature on precise quantification and scientific estimation of the percentage of the efficacy of intraoral monoplanar distractors, for an objective evaluation of their effectiveness. The objective was to study the efficacy of intraoral mandibular monoplanar distractors in the correction of severe acquired mandibular deformities and gross facial asymmetries. To objectively evaluate their effectiveness by calculating the percentage of distraction achieved as against that aimed for, and to evaluate early and late complications encountered with their use. **Materials and Methods:** Five patients in the age group of 10–22 years, with extreme mandibular deformity and gross facial asymmetry secondary to longstanding temporomandibular joint (TMJ) ankylosis, were treated. Four patients had unilateral and one patient had bilateral TMJ ankylosis, with varying degrees of acquired mandibular hypoplasia, retrogenia, retrognathia, and asymmetry. They were managed by unilateral (3 patients) and bilateral (2 patients) mandibular distraction. **Results:** Maximum horizontal corpus and vertical Ramal distraction achieved was 19 mm and 17.6 mm, respectively. The percentage of the efficacy of the intraoral monoplanar distractors used in this study ranged from 65.38% to 109.09%. Severe mandibular deformities and facial asymmetries were successfully corrected in all five patients, with no major early or late complications encountered in any of them. Results achieved were stable with nil incidence of relapse. **Discussion:** Estimation of percentage of the efficacy of distraction achieved, helped in objectively evaluating the effectiveness of the intraoral mandibular distractors. A low complication rate and good esthetic and functional outcomes achieved in all the patients demonstrated the reliability of this treatment modality in the management of extreme mandibular deformities and severe facial asymmetries.

**Keywords:** Acquired mandibular hypoplasia, distraction osteogenesis, facial asymmetry, intraoral monoplanar mandibular distractors, mandibular deformity, temporomandibular joint ankylosis

## INTRODUCTION

Acquired mandibular hypoplasia, dentofacial deformity and gross facial asymmetry in the anteroposterior, transverse and vertical planes are devastating sequelae of longstanding temporomandibular joint (TMJ) ankylosis.<sup>[1]</sup> Associated deficiencies of the overlying soft tissues, compensatory disproportional growth of the opposite side, and severe functional deficits, further compound the problem.<sup>[2]</sup> Such deformities can have a profound psychosocial impact on an individual's life. Hence, their effective correction with the restoration of facial balance and symmetry, as well as the achievement of optimal

functional efficiency, are imperative for restoring quality of life to these patients.

“Distraction Osteogenesis” (DO) is an efficacious technique, directed at modulating *de novo* bone growth,<sup>[3]</sup> and involves

**Address for correspondence:** Dr. Priya Jeyaraj,  
Commanding Officer, Military Dental Centre (Gough Lines), Secunderabad,  
Telangana, India. E-mail: jeyarajpriya@yahoo.com

**Received:** 09-05-2020

**Revised:** 31-07-2020

**Accepted:** 21-08-2020

**Published:** 23-12-2020

This is an open access journal, and articles are distributed under the terms of the Creative Commons Attribution-NonCommercial-ShareAlike 4.0 License, which allows others to remix, tweak, and build upon the work non-commercially, as long as appropriate credit is given and the new creations are licensed under the identical terms.

**For reprints contact:** WKHLRPMedknow\_reprints@wolterskluwer.com

**How to cite this article:** Jeyaraj P. Efficacy and versatility of intraoral monoplanar distractors in the correction of extreme mandibular deformities and severe facial asymmetries - A retrospective study. *Ann Maxillofac Surg* 2020;10:381-96.

### Access this article online

Quick Response Code:



**Website:**  
www.amsjournal.com

**DOI:**  
10.4103/ams.ams\_166\_20

stimulation of the genetically inbuilt potency of deficient local tissues to increase in bulk to the desired dimensions, without having to resort to tissue transfers or grafting procedures.<sup>[4]</sup> It permits complete bone sculpting to meet with the three-dimensional structural, functional, and esthetic requirements.<sup>[5]</sup> It also produces a simultaneous increase in the bulk of the surrounding soft tissue envelope by the process of “distraction histogenesis.”<sup>[6]</sup> Since locally regenerated native bone is created along with appropriate neuromuscular re-adaptation and stimulation of the deficient functional matrix in the region, results achieved are far superior to those obtained by either skeletal surgery (such as mandibular osteotomy and advancement with or without interpositional grafts)<sup>[7]</sup> or soft tissue surgery, done independently or in combination.<sup>[8-11]</sup>

Miniaturized intraoral vertical and horizontal monoplanar mandibular distractors<sup>[12]</sup> have been widely employed to increase vertical Ramal height and linear corpus length, respectively, for correction of severe mandibular deformities and deficiencies.<sup>[13]</sup> Simultaneous increase of vertical as well as linear dimensions has been accomplished by using extraoral 3-dimensional (mutiplanar) distractors.<sup>[14]</sup>

As of now, there is no recorded literature on precise quantification and scientific estimation of the percentage of the efficacy of intraoral monoplanar distractors, for an objective evaluation of their effectiveness. Keeping in mind the numerous advantages of DO, this study was undertaken to assess and evaluate the percentage efficacy, utility, and value of intraoral monoplanar mandibular distractor devices in the correction of extreme mandibular deformities and severe facial asymmetries, developing secondary to TMJ ankylosis.

**Aim and objectives**

This study was aimed at evaluating the efficacy of intraoral monoplanar distractors (vertical and horizontal) in the correction of acquired mandibular deformities and facial asymmetries, secondary to long-standing TMJ ankylosis.

The objectives of the study were as follows:

- i. To evaluate the effectiveness of intraoral mandibular distractors in achieving the desired quantum of mandibular lengthening in horizontal/vertical planes, by calculating the percentage of distraction achieved as against that intended/aimed for
- ii. To examine and assess the intraoperative and postoperative (early and late) complications encountered with their use
- iii. To evaluate the relapse rate and assess the stability of distraction thus achieved.

**MATERIALS AND METHODS**

Five patients, comprising 2 males and 3 females [Table 1], between the ages of 10 and 22 years [Table 2], were included in this study. Of them, one had bilateral and the remaining four had unilateral TMJ ankylosis, with varying degrees of mandibular hypoplasia and facial asymmetry.

**Table 1: Gender distribution of the patients**

Total number of patients	Number of males	Number of females
5	2	3

**Table 2: Age distribution of the patients**

Age group (years)	Frequency (n-)	Gender and age distribution
0-10	1	1 female (10 years)
11-20	3	2 females (18 years, 14 years); 1 male (13 years)
21-30	1	1 male (22 years)

Following release of TMJ ankylosis, the mandibular hypoplasia and facial asymmetry were corrected in all the five patients using intraoral vertical/horizontal titanium monoplanar distractor devices [Figures 1-10]. The component parts of the distractors are depicted in [Figure 11]. Institutional Ethical Committee clearance was taken vide Institutional Ethical Committee letter number INDARM MDCGLSECBD 2019NDP01PGV AFMS, dated May 4, 2019.

**Patient selection criteria**

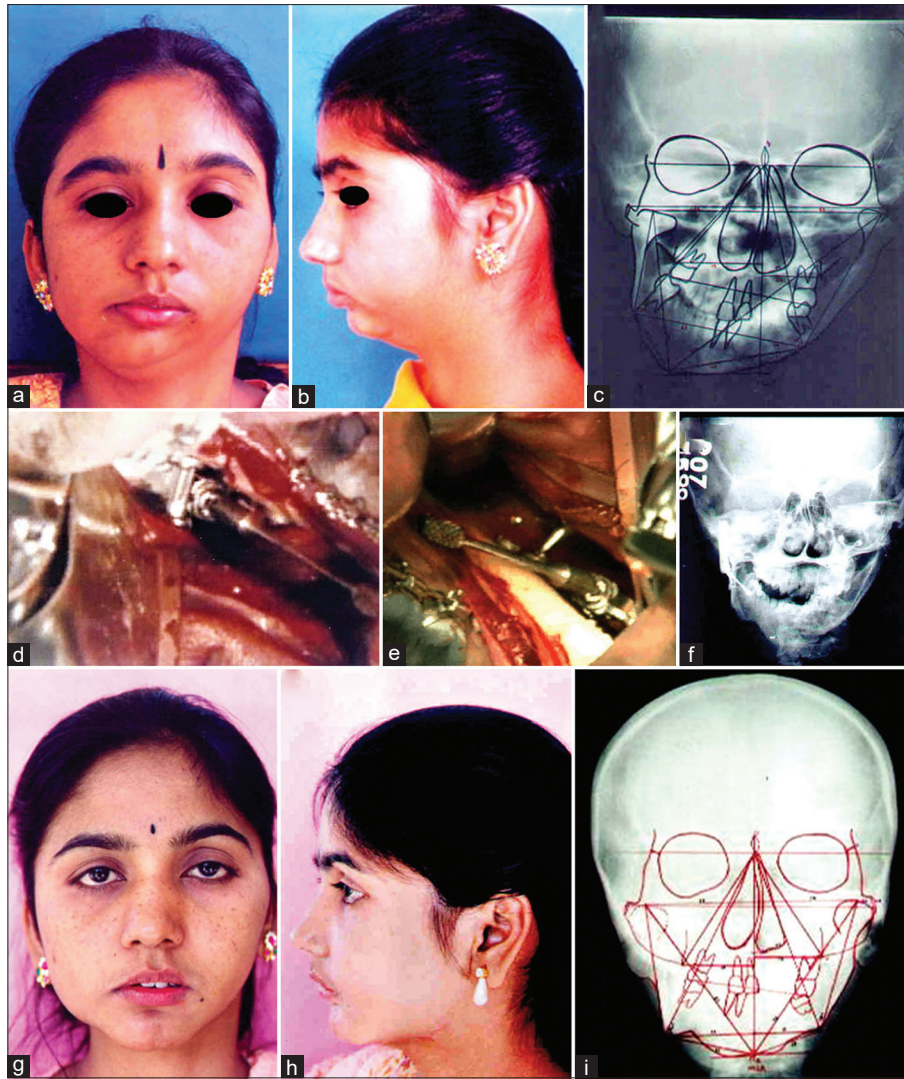
Patients in the age group of 10–25 years, who were well-motivated and psychologically prepared to undergo the surgical procedure and to strictly comply with the postoperative distraction regimen and scheduled device activation protocols, were selected. Patients with conditions such as osteomalacia and osteoporosis, and those with the insufficient quantity or inadequate quality of bone stock, which could compromise stable fixation or functioning of the distractor device, were excluded from the study. Medically compromised patients with coagulopathies, blood dyscrasias, metal allergies, neuropsychiatric and immunosuppressive disorders were also excluded.

**Treatment planning**

The mandibular deficiencies and deformities, with associated facial asymmetry in the five patients, were carefully examined and assessed. Appropriate treatment plan for each individual case was drawn up [Table 3], based on the evaluation of the front and profile photographs, orthopantomograms (OPGs), posteroanterior (PA), lateral cephalograms and noncontrast computed tomographic (NCCT) scans.

Planning of the distraction was carried out using articulated models and cephalometric tracings. Mock model surgeries and prediction tracings were employed to define the deformity, plan the osteotomy site, and decide the placement of the distractor device based on the required vector of bone lengthening. The probable outcome of treatment was analyzed and evaluated and any secondary procedure, if required, was planned as a back-up.

One of the female patients with unilateral TMJ ankylosis [Case 1; Figure 1], had already been treated elsewhere for release of the ankylosis by osteoarthrectomy, and an attempt had also been made to correct the retrogenia by horizontal



**Figure 1:** (Case 1) (a and b) 18-year-old patient with severe facial asymmetry, retrognathia and retrognathia. (c) Cephalometric tracing showing right-sided mandibular hypoplasia, deficient right ramal height, with Menton deviation to the right. (d and e) Vertical distractor placement at the right mandibular angle. (f) Radiograph with distractor *in situ*. (g and h) Improvement in facial symmetry and increased projection of lower facial third following distraction. (i) Successful correction of mandibular and facial asymmetry following right ramal distraction

augmentation genioplasty, albeit with unsatisfactory results. She was managed by unilateral vertical right Ramal distraction [Case 1; Table 3]. The remaining four patients had not received any form of treatment earlier, for either the TMJ ankylosis or for the mandibular deformity, before reporting to us (Cases 2-5).

Two of these patients underwent release of the TMJ ankylosis, followed by reconstruction of the joint with costochondral grafts (CCGs) in the same operative procedure (Cases 2 and 5). One year later, after ensuring successful take of the grafts, they were taken up for mandibular distraction [Figures 2, 3 and 10]. One of them underwent bilateral vertical Ramal distraction (Case 2), while the other (Case 5) underwent unilateral left corpus distraction.

The two remaining patients underwent release of TMJ ankylosis followed by Interpositional arthroplasty using

temporalis muscle pedicled flap (Case 3, 4). One of these patients (Case 4) underwent bilateral vertical as well as the horizontal distraction of the mandibular ramii and body in a staged manner; while the other (Case 3) underwent unilateral corpus distraction of the right mandibular body.

**Distractor vector planning**

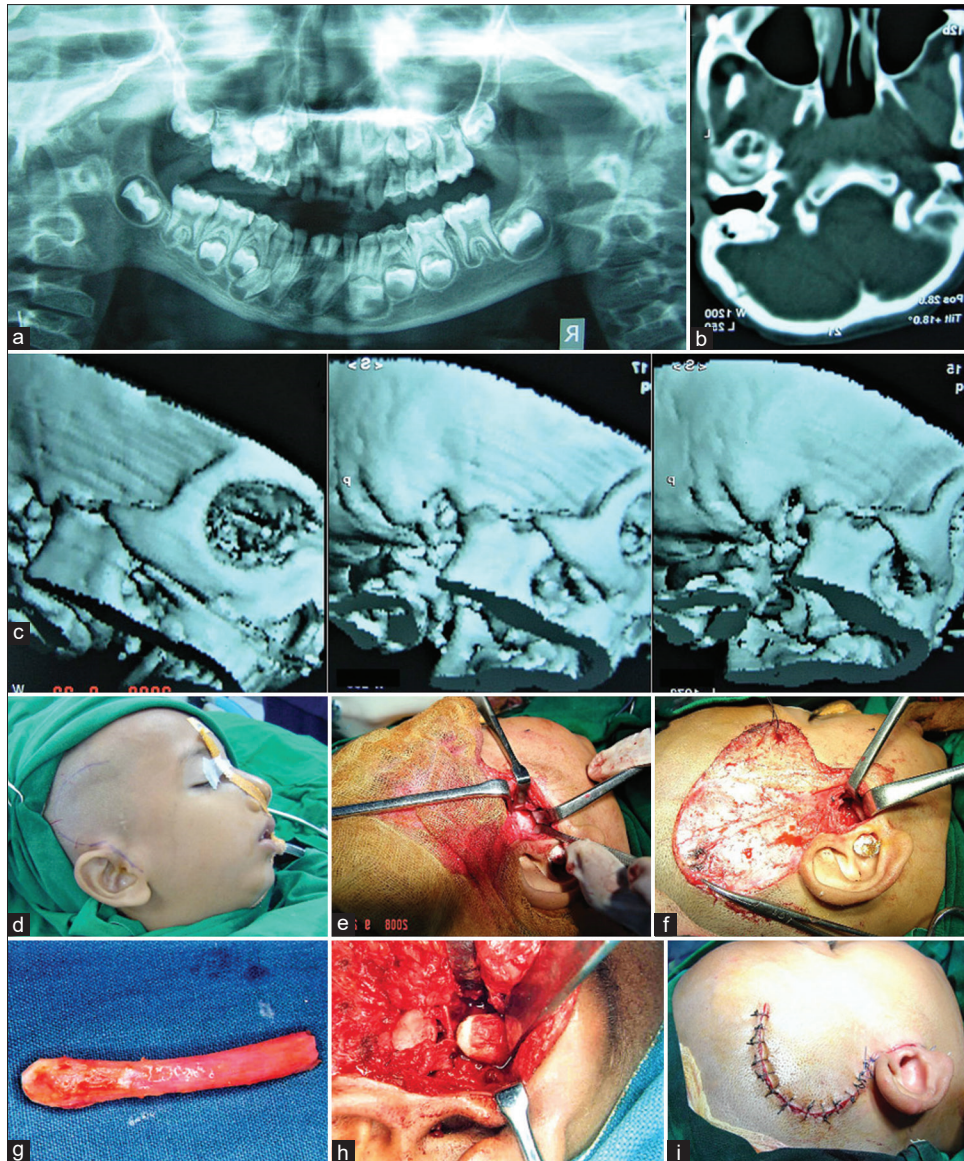
Depending on the desired direction that the distal bone segment was required to move during bone lengthening to achieve the desired correction of the mandibular deformity and asymmetry, the distraction vector was planned on a case-to-case basis [Table 3].

**Surgical phase**

*Preoperative preparation for each patient*

Routine blood and urine investigations, electrocardiogram, and chest radiographs were carried out for all patients. Blood demand was placed for fresh frozen plasma and packed red





**Figure 2:** (Case 2) (a) Orthopantomogram of a 12-year-old patient with right temporomandibular joint ankylosis. (b and c) Noncontrast computed tomographic showing bony ankylosis of the right temporomandibular joint. (d and e) Al Quayat and Bramley’s modified preauricular approach to gain access to the ankylosed joint. (f-i) Release of the ankylosis by osteoarthrectomy, followed by joint reconstruction using costochondral graft

blood cells for all patients and kept as a stand by in case of intraoperative requirement of blood transfusion.

Informed written consent was obtained from adult patients and from the parents of the minors.

*Management of temporomandibular joint ankylosis and planning of distraction*

As described in Table 3.

**Osteotomy and distractor placement**

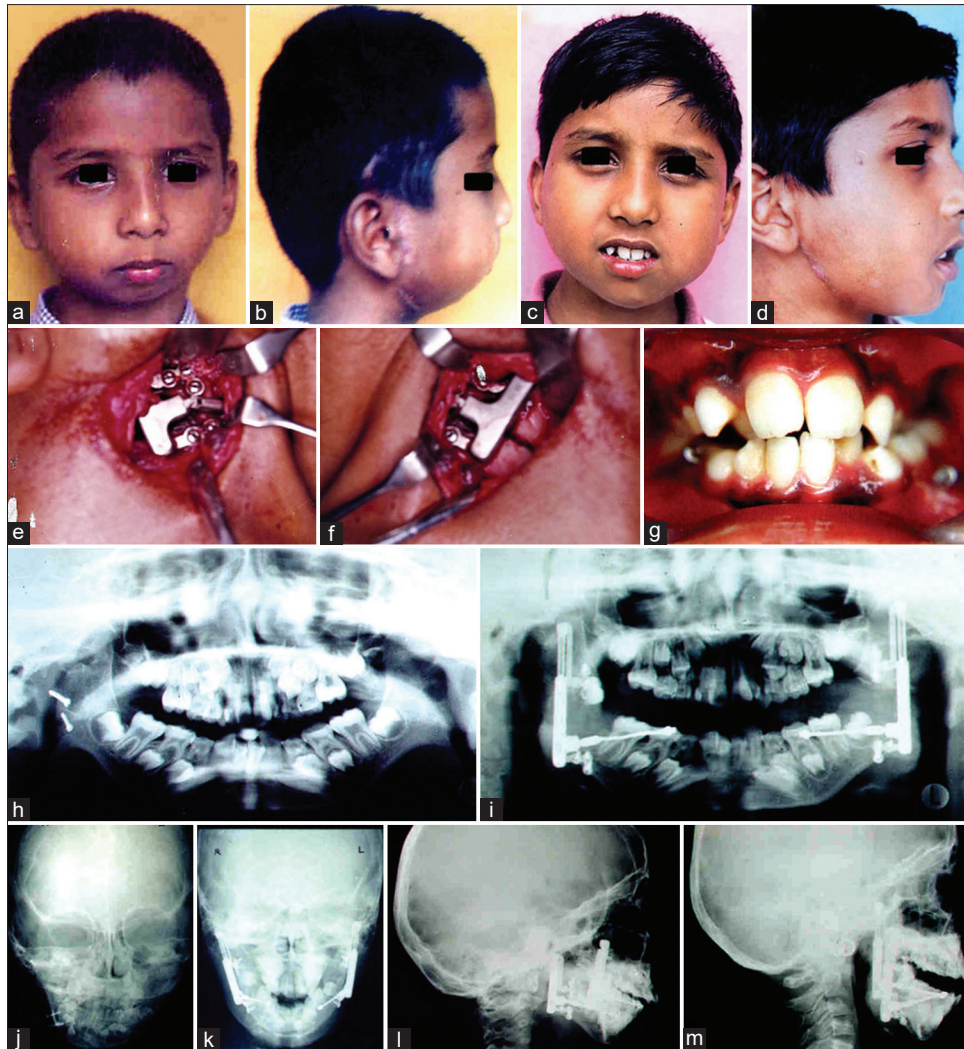
*Surgical approach*

An intraoral approach was employed for distractor placement in two patients (Cases 1 and 3), and the incision was placed in the lower buccal vestibule along the external oblique ridge, exposing the mandible in a subperiosteal

plane. Because of the rigid and hypoplastic soft tissues in the angle region of the mandible, screw fixation of the distractor was facilitated by transbuccal access [Figure 1d and e] (Cases 1, 3).

An extraoral retromandibular approach was employed in the remaining three patients (Cases 2, 4, 5). In the two patients in whom the CCG reconstruction of the TMJ had been carried out via a retromandibular approach (Cases 2, 5), the existing incision scar of graft placement was used to approach the region to place the distractor [Figure 3]. In Case 4, owing to the extreme mandibular hypoplasia, an intraoral approach was not feasible due to severely restricted access. In this case too, an extraoral approach was employed for distractor placement [Figures 7 and 8].





**Figure 3:** (Case 2) (a and b) Severely deficient lower third of face (c and d) Restoration of facial balance following bilateral vertical distraction of ramii. (e-g) Intraoral vertical distractors in place. (h) Orthopantomogram showing stunted mandibular ramii. (i) Successful increase in ramal height with well consolidated bone in distraction zones. (j) Preoperative Postero-anterior radiograph showing mandibular midline deviation to right. (k) Fully extended vertical distractors *in situ*, with successful correction of mandibular height and symmetry. (l and m) Lateral radiographs showing increased ramal heights achieved

**Osteotomy and positioning of the distractor**

The osteotomy cut was planned based on the vector of distraction to be achieved, and the distractor was positioned and temporarily fixed with monocortical screws [Figure 8c]. The osteotomy line was marked on the buccal cortex with a bur [Figure 8c], the distractor was then removed and osteotomy completed [Figures 4g, h and 8d], taking care to avoid damage to the inferior alveolar neurovascular bundle.

**Fixation of the distractor device**

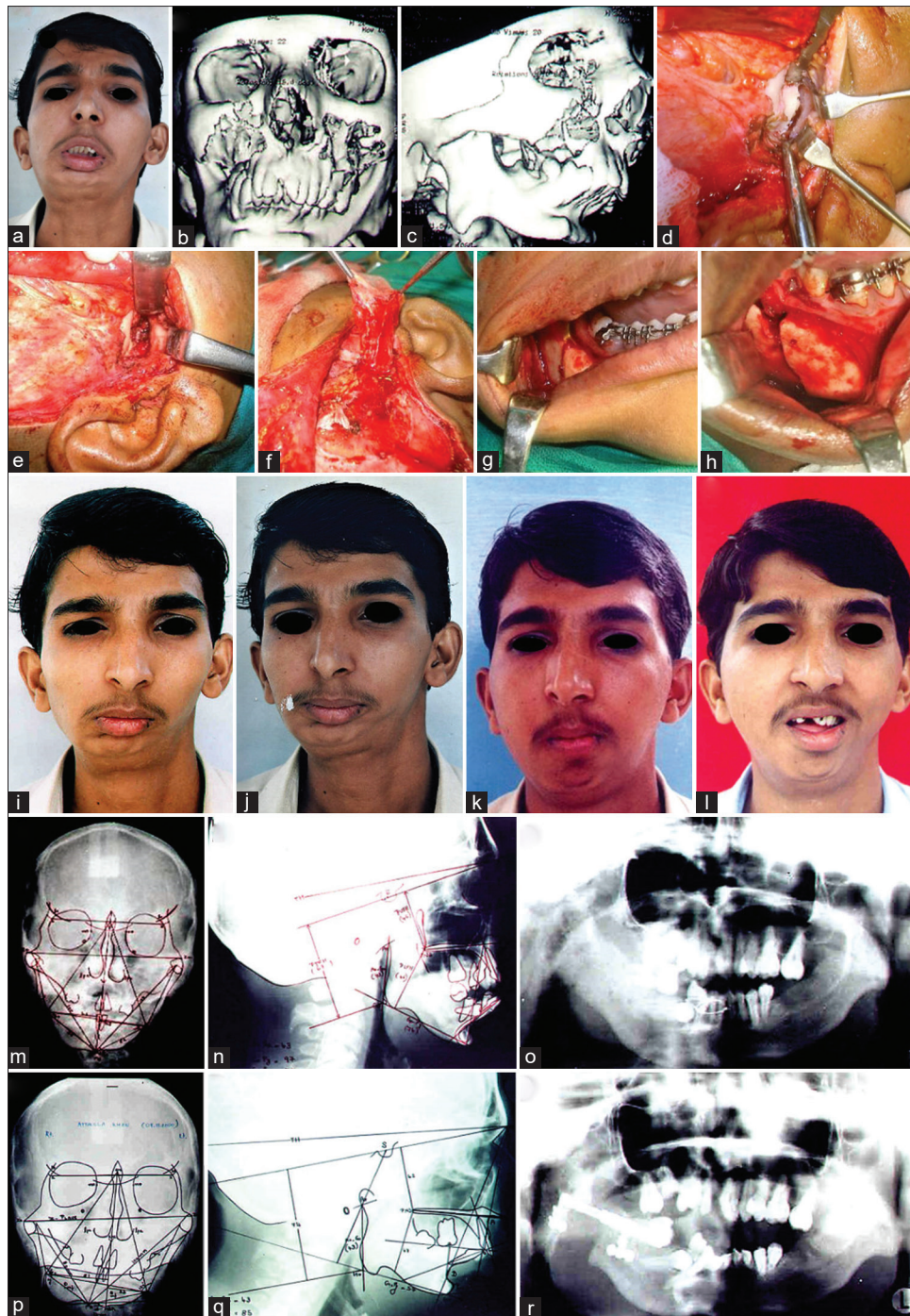
The distractor was then fixed at its predetermined position [Figures 1d, e, 3e, f, 7k, l and 8e, f], securely bridging the osteotomy site. The device activation was checked. The activation rod (in case of the vertical distractor) and the distraction cylinder (in case of the horizontal distractor) was positioned tension free in the buccal vestibule [Figure 1e, 3g and 5b] and the wound was closed in layers.

**Postoperative antibiotic regimen**

Inj cloxacillin 500 mg (intravenous [IV]) 6 hrly; Inj gentamycin 50 mg (IV) 12 hrly; Inj flayyl 500 mg (IV) 8 hrly; Inj Voveran 50 mg (IM) 12 hrly; Inj ondansetron 4 mg (slow IV infusion) SOS; Inj prednisolone 8 mg (IV) twelve hourly tapered down over 3 days.

**Distraction phase**

After a latency period of 5–7 days [Table 4], which allowed healing of the soft tissues and initial callus formation, distraction was carried out at a rate of 0.8–1.2 mm/day, at a rhythm of 2 or 3 activations of 0.4 mm each [Tables 4 and 5], until the predetermined, desired mandibular dimension was attained. The period of active distraction was followed by a consolidation period of 10–12 weeks, in which the distractor appliances were left in place, thus maintaining a state of neutral internal fixation [Tables 4 and 5], to allow maturation of the newly regenerated bone.



**Figure 4:** (Case 3) (a-c) Right temporomandibular joint ankylosis and severe mandibular deformity in a 22yr-old-patient. (d-f) Release of ankylosis. (g and h) Osteotomy for linear mandibular corpus distraction. (i-l) Comparison of predistraction (i and j), and post-distraction (k and l) frontal photographs. (m-o) Predistraction postero-anterior and lateral Cephalogram and orthopantomogram. (p-r) Post-distraction radiographs showing successful lengthening mandibular body and correction of facial asymmetry

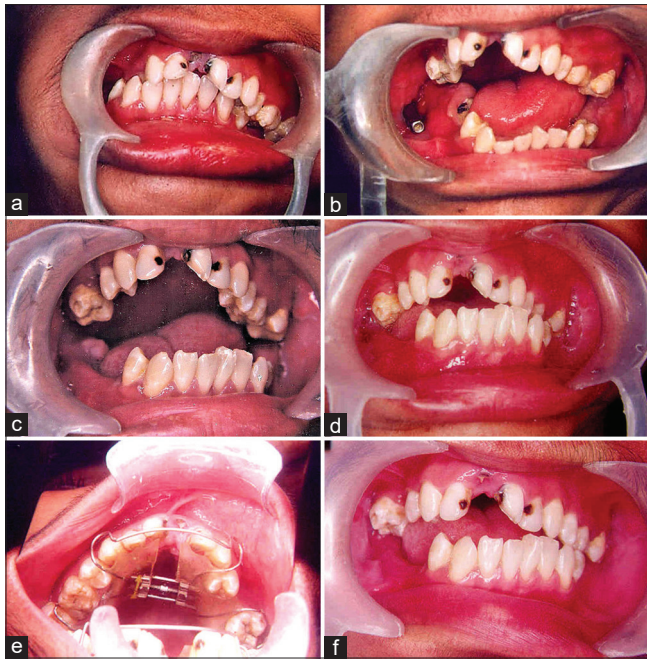#### Postdistraction evaluation

Postdistraction, 3-monthly front and profile photographs were observed to evaluate the correction of the mandibular deformity and facial asymmetry. Serial radiographs (PA, lateral cephalograms and OPGs) taken at 3, 6 and 9 months were used to assess the amount of bone elongation achieved and to evaluate the quality of the bony regenerate formed [Figures 3i and 4r].

#### RESULTS

The length of clinical follow up of patients in this study ranged from 10 to 22 months. There were nil soft tissue complications encountered, such as local inflammation, infection, wound dehiscence, hematoma, sialocele, or salivary fistula formation. There was no incidence of tooth damage, mobility, or loss in any patient. There were no neurological deficits observed,





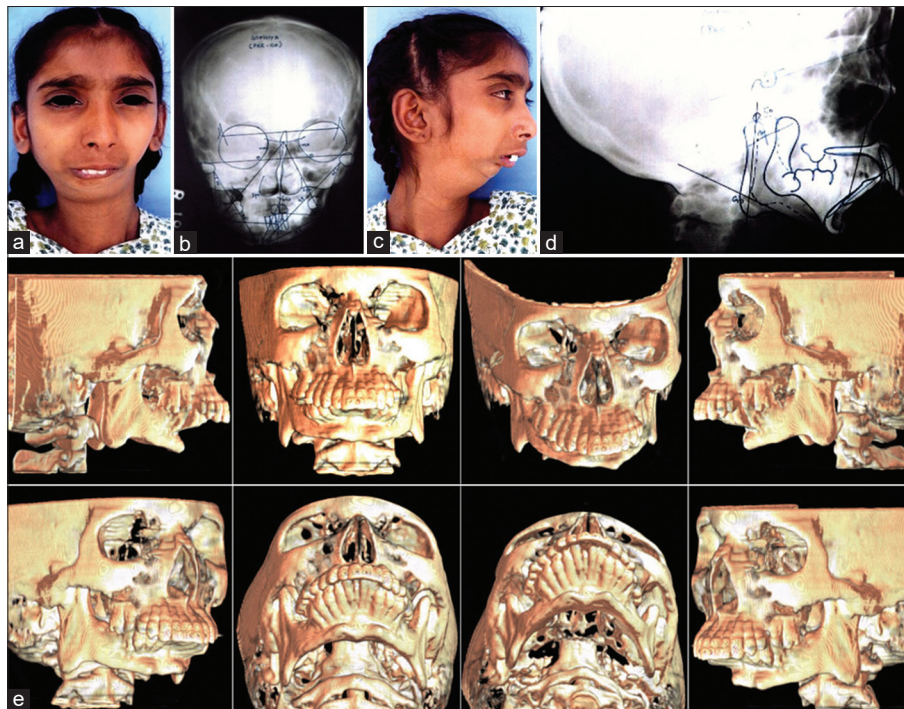**Figure 5:** (Case 3) (a) Preoperative occlusion, showing right-sided crossbite. (b) Status post- temporomandibular joint ankylosis release and with mandibular corpus distraction in progress. Maxillary arch narrow and V-shaped, and right corpus distraction was leading to a rotation-advancement of mandible towards the left. (c and d) Occlusion post-distraction, showing shift of mandibular arch to the left, resulting in a left-sided mandibular buccal crossbite. (e and f) Management of constricted maxillary arch by means of palatal expansion Hyrax appliance

involving either the inferior alveolar neurovascular bundle or branches of the facial nerve. There was no incidence of mechanical problems, such as distractor loosening, breakage or failure of its mechanism.

The regenerated bone in the distraction zone showed no evidence of either delayed or premature consolidation, and no incidence of its axial deviation, buckling, bending, bowing, deformation, or stress fracture. Concomitant expansion of the adjacent soft tissues took place, thereby effectively preventing any restriction to the distraction process and obviating relapse. There was also no development of TMJ dysfunction or re-ankylosis in any patient.

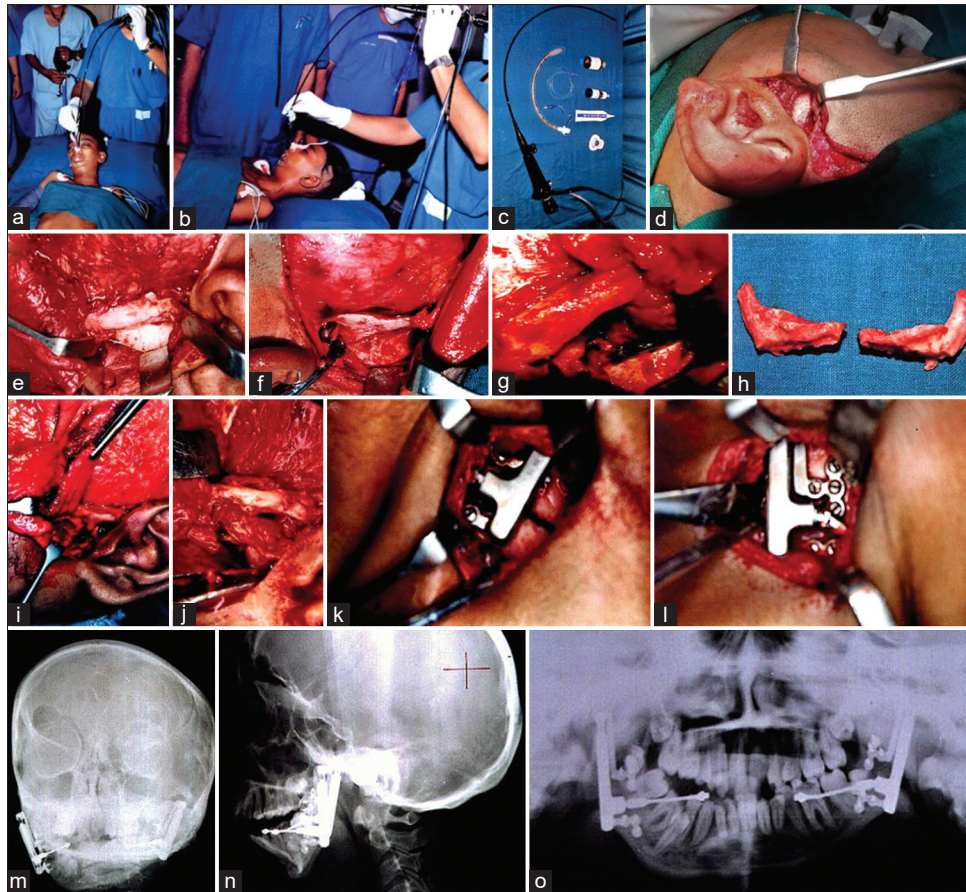
At the time of removal of the intraoral distractors, well consolidated dense bone was observed in the distraction zones [Figure 8a and b]. Serial radiographs taken postdistraction [Figures 3i and 4r], revealed different stages of callus mineralization and bone formation, evidenced as increasing radiographic density in the interval between the distracted segments. By the end of 6 months, there was seen a zone of uniform mineralization across the entire distraction zone, with formation of bony trabeculae within the bony regenerate [Figure 3i].

In the two bilateral mandibular distraction cases (Case 2, 4), after completion of the active distraction, both sides of the mandible continued to exhibit a normal and bilaterally symmetrical growth throughout the 22 months follow-up period. In the case of unilateral mandibular distraction (Case 5), normal growth of

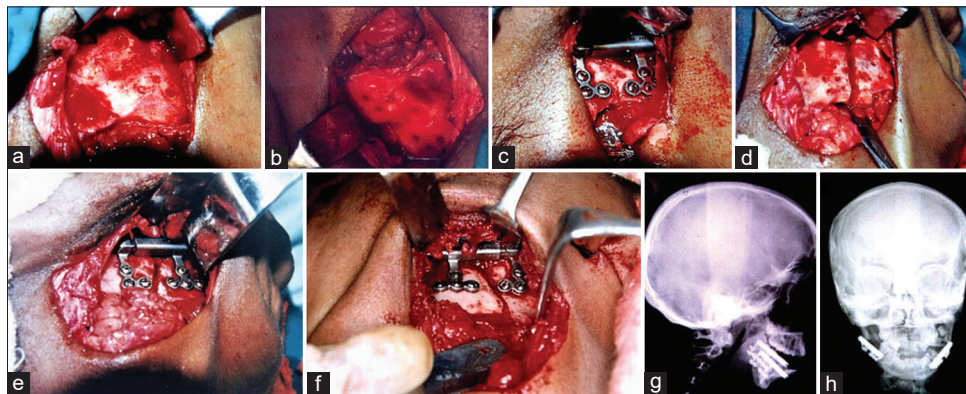


**Figure 6:** (Case 4) (a) Extreme facial deformity due to severely deficient lower facial third and deviation of mandibular midline to the right. (b) PA cephalogram showing severe mandibular deficiency and facial asymmetry, with menton shift to the right by 14mm. (c) 'Bird facies' with absent cervico-mandibular angle, retrognathia and retrogenia. (d) Lateral Cephalogram showing vertical and bilateral deficits of the mandibular ramii and body. (e) Noncontrast computed tomographic showing complete bilateral temporomandibular joint ankylosis, with a severely hypoplastic mandible, marked foreshortening of ascending ramii and body of mandible





**Figure 7:** (Case 4) (a-c) Fibreoptic assisted nasotracheal intubation. (d-j) Bilateral temporomandibular joint ankylosis release by osteoarthrectomy and temporalis muscle pedicled flap placement. (k and l) Vertical distractors placed bilaterally at angle regions, oriented parallel to the posterior border of the ramii, to achieve increase in vertical ramal height. (m-o) Radiographs showing the vertical distractors *in situ*, and vertical elongation of ramii in progress as evidenced by the partially extended distraction cylinders



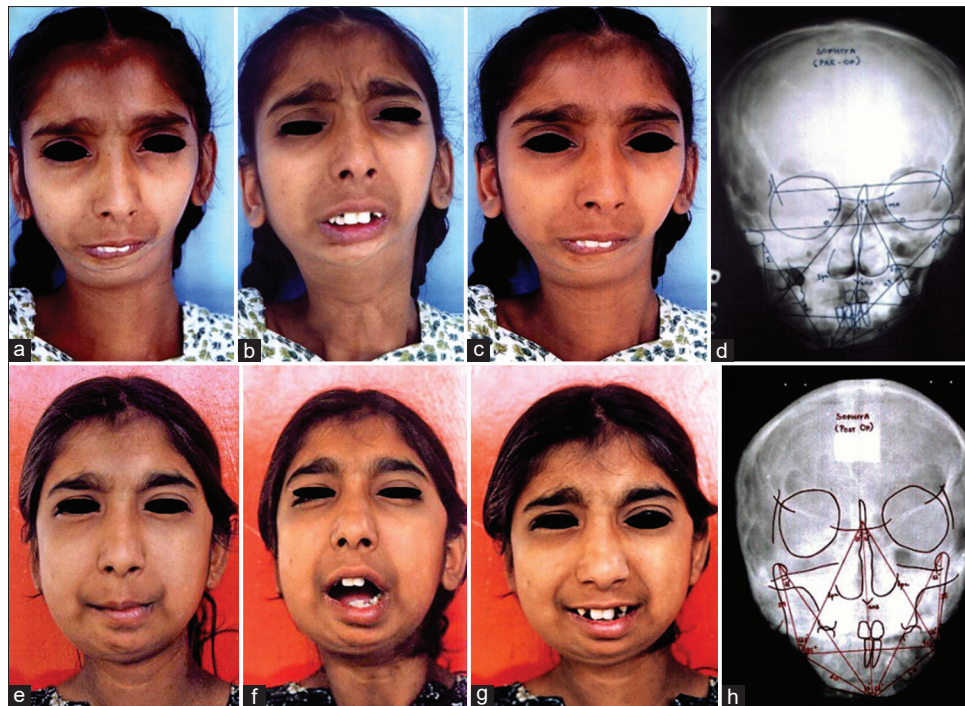**Figure 8:** (Case 4) (a and b) Surgical phase. Vertical distractors removed, distraction zones showing well consolidated bone. (c) Horizontal distractors placed at angle regions, oriented parallel to inferior border of mandible, to achieve linear corpus lengthening. Corticotomy line marked using surgical burs, with horizontal distractor temporarily in position. (d) Vertical Osteotomy completed, preserving Inferior alveolar neurovascular bundle. (e and f) Horizontal distractors fixed in pre-planned positions. (g and h) Orientation of horizontal distractors, bridging osteotomy gaps, as visible on radiographs

the distracted half of the mandible was observed, which was commensurate with the bone growth on the contralateral side, during the 18 months follow-up period.

The maximum linear and vertical distraction achieved was 19 mm and 17.6 mm, respectively [Tables 4 and 5]. The distraction planned for and achieved expressed as a

percentage of the predistraction dimension of bone in the axis of distraction, ranged between 5.33% and 100%, with a mean of 52.7% [Table 5]. The percentage of the efficacy of the distraction procedure using the intraoral mandibular distraction devices, that is, the distraction achieved expressed as a percentage of the preexisting deficit/amount of distraction





**Figure 9:** (Case 4) (a-d) Pretreatment frontal photographs and PA cephalogram demonstrating extreme mandibular deformity facial asymmetry. (e-g) 4 months' post-distraction photographs showing gratifying esthetic and functional improvement, following staged bilateral vertical and horizontal mandibular distraction. Improved projection of lower facial third, resulting in a pleasant countenance. (h) Postdistraction postero-anterior Cephalometric tracing showing successful correction of the severe mandibular deficiency and facial asymmetry

aimed for, ranged from 65.38% (Gonion to Pogonion distance) to 109.09% (Antigonial notch to Menton distance), with a mean of 88% [Tables 4 and 5], thus confirming that intraoral DO is an efficient method for correcting severe mandibular deformities of various dimensions [Table 5].

Complications encountered intraoperatively and during the early postoperative period:

- i. Anesthetic difficulties with airway access were encountered in two patients (Cases 3 and 4). None of the patients in this study needed to undergo tracheostomy, in spite of extremely restricted mouth opening due to the TMJ ankylosis. General anaesthesia could be successfully administered by means of fiberoptic assisted nasoendotracheal intubation [Figure 7a-c]
- ii. Minor complications such as intraoperative hemorrhage during the release of the ankylosis and distractor placement could be managed easily by identification, ligation and cauterization of vessels in the operative field
- iii. Although the pain was experienced by two patients during the postoperative distraction period, this did not interfere with the device activation protocol.

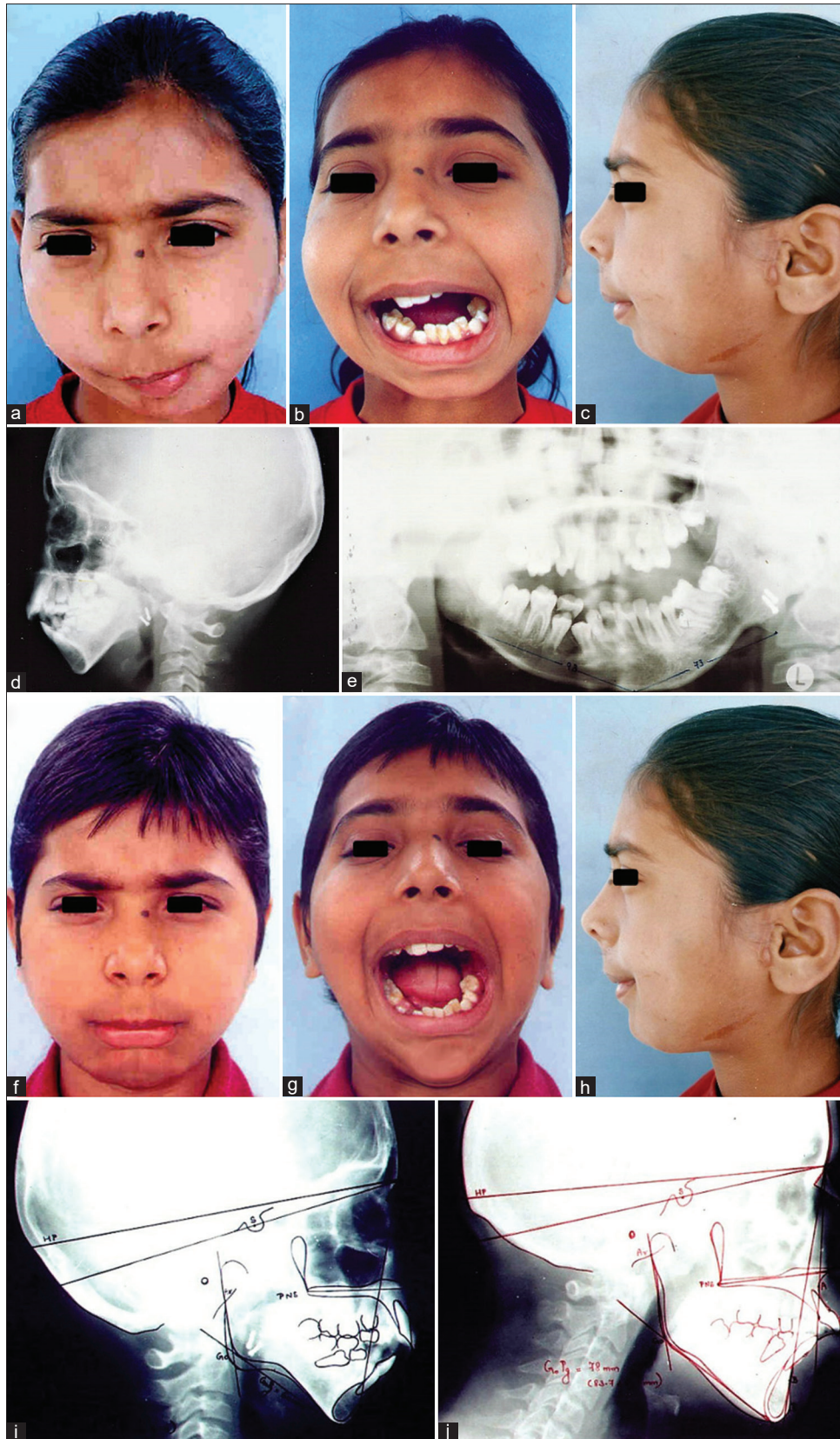Late postoperative complications encountered:

- i. The 22-year-old patient with long-standing right TMJ ankylosis (Case 3), who also suffered from a narrow, constricted V-shaped maxillary arch and a posterior buccal crossbite on the right [Figure 5a], underwent unilateral linear distraction of the right mandibular body [Figure 5b and c]. On completion of the linear lengthening of the

right body, the patient developed a buccal crossbite on the left, a premature posterior molar contact with anterior open bite [Figure 5d]. This complication was unrelated to the distraction procedure, but was due to the preexisting narrow maxillary arch [Figure 5a], which resulted in the deranged occlusion. Management of the constricted maxillary arch was undertaken by means of palatal expansion using a Hyrax appliance [Figure 5e]. Successful correction of the malocclusion was noted as maxillary expansion proceeded through postdistraction orthodontics [Figure 5f]

- ii. There was the formation of a hypertrophic scar in the submandibular region at the site of trocar insertion in one patient (Case 4), who had a tendency for developing keloids
- iii. In the patients who had undergone vertical distraction of the mandibular ramus, a posterior open bite developed, which was spontaneously corrected within a period of three to 4 months, by mandibular autorotation [Case 2; Figure 3m] and adaptive dental settling. These patients experienced some difficulty in chewing, and hence a soft diet was prescribed for this duration
- iv. Since no patient in this series could undergo presurgical orthodontics, owing to the TMJ ankylosis and practically nil mouth opening, mild degrees of occlusal disharmony and malocclusion were seen in four patients, which was then planned to be corrected by postsurgical orthodontics.

In 4 cases, excellent esthetic as well as functional results were achieved (Cases 1, 2, 4 and 5), [Table 3]. There was



**Figure 10:** (Case 5) (a-c) Facial asymmetry in a patient previously operated for left temporomandibular joint ankylosis, caused by deficient left mandibular body with deviation of the chin and mandibular midline to the left. (d and e) Radiographs showing foreshortening of left mandibular body by 20mm. (f-h) Successful correction of the mandibular midline shift, by unilateral horizontal distraction of left mandibular body by 20 mm. Improved facial balance and harmony achieved. (i and j) Comparison of the pre- and post-distraction Lateral Cephalogram showing successful elongation of the left mandibular body by 18 mm



**Table 3: Details of the craniomaxillofacial deformities of the patients; treatment plan implemented and outcome achieved for each patient**

Case number	Age (years)	Sex	Problem list	Treatment plan implemented	Treatment outcomes based on objective, subjective and functional assessment
1	18	Female	Was operated elsewhere a year ago for Rt TMJ ankylosis and Horizontal augmentation genioplasty. Presently exhibited reankylosis of the Rt TMJ, flattening of the Lt Maxilla, severe occlusal cant to the left; mandibular hypoplasia with foreshortening of the right ramus and deviation of the chin and mandibular midline to the right, causing a severe facial asymmetry	Lt Maxillary augmentation using Iliac crest corticocancellous bone graft; a simultaneous mandibular advancement as well as vertical elongation of the ramus on the right by Intraoral Vertical distractor placement at the right mandibular angle, in an oblique direction, to correct the mandibular deformity and facial asymmetry	Good
2	13	Male	Rt TMJ ankylosis, severe mandibular hypoplasia, shortened ramal height bilaterally, facial asymmetry with deviation of the chin to the right	Rt TMJ ankylosis release by osteoarthrectomy and joint reconstruction using Costochondral graft. 1 year allowed for successful take of the graft, followed by bilateral vertical distraction of the ascending mandibular ramii, to improve projection of the lower face and achieve facial symmetry and balance	Good
3	22	Male	Rt TMJ ankylosis, severe mandibular hypoplasia on the right, with shortening of the right mandibular ramus as well as body, Facial asymmetry caused by deviation of the chin and mandibular midline to the right, severely constricted maxillary arch	Release of the Rt TMJ ankylosis by osteoarthrectomy and Temporalis Muscle Pedicled (TMP) flap interpositional arthroplasty and bilateral coronoidectomy; horizontal corpus distraction of the right mandibular body; maxillary arch expansion using a Hyrax orthodontic appliance later	Fair
4	14	Female	Bilateral TMJ ankylosis, extreme micrognathia and mandibular hypoplasia affecting mandibular ascending ramii as well as body bilaterally, absence of projection of the lower third of the face in both vertical as well as anteroposterior planes, severe retrogenia, 'bird facies', absent cervico-mandibular angle, deviation of chin and mandibular midline to the right causing gross facial asymmetry; associated problems of Obstructive sleep apnea, loud snoring, daytime somnolence	Release of bilateral TMJ ankylosis by osteoarthrectomy and TMP flap interpositional arthroplasty and bilateral coronoidectomy; simultaneous bilateral intraoral vertical distractor placement during the same surgery as ankylosis release for carrying out vertical distraction of ascending ramii bilaterally. Second operative procedure carried out three months later for vertical distractor removal and intraoral horizontal distractor placement, for carrying out bilateral horizontal/linear distraction of the mandibular body	Good
5	10	Female	Lt TMJ ankylosis with severe facial asymmetry caused by a markedly hypoplastic mandibular body on the left, causing deviation of the chin and mandibular midline to the left	Release of the Lt TMJ ankylosis by osteoarthrectomy and joint reconstruction using a Costochondral graft; 1 year allowed for successful take of the graft, followed by a second surgical procedure for placement of an Intraoral horizontal mandibular distractor for elongation of the left body of the mandible to correct the mandibular deformity and facial asymmetry	Good

Lt=Left; Rt=Right

no requirement of any further unanticipated surgery or redo operation. In one case [Case 3, Table 3], most of the goals were achieved with satisfactory esthetic and functional outcomes [Figures 4 and 5]. However, there were a few complications, such as posterior molar gagging and an anterior open bite, and a unilateral crossbite, all of which could nevertheless be successfully corrected by postsurgical orthodontics [Figure 5].

## DISCUSSION

In this study, titanium intraoral monodirectional, vertical, and horizontal mandibular distractor devices were used in all five patients, with good esthetic and functional results. Stable distraction was achieved, with the maintenance of the postdistraction morphology and nil incidence of relapse in any case. The bone formed at the distraction site was found to be

**Table 4: Distraction protocol employed in the patients, for correction of the mandibular deficiency and deformity and establishment of facial symmetry**

Age and sex	Deficiency (mm)		Midline deviation (mm)	Distraction type and vector	Distraction rate (mm/day)	Distraction rhythm (times/day)	Duration of distraction (days)	Total Distraction achieved (mm)	Duration of neutral fixation (weeks)
	Ramus	Body							
Case 1 18 years/ female	(Rt) 12 mm	-	20 mm to the Rt	Unilateral Vertical Rt ramal distraction (vertical distractor placed at the angle in an oblique direction)	1.2 mm/day	3 times/day	10 days	11.6 mm	10 weeks
Case 2 13 years/ male	(Rt) 18 mm (Lt) 17.5 mm	-	-	Bilateral Vertical Ramal Distraction (Vertical distractors positioned on the ramus, perpendicular to the occlusal plane)	1.2 mm/day	3 times/day	15 days	(Rt) 17.6 mm (Lt) 17 mm	12 weeks
Case 3 22 years/ male	-	(Rt) 16 mm	14 mm to the Rt	Unilateral Horizontal Rt Corpus / Body Distraction (Horizontal distractor positioned parallel to the maxillary occlusal plane)	1.2 mm/day	3 times/day	12 days	17 mm	12 weeks
Case 4 14 years/ female	(Rt) 16 mm (Lt) 10 mm	(Rt) 12.4 mm (Lt) 9.8 mm	14 mm to the Rt	Bilateral Vertical Ramal and Horizontal/Linear Corpus/body distraction (vertical distractors positioned parallel to the posterior borders of the ascending ramii; Horizontal distractors positioned parallel to inferior borders of mandible)	Ramus (Rt) 1.2 mm/day Body (Rt) 1.2 mm/day Ramus (Lt) 0.8 mm/day Body (Lt) 1.2 mm/day	Ramus (Rt) 3 times/day Body (Rt) 3 times/day Ramus (Lt) 2 times/day Body (Lt) 3 times/day	Ramus (Rt) 13 days Body (Rt) 10 days Ramus (Lt) 13 days Body (Lt) 08 days	Ramus (Rt) 15 mm Body (Rt) 10.8 mm Ramus (Lt) 10 mm Body (Lt) 8 mm	12 weeks
Case 5 10 years/ female	-	(Lt) 14 mm	20 mm to the Lt	Unilateral horizontal distraction Lt corpus/ body distraction (horizontal distractor positioned parallel to inferior border of mandible)	1.2 mm/day	3 times/day	17 days	18 mm	12 weeks

Lt=Left; Rt=Right



**Table 5: Type and amount of distraction planned, effective distraction achieved, percentage of efficacy of distraction**

Case number; age and sex	Pre-distraction dimension of bone length in the axis of distraction			Expected bone length as per cranial base measurement and standard cephalometric analysis			Preexisting deficit			Post distraction dimension of bone length in the axis of distraction		
	PA Ceph	Lat Ceph	OPG	PA Ceph	Lat Ceph	OPG	PA Ceph	Lat Ceph	OPG	PA Ceph	Lat Ceph	OPG
Case 1. 18 year/ female (unilateral vertical distraction)	MSR-Me Shift=20 mm to Rt	Ar-GO=35 mm	RH=44 mm	MSR-Me Shift=0	Ar-GO=46.8±2.5 mm (F) Avg 47 mm	RH=56.3±3.9 mm Avg 56 mm	MSR-Me Shift=20 mm	Ar-GO=12 mm	RH=12 mm	MSR-Me Shift=2 mm to Rt	Ar-GO=46.6 mm	RH=55.6 mm
Case 2. 12 year/ male (bilateral vertical distraction)	Co-Ag R L 54 mm	Ar-Go R L 28 mm	RH 38 mm	Co-Ag=70 mm	Ar-Go=52±4.2 mm (M) Avg 52 mm	RH=56.3±3.9 mm Avg 56 mm	Co-Ag R L 16 mm	Ar-Go R L 24 mm	RH 18 mm	Co-Ag R L 67 mm	Ar-Go R L 50 mm	RH 55.5 mm
Case 3. 22 year/ male (unilateral horizontal distraction)	MSR-Me Shift=14 mm to Rt	Go-Pg=57 mm	Go-MP=90 mm	MSR-Me Shift=0	Go-Pg=83.7±4.6 mm (M) Avg 83 mm	Go-MP=100 mm	MSR-Me Shift=14 mm	Go-Pg=26 mm	Go-MP=10 mm	MSR-Me Shift=0.4 mm to Lt	Go-Pg=74 mm	Go-MP=100 mm
Case 4. 14 years/female (bilateral vertical and horizontal distraction)	MSR-Me Shift=14 mm to Rt	Ar-Go R L 23 mm	Go-MP R L 72 mm	MSR-Me Shift=0	Ar-Go=46.8±2.5 mm (F) Avg 44 mm	Go-MP=80 mm	MSR-Me Shift=14 mm	Ar-Go R L 21 mm	Go-MP R L 8 mm	MSR-Me Shift=0	Ar-Go R L 40 mm	Go-MP R L 79 mm
Case 5. 10 years/ female (unilateral horizontal distraction)	MSR-Me Shift=20 mm to Lt	Go-Pg=60 mm	Go-MP=73 mm	MSR-Me Shift=0	Go-Pg=74.3±5.8 mm (F) Avg 74 mm	Go-MP=93 mm	MSR-Me Shift=20 mm	Go-Pg=14 mm	Go-MP=20 mm	MSR-Me Shift=2 mm to Lt	Go-Pg=78 mm	Go-MP=92 mm
	Ag-Me=49 mm			Ag-Me=59 mm			Ag-Me=10 mm			Ag-Me=56 mm		

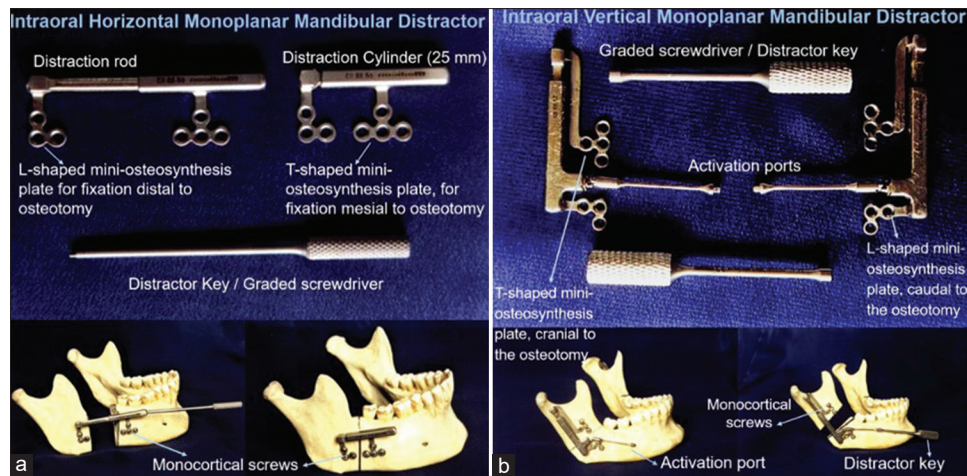
MSR=Mid Sagittal Reference; Me=Menton; Ar=Articulare; Go=Gonion; RH=Ramal Height; Co=Condylion; Ag=Antigonial notch; Pg=Pogonion; MP=Mandibular midpoint; PA Ceph=Postero-anterior Cephalogram; Lat Ceph=Lateral Cephalogram; OPG=Orthopantomogram; R=Right; L=Left

**Table 5. Contd...**

Case number; age and sex	Effective distraction achieved			Distraction length achieved as a percentage of Pre-distraction length			Percentage of efficacy of distraction		
	PA Ceph	Lat Ceph	OPG	PA Ceph	Lat Ceph	OPG	PA Ceph	Lat Ceph	OPG
Case 1. 18 year/ female (unilateral vertical distraction)	MSR-Me Shift=18 mm	Ar-Go=11.6 mm	RH=11.6 mm	MSR-Me Shift=90%	Ar-Go=33.14%	RH=26.36%	MSR-Me Shift=90%	Ar-Go=96.67%	RH=96.67%
Case 2. 12 year/ male (bilateral vertical distraction)	Co-Ag R 13 mm	Ar-Go L 20 mm	RH R 17 mm	Co-Ag R 24.07%	Ar-Go L 78.57%	RH R 46.32%	Co-Ag R 81.25%	Ar-Go L 91.66%	RH R 97.78%
Case 3. 22 year/ male (unilateral horizontal distraction)	MSR-Me Shift=14.4 mm Ag-Me=12 mm	Go- Pg=17 mm	Go- MP=10 mm	MSR-Me Shift=102.86% Ag-Me=85.71%	Go- Pg=29.82%	Go- MP=11.11%	MSR-Me Shift=102.86% Ag-Me=109.09%	Go- Pg=65.38%	Go- MP=100%
Case 4. 14 years/female (bilateral vertical and horizontal distraction)	MSR-Me Shift =14 mm	Ar-Go R 17 mm	Go- MP R 6 mm	MSR-Me Shift=100%	Ar-Go L 73.91	Go- MP R 8.33	MSR-Me Shift=%	Ar-Go L 80.95%	Go- MP R 75%
Case 5. 10 years/ female(unilateral horizontal distraction)	MSR-Me Shift=18 mm Ag-Me=10 mm	Go-Pg=18 mm	Go-MP=19 mm	MSR-Me Shift=90% Ag-Me =20.4%	Go-Pg=30%	Go-MP=26.02%	MSR-Me Shift=90% Ag-Me =100%	Go-Pg=128.57%	Go-MP=96%

MSR=Mid Sagittal Reference; Me=Menton; Ar=Articulare; Go=Gonion; RH=Ramal Height; Co=Condytion; Ag=Antigonal notch; Pg=Pogonion; MP=Mandibular midpoint; PA Ceph=Postero-anterior Cephalogram; Lat Ceph=Lateral Cephalogram; OPG=Orthopantomogram; R=Right; L=Left





**Figure 11:** Components of the intraoral monoplanar distraction devices (a) Horizontal distractors. (b) Vertical distractors

dense, well calcified and of adequate strength to withstand masticatory stresses, which corroborates with other studies.<sup>[15]</sup>

Following the release of TMJ ankylosis by osteoarthrectomy, reconstruction of the joint using costochondral graft is known to produce unpredictable growth of the affected side of the mandible.<sup>[16]</sup> In this study, two patients underwent CCG reconstruction following the release of the TMJ ankylosis (Cases 2 and 5), and both exhibited a persisting deficient growth and continued mandibular deformity and facial asymmetry, even 1 year later. DO carried both these patients successfully and effectively corrected the severe mandibular deformity and helped achieve ideal facial proportions, symmetry, and balance [Figures 3 and 10].

An additional benefit achieved following the distraction procedure, included successful correction of obstructive sleep apnoea (OSA), mouth breathing, snoring, daytime somnolence and lethargy, which was exhibited by the young patient with bilateral TMJ ankylosis and extreme mandibular hypoplasia and retrogenia [Case 4; Figure 6 and 9]. This corroborates with other studies where similar benefits were obtained.<sup>[17-19]</sup>

A wide spectrum of useful tools that are available to enhance the efficacy of the distraction procedure are stereolithographic models,<sup>[20]</sup> Three-dimensional cephalometric treatment planning,<sup>[20]</sup> geometric models, computer-aided surgery,<sup>[21]</sup> ultrasound and endoscopy. However, the key to success for each case of DO is careful treatment planning, which includes detailed PA and lateral cephalometric analyses, prediction tracings, analyses of the OPGs, and model analyses, and their incorporation into the operative procedure as well as the distraction protocol.

The results obtained in all patients in this study, were stable throughout the follow-up period with no evidence of relapse. This could partly be attributed to the concomitant stimulation and growth of the surrounding soft tissue envelope.<sup>[22]</sup>

In one patient, (Case 3) [Table 3], although the percentage of the efficacy of the linear corpus lengthening achieved by

the distraction procedure was found to be 65.3%, most of the clinical goals were achieved with a satisfactory esthetic and functional outcome [Figures 4 and 5]. In all the remaining four patients, the percentage of the efficacy of linear or vertical distraction ranged from 80% to 109.09%. Gratifying esthetic as well as functional results were achieved, as evidenced by improvement in facial symmetry and balance, improvement in occlusion and TMJ function, the achievement of satisfactory masticatory efficiency and elimination of associated problems such as OSA and excessive snoring. This confirmed the feasibility and efficacy of the technique of Intraoral mandibular DO in the correction of extreme facial deformities and asymmetries, including growth disorders and hypoplasia of the mandible, involving the ascending ramus or horizontal body or even both, developing secondary to TMJ ankylosis.

## CONCLUSION

In patients suffering from extreme facial asymmetry and severe functional debility due to acquired mandibular hypoplasia and deformity, secondary to long-standing TMJ ankylosis, DO provides an efficacious and reliable reconstructive option, with a low complication rate. The high percentage of the efficacy of intraoral monoplanar mandibular distractors allows for large skeletal advancements in both anteroposterior and vertical dimensions. The deficient bone can be successfully expanded in a controlled manner, in the desired direction and to the required dimension. This ensures an effective as well as a stable increase in the projection of the deficient and deformed lower third of the face, thus restoring ideal facial symmetry, proportions, and balance.

## Declaration of patient consent

The authors certify that they have obtained all appropriate patient consent forms. In the form the patients have given their consent for their images and other clinical information to be reported in the journal. The patients understand that their names and initials will not be published and due efforts will be made to conceal their identity, but anonymity cannot be guaranteed.

## Financial support and sponsorship

Nil.

## Conflicts of interest

There are no conflicts of interest.

## REFERENCES

- Douglas LR, Douglass JB, Smith PJ. Intraoral mandibular distraction osteogenesis in a patient with severe micrognathia secondary to TMJ ankylosis using a tooth and bone-anchored device (PIT device): A case report. *J Oral Maxillofac Surg* 2000;58:1429-33.
- Balaji SM, Balaji P. Comparison of midface advancement by external and internal craniofacial distraction osteogenesis. *Ann Maxillofac Surg* 2018;8:200-5.
- Ilizarov GA. Clinical application of the tension-stress effect for limb lengthening. *Clin Orthop Relat Res* 1990;8:26.
- Codivilla A. On the means of lengthening in the lower limbs, the muscles and tissues which are shortened through deformity. *Am J Orthop Surg* 1905;2:353-7.
- Ilizarov GA. Basic principles of transosseous compression and distraction osteosynthesis. *Ortop Travmatol Protez* 1971;32:7-15.
- Natu SS, Ali I, Alam S, Giri KY, Agarwal A, Kulkarni VA. The biology of distraction osteogenesis for correction of mandibular and craniomaxillofacial defects: A review. *Dent Res J (Isfahan)* 2014;11:16-26.
- Kohli S, Mohanty S, Singh S, Sandeep, Dabas J, Patel R. The autogenous graft versus transport distraction osteogenesis for reconstruction of the ramus-condyle unit: A prospective comparative study. *Int J Oral Maxillofac Surg* 2017;46:1106-17.
- Mehrotra D, Howladar D, Bhutia DP. Simultaneous maxillomandibular distraction osteogenesis in hemifacial microsomia: Report of 7 cases. *J Oral Biol Craniofac Res* 2017;7:147-52.
- Al-Moraissi EA, Ellis E 3<sup>rd</sup>. Bilateral sagittal split ramus osteotomy versus distraction osteogenesis for advancement of the retrognathic mandible. *J Oral Maxillofac Surg* 2015;73:1564-74.
- Rachmiel A, Even-Almos M, Aizenbud D. Treatment of maxillary cleft palate: Distraction osteogenesis vs. orthognathic surgery. *Ann Maxillofac Surg* 2012;2:127-30.
- Khan AI, Utreja A. Orthognathic surgery v/s distraction osteogenesis: A preliminary study. *Int J Contemporary Med Res* 2018;5:2454-63.
- McCarthy JG, Stelnicki EJ, Mehrara BJ, Longaker MT. Distraction osteogenesis of the craniofacial skeleton. *Plast Reconstr Surg* 2001;107:1812-27.
- Andrade N, Gandhewar T, Kalra R. Development and evolution of distraction devices: Use of indigenous appliances for distraction osteogenesis-an overview. *Ann Maxillofac Surg* 2011;1:58-65.
- Tharanon W, Sinn DP. Mandibular distraction osteogenesis with multidirectional extraoral distraction device in hemifacial microsomia patients: Three-dimensional treatment planning, prediction tracings, and case outcomes. *J Craniofac Surg* 1999;10:202-13.
- Dabas J, Mohanty S, Chaudhary Z, Rani A. Assessment of mandibular distraction regenerate using ultrasonography and cone beam computed tomography: A clinical study. *Craniofac Trauma Reconstr* 2016;9:69-75.
- Tahiri Y, Chang CS, Tuin J, Paliga JT, Lowe KM, Taylor JA, *et al*. Costochondral grafting in craniofacial microsomia. *Plast Reconstr Surg* 2015;135:530-41.
- Ul Haq ME. Distraction osteogenesis for the correction of severe mandibular deficiency. *Int J Oral Maxillofac Surg* 2017;46:150-1.
- Iatrou I, Theologie-Lygidakis N, Schoinohoriti O. Mandibular distraction osteogenesis for severe airway obstruction in Robin sequence. Case report. *J Craniofac Surg* 2010;38:431-5.
- Breik O, Tivey D, Umaphysivam K, Anderson P. Mandibular distraction osteogenesis for the management of upper airway obstruction in children with micrognathia: A systematic review. *Int J Oral Maxillofac Surg* 2016;45:769-82.
- Wang P, Zhang Z, Wang Y, Li X. The accuracy of virtual-surgical-planning-assisted treatment of hemifacial microsomia in adult patients: Distraction osteogenesis vs. orthognathic surgery. *Int J Oral Maxillofac Surg* 2019;48:341-6.
- Yu H, Wang B, Wang M, Wang X, Shen SG. Computer-assisted distraction osteogenesis in the treatment of hemifacial microsomia. *J Craniofac Surg* 2016;27:1539-42.
- Rossini G, Vinci B, Rizzo R, Pinho TM, Deregibus A. Mandibular distraction osteogenesis: A systematic review of stability and the effects on hard and soft tissues. *Int J Oral Maxillofac Surg* 2016;45:1438-44.