

Practicability confirmation by meta-analysis of intravitreal ranibizumab compared to photodynamic therapy to treat polypoidal choroidal vasculopathy

Ling Liu,¹ Jie Ma,² Ping Duan,¹ Yong Liu,¹ Zheng Qin Yin¹

¹Southwest Eye Hospital, Southwest Hospital, Key Laboratory of Visual Damage and Repair of Chongqing, Third Military Medical University, Chongqing, China; ²Schepens Eye Research Institute, Massachusetts Eye and Ear, Department of Ophthalmology, Harvard Medical School, Boston, MA

Purpose: The literatures show that photodynamic therapy (PDT) and intravitreal ranibizumab (IVR) have their own specific advantages in treating polypoidal choroidal vasculopathy (PCV). Using a meta-analysis, we want to provide some suggestions for the clinical application of the two treatments to PCV patients through a comparison of the functional outcomes in a follow-up period after administration.

Methods: A comprehensive literature search was performed using several databases to assemble the controlled trials of IVR and PDT. The program of RevMan version 5.0 was used to analyze the data. The effects of two treatments on PCV were evaluated by comparing weighted mean differences (WMDs) in the change of LogMar visual acuity, central retinal thickness (CRT), and the deterioration ratio for the proportions of patients with visual reductions from the baseline. Data with homogeneity among studies were analyzed using a fixed-effect meta-analysis model; otherwise, a random-effect model was applied to data with heterogeneity.

Results: Five studies are included covering 260 cases in total in this study. The outcomes of IVR treatment compared to PDT appear to significantly improve vision, decrease the central retinal thickness (CRT), and reduce the invalidation rate. The LogMar visual acuity shifts from 0.6 to 0.3 in the following 24 months and the improvement rate of visual acuity ranges from 60–70% in IVR treated patients. However, the visual acuity improvement is moderate in the PDT group. These analyses indicate that IVR is an applicable treatment in PCV patients, although PDT is able to yield about a 35% visual acuity improvement in a short-term follow-up. Our 3-D mesh modal also confirms that IVR is able to yield better effects to treat PCV than PDT.

Conclusions: The analysis in this study suggests that IVR has a significant effect on the improvement of visual acuity when treating patients with PCV. Our findings clearly document that IVR can be used as a more effective therapy for long-term administration in PCV.

Polypoidal choroidal vasculopathy (PCV) is one of the most common sight-threatening eye diseases, which was described for the first time in 1982 [1,2]. In the past, different names were proposed for PCV, such as posterior uveal bleeding syndrome [3] or multiple recurrent retinal pigment epithelium detachments [3,4]. However, PCV has been regarded as an under-retinal orange nodular lesion and an abnormal branching choroidal vascular network based on diagnosis through indocyanine green angiography (ICGA), fundus characteristics, and optical coherent tomography examinations. PCV has also been described in different pathological conditions, including central serous chorioretinopathy [5], circumscribed choroidal hemangioma [6], melanocytoma of the optic nerve [7], pathological myopia and staphyloma

[8], or choroidal osteoma [9]. Examinations indicate that PCV could be more like a neovasculopathy occurring in a variety of different diagnoses other than a distinct abnormality of the inner choroidal vasculature [2].

Treatment strategies for PCV include thermal laser photocoagulation, verteporfin photodynamic therapy (PDT), anti-VEGF therapies, and a combination therapy of PDT with anti-VEGF [2]. Currently, PDT is widely used in the treatment of PCV, as various studies have demonstrated that PDT can result in visual improvements [10-13]. However, evidence indicates that it is only an efficient treatment in the short term [2,11,13,14].

To date, several studies comparing PDT combined with anti-VEGF drugs and PDT monotherapy have been conducted [2,15,16]. However, they only included a small sample size and no definitive conclusions have been made yet [2]. Since 2009, a new treatment through the application of intravitreal ranibizumab (IVR) has been used to treat PCV [14,17,18]. Clinical observations indicate that IVR has a significant

Correspondence to: Zheng Qin Yin, Southwest Eye Hospital, Southwest Hospital, Key Laboratory of Visual Damage and Repair of Chongqing, Third Military Medical University, Chongqing, China, 400038; Phone: +86 23 6875 4401, FAX: +86 23 6546 0711; email: qinzyin@aaliyun.com

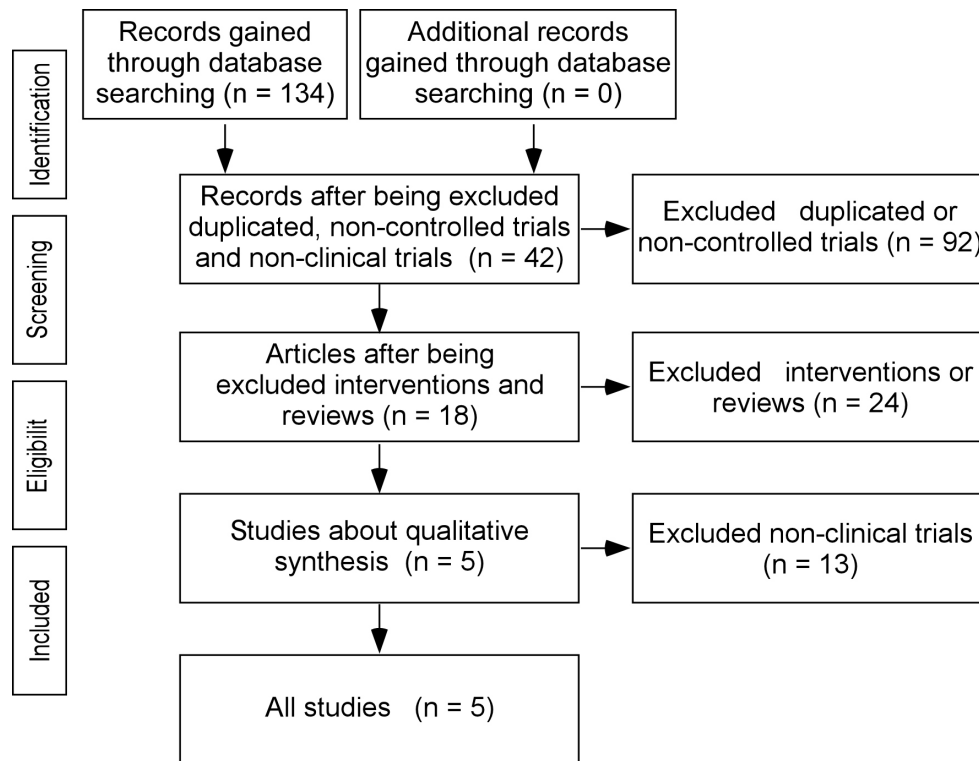


Figure 1. Selecting flowchart for controlled trials on the effects of ranibizumab versus photodynamic therapy (PDT) to treat polypoidal choroidal vasculopathy (PCV).

effect and advantage, such as small trauma and no formation of scars, to treat PCV compared to the classic therapy of PDT. Therefore, we performed a systematic review and meta-analysis of the available published literature to compare the outcomes of IVR and PDT. Our findings may be able to provide some scientific suggestion for the further treatment of PCV.

METHODS

Searching strategies: Our study reports in accordance with the preferred reporting items for systematic reviews and meta-analyses (PRISMA) statement. A systematic search of the Cochrane library, PubMed, Embase, Chinese Biologic and Medical (CBM) database, China National Knowledge Infrastructure (CNKI), VIP (Database for Chinese Technical Periodicals), and Wan Fang database was performed to assemble the controlled trials of IVR compared to PDT in the treatment of PCV up to July 2014. The search procedure was restricted to studies of human beings. There were no language restrictions. The following terms, adapted for each database, were used for the searches: (“polypoidal choroidal vasculopathy” or PCV) AND (“ranibizumab”) AND (“photodynamic therapy” or “PDT”). The related articles were also used to broaden the search, and the computer search was

supplemented with manual searches of the reference lists of all retrieved studies.

Inclusion and exclusion criteria: This study covers all PCV trials, including randomized controlled trials (RCTs) and non-randomized comparative studies that investigated PDT or IVR, or that compared PDT and IVR in all age groups. We excluded editorials, letters to the editor, review articles, meeting abstracts, and animal experimental studies. Two researchers independently read articles and excluded unmatched articles. The flow of the study in this analysis is depicted in Figure 1. The present study includes 260 PCV cases in total.

Outcome measurements: To test the hypothesis that literature supports the concept that IVR is advantageous to PDT, we used the main outcomes to compare the effect of PDT to treat PCV, including 1) mean visual acuity change at months 3, 6, 12, and 24, the proportion of treated eyes with improved, maintained, and deteriorated vision after each treatment at months 12 and 24. We also used 2) anatomic outcomes, specifically, a change in the central retinal thickness (CRT) at month 6, the regression rates of polyps at months 3 and 12, the resolution of pigment epithelial detachment (PED) in a 12-month follow-up, and recurrence rate of PCV. Finally, 3) adverse events, such as the incidence of retinal hemorrhage, were used.

Quality assessment: According to the Cochrane Reviewer’s Handbook 4.2.6, criteria (randomization method, allocation concealment, blinding, loss to follow-up, and exit) were applied to evaluate the methodological quality of the included studies. The methodological quality of RCTs and observational studies was assessed using the Cochrane Risk of Bias Tool and the modified Newcastle–Ottawa scale [2], which includes three factors: patient selection, comparability of the study groups, and outcome assessment. A score of 0–9 (allocated as stars) is allocated to each study, except RCTs. RCTs and observational studies achieving seven or more stars are considered to be of high quality.

Data analysis: Data suitable for meta-analysis were entered into the software package, RevMan version 5.0 [19]. Counting data were described as the relative risk ratio and measurement data were presented by WMD or standardized mean differences. The effects were measured at a 95% confidence interval (CI). The comparisons of heterogeneity among the studies were accessed using a chi-square test with the significance set at $p < 0.10$. The percentage of heterogeneity was evaluated using the I^2 statistic, ranging from 0% to 100%, with 0% representing no heterogeneity and larger values representing greater heterogeneity ($I^2 = 0–5\%$ indicates no or mild heterogeneity; $I^2 = 25–50\%$ indicates moderate heterogeneity; $I^2 = 50–75\%$ indicates large heterogeneity, and $I^2 = 75–100\%$ indicates extreme heterogeneity) [2,20]. If there was a statistical homogeneity between studies ($p > 0.10$, $I^2 < 50\%$), a fixed-effect meta-analysis model was used for a merger analysis. Otherwise, a random-effect model was used ($p < 0.10$,

$I^2 > 50\%$). The data are presented as mean \pm standard error of the mean (SEM), unless otherwise stated (mean \pm standard deviation [SD] of the mean). The improvement of LogMar visual acuity [21] was compared using the Mann–Whitney U test in Sigma Plot 12.5 (Systat Software, Inc., San Jose, CA). P values < 0.05 were considered indicative of statistical significance. The data were naturally Log-transformed for estimating linear regression models and the 3-D mesh model.

RESULTS

We selected five studies including 260 patients from 34 articles after excluding uncontrolled trials, repetitions, and non-clinical studies. A funnel plot yielded from those studies demonstrated no evidence of publication bias for IVR treatment versus PDT (Figure 2). General characteristics of these studies are presented in Table 1. Two of the five studies [14,22] described the details of a randomization method using random number tables of pooled participates.

LogMar visual improvement in 6-month follow-up: Four studies [13,14,17,18] reported LogMar visual acuity 6 months after treatment in patients. The average LogMar visual improvements are 0.17 ± 0.05 (0.08–0.35, 115 patients) and 0.06 ± 0.02 (0.01–0.11, 126 patients) in the IVR and PDT groups, respectively. The improvement of visual acuity shows a statistical homogeneity ($p = 0.42 > 0.10$, $I^2 = 0\% < 50\%$) between the two different groups. Meanwhile, those investigations used continuous data, and the fixed-effect model was applied for a meta-analysis to check the significant advantage of IVR to treat PCV compared with PDT. The analysis shows

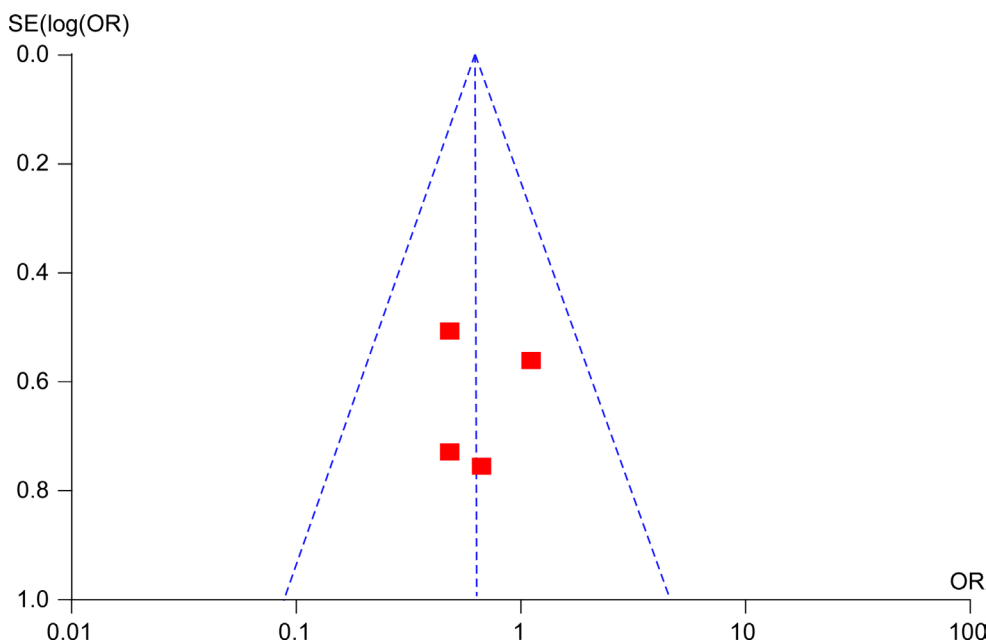


Figure 2. Funnel plot of an examination on the effects of intravitreal ranibizumab (IVR) versus PDT on PCV. This plot indicates no evidence of a publication bias for the intravitreal administration of ranibizumab versus photodynamic therapy to treat PCV. Abbreviations: SE, standard error; OR, odds ratio.

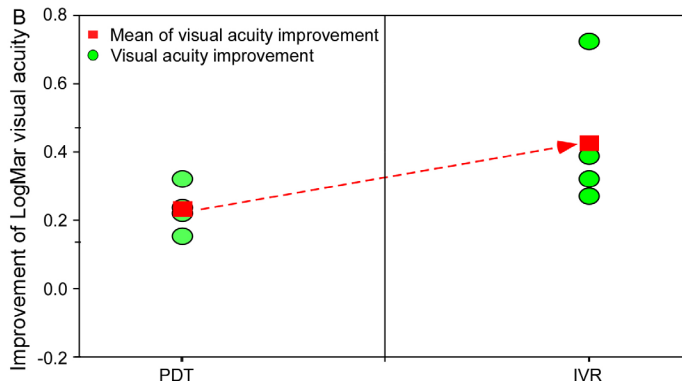
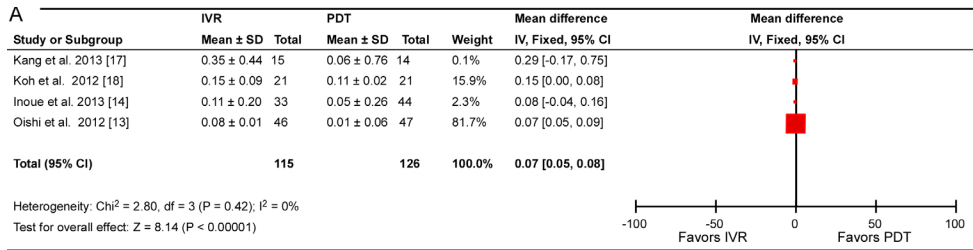


Figure 3. Four studies evaluated the visual acuity in a 6-month follow-up after the treatments. **A:** A meta-analysis indicates that IVR improved LogMar visual acuity compared to PDT 6 months after the treatments in patients with PCV. **B:** IVR has a significant advantage in the improvement of LogMar visual acuity (filled red squares) compared to PDT. Filled green circles are the average LogMar visual acuities reported in the four studies.

a significant difference between PDT and IVR treated groups ($p < 0.00001$, Figure 3A). From the four literatures, we also found that the improved LogMar visual acuity is 0.17 ± 0.05 ($n = 115$) in the IVR group and 0.06 ± 0.02 ($n = 126$) in the PDT group (Figure 3B). The LogMar visual acuity of IVR treated patients increased 3by .34±1.34 (0.36–7.00)-fold compared to the PDT group. Our meta-analysis verifies that IVR treatment has a significant advantage to improve vision in patients with PCV compared to traditional PDT.

LogMar visual upgrade in one-year follow-up: Four investigations [13,14,17,22] reported the upgrade of LogMar visual acuity 12 months after the treatments of IVR and PDT. A significant statistical heterogeneity was found in those studies ($p = 0.02 < 0.10$, $p = 71\% > 50\%$). Therefore, those data were subjected to a random-effect model using a meta-analysis. Our analysis indicates the significant difference between the two groups ($p < 0.00001$, Figure 4A). The means of increased

LogMar visual acuity are 0.08–0.35 in the IVR group and 0.01–0.16 in the PDT group. From the four literatures, we also found that the improved LogMar visual acuity is 0.21 ± 0.06 ($n = 101$) in the IVR group and 0.08 ± 0.03 ($n = 117$) in the PDT group (Figure 4B). The LogMar visual acuity of IVR-treated patients increased by 3.46±1.16 (0.94–7.00)-fold compared to the PDT group. These findings indicate that the vision of the IVR-treated group was significantly improved, unlike the subjects with PCV, who received traditional verteporfin photodynamic therapy (PDT).

Comparison of visual acuity improvement in two-year follow-up: IVR is able to improve LogMar visual acuity compared to the PDT group in a 24-month follow-up after treatments in patients with PCV [13,14,17,18,22] (Figure 5). In the patients given IVR treatment, the LogMar visual acuity shifts from about 0.6 to 0.3 in the following 24 months. However, the visual acuity in the subject having received PDT shows a

TABLE 1. THE GENERAL INFORMATION OF THE FIVE INVESTIGATIONS INCLUDED IN OUR STUDY.

Authors	Age (IVR/PDT)	Sex (M/F; IVR/PDT)	Samples (IVR/PDT)	Trial methods
Oishi et al. 2013 [13]	75.4±6.9/75.0±8.0	14:9/32:15	46/47	Multicenter RCT
Inoue et al. 2013 [14]	73.2±7.5/71.0±7.8	19:14/30:14	33/44	Retrospect
Kang et al. 2013 [17]	35.0±9.2/35.2±7.1	11/17	15/14	Retrospect
Koh et al. 2012 [18]	69.3±8.3/62.2±9.8	15:6/15:6	21/21	Multicenter RCT
Lai et al. 2011 [22]	64.6±7.9/65.6±11.0	4:3/5:1	7/12	Retrospect

Abbreviations: IVR (intravitreal ranibizumab), photodynamic therapy (PDT), RCT (randomized controlled trial).

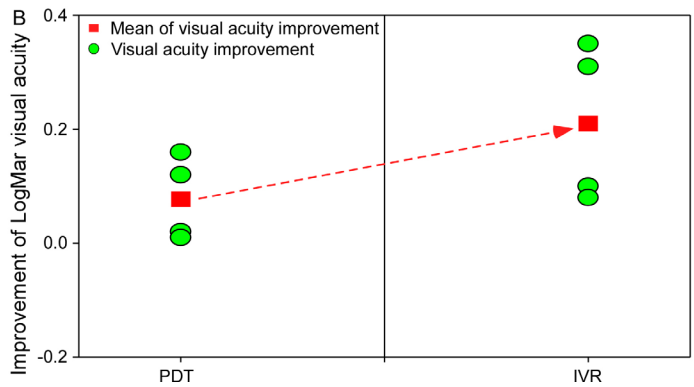
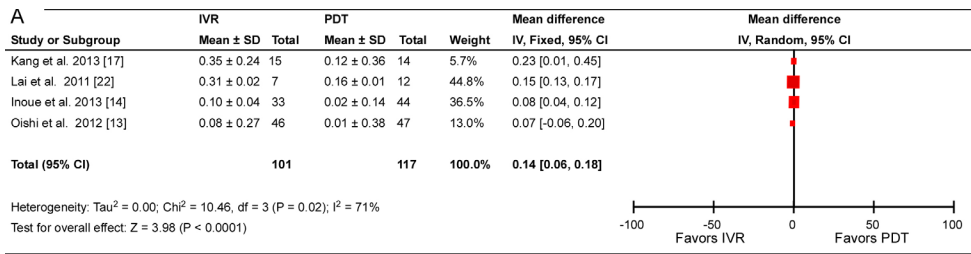


Figure 4. Four studies evaluated the visual acuity in a 24-month follow-up after the treatments. **A:** A meta-analysis indicates that IVR improved LogMar visual acuity compared to PDT 24 months after the treatments in patients with PCV. **B:** IVR has a significant advantage in the improvement of LogMar visual acuity (filled red squares) compared to PDT. Filled green circles are the average LogMar visual acuities reported in the four studies.

relatively moderate change from about 0.6 to 0.5, but it returns to the baseline at 6 months after treatment (Figure 5A). A significant difference was found in the visual acuity between the patients having received IVR or PDT treatment ($p < 0.001$; Figure 5A). After being normalized to the baseline before the treatment, LogMar visual acuity increased by 60–70% in the patients treated with IVR in two years, but it only showed about a 35% increase at month 6 and then gradually went back to the baseline in the patients having received PDT. The difference in the visual acuity increase in the patients given IVR treatment is significantly larger than that of PDT-treated patients (Figure 5B). The area plot in Figure 5C also confirms the relative improvement to the LogMar visual acuity is much larger after the IVR treatment (3.12) when compared to PDT (2.25). All of the outcomes and comparisons confirm that IVR treatment is a more effective therapy to treat PCV compared with the traditional administration of PDT.

CRT measurements: CRT is usually used as an important factor to indicate the healthy situation of the retina. We found that two literatures [13,18] reported the CRT changes at month 6 after the IVR treatments. A significant heterogeneity was found between studies with continuous data ($p = 0.06 < 0.10$, $I^2 = 71% > 50%$). Therefore, the random effect model was used for the meta-analysis. The results shows that CRT in the patients given IVR treatment is statistically thinner than in the PDT-treated groups ($p < 0.00001$, Figure 6A). From the two literatures, the decreases in CRT are $86.70 \pm 10.50 \mu\text{m}$ ($n = 67$) in the IVR group and $87.90 \pm 5.10 \mu\text{m}$ ($n = 68$) in the PDT group (Figure 6B). The CRT of IVR-treated patients reduced

by $2.79 \pm 17.91%$ compared to the PDT group. Therefore, IVR treatment has a greater potential to decrease the CRT and keep the retina healthy than PDT treatment.

Safety of IVR treatment in the improvement of visual acuity: Edema and bleeding complication are rarely encountered in patients having received IVR or PDT treatment. We only found that two studies [18,22] reported two cases of edema and bleeding complication after IVR or PDT treatment. However, no eye infection was observed in both studies. In the two studies with binary data types, a significant statistical difference of homogeneity was found between investigations ($p = 0.69 > 0.10$, $I^2 = 0% > 50%$). Therefore, the fixed-effect model was used for the meta-analysis. The results show that the potential risk of IVR treatment on PCV is quite lower compared to the traditional verteporfin photodynamic therapy (PDT; $p = 0.13$, Figure 7A). In addition, four literatures [13,14,17,18] discussed the potential risk on visual acuity in a 6-month follow-up after IVR treatments. From the four literatures, we found that the potential risk to worsen LogMar visual acuity is $19.75 \pm 4.90%$ ($n = 115$) in the IVR group and $24.50 \pm 6.27%$ ($n = 126$) in the PDT group (Figure 3B). The deterioration of LogMar visual acuity decreases by $17.91 \pm 1.95%$ ($12.50\text{--}23.53%$) in IVR patients compared to the control group. These findings from our analysis indicate that IVR treatment is a safe strategy to administrate PCV.

IVR has a greater significance on vision improvement and applicable safety to treat PCV patients: The average age, LogMar visual acuity, and safety from the four literatures

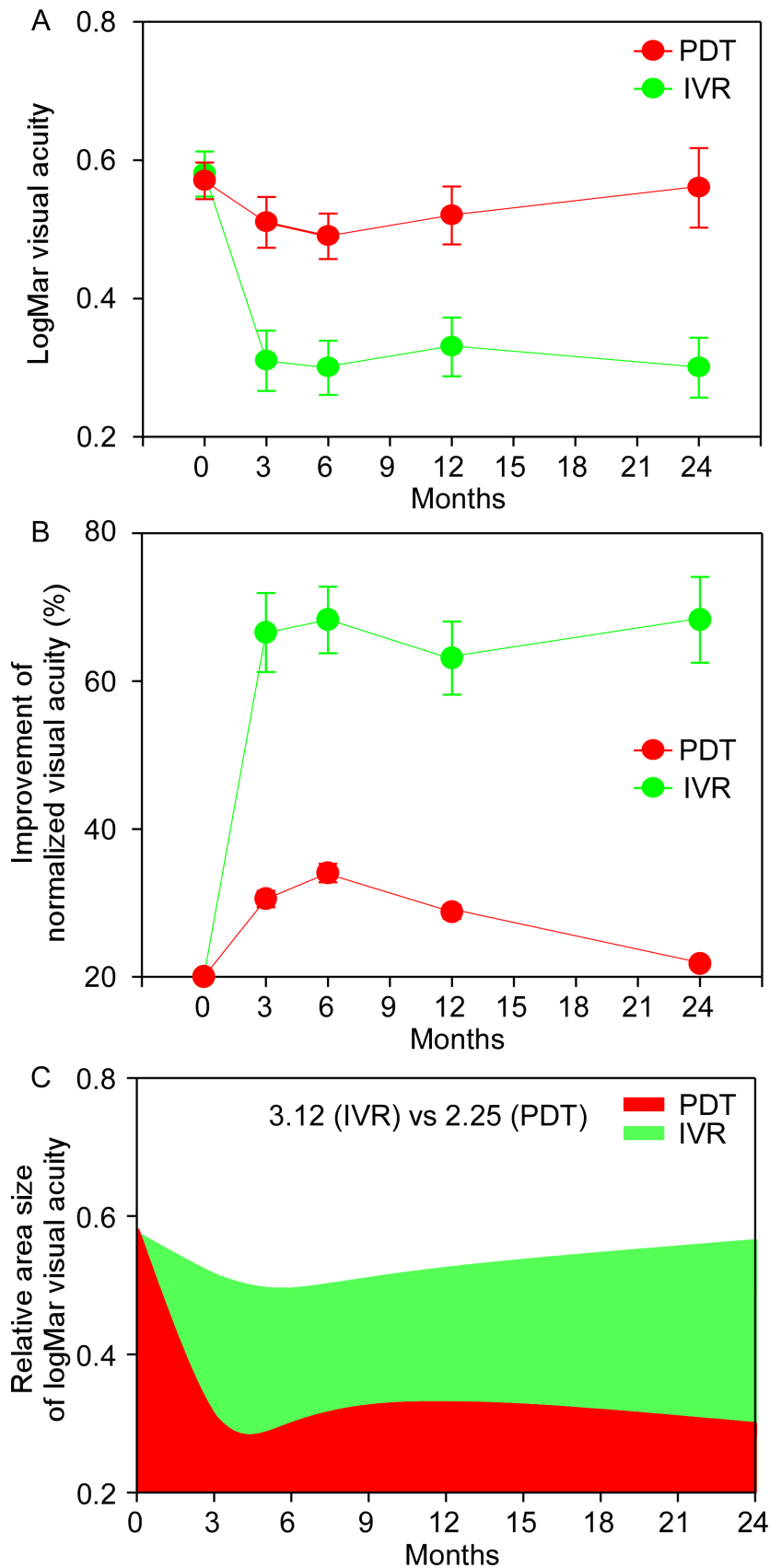


Figure 5. IVR improves LogMar visual acuity compared to PDT in a 24-month follow-up after the treatments in patients with PCV. **A:** PDT only yields a moderate improvement of visual acuity 6 months after the treatment, but IVR significantly increases vision in two years. **B:** After being normalized, LogMar visual acuity increased by 60–70% in the patients treated with IVR in two years, but only showed about a 35% increase at month 6 and then a gradual return to the baseline in the patients having received PDT. **C:** The area plot indicates the relative difference in the improvement of visual acuity after the treatments of IVR (3.12) and PDT (2.25).

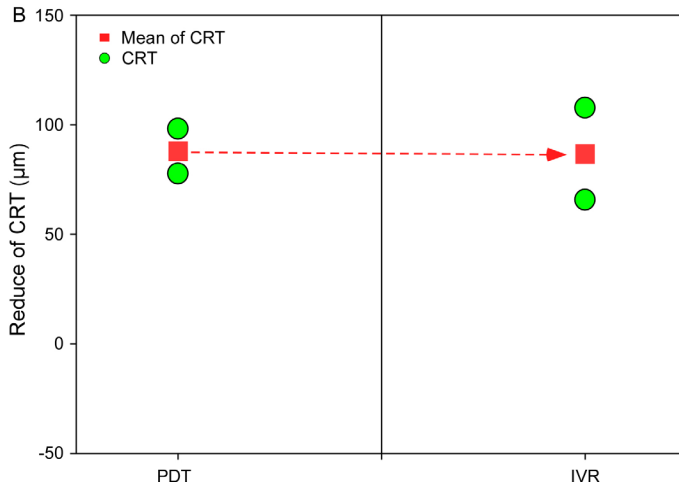
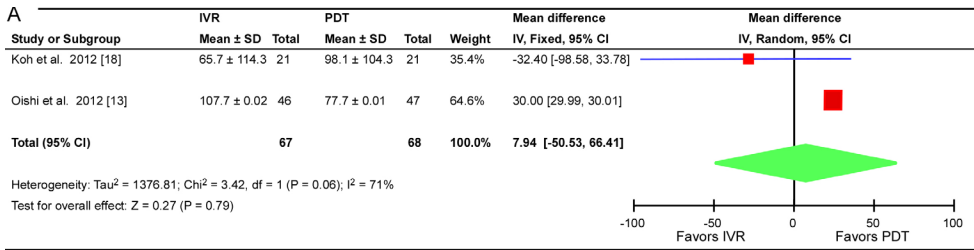


Figure 6. Previous studies show that the central retina thickness (CRT) is larger in PCV patients treated with IVR compared to the patients given PDT. **A:** A meta-analysis demonstrates that treatment has a greater potential to keep the retina healthy than PDT 6 months after the treatments in patients with PCV. **B:** IVR has a significant advantage in the reduction of CRT (filled red squares) compared to PDT. Filled green circles are the average CRTs reported in the two studies.

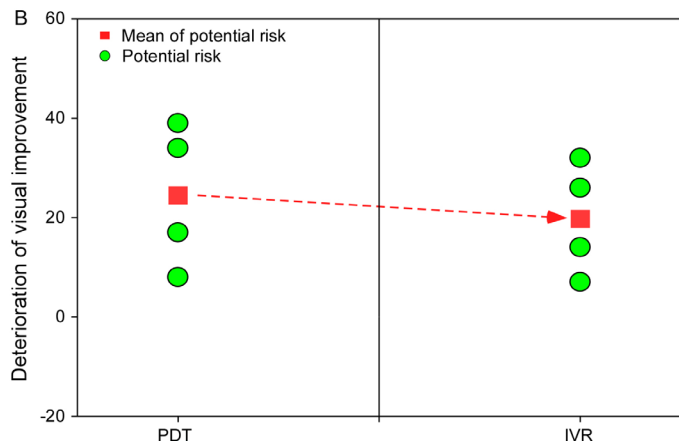
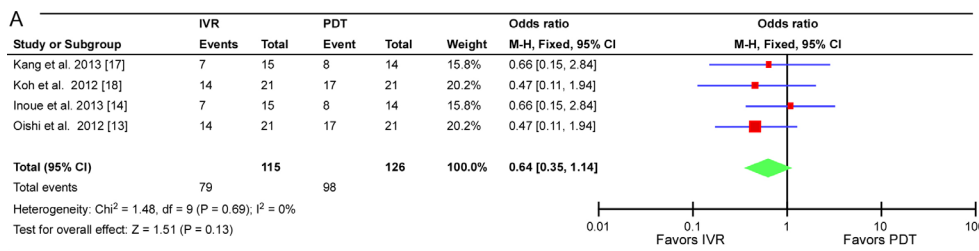


Figure 7. IVR is a safe treatment for PCV. **A:** A meta-analysis indicates that IVR has a lesser potential risk to decrease LogMar visual acuity compared to PDT 6 months after the treatments in patients with PCV. **B:** IVR has a lower deterioration risk for vision loss in treating PCV compared to PDT.

[13,14,17,18] were Ln-transformed to yield the association among the three parameters. In a two-year follow-up of the four studies, we found that there is a significantly linear association between LogMar visual acuity and safety after IVR treatment ($y = -1.04x + 1.17$, $R^2 = 0.88$) and PDT ($y = -1.60x + 1.71$, $R^2 = 0.74$) for PCV. However, this model indicates that IVR treatment has a greater effect on vision improvement with a higher applicable safety compared to PDT treatment (Figure 8A). Similarly, there is a linear relationship between age and the deterioration rate of treatment in PCV patients using IVR ($y = -1.09x + 7.30$, $R^2 = 0.33$) and PDT ($y = -1.22x + 8.02$, $R^2 = 0.35$). In this linear model, the regression shows that IVR has a lower potential risk to worsen the vision of PCV patients in all age groups compared to PDT treatment (Figure 8B). In other words, compared to PDT treatment, IVR has a better promotion to improve vision in PCV patients. A linear relationship is also found between LogMar visual acuity and age in both treatments ($y = 1.33x - 7.19$, $R^2 = 0.040$ in the IVR group; $y = 1.97x - 11.15$, $R^2 = 0.26$ in the PDT group). This association demonstrates that IVR treatment has a stronger effect in improving the vision of PCV patients compared to PDT treatment when age is a considered factor (Figure 8C).

When we put Ln-transformed age, potential risk of vision decrease, and change in LogMar visual acuity together, we generated a 3-D mesh plot to show that IVR has a greater effect on vision improvement and higher safety in all patients (Figure 8D). The mesh (green) yielded from the three parameters of IVR-treated patients is closer to the top ceiling in the 3-D model compared to that of PDT (red; Figure 8D). This indicates that IVR is a more applicable treatment for PCV patients to improve vision.

DISCUSSION

Similar to wet age-related macular degeneration (AMD), previous studies reported a high concentration of VEGF in the aqueous humor and a high expression of VEGF in PCV histologic samples [12,23,24]. These findings have indicated that VEGF is involved in the pathogenesis of PCV [12,23,24]. To date, three types of anti-VEGF agents have been administered to treat PCV. All anti-VEGF agents are VEGF-A traps, including ranibizumab (Lucentis), bevacizumab (Avatin), and aflibercept (Eylea) [25]. As a humanized anti-VEGF antibody, ranibizumab inhibits all forms of biologically active VEGF-A; treatment with ranibizumab appears to significantly decrease bleeding and exudation in PCV patients [26]. Bevacizumab is another humanized full-length anti-VEGF antibody, and it has a treatment effect in PCV eyes [22,27]. Compared to the effects of bevacizumab, ranibizumab has

been shown to have a greater significance in improving visual acuity and foveal center thickness [28]. Considering the molecular weight, ranibizumab is a 48 kDa Fab fragment, but bevacizumab is a complete 149 kDa antibody; the smaller molecular weight of ranibizumab may be the reason that it is more effective in treatment and has a possibly deeper penetration to choroidal vascular abnormality lesions of PCV [27,28]. In addition, compared to bevacizumab, ranibizumab is an affinity-matured VEGF-A trap and may provide better VEGF inhibition through a stronger molecular binding affinity [28]. The third anti-VEGF agent used to treat PCV is aflibercept, and it has broadly been applied to administrate wet AMD. In Japan, Saito et al. injected aflibercept into PCV patients with resistance to ranibizumab and found the promising effects on maintaining or improving visual acuity and reducing or eliminating exudative lesions and occluding polypoidal lesions without adverse events and with a short-term follow-up [25]. Their findings are quite exciting, especially for those PCV patients with other anti-VEGF resistances. In 2012, Papadopoulos et al. compared the binding affinity of the three anti-VEGF agents and found that the binding affinity of ranibizumab and bevacizumab to VEGF-A is lower than that of aflibercept [29]. The VEGF-binding affinity of aflibercept is about 140 times that of ranibizumab [25,29]. Based on the study of Papadopoulos et al., Saito et al. suggested that the powerful VEGF-binding affinity of aflibercept might be the primary reason why polypoidal lesions tend to become occluded in PCV patients [25]. Aflibercept started to be applied to treat PCV in 2012; therefore, there is not enough literature to allow us to compare systemically its effects with other anti-VEGF agents to treat PCV.

In this study, for a short-term follow-up after treatment, LogMar visual acuity confirms that the effect of PDT on vision improvement is quite limited in participant patients. However, the improvement is dramatically significant in the patients who received IVR treatment. Our further analysis based on the studies about a one-year follow-up found that IVR is obviously more effective to improve visual acuity in those treated patients. However, the patients that received PDT treatment had no observable vision improvement in the same period. In an investigation of a two-year follow-up, our analysis indicates that PDT-treated patients had moderate improvement of visual acuity 6 months after the surgery, but vision returned to the pre-surgery level after a couple weeks. However, in the patients given IVR treatment, their vision had a continuous increase after the performance. All of the outcomes and comparisons clearly show that IVR rather than PDT is a more acceptable and practicable treatment to help PCV patients regain some vision. Furthermore, our analysis indicates that IVR has a significant protective effect on CRT

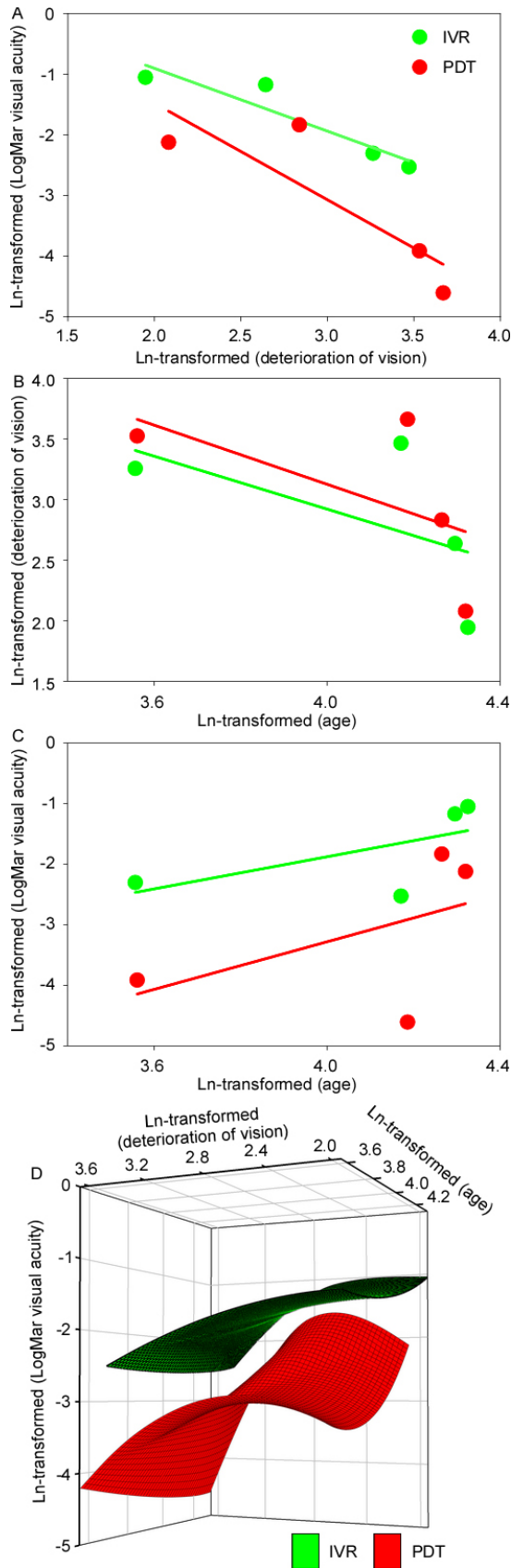


Figure 8. The relationships are yielded among the ages of PCV patients, the safety, and the vision improvement after the treatments of IVR and PDT. **A:** A linear association can be found between LogMar visual acuity and the safety of treatment for PCV. **B:** There is a linear relationship between age and safety of treatment. **C:** Linear regression can be established between LogMar visual acuity and age. **D:** A 3-D mesh model (age, deterioration, and LogMar visual acuity) indicates that IVR has a greater effect on vision improvement, lower deterioration risk, and higher efficiency in all PCV patients.

compared to PDT after treatment. CRT has been used as an essential index of the healthy condition of the retina. Therefore, these findings suggest that IVR has a more promising effect to treat PCV patients in clinic.

PCV is more prevalent in Asian and African-American populations than Caucasians, which may lead to the heterogeneity in the clinical features of AMD among the races [30]. Although PCV is most commonly diagnosed in patients between the ages of 50 and 70 years [31-35], previous studies also addressed that some patients were diagnosed with PCV in their 40s [34] and even as early as the age of 20 years [33]. The average age of onset for all the affected patients from the literature is 60.1 years [31,33]. However, the age of PCV diagnosis can range from the 20s to 90s [31,32,34,36-38]. In our study, the average age of 14 patients is 35.0 years (ranging from 20 to 47 years old) in one study [17], but the average age of most patients was 64.6–75.4 years in other cited literature [13,14,18,22]. It looks as though PCV can be diagnosed in people covering quite broad age range (>70 years) rather than with a clear prevalence in a specific age group. The patients' ages in our study are covered in the age range reported in previous studies [31-35]. Therefore, the age range included in our study might be unable to affect significantly the outcome of the meta-analysis.

Our meta-analysis indicates that IVR is quite a safe treatment for PCV patients. Edema and bleeding complication were quite rarely observed in patients that were given IVR administration in a 6-month follow-up. However, the operation of PDT can cause aggravated edema and inflammation reactions. This might be the reason that PDT has no clear effect to improve eyesight. In contrast, IVR usually does not cause an inflammatory response or edema after administration in PCV patients. Improved vision in the IVR-treated patients is obvious compared with the PDT-treated individuals. A previous study confirmed that PDT was associated with the risk of submacular hemorrhages in PCV [2], and it suggested that PDT alone would not be the best option to treat PCV, mainly until 6 months [2]. Our linear regressions also confirm that IVT treatment has better effects to treat PCV rather than PDT. The 3-D mesh model clearly indicates that IVT treatment has a more significant practicability to improve visual acuity but a lower deterioration risk in PCV patients compared to PDT administration.

The present meta-analysis has some limitations that cannot be ignored regarding this analysis. The first limitation is that there were only two studies [14,39] giving detailed descriptions on stochastic methods. Therefore, it is quite hard to know whether there was any selective bias during the procedure or the possibility of implementing the measurement

bias in other studies. In addition, the inconsistent use of units in different studies may lead to some bias in the results. The second limitation is the relatively small patient sample sizes in the studies used in our analysis. Only two studies [13,14] included nearly 100 cases, but other studies covered only a small group of patients. This could influence the stability of outcome measures and may reduce test power. The third possible limitation is the short follow-up of those studies. Most of the research studies, which simply reported short-term observations after treatments, had not covered the long-term observation of these cases. Given that the treatment of PCV might be longer than two years, more data are needed from studies of longer follow-up to determine the efficacy and safety of the therapy over the long duration.

In conclusion, our analysis establishes a comparison of the advantages between IVR and PDT treatment for PCV patients. Based on the detailed investigation, our findings clarify that IVR has a more promising significance in treating PCV compared to the traditional therapy of PDT. Our analysis confirms that IVR could be regarded as a safe treatment for patients with PCV.

ACKNOWLEDGMENTS

This study was supported by the National Basic Research Program of China (973 Program, 2013CB967002 to ZQY) and the National Natural Science Foundation of China (No. 81470671 to YL). Yong Liu (liu_yong2012@yahoo.com) and Zheng Qin Yin (qinzyin@aliyun.com) are co-corresponding authors for this paper.

REFERENCES

1. Sakurada Y, Yoneyama S, Imasawa M, Iijima H. Systemic risk factors associated with polypoidal choroidal vasculopathy and neovascular age-related macular degeneration. *Retina* 2013; 33:841-5. [PMID: 23400077].
2. Wang W, He M, Zhang X. Combined intravitreal anti-VEGF and photodynamic therapy versus photodynamic monotherapy for polypoidal choroidal vasculopathy: a systematic review and meta-analysis of comparative studies. *PLoS ONE* 2014; 9:e110667-[PMID: 25343244].
3. Kleiner RC, Brucker AJ, Johnston RL. The posterior uveal bleeding syndrome. *Retina* 1990; 10:9-17. [PMID: 2343198].
4. Stern RM, Zakov ZN, Zegarra H, Gutman FA. Multiple recurrent serosanguineous retinal pigment epithelial detachments in black women. *Am J Ophthalmol* 1985; 100:560-9. [PMID: 2413762].
5. Yannuzzi LA, Freund KB, Goldbaum M, Scassellati-Sforzolini B, Guyer DR, Spaide RF, Maberley D, Wong DWK, Slakter JS, Sorenson JA, Fisher YL, Orlock DA. Polypoidal choroidal vasculopathy masquerading as central serous

- chorioretinopathy. *Ophthalmology* 2000; 107:767-77. [PMID: 10768341].
6. Li H, Wen F, Wu D. Polypoidal choroidal vasculopathy in a patient with circumscribed choroidal hemangioma. *Retina* 2004; 24:629-31. [PMID: 15300094].
 7. Mieler WF, Bartlett HM, Willoughby B, Mandava N. Polypoidal choroidal vasculopathy in a patient with melanocytoma of the optic nerve. *Retina* 2001; 21:396-9. [PMID: 11508895].
 8. Mauguet-Fayssse M1, Cornut PL, Quaranta El-Maftouhi M, Leys A. Polypoidal choroidal vasculopathy in tilted disk syndrome and high myopia with staphyloma. *Am J Ophthalmol* 2006; 142:970-5. [PMID: 17046703].
 9. Fine HF, Ferrara DC, Ho IV, Takahashi B, Yannuzzi LA. Bilateral choroidal osteomas with polypoidal choroidal vasculopathy. *Retinal Cases and Brief Reports* 2008; 2:15-7. [PMID: 25389606].
 10. Nowak-Sliwinska P, van den Bergh H, Sickenberg M, Koh AHC. Photodynamic therapy for polypoidal choroidal vasculopathy. *Prog Retin Eye Res* 2013; 37:182-99. [PMID: 24140257].
 11. Spaide RF, Donsoff I, Lam DL, Yannuzzi LA, Jampol LM, Slakter J, Sorenson J, Freund KB. Treatment of polypoidal choroidal vasculopathy with photodynamic therapy. *Retina* 2002; 22:529-35. [PMID: 12441716].
 12. Tomita K, Tsujikawa A, Yamashiro K, Ooto S, Tamura H, Otani A, Nakayama Y, Yoshimura N. Treatment of polypoidal choroidal vasculopathy with photodynamic therapy combined with Intravitreal injections of ranibizumab. *Am J Ophthalmol* 2012; 153:68-80. [PMID: 21907965].
 13. Oishi A, Kojima H, Mandai M, Honda S, Matsuoka T, Oh H, Kita M, Nagai T, Fujihara M, Bessho N, Uenishi M, Kurimoto Y, Negi A. Comparison of the effect of ranibizumab and verteporfin for polypoidal choroidal vasculopathy: 12-month LAPTOS study results. *Am J Ophthalmol* 2013; 156:644-51. [PMID: 23876867].
 14. Inoue M, Arakawa A, Yamane S, Kadonosono K. Long-term outcome of intravitreal ranibizumab treatment, compared with photodynamic therapy, in patients with polypoidal choroidal vasculopathy. *Eye (Lond)* 2013; 27:1013-21. [PMID: 23970023].
 15. Rouvas AA, Papakostas TD, Ntouraki A, Douvali M, Vergados I, Ladas ID. Photodynamic therapy, ranibizumab, and ranibizumab with photodynamic therapy for the treatment of polypoidal choroidal vasculopathy. *Retina* 2011; 31:464-74. [PMID: 20948458].
 16. Lee MY, Lee WK, Baek J, Kwon OW, Lee JH. Photodynamic therapy versus combination therapy in polypoidal choroidal vasculopathy: changes of aqueous vascular endothelial growth factor. *Am J Ophthalmol* 2013; 156:343-8. [PMID: 23664208].
 17. Kang HM, Koh HJ. Intravitreal anti-vascular endothelial growth factor therapy versus photodynamic therapy for idiopathic choroidal neovascularization. *Am J Ophthalmol* 2013; 155:713-9. [PMID: 23219069].
 18. Koh A, Lee WK, Chen LJ, Chen SJ, Hashad Y, Kim H, Lai TY, Pilz S, Ruamviboonsuk P, Tokaji E, Weisberger A, Lim TH. Everest study: efficacy and safety of verteporfin photodynamic therapy in combination with ranibizumab or alone versus ranibizumab monotherapy in patients with symptomatic macular polypoidal choroidal vasculopathy. *Retina* 2012; 32:1453-64. [PMID: 22426346].
 19. Centre TNC. The cochrane collaboration. In: (RevMan) RM, editor. 5.2 ed. 2012; pp. Version 5.2 Copenhagen.
 20. Higgins JPT, Thompson SG, Deeks JJ, Altman DG. Measuring inconsistency in meta-analyses. 2003; 557-560 p.
 21. Bailey IL, Lovie JE. New design principles for visual acuity letter charts. *Am J Optom Physiol Opt* 1976; 53:740-45. [PMID: 998716].
 22. Lai TY, Lee GK, Luk FO, Lam DS. Intravitreal ranibizumab with or without photodynamic therapy for the treatment of symptomatic polypoidal choroidal vasculopathy. *Retina* 2011; 31:1581-8. [PMID: 21610566].
 23. Tong J-P, Chan W-M, Liu DTL, Lai TYY, Choy K-W, Pang C-P, Lam DSC. Aqueous humor levels of vascular endothelial growth factor and pigment epithelium-derived factor in polypoidal choroidal vasculopathy and choroidal neovascularization. *Am J Ophthalmol* 2006; 141:456-62. [PMID: 16490490].
 24. Matsuoka M, Ogata N, Otsuji T, Nishimura T, Takahashi K, Matsumura M. Expression of pigment epithelium derived factor and vascular endothelial growth factor in choroidal neovascular membranes and polypoidal choroidal vasculopathy. *Br J Ophthalmol* 2004; 88:809-15. [PMID: 15148217].
 25. Saito M, Kano M, Itagaki K, Oguchi Y, Sekiryu T. Switching to intravitreal aflibercept injection for polypoidal choroidal vasculopathy refractory to ranibizumab. *Retina* 2014; 34:2192-201. [PMID: 25077530].
 26. Cho M, Barbazetto IA, Freund KB. Refractory neovascular age-related macular degeneration secondary to polypoidal choroidal vasculopathy. *Am J Ophthalmol* 2009; 148:70-8. [PMID: 19403115].
 27. Gomi F, Sawa M, Sakaguchi H, Tsujikawa M, Oshima Y, Kamei M, Tano Y. Efficacy of intravitreal bevacizumab for polypoidal choroidal vasculopathy. *Br J Ophthalmol* 2008; 92:70-3. [PMID: 17567661].
 28. Cho HJ, Kim JW, Lee DW, Cho SW, Kim CG. Intravitreal bevacizumab and ranibizumab injections for patients with polypoidal choroidal vasculopathy. *Eye (Lond)* 2012; 26:426-33. [PMID: 22173075].
 29. Papadopoulos N, Martin J, Ruan Q, Rafique A, Rosconi MP, Shi E, Pyles EA, Yancopoulos GD, Stahl N, Wiegand SJ. Binding and neutralization of vascular endothelial growth factor (VEGF) and related ligands by VEGF Trap, ranibizumab and bevacizumab. *Angiogenesis* 2012; 15:171-85. [PMID: 22302382].
 30. Honda S, Matsumiya W, Negi A. Polypoidal choroidal vasculopathy: clinical features and genetic predisposition. *Ophthalmologica* 2014; 231:59-74. [PMID: 24280967].

31. Ciardella AP, Donsoff IM, Huang SJ, Costa DL, Yannuzzi LA. Polypoidal choroidal vasculopathy. *Surv Ophthalmol* 2004; 49:25-37. [PMID: 14711438].
32. Imamura Y, Engelbert M, Iida T, Freund KB, Yannuzzi LA. Polypoidal choroidal vasculopathy: A review. *Surv Ophthalmol* 2010; 55:501-15. [PMID: 20850857].
33. Yannuzzi LA, Ciardella A, Spaide RF, Rabb M, Freund K, Orlock DA. The expanding clinical spectrum of idiopathic polypoidal choroidal vasculopathy. *Arch Ophthalmol* 1997; 115:478-85. [PMID: 9109756].
34. Uyama M, Matsubara T, Fukushima I, Matsunaga H, Iwashita K, Nagai Y, Takahashi K. Idiopathic polypoidal choroidal vasculopathy in Japanese patients. *Arch Ophthalmol* 1999; 117:1035-42. [PMID: 10448746].
35. Kwok AKH, Lai TY, Chan CW, Neoh E-L, Lam DS. Polypoidal choroidal vasculopathy in Chinese patients. *Br J Ophthalmol* 2002; 86:892-7. [PMID: 12140211].
36. Sho K, Takahashi K, Yamada H, Wada M, Nagai Y, Otsuji T, Nishikawa M, Mitsuma Y, Yamazaki Y, Matsumura M, Uyama M. Polypoidal choroidal vasculopathy: Incidence, demographic features, and clinical characteristics. *Arch Ophthalmol* 2003; 121:1392-6. [PMID: 14557174].
37. Yannuzzi LA, Wong DWK, Sforzolini BS, Goldbaum M, Tang KC, Spaide RF, Freund KB, Slakter JS, Guyer DR, Sorenson JA, Fisher Y, Maberley D, Orlock DA. Polypoidal choroidal vasculopathy and neovascularized age-related macular degeneration. *Arch Ophthalmol* 1999; 117:1503-10. [PMID: 10565519].
38. Bessho H, Honda S, Imai H, Negi A. Natural course and fundusoscopic findings of polypoidal choroidal vasculopathy in a Japanese population over 1 year of follow-up. *Retina* 2011; 31:1598-602. [PMID: 21478804].
39. Saito M, Iida T, Kano M, Itagaki K. Two-year results of combined intravitreal ranibizumab and photodynamic therapy for polypoidal choroidal vasculopathy. *Graefes Arch Clin Exp Ophthalmol* 2013; 251:2099-110. [PMID: 23553286].

Articles are provided courtesy of Emory University and the Zhongshan Ophthalmic Center, Sun Yat-sen University, P.R. China. The print version of this article was created on 3 October 2015. This reflects all typographical corrections and errata to the article through that date. Details of any changes may be found in the online version of the article.