

# Regional & Topical Anaesthesia of Upper Airways

Nibedita Pani<sup>1</sup>, Shovan Kumar Rath<sup>2</sup>

## Summary

A combination of techniques are required to adequately anaesthetise upper airway structures for awake intubation. The widest coverage is provided by the inhalational technique. This technique, however, does not always provide a dense enough level of anaesthesia for all patients. Supplementation of this technique with any of the specific nerve blocks is an excellent way to accomplish efficacious anaesthesia for awake intubation. Anaesthetising upper airway is not a difficult skill to master and should be in the armamentarium of all practising anaesthetist.

**Key words** Awake intubation, Fibre optic intubation, Laryngoscopy, Topical anaesthesia, Local anaesthetics, Nerve block

## Introduction

Airway management is fundamental to the practice of anaesthesia and tracheal intubation is frequently required to ensure adequate airway control, while providing optimal operating conditions. Intubation by direct laryngoscopy is usually satisfactory. However, providing anaesthetic care to the patient with a difficult airway keenly interests anaesthesiologists. Expertise with regional anaesthesia of the airway allows intubation in awake patients with suspected difficult intubation in the presence of certain anatomical variants or airway pathology, where visualization of the glottis by direct laryngoscopy can be difficult or impossible. Furthermore, in the presence of upper airway trauma & cervical spine injury, neck movement must be minimized if neurological injury is to be avoided. Therefore, it is essential that every regional anaesthesiologist be skilled enough to administer general anaesthesia and especially in the management of the difficult airway with the knowledge of recent development in the field of regional anaesthesia of the upper airways.

The mainstay of difficult airway management remains flexible fiberoptic laryngobronchoscopic intubation. In the awake patient fiberoptic intubation maintains a wide margin of safety while producing minimal

patient discomfort, but requires adequate local anaesthesia of the airway. Fiberoptic intubation (FOI) is regarded as a safe way of managing some airway problems, particularly anticipated difficulty with direct laryngoscopy<sup>1-3</sup>. Several authors have reported that FOI can be achieved with considerable haemodynamic stability<sup>4-6</sup> under local anaesthetic when combined with sedation.

Laryngobronchoscopy in an awake, unprepared patient lead to undesirable elevations in the patient's sympathetic and parasympathetic outflow causing excessive salivation and gag and cough reflexes making intubation difficult, To decide on a proper approach to an awake intubation, one must determine what structures need to be anaesthetized along the two basic routes of intubation (oral or nasal) to facilitate optimal surgical conditions in the context of patient-specific anatomic considerations. Each of these routes has a well-defined pattern of innervation that can be specifically blocked to provide adequate anaesthesia to subdue these reflexes and facilitate intubation.

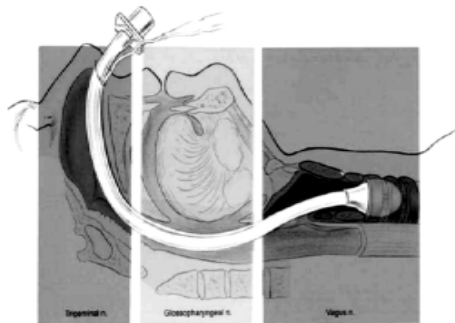
Although fiberoptic intubation can be done in the unconscious individual, it is particularly suited to the awake patient and, with proper technique, produces minimal discomfort while maintaining a wide margin of safety.<sup>7-11</sup>

1. Professor, 2. P G Student, Department of Anaesthesiology, SCB Medical College, Cuttak-753007, Orissa,  
**Correspondence to:** Nibedita Pani, Department of Anaesthesiology, SCB Medical College, Cuttak-753007, Orissa,  
 Email: drnp@rediffmail.com, drshovankumarrath@gmail.com *Accepted for publication on: 25.11.09*

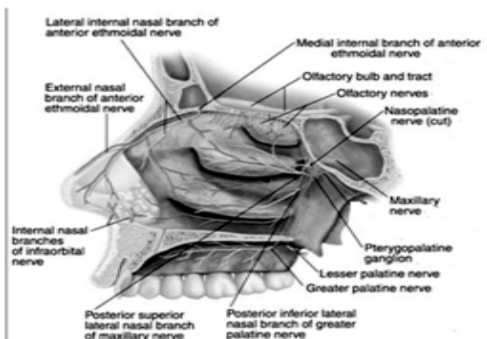
## Relevant Anatomy

Three major neural pathways supply sensation to airway structures (Fig 1)

**1. Terminal branches of the ophthalmic and maxillary divisions of the trigeminal nerve supply the nasal cavity and turbinates.** (Fig 2),<sup>12</sup> (i.e. the greater and lesser palatine nerves arising from the pterygopalatine ganglion innervate the nasal turbinates and most of the nasal septum.. The anterior ethmoidal nerve arises from the olfactory nerve (CN I) and innervates the nares and the anterior third of the nasal septum.)



**Fig 1 Three major neural pathways supplying sensation to airway structures.**

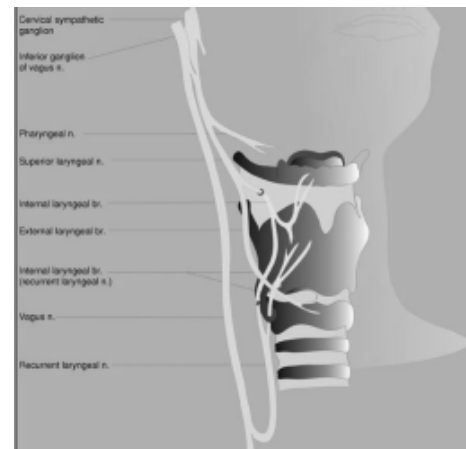


**Fig 2 Sensory supply of nose**

**2. The oropharynx and posterior third of the tongue are supplied by the glossopharyngeal nerve.**

(The sensory innervation of the anterior two thirds of the tongue is provide by the trigeminal nerve i.e. lingual branch of the mandibular division. it is not a part of the reflex arcs controlling gag or cough, its blockade is not essential for comfort during FOI.)

**3. Branches of the vagus nerve innervate the epiglottis and more distal airway structures.(Fig 3)**



**Fig 3 Branches of the vagus nerve innervating the epiglottis and more distal airway structures.**  
The airway reflexes important for awake intubation

The aforementioned nerves participate in several brainstem-mediated reflex arcs.

**1.Gag reflex** – triggered by mechanical and chemical stimulation of areas innervated by the glosso-pharyngeal nerve, and the efferent motor arc is provided by the vagus nerve and its branches to the pharynx and larynx.

**2.Glottic closure reflex** – elicited by selective stimulation of the superior laryngeal nerve, and efferent arc is the recurrent laryngeal nerve.– exaggeration of this reflex is called laryngospasm.

**3.Cough** – the cough receptors located in the larynx and trachea receive afferent and efferent fibers from the vagus nerve.

### Techniques for Anaesthetizing the Airway

Even in the hands of the most skilled regional anesthesiologist, blocks are subject to a certain rate of complications or failure<sup>13-16</sup>. So Fiberoptic intubation can be performed under a variety of conditions. However, one major decision must be made with every procedure will the patient be intubated while under general anaesthesia, or does the patient need to be awake dur-

ing intubation? Intubation under general anaesthesia (even with inhalational induction and spontaneous respiration) carries the inherent risk of losing control of the difficult airway. For this reason, many anaesthesiologists, on recognition of a difficult airway, elect to perform an awake intubation using either fiber optic laryngobronchoscopy or awake direct laryngoscopy

### **Preparation for Awake Intubation**

Adequate sedation & analgesia is important and advantageous in both the anaesthetizing of the airway as well as during the intubation. Agents used for this purpose are generally fall into 2 group: benzodiazepines and opioids. For this purpose, it is best to use short-acting or reversible agents for sedation or agents that do not cause a considerable degree of respiratory depression, i.e midazolam, alfentanil, and fentanyl

Second is Antisialagogues,<sup>17,18</sup> as oral secretions may make visualization via the fiberoptic equipment difficult and may serve as a barrier to effective penetration of local anaesthetic into the mucosa. Glycopyrrolate or atropine may be used<sup>12,19</sup>.

### **Local anaesthetics**

There are three most often used local anaesthetic with or without the use of vasoconstrictors: Cocaine, Benzocaine, & Lidocaine

#### **Local anaesthetics – benzocaine**

A water-insoluble ester that is frequently used in a 20% spray to produce anaesthesia in mucous membranes.

#### **Local anaesthetics – lidocaine**

Lidocaine is probably the local anaesthetic most frequently used for topical anaesthesia of the airway. Lidocaine 2-4% applied to mucous membranes produces superficial anaesthesia in about one minute.<sup>12,20</sup> The peak effect occurs within two to five minutes and the duration of action is 30-45min.<sup>21</sup> The maximum safe dosage has generally been considered to be 3-4 mg. kg<sup>-1</sup>, although some recommend up to 6 mg./ kg.<sup>20,22-25</sup>

**Advantages:** 1. ready availability; 2. relatively low CNS and cardiac toxicity; 3. quick onset; 4. clinically useful duration of action (30-60 mins for topical application and 1 to 2 hours after infiltration).

#### **Disadvantages:**

1. Toxic plasma levels (>5 mcg.ml<sup>-1</sup>) can be reached when moderate amounts of high concentration solutions are used;
2. Caution must be used in patients with hepatic dysfunction.

#### **Topical anaesthesia**

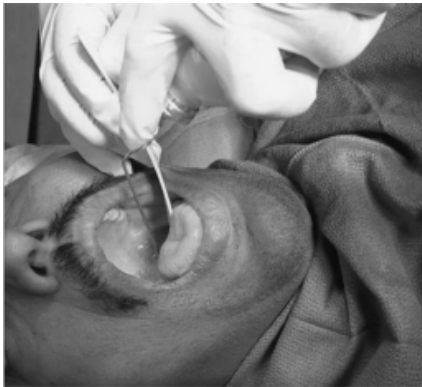**1. Topicalization** is the simplest method for anaesthetizing the airway. Topicalization of the airway is the spreading of local anaesthetic over a region of mucosa to achieve local uptake and neural blockade of that region

**2. Local anaesthetic can be sprayed**<sup>12</sup> directly onto the desired mucosa. (Fig 4) (Pressurized solution of benzocaine, tetracaine, and butamben in a small canister, delivers a spray via a long spray nozzle pointed in the desired direction. (being oily its absorbed easily). Alternatively, a 10-mL syringe can be filled with lidocaine 2-4% and sprayed via a small-bore single or multiperforated catheter or the working channel of the fiberoptic bronchoscope.)

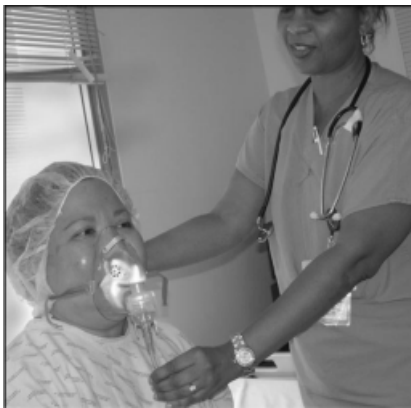**3. Nebulization** of lidocaine 2-4% via face mask or oral nebulizer for 15-30 minutes can achieve highly effective anaesthesia of the oral cavity and trachea for intubation. (Fig 5). The major advantage of this technique lies in its simplicity and lack of discomfort. In addition, very little working knowledge of the anatomy of the region is required for its successful implementation

**4. Atomization**<sup>12,18</sup> is ideal for airway topicalization during nasotracheal intubations.

**5. Density of anaesthesia** is variable and often requires supplementation to facilitate intubation. Some



**Fig 4 Local anesthetic can be sprayed directly onto the Desired mucosa.**



**Fig 5 Nebulization of lidocaine 2–4% via face mask**

patients may have intact cough reflex making intubation difficult. Rate of onset is highly dependant on patient compliance. deep breaths may also lead to CNS depression in previously diseased patients .

6. Anaesthetic-soaked cotton pledgets<sup>12,18,24,26,27</sup> or swabs can be applied to targeted mucosal surfaces for 5-15minutes to effect selective blockade of underlying nerves. These are soaked in either viscous or aqueous solutions of local anesthetic The cotton acts as a reservoir for the anesthetic agent, producing a dense block. This technique is especially effective in the nasal passages. Cotton-tipped swabs soaked in either lidocaine or cocaine and placed superiorly and posteriorly in the nasopharynx to block the branches of the ethmoidal and trigeminal nerves. Bilateral nasal administration of anaesthetic provides partial posterior pharyngeal anaesthesia by affecting the Sphenopalatine nerve fibers, thus diminishing the gag reflex.

7. Vasoconstrictors such as epinephrine (1:200,000) or phenylephrine (0.05%) can be added to the solution to

1. To prolong the duration of nerve blocks

2. Causes mucosal vasoconstriction, which improves visualization during the procedure and helps limit bleeding.

Topical nasal vasoconstrictors<sup>28-30</sup>

1. Neosynephrine

- Adults (~\_12 yr): 0.25-0.5%, 2-3 sprays in each nostril

- Children (6-12 yr): 0.25%, 2-3 sprays in each nostril

- Infants (<6 too): 0.16%, i-2 drops in each nostril

2 Xylometazoline

- Adults: 0.1%, 1-2 sprays or I metered dose spray or 2-3 drops in each nostril

- Children (>6 yr): 0.05%, 1-2 sprays or 2-3 drops in each nostril

- Children (<6 yr): 0.05%, 1 spray or I drop in each nostril

3.Oxymetazoline

- Adults and children >6 yr: 0.05%, 2-3 sprays or drops in each nostril

- Children (2-5 yr): 0.025%, 2-3 drops in each nostril

8. Gargling often does not cover the larynx or trachea adequately.

### **Techniques for Block Individual Nerves of the Airway**

Often more difficult to perform, and carry a higher risk of complications than the above mentioned methods. The common complications of nerve blocks are: bleeding, nerve damage, and intra-vascular injection.

## Nerve blocks

There are 3 blocks used for upper airway anesthesia:

1. Glossopharyngeal block – for oropharynx.
2. Superior laryngeal block – larynx above the cords.
3. Translaryngeal block – larynx and trachea below the cords.

### Blockade of the Glossopharyngeal Nerve

It provides sensory innervation to the posterior third of the tongue, the vallecula, the anterior surface of the epiglottis (lingual branch), the walls of the pharynx (pharyngeal branch), and the tonsils (tonsillar branch)<sup>31</sup>

Facilitates endotracheal intubation by blocking the gag reflex associated with direct laryngoscopy as well as facilitating passage of a nasotracheal tube through the posterior pharynx. Glossopharyngeal nerve block is not adequate as a solo technique to facilitate intubation, but in combination with other techniques it is highly effective.

### Blockade of the Glossopharyngeal Nerve

It can be blocked using one of three methods:

1. Topical spray application,
2. Direct mucosal contact of soaked pledgets, or
3. Direct infiltration by injection.

### Glossopharyngeal block

There are two way to approach:

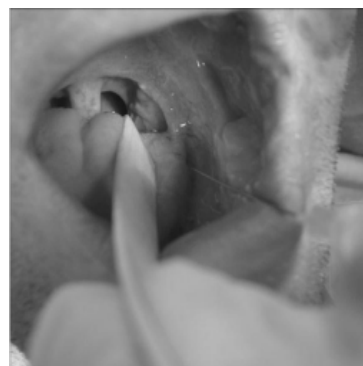1. Intra-oral – need enough mouth opening (Fig 6)

It is most easily blocked Intraorally by instilling 5 mL LA submucosally (by a 22-gauge needle) at the caudal aspect of the posterior tonsillar pillar (where it crosses the palatoglossal arch).

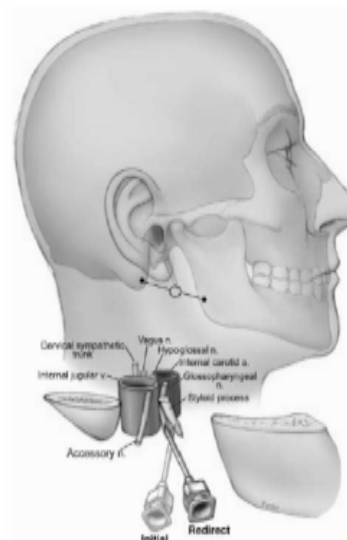
2. Peristyloid – require the ability to distinguish the bony landmarks (Fig 7)

Patient is placed supine and a line is drawn between the angle of the mandible and the mastoid process. Using deep pressure, the styloid process is palpated just posterior to the angle of the jaw along this line, and a short, small-gauge needle is seated against the styloid process. The needle is then withdrawn slightly and directed posteriorly off the styloid process. As soon as bony contact is lost, 5–7 mL of local anesthetic solution are injected after careful aspiration for blood.

For both approaches, careful aspiration for blood must be carried out prior to injection (to prevent inadvertent intravascular injection) because the glossopharyngeal nerve is closely associated with the internal carotid a. & palatoglossal



**Fig 6 Glossopharyngeal block (Intraoral approach).**



**Fig 7 Glossopharyngeal block (Peristyloid approach)**

arch is highly vascular and even a very small amount of local anesthetic can cause seizures.

Contraindicated in patients with coagulopathies or anticoagulation.

### Superior laryngeal block (Fig 8)

Internal branch<sup>12,32</sup> (originates from the superior laryngeal nerve lateral to the greater cornu of the hyoid bone. The nerve should pass approximately 2–4 mm inferior to the greater cornu of the hyoid bone, where it pierces the thyrohyoid membrane and travels under the mucosa in the pyriform recess.) innervates the base of the tongue, posterior surface of the epiglottis, aryepiglottic fold, and the arytenoids<sup>33</sup>

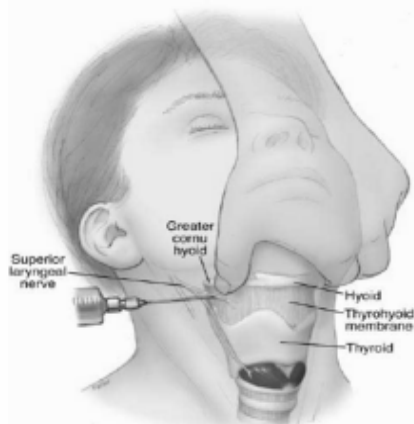


Fig 8 Superior laryngeal block

Blockade is usually inadequate as a solo technique for intubation. The superior laryngeal nerve can be blocked in the pyriform fossa where it runs just deep to the mucosa by using Kraus or Jackson forceps to hold a cotton pledget soaked in lidocaine 2–4% against the mucosa for about 60 sec<sup>12,24,26,27</sup>. Alternatively, this block can be performed using an external approach to the nerve as it penetrates the thyrohyoid membrane near the greater cornu of the hyoid<sup>26,34</sup> Direct infiltration is accomplished by a 25G needle at the level of the thyrohyoid membrane inferior to the cornu of the hyoid bone<sup>33,35</sup>. A reliable block with a definite endpoint is effected by retracting the needle marginally after contacting the greater cornu and injecting 2mL of LA (2% lidocaine) after negative aspiration in extended neck position.

The hyoid bone can be easily fractured if excess pressure is applied. 2 ml of LA should reliably bathe the internal branch of the superior laryngeal nerve, given at its proximity to the hyoid bone. If this volume is injected outside the thyrohyoid membrane, it is likely to block the external branch of the superior laryngeal nerve as well. Isolated external branch blockade may result in cricothyroid muscle weakness, which eliminates its function as an airway dilator. The motor input of the recurrent laryngeal nerve is spared, however, and therefore does not result in clinically significant change in laryngeal inlet diameters.

In case of contraindications, unwillingness or distorted anatomy noninvasive blockade can be accomplished by placing anesthetic-soaked cotton pledgets into the pyriform fossae bilaterally (for 10–15 min).

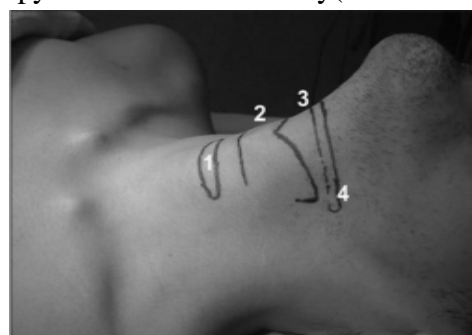


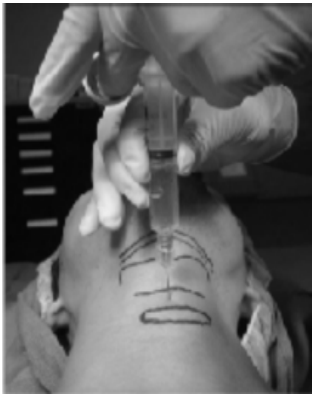
Fig 9 Normal surface anatomy of Larynx:1) cricoid cartilage 2) thyroid cartilage 3) hyoid bone 4) cornu of hyoid

### Recurrent Laryngeal Nerve Block (Fig 10)

Recurrent laryngeal nerve provides sensory innervation to the trachea and vocal folds. Blockade facilitates comfortable passing of the endotracheal tube into the trachea.

This nerve can be blocked by using topicalization techniques described previously.

Translaryngeal block of the recurrent laryngeal nerve is easily accomplished at the level of the cricothyroid membrane. A 10-mL syringe with a 22- or 20-gauge needle is advanced until air is aspirated into the syringe. 4ml of LA (4% lidocaine) are then injected, inducing coughing that disperses the local anesthetic.



**Fig 10 Recurrent Laryngeal Nerve Block**  
Translaryngeal block of the recurrent laryngeal nerve at the level of the cricothyroid membrane.

The recurrent laryngeal nerve can also be blocked by spraying local anesthetic via the injection port of the fiberoptic bronchoscope. Motor function remains completely unaffected. Direct infiltration of recurrent laryngeal nerve is contraindicated as it may cause upper airway obstruction since all motor supply to larynx except cricothyroid is by recurrent laryngeal nerve.

### **Blockade of the Palatine Nerves**

Nasal intubation requires blockade of the nasal passages.

Blockade of the greater and lesser palatine nerves blocks sensation to the nasal turbinates and posterior two thirds of the nasal septum. Topicalization of these structures is typically effective for intubation. Alternatively, the pterygopalatine ganglion can be blocked by passing a local anaesthetic-soaked cotton applicator along the upper border of the middle turbinate to the posterior wall of the nasopharynx, where it is left for 5–10 minutes. Transoral and percutaneous approaches to the pterygopalatine ganglion can be accomplished, but technical difficulty and an increased potential for complications preclude their routine use.<sup>36</sup>

### **Blockade of the Anterior Ethmoid Nerve**

The anterior ethmoid nerve innervates the remainder of the nasal passage. Anesthetic soaked cotton applicator is passed along the dorsal surface of the nose until the anterior cribriform plate is reached to achieve selective blockade after 5–10 minutes.

Theoretically, in high-risk situations, administration of local anaesthesia to the larynx and trachea may predispose to aspiration by obtunding protective airway reflexes.<sup>27,34</sup> However, these techniques have been used in these circumstances without associated aspiration,<sup>30,37,38</sup> and the relative risk must be weighed against those associated with other airway management modalities. A common sense approach using good clinical judgement is mandatory

A combination of techniques is required to adequately anaesthetise upper airway structures for awake intubation. The widest coverage is provided by the inhalational technique. This technique, however, does not always provide a dense enough level of anaesthesia for all patients. Supplementation of this technique with any of the specific nerve blocks is an excellent way to accomplish efficacious anaesthesia for awake intubation.<sup>39</sup> by laryngoscopic or fiberoptic method<sup>40</sup>.

### **References**

1. Benumof J. Management of the difficult adult airway. With special emphasis on awake tracheal intubation. *Anesthesiology* 1991; 75:1087–110.
2. Popat M. State of the art. The airway. *Anaesthesia* 2003; 58:1166–72.
3. An Updated Report by the ASA Task Force on Management of the Difficult Airway. Practice guidelines for the management of the difficult airway. *Anesthesiology* 2003; 98: 1269–77.
4. Ovassapian A, Yelich SJ, Dykes MHM, Brunner EE. Blood pressure and heart rate changes during awake fiberoptic nasotracheal intubation. *Anesth Analg* 1983; 62: 951–4.
5. Sutherland AD, Williams RT. Cardiovascular responses and lidocaine absorption in fiberoptic-assisted awake intubation. *Anesth Analg* 1986; 65: 389–91.
6. Hawkyard SJ, Morrison A, Doyle LA, Croton RS, Wake PN. Attenuating the hypertensive response to laryngoscopy and endotracheal intubation using awake fiberoptic intubation. *Acta Anaesthesiol Scand* 1992; 36: 1–4.
7. Telford R J, Liban JB. Awake fiberoptic intubation. *Br J Hosp Med* 1991; 46: 182–4.
8. Ovassapian A, Yelich S J, Dykes MHM, Brunner EE. Blood pressure and heart rate changes during awake fiberoptic nasotracheal intubation. *Anesth Analg* 1983; 62:951-4.

9. Ovassapian A, Krejcie TC, Yelich S J, Dykes MHM. Awake fiberoptic intubation in the patient at high risk of aspiration. *Br J Anaesth* 1989; 62: 13-6.
10. Raj PP, Foresmer J, Watson TD, Morris RE, Jenkins MT. Technics for fiberoptic laryngoscopy in anesthesia. *Ancsth Analg* 1974; 53: 708-13.
11. Reed AP, Han DG. Preparation of the patient for awake fiberoptic intubation. *Anesthesiology Clinics of North America* 1991; 9: 69-81.
12. Morris IR. Pharmacologic aids to intubation and the rapid sequence induction. *Emerg Med Clin North Am* 1988; 6:753-68.
13. Faccenda KA, Finucane BT: Complications of regional anaesthesia: Incidence and prevention. *Drug Saf* 2001;24:413-442.
14. Auroy Y, Narchi P, Messiah A, et al: Serious complications related to regional anesthesia: Results of a prospective survey in France. *Anesthesiology* 1997;87:479-486.
15. Naguib M, Magboul MM, Samarkandi AH, Attia M: Adverse effects and drug interactions associated with local and regional anaesthesia. *Drug Saf* 1998;18:221-250.
16. Cotter JT, Nielsen KC, Guller U, et al: Increased body mass index and ASA physical status IV are risk factors for block failure in ambulatory surgery: An analysis of 9,342 blocks. *Can J Anaesth* 2004;51:810-816.
17. Crosby ET, Lui A. The adult cervical spine: implications for airway management. *Can J Anaesth* 1990; 37: 77-93.
18. Morris IR. Techniques of endotracheal intubation and muscle relaxation. In: Rosen P (Ed.). *Emergency Medicine: Concepts and Clinical Practice*, 2nd ed., St. Louis: The CV Mosby Co., 1988; 69-82.
19. Morris IR. Airway management. In: Rosen P (Ed.). *Emergency Medicine: Concepts and Clinical Practice*, 3rd ed., St. Louis: Mosby Yearbook, 1992: 79-105.
20. Dripps RD, Eckenhoff JE, VanDam L1) *Introduction to Anesthesia: The Principles of Safe Practice*, 6th ed. Philadelphia: WB Saunders Co., 1982.
21. Ritchie JM, Greene NM. Local anesthetics. In: Gilman AG, Goodman LS, Gilman A (Eds.). *Goodman and Gilman's The Pharmacological Basis of Therapeutics*, 6th ed., New York: MacMillan Publishing Co., 1980; 300-20.
22. Atkinson RS, Rushman GB, Lee JA. *A Synopsis of Anaesthesia*, 8th ed. Bristol, UK: John Wright and Sons Ltd., 1977.
23. Donlon JV Jr. Anesthesia for eye, ear, nose, and throat surgery. In: Miller RD (Ed.). *Anesthesia*, 2nd ed., New York: Churchill-Livingstone, 1986; 1837-94.
24. Snow JC. *Manual of Anesthesia*. Boston: Little Brown & Co., 1977.
25. Sutherland AD, Williams RT. Cardiovascular responses and lidocaine absorption in fiberoptic-assisted awake intubation. *Anesth Analg* 1986; 65: 389-91.
26. Reed AP, Han DG. Preparation of the patient for awake fiberoptic intubation. *Anesthesiology Clinics of North America* 1991; 9: 69-81.
27. Donlon JV. Anesthetic management of patients with compromised airways. *Anesthesiology Reviews* 1980; 7: 22.
28. Kleeman P-P, Jantzen J-PAH, Bonfils T?. The ultra-thin bronchoscope in management of the difficult paediatric airway. *Can J Anaesth* 1987; 34: 606-8.
29. Hill 1-1, Calder/. Safer fiberoptic intubation (Letter). *Anaesthesia* 1988; 43: 1062.
30. Krogh CME (Ed.) *Compendium of Pharmaceuticals and Specialties*, 29th ed., Ottawa, Canada: Canadian Pharmaceutical Association, 1994.
31. Netter F: *Atlas of Human Anatomy*. Ciba-Geigy Corporation, 1989, Plate 56.
32. Morris IR. Functional anatomy of the upper airway. *Emerg Med Clin North Am* 1988; 6: 639-69.
33. Netter F: *Atlas of Human Anatomy*. Ciba-Geigy Corporation, 1989, Plates 37-40.
34. Gotta AW, Sullivan CA. Superior laryngeal nerve block: an aid to intubating the patient with fractured mandible. *J Trauma* 1984; 24: 83-5.
35. Wheatley JR, Brancatisano A, Engel LA: Respiratory-related activity of cricothyroid muscle in awake normal humans. *J Appl Physiol* 1991;70:2226-2232.
36. Reasoner DK, Warner DS, Todd MM, et al: A comparison of anesthetic techniques for awake intubation in neurosurgical patients. *J Neurosurg Anesthesiol* 1995;7:94-99.
37. Kopman AF, Wallman SB, Ross K, Surks SN. Awake endotracheal intubation: a review of 267 cases. *Anesth Analg* 1975; 54: 323-7.
38. Meschino A, Devitt JH, Koch J-P, Szalai JP, Schwartz ML. The safety of awake tracheal intubation in cervical spine injury. *Can J Anaesth* 1992; 39: 114-7.
39. Reasoner DK, Warner DS, Todd MM, et al: A comparison of anesthetic techniques for awake intubation in neurosurgical patients. *J Neurosurg Anesthesiol* 1995;7:94-99.
40. Ovassapian A. Fiberoptic tracheal intubation in adults. In: Ovassapian A (Ed). *Fiberoptic Endoscopy and the Difficult Airway*, 2<sup>nd</sup> ed. New York: Lippincott-Raven.