

A case of incidentally discovered solitary fibrous tumor of the kidney: A case study

LUIGI DE LUCA^{1*}, MASSIMILIANO CRETA^{1*}, BIAGIO BARONE¹, FELICE CROCETTO¹, MIRIAM CIERI², MARIA RAFFAELA CAMPANINO², LUIGI INSABATO², FRANCESCO MANGIAPIA¹, FERDINANDO FUSCO³, CIRO IMBIMBO¹, VINCENZO MIRONE¹ and NICOLA LONGO¹

Departments of ¹Neuroscience, Reproductive Sciences and Odontostomatology and ²Advanced Biomedical Sciences, University of Naples Federico II; ³Department of Woman, Child and General and Specialized Surgery, Urology Unit, University of Campania 'Luigi Vanvitelli', I-80123 Naples, Italy

Received February 29, 2020; Accepted June 25, 2020

DOI: 10.3892/mco.2020.2109

Abstract. Solitary fibrous tumor (SFT) is a rare neoplasm of mesenchymal origin. The kidney represents an unusual location for SFT and the diagnosis and treatment of renal SFT remains challenging. The present study reports the case of a right kidney SFT incidentally discovered in a 52-year old woman. Radiological findings from computed tomography and magnetic resonance imaging were not specific but highly suspect for a malignant neoplasm. The definitive diagnosis relied on histological examination and immunohistochemical staining for CD34 and signal transducer and activator of transcription 6.

Introduction

Solitary fibrous tumor (SFT) represent rare tumors of mesenchymal origin and account for < 2% of all soft tissue tumors (1,2). The etiology of SFT remains unknown (1). Commonly, they are slow-growing tumors with a favorable prognosis. However, cases with malignant features have been described (3). Although SFT may be found in any site of the body, the most common location is the thorax (1). The kidney represents an unusual location for SFT and both diagnosis and treatment of renal SFT remains challenging. Clinically, these tumors remain asymptomatic for long time. Moreover, radiologic features are not specific and renal SFT are usually diagnosed as renal cell carcinoma (RCC) and managed

as such (2). Currently, there are no clear evidence-based guidelines for the diagnostic and therapeutic management of these tumors, and radical nephrectomy is the treatment of choice preferred by most authors. Definitive diagnosis is based on histological evaluation and immunohistochemical investigations are often required to confirm the diagnosis. Recently, the use of immunohistochemistry for signal transducer and activator of transcription 6 (STAT6) has been introduced and has been showed to be highly sensitive and specific for SFTs (4). To date, STAT6 immunoreactivity has been reported only in few cases of SFT of the kidney (3). We describe a case of a renal SFT incidentally discovered in a 52-year-old female characterized by STAT6 immunoreactivity.

Case report

A 52-year-old woman presented to our outpatient department for a routinely screening visit. She denied pain, fewer, lower urinary tract symptoms, and hematuria. Medical history was relevant for arterial hypertension, chronic obstructive pulmonary disease, and intestinal polyposis. She smoked 25 cigarettes a day. Physical examination and laboratory data failed to reveal pathological findings. An abdominal ultrasound was required showing a 7-cm hypoechoic lesion involving the right kidney. A contrast-enhanced abdominal computed tomography (CT) confirmed the presence of an inhomogeneous, 7x6 cm solid lesion involving the lower pole of the right kidney. The mass was well-circumscribed and contained areas of enhancement. There was no CT evidence of vascular invasion, lymph nodes involvement or metastases. The mass compressed the lower calyceal system and caused obstruction of the upper calyces with subsequent hydrocalyx (Fig. 1A). The left kidney was characterized by a 12-cm simple cystic lesion. On a subsequent Magnetic Resonance Imaging (MRI), the lesion involving the right kidney appeared as solid, isointense on T1-weighted images and inhomogeneous in T2-weighted images with suspect hemorrhagic foci. The lesion was highly hypervascular without significant wash-out of contrast medium. No significant intralésional adipose tissue was detected. Overall, CT and MRI imaging were judged as atypical, but highly suspect for a malignant

Correspondence to: Professor Massimiliano Creta, Department of Neuroscience, Reproductive Sciences and Odontostomatology, University of Naples Federico II, Via Sergio Pansini 5, I-80123 Naples, Italy

E-mail: max.creta@gmail.com

*Contributed equally

Key words: computed tomography, immunohistochemistry, MRI, renal cell carcinoma, solitary fibrous tumor

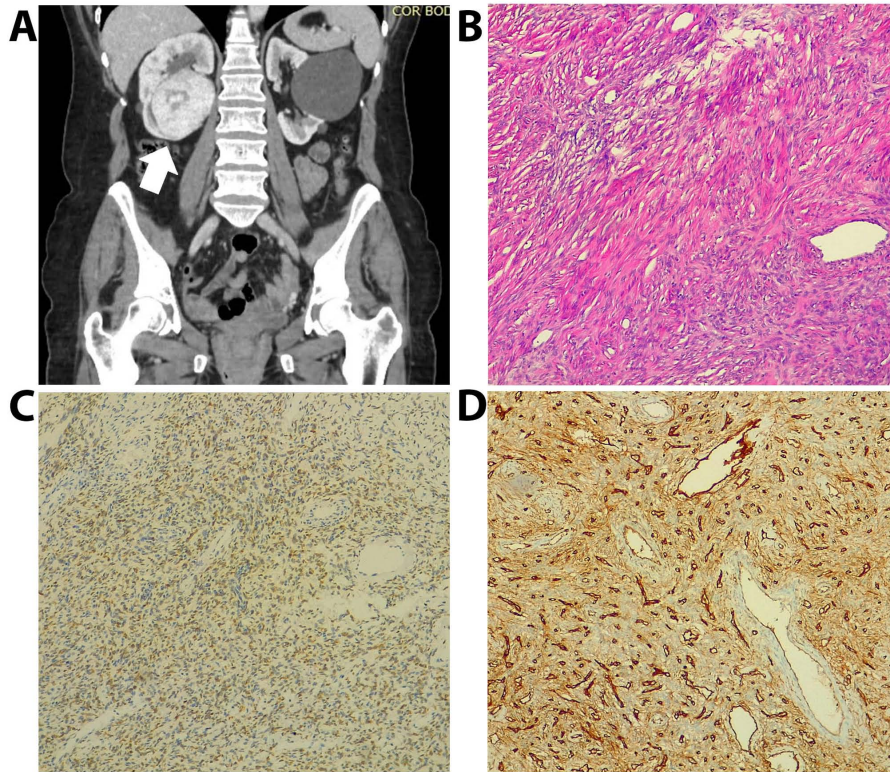


Figure 1. (A) coronal contrast-enhanced CT scan showing a heterogeneous enhancing mass involving the lower pole of the right kidney (arrow). (B) Hematoxylin/eosin staining (magnification, x40) showing a proliferation composed of long spindle cell with acidophilic cytoplasm and vesicular nuclei, with alternating hypo and hypercellular areas, storiform, fascicular and hemangiopericytoma like growth pattern. (C) Immunohistochemical staining (magnification, x40) revealing vascular endothelial cell reactivity for CD34. (D) Immunohistochemical staining (magnification, x40) revealing diffuse nuclear positivity for STAT6. STAT6, signal transducer and activator of transcription 6.

neoplasm. A Tc99m-DTPA renal scan revealed a glomerular filtration rate of 44.95 ml/min and of 84.98 ml/min on the right, and left kidney, respectively. The patient underwent a right laparoscopic radical nephrectomy. The intra- and postoperative course was uneventful and the patient was discharged home on postoperative day 8. Macroscopic examination showed a well circumscribed, white, firm tumor confined to the lower pole which measuring cm 7.4x6.3x5.8. There was no macroscopic capsular involvement. Formalin-Fixed Paraffin- Embedded tissue specimens, mounted in a thin layer on a microscope slide covered with a jet cover 75 by 26 mm and approximately 1 mm thick), and observed under a microscope. Microscopic examination showed a well mesenchymal neoplasm surrounded by fibrous tissue occasionally separated by strip-like bands of collagen. The proliferation was composed of long spindle cell with acidophilic cytoplasm and vesicular nuclei, round to oval, organized in a patternless architecture with a combination of alternating hypocellular and hypercellular areas separated from each other by thick bands of hyalinized collagen. It also showed a thick-walled vessel. Mitotic activity was irrelevant and mild atypia was observed. There was no evidence of necrosis. Immunohistochemical staining showed reactivity for CD34 and for STAT6. These findings established the positive diagnosis of SFT of the kidney (Fig. 1B-D).

Discussion

SFT of kidney represent a rare entity that poses diagnostic and therapeutic challenges (5-7). To date, a total of 56 SFT of the

kidney have been reported worldwide (5). Median age at the diagnosis is 51 years (range: 4-85) and the incidence has been reported to be higher in female subjects (7). Although about 15% of SFT of the kidney have been reported to be located in the renal capsule and 3% in the renal pelvis, the site of origin remains unknown in the majority of cases (5). The majority of SFT of the kidney are benign with about 14% of cases exhibiting malignant behavior (6,7). Like RCC, most of these tumors are asymptomatic and are incidentally discovered on radiologic evaluations. Mean tumor size at the diagnosis is 7.6 cm (range 2-20 cm) (7). Unfortunately, imaging features of renal SFT are non-specific. Indeed, CT may reveal findings such as heterogeneous enhancement, areas of necrosis, and calcifications while MRI features are highly variable. In some cases, MRI can help in the detection of fibrosis and dense collagen content as low signal intensity on T2-weighted images (1). However, these features overlap with other renal neoplasm such as papillary RCC (1). The clinical case we describe corroborates existing evidences about the diagnostic challenges associated with clinical and radiological diagnosis of SFT of kidney. Interestingly, the lesion we described was isointense to the kidney in T1 weighted image and had heterogeneous intensity in T2 weighted image. This uncommon finding was also described by Zaghbib *et al* (2). Currently, renal biopsy is indicated before ablative therapy and systemic therapy without previous pathology and in select patients who are considering active surveillance. To date there are no evidences about the role of renal biopsy in patients with SFT of the kidney. Consequently, as in the present case,

the definitive diagnosis of SFT of the kidney is commonly performed after histological and immunohistochemical examination of the surgical specimen. Histologically SFT are mesenchymal neoplasms with fibroblastic features that can be defined as cellular or fibrous based on the predominant histopathologic pattern (1). The differential diagnosis of SFT of the kidney mainly includes angiomyolipoma, fibromas, fibrosarcomas, and sarcomatoid variant of RCC (6). Typically, a strong CD34 immunocytochemical reactivity is found in the fibrous variant (1). However, this marker lacks specificity. In recent years, sequencing studies on SFT lead to the identification of an intrachromosomal inversion-derived gene fusion juxtaposing the neighboring NGFI-A binding protein 2 (NAB2) gene and STAT6 gene on 12q13 (8).

NAB2-STAT6 fusion is considered an initiating pathogenomic event in both benign and malignant SFT. STAT6 immunoreactivity has recently been found to be a more sensitive and specific marker for SFT, helpful when diagnosis is controversial (3). To date, however, the prognostic role of NAB2-STAT6 fusion deserves further investigations (8). To date, no clear evidence-based guidelines for the management of SFT of the kidney exist. Surgical resection is the mainstay of therapy of SFT involving the kidney (6). The role of nephron-sparing surgery in patients with SFT of the kidney is unclear and, currently, the standard treatment is radical nephrectomy due to the malignant potential associated with the disease and lack of recurrence after radical surgery (1,5).

Although most renal SFTs are benign, the behavior of renal SFTs is unpredictable and long-term follow-up is advocated (1).

SFT of the kidney is a rare clinic-pathological entity characterized by challenging diagnostic work-up. Immunostaining for CD34 and STAT6 are useful diagnostic tools.

Acknowledgements

Not applicable.

Funding

No funding was received.

Availability of data and materials

Not applicable.

Authors' contributions

LDL, MaC, FC, BB, CI, VM, NL analyzed and interpreted the clinical patient data. MaC drafted the manuscript. FM and FF were involved in revising it critically for important intellectual content. LI, MiC, MRC performed the histological examination of the kidney. All authors read and approved the final manuscript.

Ethics approval and consent to participate

The patient provided written informed consent for the publication data and images.

Patient consent for publication

The patient provided written informed consent for the publication data and images.

Competing interests

The authors declare that they have no competing interests.

References

1. Fursevich D, Derrick E, O'Dell MC, Vuyyuru S and Burt J: Solitary fibrous tumor of the kidney: A case report and literature review. *Cureus* 8: e490, 2016.
2. Zaghbib S, Chakroun M, Essid MA, Saadi A, Bouzouita A, Derouiche A, Slama MR, Ayed H and Chebil M: Solitary fibrous tumor of the kidney: A case report. *Int J Surg Case Rep* 62: 112-114, 2019.
3. Yang Y, Miller CR, Clement C, Hes O and Eyzaguirre E: Malignant solitary fibrous tumour of the kidney with lymph node and liver metastases: Beware of STAT6 expression in dedifferentiated liposarcoma with a solitary fibrous tumour-like morphology: Author reply. *Pathology* 49: 671-672, 2017.
4. Geramizadeh B, Marzban M and Churg A: Role of immunohistochemistry in the diagnosis of solitary fibrous tumor, a review. *Iran J Pathol* 11: 195-203, 2016.
5. Kopel J, Sharma P and Warriach I: A solitary fibrous tumor of the kidney. *Urol Case Rep* 28: 101072, 2019.
6. Wang H, Liao Q, Liao X, Wen G, Li Z, Lin C and Zhao L: A huge malignant solitary fibrous tumor of kidney: Case report and review of the literature. *Diagn Pathol* 9: 13, 2014.
7. Cuello J and Brugués R: Malignant solitary fibrous tumor of the kidney: Report of the first case managed with interferon. *Case Rep Oncol Med* 2013: 564980, 2013.
8. Tai HC, Chuang IC, Chen TC, Li CF, Huang SC, Kao YC, Lin PC, Tsai JW, Lan J, Yu SC, *et al*: NAB2-STAT6 fusion types account for clinicopathological variations in solitary fibrous tumors. *Mod Pathol* 28: 1324-1335, 2015.



This work is licensed under a Creative Commons Attribution-NonCommercial-NoDerivatives 4.0 International (CC BY-NC-ND 4.0) License.