

Available online at www.sciencedirect.com

ScienceDirect

journal homepage: www.elsevier.com/locate/radcr

Case Report

Stent implantation in a patient with non-hemorrhagic vertebral artery dissection associated with severe, continuously progressive stenosis in the posterior inferior cerebellar artery bifurcation region: A case report [☆]

Akio Nishino, MD, PhD*, Motoki Nakamura, MD, Katsuhiko Nakanishi, MD, Eiji Kohmura, MD, PhD

Department of Neurosurgery, Kinki Central Hospital, 3-1 Kurumazuka, Itami-city, Hyogo, Japan

ARTICLE INFO

Article history:

Received 13 July 2022

Revised 28 July 2022

Accepted 31 July 2022

Keywords:

Vertebral artery dissection

Non-hemorrhagic dissection

Posterior inferior cerebellar artery

Enterprise VRD stent

Endovascular treatment

ABSTRACT

Generally, the prognosis of non-hemorrhagic vertebral artery dissection is good. Treatment should be considered when stenosis progresses or when an aneurysm is formed. However, no clear treatment policy has been established. The purpose of this case report was to describe the treatment policy for non-hemorrhagic onset vertebral artery dissection with severe stenosis around the posterior inferior cerebellar artery (PICA) bifurcation and aneurysm, where stent placement in the vertebral artery was difficult. This report describes healing without complications with stent implantation in the PICA performed to treat non-hemorrhagic vertebral artery dissection with associated severe, continuously progressive stenosis in the PICA bifurcation region. A 36-year-old woman was examined at the authors' hospital for persistent pain in the left posterior neck. Left vertebral arteriography revealed stenosis due to dissection around the PICA bifurcation and aneurysm formation at the distal position. Due to the progression of stenosis, there were concerns about PICA occlusion, and stent implantation in the vertebral artery was performed via the PICA. Neck pain ceased immediately after surgery, and 3 months later, cerebral angiography showed favorable patency of the PICA and decreased aneurysm size. This case suggests that stent implantation in the PICA might be a useful treatment option for non-hemorrhagic vertebral artery dissection with associated severe stenosis in the PICA bifurcation region.

© 2022 The Authors. Published by Elsevier Inc. on behalf of University of Washington.

This is an open access article under the CC BY-NC-ND license

(<http://creativecommons.org/licenses/by-nc-nd/4.0/>)

[☆] Competing Interests: None of the authors or co-authors of the present report have conflicts of interest that have to be reported.

* Corresponding author.

E-mail address: nishino_a@kich.itami.hyogo.jp (A. Nishino).

<https://doi.org/10.1016/j.radcr.2022.07.114>

1930-0433/© 2022 The Authors. Published by Elsevier Inc. on behalf of University of Washington. This is an open access article under the CC BY-NC-ND license (<http://creativecommons.org/licenses/by-nc-nd/4.0/>)

Introduction

Generally, vertebral artery dissection with a non-hemorrhagic onset has a favorable prognosis. However, with the progression of the condition, patients sometimes suffer from cerebral infarction or subarachnoid hemorrhage [1,2]. The patient's condition started with persistent pain in the left posterior neck, and cerebral angiography showed severe progressive stenosis of the vertebral artery around the left posterior inferior cerebellar artery (PICA) bifurcation, complicated by a dissecting aneurysm distal to the stenosis, which was treated by stent implantation in the PICA via the vertebral artery, resulting in alleviation of stenosis and aneurysm size reduction. It seems common to place a stent in stenosis of the vertebral artery, and coil embolization is added to the aneurysm. However, because the vertebral artery was severely stenotic and it was difficult to place a stent, it was possible to improve the stenosis and reduce the aneurysm by placing a stent in the PICA and reducing the load on the aneurysm.

There is no definitive treatment policy for non-hemorrhagic arterial dissection with imaging deterioration, and we hope the current report will support the future definition of such a treatment policy.

Case report

Case presentation

A 36-year-old woman with no medical history suddenly developed pain in the left posterior neck 1 week before the initial examination at the authors' hospital, and received oral, commercially available analgesics (loxoprofen 60 mg several times a day). However, the pain was not alleviated, and she was examined by a local physician. Cranial magnetic resonance imaging (MRI) showed that the left vertebral artery had an irregular diameter, and vertebral artery dissection was suspected. Therefore, the patient was referred to our hospital.

Magnetic resonance angiography (MRA) showed that the left vertebral artery close to the PICA bifurcation was irregular in diameter. Spindle-shaped vasodilation was also observed in the right vertebral artery (Fig. 1A). Fluid-attenuated inversion recovery (FLAIR) showed a high signal that was suspected to indicate an intramural hematoma and was consistent with the part of the left vertebral artery with an irregular diameter (Fig. 1B). Diffusion-weighted imaging revealed no clear cerebral infarction or hemorrhage (Fig. 1C). The patient was recommended to be hospitalized for thorough tests, but she did not consent. Therefore, observation was continued on an outpatient basis. Her systolic blood pressure was 100–120 mmHg, and no antihypertensive agents were prescribed.

Hospital admission

The patient's unbearably severe posterior neck pain persisted, and she was hospitalized for thorough testing on day 17 after the onset of neck pain. Cerebral angiography on the following day showed stenosis immediately before the PICA bifurcation of the left vertebral artery and severe stenosis and aneurysm formation immediately after that bifurcation. Slow blood flow was not found in the PICA, and the images were favorable to the peripheral vessels. The PICA had a large return flow region, and the anterior inferior cerebellar artery had not developed (Fig. 2A). Spindle-shaped vasodilation was observed immediately before PICA, even in the right vertebral artery (Fig. 3A). Bilateral vertebral artery dissection was suspected. However, no endogenous diseases, such as hypertension, dyslipidemia, or diabetes, were found, nor were any physical characteristics or family history suggestive of congenital diseases, such as Marfan syndrome or Ehlers-Danlos syndrome. In addition, no exogenous factors, such as cranial trauma, were present. Therefore, the cause of the condition was unknown. On day 29 after onset, cerebral angiography was performed again, and the stenosis progressed immediately before the left PICA bifurcation (Fig. 2B), and slow blood flow in the vertebral artery was observed. No clear neurological symptoms were found at this time, but the persistence of neck pain and progression of dissection meant that the risk of occlusion was high, and cerebroendovascular surgery was performed.

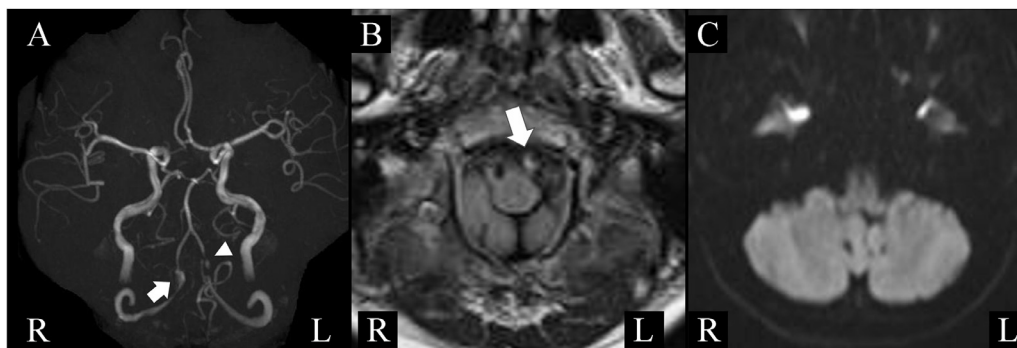


Fig. 1 – Initial head MRI. (A) MRA: Wall irregularity is observed in the left vertebral artery near the bifurcation of the posterior inferior cerebellar artery (arrow head). A fusiform aneurysm is observed in the right vertebral artery. (arrow). (B) FLAIR: High signal is observed in the left vertebral artery. (arrow). (C) Diffusion-weighted image: No obvious infarction is found in the brainstem and cerebellum. MRI, magnetic resonance imaging; MRA, magnetic resonance angiography; FLAIR, fluid-attenuated inversion recovery.

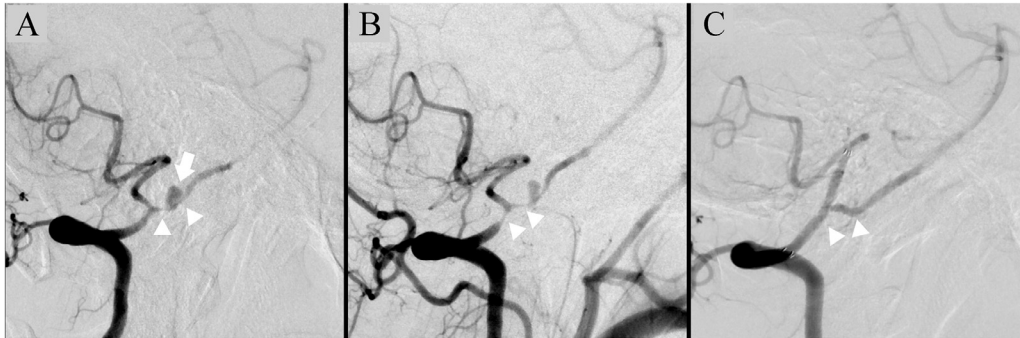


Fig. 2 – Lateral image of the left vertebral artery. (A) Day 18, (B) before stent placement (Day 27), (C) 3 months after surgery. (A): Narrowing of the vertebral artery (arrow heads) and distal aneurysm formation near the bifurcation of the left posterior inferior cerebellar artery (arrow) are observed. (B): Progression of vertebral artery stenosis is observed. (arrow heads) (C): Improvement of stenosis and disappearance of aneurysm are observed (arrow heads).

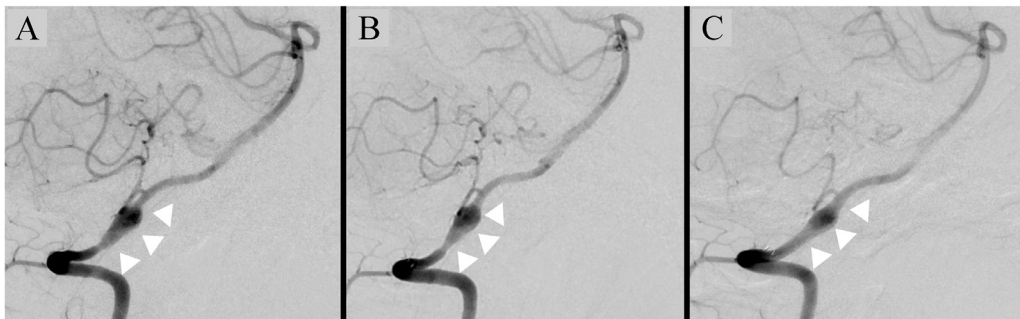

Fig. 3 – Lateral image of the right vertebral artery. (A) Day 18, (B) before stent placement (Day 27), (C) at 3 months after surgery. (A, B): Wall irregularity and fusiform aneurysm in the proximal part of the posterior inferior cerebellar artery are observed (arrow heads) (C): Improvement of wall irregularity and reduction of aneurysm are observed (arrow heads).

Cerebroendovascular surgery

A-4 Fr ASAHI FUBUKI Dilator Kit (Asahi Intecc Co., Ltd., Aichi, Japan) was implanted in the left vertebral artery. The PICA diameter was slightly less than 2 mm, and the vertebral artery diameter in the proximal part of the stenosis was 2.6 mm. As first-line treatment, the approach was stent implantation in the main trunk of the vertebral artery with stenosis and coil embolization in the dissecting aneurysm. However, vertebral artery stenosis was severely distal to the PICA. Even when attempts were made by introducing a micro-guidewire, it was difficult to make this pass the curves in the aneurysm-like dilated part. The option of retrograde treatment from the right vertebral artery via the confluence part was examined, but there was the potential for catheter operations to place a burden on the right vertebral artery aneurysm, as well as concerns about the risk of hemorrhage due to vascular perforation when passing the microguide wire through the stenosis.

The next approach was stent implantation in the PICA from the vertebral artery, thus ensuring blood flow to the PICA and suppressing entry to the dissection, and thus progression. This treatment method was also selected because it was hoped that by straightening the PICA from the vertebral artery, the inflow to the dissecting aneurysm would change, and this

method would effectively reduce the burden and risk of rupture.

A Prowler Select Plus (Cerenovus, Inc., Miami, FL, USA) was introduced to the distal side of the left PICA, and an Enterprise 2 VRD (4.0 × 23 mm; Cerenovus, Inc.) was extended to the vertebral artery (Fig. 4). Imaging after stent implantation showed decreased blood flow to the aneurysm distal to the vertebral artery, and imaging of the opposite vertebral artery showed an aneurysm due to retrograde blood flow via the confluence region. The aneurysm was non-hemorrhagic at onset, and it was judged that decreased blood flow to the aneurysm reduced the risk of rupture. Therefore, surgery was completed at that point, with the provision that coil embolization would also be performed if the aneurysm was to increase in size or change in shape later. As the patient's pain was localized on the left side, there was no need for rapid treatment in connection with the right vertebral artery aneurysm, and it was decided that the only treatment would be monitoring the patient's progression.

Postoperative progression and outcome

Pain in the left posterior neck showed clear alleviation immediately after surgery, and no clear nerve deficiency symptoms were present. Cranial MRI performed the following

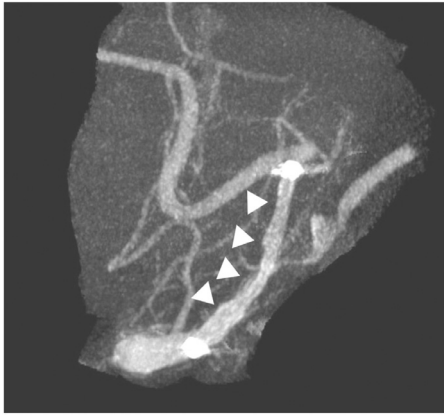

Fig. 4 – Cone-beam CT after stent placement. The stent was placed in the vertebral artery from the posterior inferior cerebellar artery, and straightening of the stent placement was observed (arrow heads). CT, computed tomography.

day showed no cerebral infarction or other treatment-related complications. Cerebral angiography 3 months after surgery showed favorable images of the PICA, vertebral artery stenosis was alleviated, and the aneurysm was almost absent in the images (Fig. 2C). The spindle-shaped aneurysm in the opposite vertebral artery also tended to decrease in size (Figs. 3B and C).

Discussion

Patients with the pearl-and-string sign, such as this patient, have been reported to have a high probability of configuration changes, resulting in more time being required for full recovery [3]. In addition, in the case of vertebral artery dissection at neck pain onset, the link between neck pain and dissection has been indicated [4]. In our patient, discomfort was persistent, suggesting progression of dissection. Therefore, treatment is necessary to suppress the progression of the dissection. The neck pain ceased immediately after the stent implantation. Therefore, it is considered that suppression of dissection progression by the treatment effectively alleviated the symptoms.

The reported treatment options for vertebral artery dissection include (1) proximal artery occlusion and (2) surgical anastomosis of the occipital artery (OA) and PICA, followed by trapping of the dissected part [5–7].

In this patient, proximal artery occlusion showed severe stenosis distal to the PICA and retrograde blood flow was not expected. Evaluation by the balloon occlusion test was considered. However, considering the potential for ischemic symptoms to occur with the progression of stenosis, this test was not performed even though ischemic symptoms were not present at the time of evaluation. There were also concerns about the increased burden on aneurysms in the opposite artery.

OA-PICA anastomosis has been reported to have a relatively high probability of cerebral infarction occurring as a

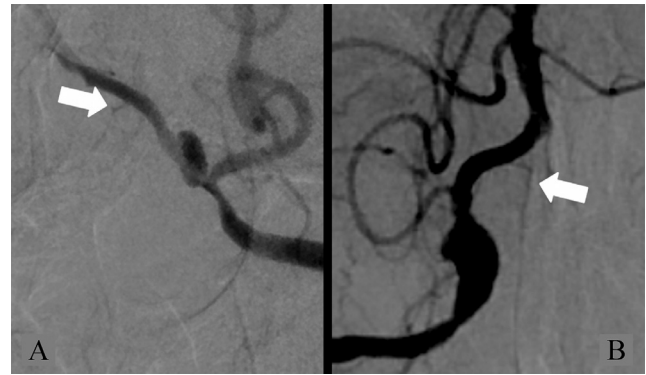


Fig 5 – Perforating branch from the vertebral artery (arrow). (A) Left vertebral artery oblique image. (B) Anteroposterior view of the right vertebral artery.

complication [7]. Therefore, this treatment was not considered optimal for this patient, who had non-hemorrhagic onset.

The treatment method used involves perforating branch injuries due to stent implantation. In the middle and lower parts of the medulla oblongata, perforating branches are distributed to complement each other from the vertebral artery and PICA [8]. Perforating branches from the vertebral artery frequently bifurcate from a position close to the confluence region of the vertebral artery distal to the PICA [9]. There is a high probability that these types of perforating branch occlusions induce Wallenberg syndrome or other neurological symptoms. In addition, an important branch of the vertebral artery is the anterior spinal artery. In this patient, left vertebral arteriography revealed a perforating branch reaching the brainstem from a site distal to the stenosis (Fig. 5A). Furthermore, imaging of the anterior spinal artery was performed primarily from the right vertebral artery (Fig. 5B). It was not possible to confirm a clear perforating branch from the stent implantation site, but there is also the potential for a perforating branch that cannot be confirmed by cerebral angiography to suffer occlusion due to stent implantation. Therefore, it is preferable for a stent containing relatively little metal to be selected. LVIS (Terumo Corporation, Tokyo, Japan), a braided stent, has a higher metal coverage rate (23%) than Enterprise 2 VRD, a laser-cut stent (8%) [10]. Increasing the metal coverage rate is expected to reduce stress on the aneurysm effectively.

Conversely, consideration must be given to the potential to induce thrombogenesis. This patient's PICA had a small diameter of 2 mm or less. Therefore, because of the high metal content of the LVIS, there were concerns about the occlusion of the stent or the above-mentioned perforating branch due to thrombogenesis. Several reports have shown Enterprise 2 VRD being used with blood vessels less than 2 mm in diameter [11–13]. Enterprise 2 VRD was selected for this patient.

There have recently been reports on the use of flow diverters in non-hemorrhagic vertebral artery dissections [14,15]. However, there have also been reports of stent occlusion and transient cranial nerve palsy when flow diverters were used [14]. Flow-diverters are a relatively new therapeutic technology, and the number of reports of their use for treating non-hemorrhagic vertebral artery dissection is not great. There-

fore, it will be necessary to investigate this indication more when more cases have accumulated.

In addition to the stents used to support aneurysm occlusion surgery, the Wingspan Stent System (Stryker Corporation, Kalamazoo, MI, USA) is used for arterial dissection as a complication of angioplasty. The wingspan has a 9-mm inner-body tip in the tip region, and this patient had a sharp curve in the PICA bifurcation region. Therefore, there were concerns about the leading tip placing a burden on the vascular wall in the area of the curve when the system was moved forward. In this respect, it was considered that Enterprise 2 VRD could be introduced using a microcatheter, placing little burden on the vascular wall.

Zenteno et al. reported the usefulness of stent-only treatment for vertebral artery stenosis [16]. In this case, aneurysm occlusion surgery planned initially was technically difficult. When rupture occurs, it is essential to achieve hemostasis promptly, but this patient showed non-hemorrhagic onset, and an effective reduction of the burden on the aneurysm was expected. Therefore, the only treatment performed was stent implantation. Meng et al. emphasized the importance of a linear position relative to the parent blood vessel for thrombus formation in an aneurysm [17]. In this patient, straightening of the PICA from the vertebral artery immediately after stent implantation made the aneurysm the side-wall type, and intraneurysm stagnation then occurred. In addition to suppressing entry into the dissection with a stent, straightening with a stent reduces blood flow to the dissecting aneurysm, and it is considered that successful reduction of the burden on the aneurysm was a factor in aneurysm size reduction.

With non-hemorrhagic arterial dissection, no definite treatment policy has been established when deterioration is observed by imaging. There are a few cases similar to the one in this report, and it is necessary to examine the efficacy in more cases in the future. We hope this report will provide useful information for deciding upon treatment for future patients similar to the present patient.

Conclusions

PICA stent implantation is considered a useful treatment option for non-hemorrhagic onset vertebral artery dissection associated with a vertebral artery aneurysm involving severe and continuously progressive stenosis around the PICA origin.

Ethical audit

Sufficient consideration was given to the patient's personal information in this case report, and a written agreement was obtained.

Patient consent

Written informed consent was obtained from the patient for the publication of this case report.

REFERENCES

- [1] Kai Y, Nishi T, Watanabe M, Morioka M, Hirano T, Yano S, et al. Strategy for treating unruptured vertebral artery dissecting aneurysms. *Neurosurgery* 2011;69:1085–92.
- [2] Naito I, Iwai T, Sasaki T. Management of intracranial vertebral artery dissections initially presenting without subarachnoid hemorrhage. *Neurosurgery* 2002;51:930–8.
- [3] Nakagawa K, Touho H, Morisako T, Osaka Y, Tatsuzawa K, Nakae H, et al. Long-term follow-up study of unruptured vertebral artery dissection: clinical outcomes and serial angiographic findings. *J Neurosurg* 2000;93:19–25.
- [4] Silbert PL, Mokri B, Schievink WI. Headache and neck pain in spontaneous internal carotid and vertebral artery dissections. *Neurology* 1995;45:1517–22.
- [5] Sönmez Ö, Brinjikji W, Murad MH, Lanzino G. Deconstructive and reconstructive techniques in treatment of vertebrobasilar dissecting aneurysms: a systematic review and meta-analysis. *AJNR Am J Neuroradiol* 2015;36:1293–8.
- [6] Jin SC, Kwon DH, Choi CG, Ahn JS, Kwun BD. Endovascular strategies for vertebrobasilar dissecting aneurysms. *AJNR Am J Neuroradiol* 2009;30:1518–23.
- [7] Endo H, Matsumoto Y, Kondo R, Sato K, Fujimura M, Inoue T, et al. Medullary infarction as a poor prognostic factor after internal coil trapping of a ruptured vertebral artery dissection. *J Neurosurg* 2013;118:131–9.
- [8] Akar ZC, Dujovny M, Slavin KV, Gomez-Tortosa E, Ausman JJ. Microsurgical anatomy of the intracranial part of the vertebral artery. *Neurol Res* 1994;16:171–80.
- [9] Mahmood A, Dujovny M, Torche M, Dragovic L, Ausman JJ. Microvascular anatomy of foramen caecum medullae oblongatae. *J Neurosurg* 1991;75:299–304.
- [10] Wang C, Tian Z, Liu J, Jing L, Paliwal N, Wang S, et al. Flow diverter effect of LVIS stent on cerebral aneurysm hemodynamics: a comparison with enterprise stents and the pipeline device. *J Transl Med* 2016;14:199.
- [11] Chung J, Suh SH, Hong CK, Joo JY, Lim YC, Shin YS, et al. Preliminary experience with self-expanding closed-cell stent placement in small arteries less than 2 mm in diameter for the treatment of intracranial aneurysms. *J Neurosurg* 2015;122:1503–10.
- [12] Chung J, Kim YB, Hong CK, Joo JY, Shin YS, Lim YC. Stent salvage using the Enterprise stent for procedure-related complication during coil embolization of ruptured intracranial aneurysms. *Acta Neurochir (Wien)* 2013;155:223–9.
- [13] Kim MJ, Chung J, Kim SL, Roh HG, Kwon BJ, Kim BS, et al. Stenting from the vertebral artery to the posterior inferior cerebellar artery. *AJNR Am J Neuroradiol* 2012;33:348–52.
- [14] Kim CH, Lee CH, Kim YH, Sung SK, Son DW, Lee SW, et al. Flow diverter devices for the treatment of unruptured vertebral artery dissecting aneurysm. *J Korean Neurosurg Soc* 2021;64:891–900.
- [15] Yeung TW, Lai V, Lau HY, Poon WL, Tan CB, Wong YC. Long-term outcome of endovascular reconstruction with the Pipeline embolization device in the management of unruptured dissecting aneurysms of the intracranial vertebral artery. *J Neurosurg* 2012;116:882–7.
- [16] Zenteno MA, Santos-Franco JA, Freitas-Modenesi JM, Gómez C, Murillo-Bonilla L, Aburto-Murrieta Y, et al. Use of the sole stenting technique for the management of aneurysms in the posterior circulation in a prospective series of 20 patients. *J Neurosurg* 2008;108:1104–18.
- [17] Meng H, Wang Z, Kim M, Ecker RD, Hopkins LN. Saccular aneurysms on straight and curved vessels are subject to different hemodynamics: implications of intravascular stenting. *AJNR Am J Neuroradiol* 2006;27:1861–5.