

Received: 2018.05.24
Accepted: 2018.07.17
Published: 2018.10.03

Endoscopic Retrograde Cholangiopancreatography (ERCP) with Laparotomic Small-Intestinal Incision Approach for Extraction of a Common Bile Duct (CBD) Stone Following Total Gastrectomy and Roux-en-Y (R-Y) Anastomosis: A Case Report

Authors' Contribution:
Study Design A
Data Collection B
Statistical Analysis C
Data Interpretation D
Manuscript Preparation E
Literature Search F
Funds Collection G

ABCDEF 1 **Hiroki Nakamoto**
E 1 **Makoto Nishikawa**
E 1 **Takahisa Ishikawa**
E 1 **Ryouji Yokoyama**
E 2 **Akinobu Taketomi**

1 Department of Surgery, Abashiri-Kosei General Hospital, Abashiri, Hokkaido, Japan
2 Department of Gastroenterological Surgery I, Hokkaido University Graduate School of Medicine, Sapporo, Hokkaido, Japan

Corresponding Author: Makoto Nishikawa, e-mail: mcnishi@jcom.home.ne.jp
Conflict of interest: None declared

Patient: Female, 86
Final Diagnosis: Common bile stone
Symptoms: Abdominal pain
Medication: —
Clinical Procedure: —
Specialty: Gastroenterology and Hepatology

Objective: Unusual setting of medical care

Background: Endoscopic retrograde cholangiopancreatography for common bile duct stone in patients who underwent gastrectomy and Roux-en-Y anastomosis is challenging. We report a case in which we performed endoscopic retrograde cholangiopancreatography through a small-intestinal incision approach for a common bile duct stone, which had developed after total gastrectomy and Roux-en-Y anastomosis.

Case Report: An 86-year-old woman with a history of laparoscopic-assisted total gastrectomy and R-Y anastomosis and incision of the common bile duct and cholecystectomy for common bile duct stone by open surgery 3 years ago presented with abdominal pain. Examination revealed a 10-mm stone in the lower part of common bile duct. We planned a combined endoscopic and open surgical approach. An incision on the Y limb of the Roux-en-Y anastomosis 20 cm from the jejunojunal anastomosis and insertion of an endoscope through this opening were performed to extract the common bile duct stone. The patient was discharged on postoperative day 22 without complications.

Conclusions: For a patient with a common bile duct stone, who underwent gastrectomy and Roux-en-Y anastomosis, with firm adhesions at the porta hepatis, combined endoscopy and open surgery using a small-intestinal incision approach can be effective when small-bowel endoscopes are unavailable or the cannulation to Vater's papilla by them is difficult.

MeSH Keywords: Anastomosis, Roux-en-Y • Cholangiopancreatography, Endoscopic Retrograde • Common Bile Duct

Abbreviations: ERCP – endoscopic retrograde cholangiopancreatography; CBD – common bile duct; R-Y – Roux-en-Y; MRCP – magnetic resonance cholangiopancreatography; PTCS – percutaneous transhepatic cholangioscopy

Full-text PDF: <https://www.amjcaserep.com/abstract/index/idArt/911325>



894



—



4



10



Background

Endoscopic retrograde cholangiopancreatography (ERCP) for removal of a common bile duct (CBD) stone in patients who underwent gastrectomy and Roux-en-Y (R-Y) anastomosis is challenging. Repeat incision of the CBD by open or laparoscopic surgery has a risk of postoperative biliary strictures. In recent times, small-bowel endoscopes such as single or double balloon are available, which can make reaching the duodenal papilla possible. However, they are technically more demanding than the conventional ERCP since they need limited equipment and lack the function of forceps elevation. We describe a case of ERCP using a small-intestinal incision approach for removal of a CBD stone that had developed after total gastrectomy and R-Y anastomosis.

Case Report

An 86-year-old woman presented with abdominal pain. On examination, she was 148.2 cm tall and weighed 46.0 kg (Basal Metabolic Index 20.9). Her liver enzymes were elevated, but other hematological values were within normal ranges. She had a history of laparoscopic-assisted total gastrectomy and R-Y anastomosis, as well as incision of the CBD and cholecystectomy for removal of the CBD stone by open surgery. A mid-line incision scar was visible on her upper abdomen. She also had chronic kidney disease and persistent atrial fibrillation.

Magnetic resonance cholangiopancreatography (MRCP) revealed a 10-mm stone in the lower part of the CBD. She was diagnosed with recurrent choledocholithiasis.

This facility had no available small-bowel endoscopes (e.g., single or double balloon) and we lacked experience in treating CBD by them, so we planned a combined endoscopic and open surgery. The patient was placed in the lithotomy position. On making an upper midline abdominal incision, intense adhesions at the porta hepatis were observed, making it difficult to view the CBD. Since the jejunal part of the R-Y anastomosis was easily visible, an incision on the Y limb of the R-Y anastomosis 20 cm from the jejunojejunal anastomosis was made, and the endoscope was inserted through this opening (Figures 1, 2). The endoscope with a plastic cap and straight optics was used to get better access to the Vater's papilla at the retrograde access. The Y limb of the R-Y anastomosis near the jejunojejunal anastomosis was clamped to avoid expanding anal intestines. We inserted a cannula up to the Vater's papilla and identified a 10-mm CBD stone during intraoperative cholangiography (Figure 3). The Vater's papilla was dilated using a 13-mm balloon catheter and the stone was extracted using a 15-mm balloon catheter (Figure 4). During the ERCP procedure,

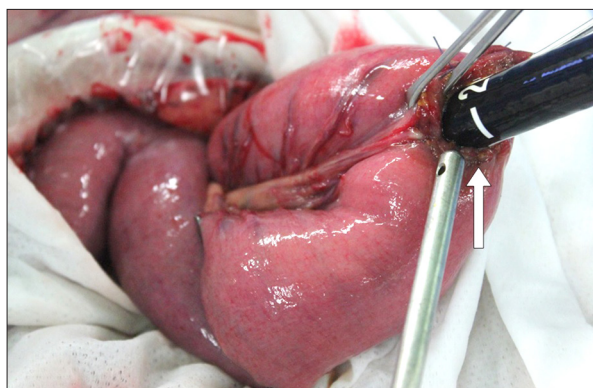


Figure 1. Incision on the afferent loop of R-Y anastomosis 20 cm from the jejunojejunal anastomosis and insertion of an endoscope through the incision (white arrow).

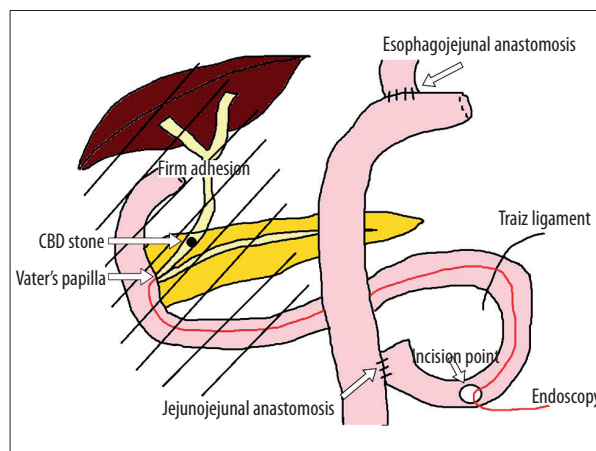


Figure 2. Schema of the operation.

the duodenum was pushed or held by hand, as appropriate. The incision in the small intestine was closed in 2 layers.

The operation time was 88 min and the estimated blood loss was 5 ml. The patient was discharged on postoperative day 22, with no complications. Six months after surgery, she has no recurrence or postoperative complications.

Discussion

Treatment of choledocholithiasis for patients with gastrectomy, R-Y anastomosis, and cholecystectomy is challenging.

Repeat incision of the CBD has a risk of postoperative biliary stricture. Attention must be paid to the CBD incision when the CBD is less than 10 mm in diameter. Moreover, in a patient with a history of open surgery for removal of the CBD stone by incision of the CBD or any other previous surgery near the porta hepatis, extensive adhesions can make repeat surgery more difficult.

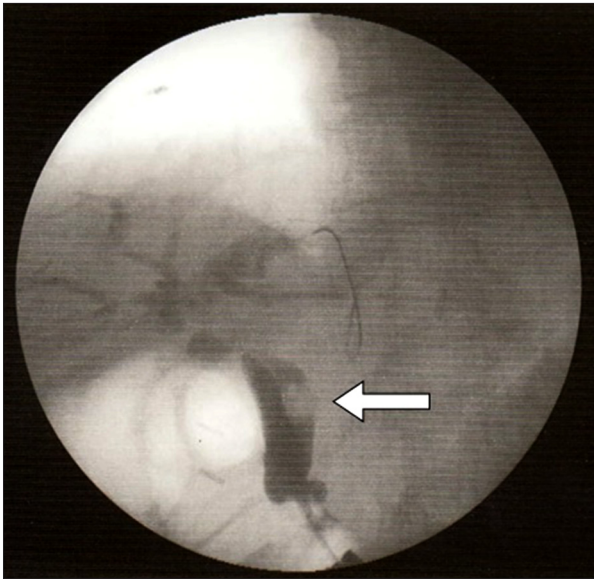


Figure 3. Intraoperative cholangiography showing a 10-mm common bile duct stone (white arrow).

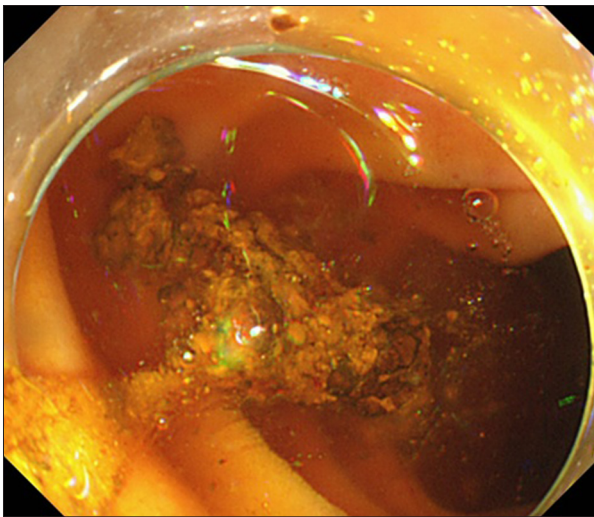


Figure 4. Dilation of the duct with a 13-mm balloon catheter and extraction of the stone with a 15-mm balloon catheter.

Patients who have previously undergone R-Y anastomosis are usually treated by percutaneous transhepatic cholangioscopy (PTCS) [1]. However, if the biliary lumen is narrow, it is very difficult to puncture the intrahepatic bile duct. Some studies report that a laparoscopic transcystic approach to the CBD is

References:

1. Jeong EJ, Kang DH, Kim DU et al: Percutaneous transhepatic choledochoscopic lithotomy as a rescue therapy for removal of bile duct stones in Billroth II gastrectomy patients who are difficult to perform ERCP. *Eur J Gastroenterol Hepatol*, 2009; 21: 1358–62
2. Grubnik VV, Tkachenko AI, Ilyashenko VV, Vorotyntseva KO: Laparoscopic common bile duct exploration versus open surgery: Comparative prospective randomized trial. *Surg Endosc*, 2012; 26: 2165–71
3. Rhodes M, Sussmann L, Cohen L, Lewis MP: Randomised trial of laparoscopic exploration of common bile duct versus postoperative endoscopic retrograde cholangiography for common bile duct stones. *Lancet*, 1998; 351: 159–61
4. Rogers SJ, Cello JP, Horn JK et al: Prospective randomized trial of LC+LCBDE vs. ERCP/S+LC for common bile duct stone disease. *Arch Surg*, 2010; 45: 28–33

effective [2–6]; however, in cases with a history of cholecystectomy, this option is unavailable.

In recent times, small-bowel endoscopes such as single or double balloon are available, which can make reaching the duodenal papilla possible. ERCP using a small-bowel endoscope is technically more demanding than the conventional ERCP, since they need both limited equipment and lack the function of forceps elevation. Moreover, complications such as perforation in the insertion can occur in patients who have adhesions after surgery. In some studies, the rate of success in reaching the papilla in patients who underwent R-Y anastomosis was 54–62% [7–10].

In the present case report, the patient had a history of total gastrectomy and R-Y anastomosis. This facility had no available small-bowel endoscopes (e.g., single or double balloon) and we lacked experience in their use in treating CBD, so we performed a combined endoscopic and open surgery through an incision on the Y limb of R-Y anastomosis. Avoiding incision of the CBD can prevent postoperative biliary stricture. Moreover, if there is a history of incision of the CBD or any other surgery near the porta hepatis, a repeat surgery is not possible due to extensive adhesions. Additionally, removal of a CBD stone can be performed by a conventional ERCP without using a long small-bowel endoscope that requires a specific set of instruments.

Conclusions

In patients with a CBD stone and a history of gastrectomy and R-Y anastomosis, incision of the CBD, or any other surgery near the porta hepatis, it is very difficult to reach the CBD due to firm adhesions. A combined endoscopy and open surgery using a small-intestinal incision approach is effective when small-bowel endoscopes are unavailable or the cannulation to the Vater's papilla by them is difficult.

Acknowledgements

We thank all staff members at Abashiri-Kosei General Hospital.

Conflict of interests

None.

5. Transter SE, Thompson MH: Comparison of endoscopic sphincterotomy and laparoscopic exploration of the common bile duct. *Br J Surg*, 2002; 9: 1495–504
6. Stromberg C, Nilsson M, Leijonmarck CE: Stone clearance and risk factors for failure in laparoscopic transcystic exploration of the common bile duct. *Surg Endosc*, 2008; 22: 1194–99
7. Itoi T, Ishii K, Sofuni A, Itokawa F et al: Long- and short-type double-balloon enteroscopy-assisted therapeutic ERCP for intact papilla in patients with a Roux-en-Y anastomosis. *Surg Endosc*, 2011; 25: 713–21
8. Itoi T, Ishii K, Sofuni A et al: Large balloon dilatation following endoscopic sphincterotomy using a balloon enteroscope for the bile duct stone extractions in patients with Roux-en-Y anastomosis. *Dig Liver Dis*, 2011; 43: 237–41
9. Neumann H, Fry LC, Meyer F: Endoscopic retrograde cholangiopancreatography using the single balloon enteroscope technique in patients with Roux-en-Y anastomosis. *Digestion*, 2009; 80: 52–57
10. Schreiner MA, Chang L, Gluck M et al: Laparoscopy-assisted versus balloon enteroscopy-assisted ERCP in bariatric post-Roux-en-Y gastric bypass patients. *Gastrointest Endosc*, 2012; 75: 748–56