

Posterior Belly of Digastric Muscle Transposition Flap in Preventing Frey's Syndrome after Superficial Parotidectomy- A Prospective Study

Srikant Patro, Narendra Nath Swain, Kailash Chandra Mohapatra, Haramohan Barik, Ashish Kumar Sahoo, Prasanjit Pattnayak

Department of General Surgery, SCB Medical College, Cuttack, Odisha, India

Abstract

Introduction: Superficial parotidectomy is an effective management for benign and malignant tumours of the superficial lobe of the parotid gland. Frey's syndrome is one of the most common complications observed after parotidectomy. The objective of our study was to find the incidence of Frey's syndrome 6 months and 1 year postoperatively after doing posterior belly of the digastric flap during superficial parotidectomy. **Materials and Methods:** This is an observational prospective study done in the Department of General Surgery of the Institute from November 2018 to December 2020. Thirty-eight patients with parotid swellings (both due to benign or malignant causes) were evaluated preoperatively and planned for superficial parotidectomy with a posterior belly of digastric muscle (PBDM) flap to prevent the occurrence of Frey's syndrome. They were followed up in 6 months and 1 year. Minor's test was done in each visit to look for the occurrence of Frey's syndrome. **Results:** Two patients (5.2%) out of 38 patients developed asymptomatic Frey's syndrome after 6 months postoperatively out of which one patient (2.6%) developed symptomatic Frey's syndrome after 9 months postoperatively with symptoms such as sweating, flushing, and redness over the parotid area during chewing. **Discussion:** PBDM flap following superficial parotidectomy in a single-stage surgery is an effective and easy method to prevent Frey's syndrome. This procedure is easy to perform and requires no complex dissection. There have not been many studies regarding the use of this flap; hence, this study may be considered as a pilot study.

Keywords: Flap, Frey's syndrome, parotid, posterior belly of digastric, superficial parotidectomy

INTRODUCTION

Superficial parotidectomy is an effective management for benign and malignant tumours of the superficial lobe of the parotid gland.^[1,2] Gustatory sweating (Frey's syndrome) is a common complication after parotidectomy due to abnormal regeneration of the secretomotor parasympathetic fibers of auriculotemporal nerve, which aberrantly supply the skin over the parotid.^[3] The injured nerve fibers regenerate and innervate the sweat glands of the skin overlying the parotid region, which cause sweating on chewing and thought of food. The parasympathetic innervation of the parotid gland arises in the brain stem at the superior salivatory nucleus and the fibers travel with the ninth cranial nerve and enter the middle ear as Jacobson's nerve, and then emerges from the roof of the petrous pyramid as the lesser petrosal nerve. After that, it passes through the foramen ovale to relay at the otic ganglion at the infratemporal fossa. The postganglionic fibers reach

the parotid gland through the auriculotemporal nerve. After parotidectomy, these nerve fibers aberrantly regenerate and supply the sweat glands present in the skin over the parotid.^[3-5] The incidence of Frey's syndrome after parotidectomy can be as high as 96% when the starch iodine test (Minor's test) is done according to the literature. Only a few patients become symptomatic for Frey's syndrome according to various studies after parotidectomy.^[4-6] Many methods have been described using flaps and grafts to reduce the chances of

Address for correspondence: Dr. Ashish Kumar Sahoo, Room No-11, NGH and House Staff Hostel, SCB Medical College, Cuttack - 753 007, Odisha, India. E-mail: sahuo.aks9227@gmail.com

Received: 21-01-2021

Last Revised: 23-05-2021

Accepted: 10-07-2021

Published: 01-02-2022

This is an open access journal, and articles are distributed under the terms of the Creative Commons Attribution-NonCommercial-ShareAlike 4.0 License, which allows others to remix, tweak, and build upon the work non-commercially, as long as appropriate credit is given and the new creations are licensed under the identical terms.

For reprints contact: WKHLRPMedknow_reprints@wolterskluwer.com

How to cite this article: Patro S, Swain NN, Mohapatra KC, Barik H, Sahoo AK, Pattnayak P. Posterior belly of digastric muscle transposition flap in preventing frey's syndrome after superficial parotidectomy- A prospective study. *Ann Maxillofac Surg* 2021;11:266-9.

Access this article online

Quick Response Code:



Website:
www.amsjournal.com

DOI:
10.4103/ams.ams_21_21

Frey's syndrome after superficial parotidectomy such as fascia lata graft,^[7] sternocleidomastoid flap,^[8] dermal fat graft,^[9] platysma muscle flap,^[10] temporoparietal fascia flap,^[11] and polytetrafluoroethylene implant.^[12] The posterior belly of the digastric muscle (PBDM) flap is a novel, easy, and effective procedure to prevent Frey's syndrome in parotidectomy patients.^[13]

MATERIALS AND METHODS

Patients

This observational prospective study was done in the general surgery department of our institute from November 2018 to December 2020. The study was approved by the institutional ethics committee vide IEC Appln. No:-252/26.08.2020. The study included all the patients who attended the surgery clinic of our institution with a parotid swelling involving only the superficial lobe due to any cause (benign lesion, malignancy) after obtaining a valid consent.

Patients below 18 years and above 60 years of age, patients with life-threatening comorbidities (American Society of Anaesthesiology Grade-3 or more),^[14] patients who require excision of deep lobe of parotid, and patients not giving consent to take part in the study were excluded from the study.

Methods

All patients in the study underwent routine preoperative investigations, ultrasonography of parotid region, and fine-needle aspiration cytology of the swelling, preanaesthetic evaluation before surgery.

After obtaining informed and written consent and explaining all the complications of surgery, patients were planned for surgery. General anaesthesia was administered and superficial parotidectomy was done with Modified Blair's incision^[15] after identifying and protecting the facial nerve from any inadvertent injury. The PBDM originates [Figure 1] from the mastoid process of the temporal lobe and is inserted as a common

digastric tendon. The branches of the occipital artery supply the posterior belly of digastric. It lies in close vicinity of the parotid and is used as one of the landmarks to identify facial nerves. The posterior belly of digastric [Figure 2] is detached from the common digastric tendon and sutured to the tissue near the tragus to fill the void after excision of the superficial lobe of parotid, care was taken to preserve the blood supply to the muscle belly. After transposition of the flap, the wound was closed with a close suction drain *in situ*. All patients were given standard postoperative care after surgery. The drain was removed on postoperative day 2 and sutures were removed after 7 days and patients were followed up afterward in 6 months and 1 year.

In every visit, Minor's test^[16] was done in the biochemistry department of the institute by a trained technician to look for the occurrence of Frey's syndrome. Sweating due to stress and anxiety might hamper the results, but its occurrence was unlikely.^[16] A positive test with symptoms such as sweating, flushing, and redness over the parotid area during chewing is diagnosed as symptomatic Frey's syndrome and without symptom is diagnosed as asymptomatic Frey's syndrome.

Statistical analysis

Statistical analysis was done using Microsoft Excel version 2013 and the proportional incidence was calculated. Parametric numerical data were reported as mean \pm standard deviation for continuous variables; nonparametric numerical data were represented as median (range). As this is not a comparative study, *P* value was not used in the results.

RESULTS

With the above criteria, 40 patients were selected. Two of the patients were lost to follow-up. Hence, 38 patients were included in the study. Among the patients, 23 (60.52%) males and 15 (39.48%) females undergone superficial parotidectomy during the study period and flap reconstruction using the PBDM was done in all. The demographic data and various

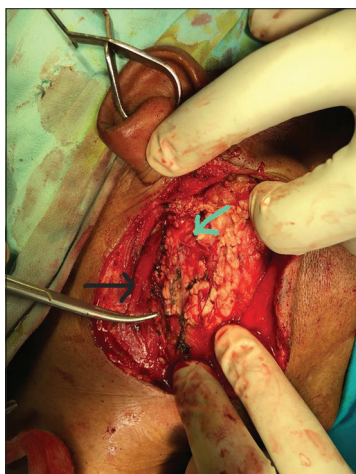


Figure 1: Posterior belly of digastric muscle (black arrow) before being transposed on the parotid bed bearing branches of facial nerve (green arrow)

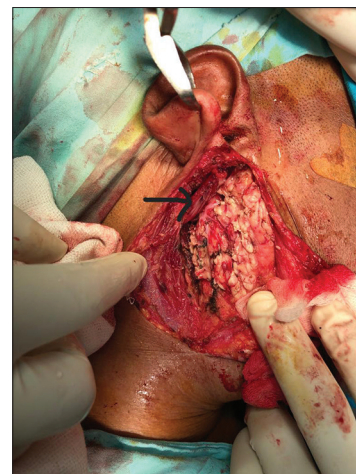


Figure 2: Posterior belly of digastric muscle after being transposed (black arrow)

outcomes of the study are depicted in Table 1. Five (13.15%) patients developed complications in the postoperative period (2 [5.2%] wound infection, 1 [2.6%] parotid fistula, and 2 [5.2%] Frey's syndrome). All complications were managed conservatively in the postoperative period. Two patients (5.2%) showed positive Minor's test after 6 months of surgery which means asymptomatic Frey's syndrome (patients with positive Minor's test but no symptoms of Frey's syndrome). Only one patient (2.6%) developed symptoms after 9 months of surgery who improved after local application of scopolamine over the affected area.

DISCUSSION

Frey's syndrome is believed to be caused by an aberrant regeneration of the injured parasympathetic nerve fibers of the parotid gland during parotidectomy. The injured nerve fibers regenerate and innervate the sweat glands of the overlying skin of the parotid region which cause gustatory sweating. The parasympathetic innervation of the parotid gland originates in the brain stem at the superior salivatory nucleus. The fibers travel with the ninth cranial nerve and enter the middle ear as Jacobson's nerve, and then emerges from the roof of the petrous pyramid as the lesser petrosal nerve. After that, it passes through the foramen ovale to relay at the otic ganglion at the infratemporal fossa. The postganglionic fibers reach the parotid gland through the auriculotemporal nerve.^[3,4] This can be prevented by placing a flap of tissue between the skin and the space created after parotidectomy.^[10]

The incidence of asymptomatic Frey's syndrome after a posterior belly of the digastric flap after superficial parotidectomy is only 5.2%, in our study, while the incidence of symptomatic disease is only 2.6%. In contrast to doing parotidectomy without flap reconstruction of the defect which has an incidence rate for gustatory sweating of 94%,^[4,5] the PBDM flap is a much better alternative. Casler and Conley

used the sternocleidomastoid muscle flap and found out the incidence of symptomatic Frey's syndrome to be 12.5% in their study.^[8] Kim and Mathog reported the incidence of Frey's syndrome (22.2%) in their study using platysma muscle flap.^[10] Rapport and Allison used a platysma muscle flap and found the incidence of Frey's syndrome to be 4%.^[17] Other flap techniques such as fascia lata graft, dermal fat flap, and platysma flap have a higher learning curve and are associated with complex dissection. The PBDM flap is technically very easy to perform with no complex dissection.^[13]

CONCLUSION

The PBDM flap is technically very easy to perform and no complex dissection is required. There have not been many studies regarding the use of this flap; hence, this study may be considered as a pilot study. The limitations of the study are the small sample size, shorter follow-up period, and no comparison with the available other methods. In future to establish PBDM flap after superficial parotidectomy as a definitive option to prevent the occurrence of Frey's syndrome, more number of randomized control trials are required.

Declaration of patient consent

The authors certify that they have obtained all appropriate patient consent forms. In the form, the patient(s) has/have given his/her/their consent for his/her/their images and other clinical information to be reported in the journal. The patients understand that their names and initials will not be published and due efforts will be made to conceal their identity, but anonymity cannot be guaranteed.

Financial support and sponsorship

Nil.

Conflicts of interest

There are no conflicts of interest.

REFERENCES

1. Stathopoulos P, Igoumenakis D, Smith WP. Partial superficial, superficial, and total parotidectomy in the management of benign parotid gland tumors: A 10-year prospective study of 205 patients. *J Oral Maxillofac Surg* 2018;76:455-9.
2. Kilavuz AE, Songu M, Pinar E, Ozkul Y, Ozturkcan S, Aladag I. Superficial parotidectomy versus partial superficial parotidectomy: A comparison of complication rates, operative time, and hospital stay. *J Oral Maxillofac Surg* 2018;76:2027-32.
3. Motz KM, Kim YJ. Auriculotemporal syndrome (Frey Syndrome). *Otolaryngol Clin North Am* 2016;49:501-9.
4. Grosheva M, Horstmann L, Volk GF, Holler C, Ludwig L, Weiß V, et al. Frey's syndrome after superficial parotidectomy: Role of the sternocleidomastoid muscle flap: A prospective nonrandomized controlled trial. *Am J Surg* 2016;212:740-7.
5. Infante-Cossio P, Gonzalez-Cardero E, Garcia-Perla-Garcia A, Montes-Latorre E, Gutierrez-Perez JL, Prats-Golczer VE. Complications after superficial parotidectomy for pleomorphic adenoma. *Med Oral Patol Oral Cir Bucal* 2018;23:e485-92.
6. Li C, Yang X, Pan J, Shi Z, Li L. Graft for prevention of Frey syndrome after parotidectomy: A systematic review and metaanalysis of randomized controlled trials. *J Oral MaxillofacSurg* 2013;71:419-27.

Table 1: Results

Variables	Results
Total cases (%)	38
Males	23 (60.52)
Females	15 (39.48)
Age (years), mean±SD (range)	48.3±8.75 (32-67)
BMI (kg/m ²), mean±SD (range)	22.1±1.97 (18.7-26.6)
Diagnosis (%)	
Pleomorphic adenoma	26 (68.42)
Warthin's tumour	12 (31.58)
Operative time (min), mean±SD (range)	59.2±11 (48-92)
Length of hospital stay (days), mean±SD (range)	2.6±0.75 (2-5)
Postoperative complications (%)	
Wound infection	2 (5.2)
Parotid fistula	1 (2.6)
Frey's syndrome	2 (5.2)

SD: Standard deviation, BMI: Body mass index

7. Wallis KA, Gibson T. Gustatory sweating following parotidectomy: Correction by a fascia lata graft. *Br J Plast Surg* 1978;31:68-71.
8. Casler JD, Conley J. Sternocleidomastoid muscle transfer and superficial musculoaponeurotic system plication in the prevention of Frey's syndrome. *Laryngoscope* 1991;101:95-100.
9. Wang S, Li L, Chen J, Li X, Yin J, Liu K, *et al.* Effects of free fat grafting on the prevention of Frey's syndrome and facial depression after parotidectomy: A prospective randomized trial. *Laryngoscope* 2016;126:815-9.
10. Kim SY, Mathog RH. Platysma muscle-cervical fascia-sternocleidomastoid muscle (PCS) flap for parotidectomy. *Head Neck* 1999;21:428-33.
11. Ye L, Cao Y, Yang W, Wu F, Lin J, Li L, *et al.* Graft interposition for preventing Frey's syndrome in patients undergoing parotidectomy. *Cochrane Database Syst Rev* 2019;10:CD012323.
12. Dulguerov P, Quinodoz D, Cosendai G, Piletta P, Marchal F, Lehmann W. Prevention of Frey syndrome during parotidectomy. *Arch Otolaryngol Head Neck Surg* 1999;125:833-9.
13. Rai A, Jain A, Datarkar A, Kawadkar D. Reconstruction using sternocleidomastoid muscle flap versus posterior belly of digastric muscle flap compared with no reconstruction following superficial parotidectomy. *Oral Maxillofac Surg* 2021;25:81-7.
14. Doyle DJ, Goyal A, Bansal P, Garmon EH. American Society of Anesthesiologists Classification. In: *StatPearls*. Treasure Island (FL): StatPearls Publishing; 2020.
15. Wormald R, Donnelly M, Timon C. 'Minor' morbidity after parotid surgery via the modified Blair incision. *J Plast Reconstr Aesthet Surg* 2009;62:1008-11.
16. Choi HG, Kwon SY, Won JY, Yoo SW, Lee MG, Kim SW, *et al.* Comparisons of three indicators for Frey's syndrome: Subjective symptoms, minor's starch iodine test, and infrared thermography. *Clin Exp Otorhinolaryngol* 2013;6:249-53.
17. Rappaport I, Allison GR. Superficial musculoaponeurotic system amelioration of parotidectomy defects. *Ann Plast Surg* 1985;14:315-23.