

The role of regional and neuroaxial anesthesia in patients with systemic sclerosis

Zoey Sarah Dempsey¹

Simone Rowell²

Rose McRobert³

¹Department of Anaesthesia, Southern General Hospital, Glasgow, Lanarkshire, ²Department of Anaesthesia, Western Infirmary, Glasgow, Lanarkshire, ³Department of Anaesthesia, The Ayr Hospital, Ayr, Ayrshire, UK

Abstract: Systemic sclerosis (SSc), previously known as progressive systemic sclerosis, is a form of scleroderma and a multisystem connective tissue disease which can impact on every aspect of anesthetic care, especially airway management. In this review we outline clinical manifestations and current medical treatment of the disease, and general principles of anesthetizing these patients. We focus on the role of regional anesthesia, including neuroaxial anesthesia, which may serve as a safe alternative to general anesthesia but can be technically challenging. We address concerns regarding abnormal responses to local anesthesia which have previously been reported in patients with SSc, and explore future developments in technology and pharmacology, which may enable regional anesthesia to be performed more successfully and with fewer complications.

Keywords: systemic sclerosis, scleroderma, regional anesthesia, neuroaxial anesthesia

Introduction

Scleroderma is a connective tissue disease associated with excess production and deposition of collagen types I and III, glycosaminoglycans, and fibrinectins within connective tissues.¹⁻³ Systemic sclerosis (SSc) is a form of scleroderma with involvement of internal organs. SSc is subdivided into diffuse cutaneous (dcSSc) and the limited cutaneous forms (lcSSc).⁴

The prevalence of scleroderma ranges from 4–489 cases per million worldwide with an annual incidence of 0.6–122 per million.⁵ There is significant global variation with greater prevalence seen in the US and Australia than in Europe and Japan.⁵ The disease typically affects women more than men in a ratio of approximately 3:1 and reaches peak incidence in the fifth decade of life.⁵

The cause of the disease is unknown and likely to be multifactorial. Human leukocyte antigens (HLA DR1, 2, 3, 5, and HLA DQA2), anticentromere antibodies, and antinucleolar antibodies have all been implicated,^{6,7} and raised levels of endothelial cell antibodies are associated with increased disease severity.¹ Past exposure to cytomegalovirus, organic solvents, silica, dust, drugs (bleomycin), and aromatic hydrocarbons may also increase the risk of developing SSc.^{1,6}

The multisystem involvement of SSc can impact on every aspect of anesthetic care, especially airway management. Patients are chronically unwell and may present repeatedly for a wide variety of surgical procedures. The role of regional anesthesia, particularly neuroaxial blockade, may serve as a safe alternative to general anesthesia and a useful adjunct in management of postoperative pain.

Correspondence: Rose McRobert
Department of Anaesthesia,
The Ayr Hospital, Dalmellington Road,
Ayr, KA6 6DX, UK
Tel +44 1292 610 555
Email rose.mcrobert@aaht.scot.nhs.uk

Clinical features

The scleroderma spectrum of disorders present with skin thickening and hardening (sclerosis). They are subdivided as shown in Figure 1.

Systemic sclerosis is diagnosed on the basis of characteristic skin changes and one or more extracutaneous features, including new heartburn or dysphagia, new hypertension, new renal insufficiency, dyspnea on exertion with interstitial changes on chest x-ray, pulmonary hypertension, diarrhea with malabsorption, mucocutaneous telangiectasia of face, lips, mouth, or hands, and digital infarctions or digital tip pitting.⁷

Patients with lcSSc have skin sclerosis that is normally limited to the hands, but will occasionally affect the face and neck.¹ They have many vascular manifestations of the disease and may exhibit features of CREST syndrome (calcinosis, Raynaud's phenomenon, esophageal dysmotility, sclerodactyly, and telangiectasia).¹

Patients with dcSSc exhibit more widespread cutaneous lesions from the upper limbs proximal to the wrists and the body, but with sparing of the upper back.¹

There is a five- to eight-fold increase in mortality associated with SSc,^{8,9} particularly due to pulmonary hypertension, more commonly associated with lcSSc. Cardiac mortality is also common.¹⁰ Risk factors for increased mortality include age greater than 65 years, forced vital capacity less than 50% predicted, significant cardiac arrhythmia, hypertension, pulmonary fibrosis, and low body mass index.¹¹

Organ involvement in systemic sclerosis

Gastrointestinal disease

Nearly 90% of patients with SSc will have gastrointestinal involvement, of which up to 50% will be asymptomatic.^{12,13} Any part of the gastrointestinal tract may be affected, and symptoms include vomiting, diarrhea, constipation, and pseudo-obstruction.^{15,16}

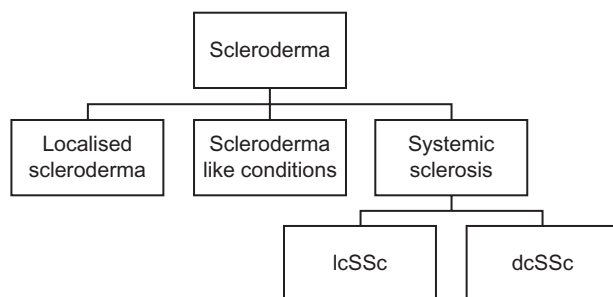


Figure 1 Spectrum of scleroderma.

Abbreviations: lcSSc, limited cutaneous systemic sclerosis; dcSSc, diffuse cutaneous systemic sclerosis.

The esophagus is the most commonly affected organ with esophageal mucosal thinning.^{1,6} Patients may have chronic gastro-esophageal reflux, peptic esophagitis, and recurrent stricture formation^{14–16} with risk of developing Barrett's esophagus and esophageal cancer.¹ Repeated aspiration may also lead to development of interstitial lung disease.¹⁶

Barium studies of the stomach show dilatation, atony, and delayed gastric emptying.¹⁵ Gastrointestinal bleeding and anemia may occur secondary to angiodysplasia of the upper gastrointestinal tract.¹⁶ Malabsorption syndromes are also common, and can lead to electrolyte imbalance, hypokalemia, hypoprothrombinemia, osteomalacia, and protein deficiency.^{15–17} Chronic malabsorption of vitamin B12 has resulted in subacute degeneration of the spinal cord.¹⁸ Blood clotting may also be affected due to impaired absorption of vitamin K.¹⁴

Pulmonary disease

Pulmonary disease is the second most common systemic manifestation of SSc, documented in over 70% of patients¹⁶ and accounts for the majority of deaths in affected patients.¹⁰ There are two principal clinical manifestations of pulmonary disease: interstitial lung disease and pulmonary vascular disease.¹⁶

Interstitial lung disease may develop as pulmonary infiltration leads to interstitial and peribronchial fibrosis and bronchial epithelial proliferation. Pulmonary function tests show decreased compliance, reduced vital capacity, and altered diffusion capacity associated with hypoxemia.^{6,14,19,20}

Pulmonary vascular disease, principally pulmonary arterial hypertension, may develop in 10%–40% of patients with SSc, and symptoms, including dyspnea on exertion and diminished exercise tolerance, may be absent until the disease is advanced.¹⁶ It may lead to cor pulmonale and right-sided heart failure, progressing to death due to thrombosis of pulmonary vasculature.¹⁶

The risk of developing lung cancer is five times higher in patients with SSc compared to the general population.¹⁶

Renal disease

Evidence of renal disease is found in 60%–80% of autopsies of patients with dcSSc.^{21,22} Findings include thickening of the renal glomerular basement membrane, intimal hyperplasia of interlobular arteries and arterioles, and glomerulosclerosis.^{1,23} It is a particularly high cause of mortality in affected pregnant patients.³ The patient may develop a “scleroderma renal crisis”, characterized by acute oliguric renal failure, hypertension (which may progress to malignant hypertension), and

proteinuria.^{14–17,23} They may also develop microangiopathic hemolytic anemia.³

Cardiovascular disease

Cardiac complications are most commonly secondary to systemic or pulmonary hypertension, but primary cardiac disease also occurs.^{24,25}

Ninety percent of patients have concomitant Raynaud's disease. This may be the initial presentation,^{2,6,17} ranging from vascular hyperactivity to complete vascular obliteration.²⁶ It may be triggered by exposure to cold, vibration, and stress.²³

An accumulation of excess collagen, glycosaminoglycan, and fibronectin leads to characteristic structural alterations in the small arteries and microvasculature.³ There is severe narrowing, or even occlusion, of the arterial lumina, which can result in ischemia and ultimately ulceration of peripheries.³ This may cause significant peripheral ischemic pain.² It is thought that the sympathetic system is involved in the pathogenesis of Raynaud's disease²⁶ with a sympathetic neuropathy the cause of a decreased, or even absent, vasoconstrictor response to an increase in venous transmural pressure.²⁵

Cardiac manifestations include cardiomegaly, systolic dysfunction, myocardial fibrosis, dilated or restricted cardiomyopathy, conduction defects, and arrhythmias. Only 19% of patients exhibit abnormal rhythm during continuous 24-hour ECG monitoring.^{6,14–16,27} Pathological evidence of pericardial involvement is evident in 70%–80% of patients at autopsy, but symptomatic pericarditis is found in only 7%–20% of patients.¹⁶ There is an association between the development of acute renal failure and pericardial effusion.¹⁶

The 2- and 5-year mortality rates are 65% and 70%, respectively, in those with symptomatic cardiac disease.²⁴

Dermatological disease, orofacial findings, and musculoskeletal disease

Dermal fibrosis sequentially affects the hands, arms, face, and upper chest leading to a waxy, non-pitting edema, flexion contractures, ischemic ulceration, and resorption of distal phalanges.^{1,6,28}

In up to 70% of patients, the face may become pinched, with atrophied nasal alae and restricted mouth opening as a result of soft tissue shrinkage.^{1,17,20,23,29} There may also be limited neck extension due to thickened inelastic skin.¹⁴ Radiographs may reveal widening of the periodontal membrane,²³ blunting of the angle of the mandible and even pathological mandibular fractures, caused by mandibular resorption.¹ Keratoconjunctivitis sicca and xerophthalmia occur in some

patients, predisposing to corneal abrasions.^{1,17} Others develop xerostomia and dental caries as a result of fibrosis of salivary and lacrimal glands.¹ Telangiectatic units, prone to bleeding heavily, are found on the fingers, face, tongue, lips, and buccal or nasal mucosa.^{6,20} Sweating is considerably hindered.¹

Interstitial fibrosis and lymphocytic infiltration of skeletal muscle fibers and synovia may cause proximal muscle weakness, symmetrical polyarthritis, and joint crepitation.⁶ Poor blood supply through diseased vasculature with accumulation of products of anaerobic metabolism activates nociceptors causing ischemic muscle pain.⁶

Skin tightening may cause decline in hand and joint function over time.¹ This contributes to problems maintaining daily hygiene, particularly oral hygiene.¹

Neurological disease

Once thought rare, neurological manifestations of SSc are increasingly recognized^{30–34} and often herald the onset of disease.³⁵ The most commonly observed neurological manifestations are trigeminal neuralgia, peripheral mononeuropathies, mononeuritis multiplex, and nerve entrapment neuropathies.^{32,35} Peripheral neuropathy is estimated to occur in up to 16%³⁶ of patients, but many more complain of chronic neuropathic pain and sensory loss.^{2,18,32,34,36} A significant proportion of patients are now thought to have subclinical neuropathy.³⁶

Autonomic nervous system involvement is particularly common in the progressive form of the disease.³⁷ Many of the clinical features of SSc, such as vasomotor dysfunction, abnormal gastrointestinal tract motility, and anhidrosis, are all features of the autonomic neuropathy, leading some authors to describe SSc as a disease primarily of the autonomic nervous system.¹⁸ In addition to peripheral and autonomic neuropathy, there have also been reports of increased risk of cerebrovascular events, myasthenia gravis, migraine, transverse myelopathy, multiple sclerosis, and steroid responsive psychosis.¹⁸ There is an increase risk of seizure activity when SSc is associated with uremia or hypertension.¹⁸

The effect of pregnancy on systemic sclerosis

Women with SSc can have a normal fertility index yet there is a high rate of spontaneous abortion, still birth, premature labor, and prenatal mortality.¹⁷ Pregnancy accelerates the disease process in approximately 50% of affected parturients.²⁰ Those with multiorgan involvement¹⁷ and dcSSc are worst affected.³⁸ Women with SSc who have severe cardiomyopathy (ejection fraction < 30%), pulmonary hypertension,

severe restrictive lung disease, (forced vital capacity <50% of predicted), malabsorption, or renal insufficiency may be advised against pregnancy and parturients who develop rapid deterioration in internal organ function may be offered termination (first trimester) or early delivery.^{38,39}

Morbidity and mortality is particularly elevated in those who have concomitant hypertension¹⁷ and during the second half of pregnancy it may be difficult to differentiate between renal scleroderma and preeclampsia.²⁷ However, plasma renin is high as a result of renal cortical ischemia if hypertension is due to SSc. Treatment is with angiotensin-converting enzyme inhibitors.³⁹

Pregnant patients with SSc should be considered high risk and have experienced obstetric lead care and multidisciplinary team involvement.³⁹ Early epidural anesthesia is recommended for labor although there is a significant risk of failure to progress due to vaginal constriction.³⁹ General anesthetic may be particularly hazardous, and patients should have operative delivery under regional anesthesia should there be any signs of fetal or maternal compromise.

Treatments for systemic sclerosis

Immunosuppressants such as glucocorticoids, methotrexate, cyclophosphamide, and azathioprine form the mainstay of treatment for disease modification in addition to treatment of alveolitis.⁴⁰ Future treatments may include humanized anti-transforming growth factor and beta-1 monoclonal antibody.^{41,42}

Angiotensin-converting enzyme inhibitors are first-line antihypertensive agents in SSc patients.⁴⁰ In order to prevent a vasospastic crisis, patients are advised to avoid nicotine, cold, stress, and sympathomimetic decongestant medications.⁴⁰ Raynaud's phenomenon is principally treated with calcium channel blockers.⁴⁰ Other treatments that may provide relief are bosentan (a nonselective endothelin antagonist),⁴⁰ iloprost (a prostacyclin),⁴³ and phosphodiesterase type 5 inhibitors such as sildenafil.⁴⁰ Both bosentan and sildenafil are used to treat severe pulmonary hypertension.⁴⁴

Proton pump inhibitors are used to treat gastroesophageal reflux⁴⁰ whilst prokinetic agents such as erythromycin, may be used in patients with esophageal hypomotility.⁴⁰ In cases of pseudo-obstruction, parenteral nutrition and surgery may be considered.⁴⁰

Specific surgical interventions include cervical sympathectomy (which may provide only short term benefits), lumbar sympathectomy, and radical microarteriolytic (digital sympathectomy).⁴⁵ Eventually debridement and amputation of digits may be necessary in severe cases of gangrene.⁴⁵

Anesthetic considerations in the patient with systemic sclerosis

Patients with SSc typically present for dental procedures, digit amputation, esophageal procedures and for management of labor complications or delivery.

Understanding of pathophysiological complications of SSc and careful preoperative assessment are essential when making an anesthetic plan.¹⁹ A summary of preoperative investigations is included in Table 1.

Airway considerations

Anatomical deformities include poor mouth opening, fibrosis of the temporomandibular joint and skin tightening of the face, neck, and mouth, and may cause difficulties with mask ventilation and intubation.^{19,20} Fiberoptic, blind oral, or retrograde intubation techniques^{1,6,19,27} have previously been described. Careful airway manipulation is required as mucosal telangiectasiae may bleed profusely if traumatized.^{14,20,27} Rapid sequence induction may not be advisable, despite the high risk of aspiration, due to the risk of difficult intubation. Sellick's maneuver may be ineffective due to fibrosis of the esophagus.^{14,28} In particularly difficult situations, it may be necessary to consider awake tracheotomy with local anesthesia.^{6,20}

Ventilation

Endotracheal intubation is advocated to decrease the risk of aspiration.¹⁵ Ventilation may be difficult due to reduced pulmonary compliance and these patients are at risk of barotrauma. Standard protective lung strategies should be employed. A period of postoperative ventilation may be required due to reduced oxygen reserve, progressive weakening of intercostal and diaphragmatic muscles,^{14,15} and opiate sensitivity.²⁰ Patients with a vital capacity of less than 1 liter are at particular risk of postoperative respiratory failure.⁶

Monitoring

Routine monitoring (as per Association of Anesthetists Great Britain and Ireland guidelines)⁴⁶ is advocated in all SSc patients. Difficulties in obtaining intravenous access and non-invasive blood pressure readings⁶ may be encountered due to dermal thickening, flexion contractures, and vasoconstriction. Accordingly, invasive monitoring and central venous access may be necessary. Radial artery cannulation may precipitate Raynaud's phenomenon and even subsequent necrosis.^{20,28} Pulse oximeter probes should be alternated between digits during surgery, or ischemic damage may be precipitated.^{6,27} In the presence of severe cardiac disease and pulmonary hypertension in patients undergoing major surgery, it may prove beneficial to monitor parameters of cardiac performance.²⁸

Table I Suggested list of preoperative investigations in patients with SSc

Organ involvement	Investigation
Gastrointestinal disease	Full blood count Coagulation screen Bone profile Liver function tests
Pulmonary disease	Chest radiography Pulmonary function tests Arterial blood gases
Renal disease	Urinalysis Urea and electrolytes Intravenous pyelogram
Cardiovascular disease	Electrocardiography Echocardiography
Dermatological disease, orofacial findings, and musculoskeletal disease	Investigation of esophageal disease Examination of airway and mucosal telangiectasia Examination of range of movement of neck Examination for evidence of periodontal disease Examination for gangrene of digits, peripheral pulses, and sites for intravenous access

It is possible that esophageal disease, aortic disease, and altered vascular compliance in patients with SSc may affect the accuracy of cardiac output monitors.

Warming

Close attention should be given to maintenance of patient temperature using standard techniques to reduce the risk of vascular crisis. As sweating is hindered in the patient with SSc,¹⁵ care should also be taken avoid overheating, which may present as malignant hypertension.¹⁵

Positioning and eye care

Due to flexion contractures, positioning is best accomplished with gentle guidance and the cooperation of the awake patient.¹⁷ Special attention should be given to protecting pressure areas with additional padding if necessary.

Patients are prone to developing keratoconjunctivitis sicca and xerophthalmia, both of which lead to dry eyes.^{1,17} This problem may be compounded as scarring of the eyelids causing widening of the palpebral fissures and inadequate closure. It is important to maintain lubrication of the eyes to avoid corneal abrasions.^{1,17}

The use of regional anesthesia in systemic sclerosis

Regional anesthesia can be a safe alternative to general anesthesia^{15,28,47} in SSc and other connective tissue disorders,

and a useful adjunct in the treatment of postoperative pain, which can be severe in these patients and resistant to opiates.^{2,23,48}

Controlled vasodilatation produced by regional anesthetic techniques can also improve tissue perfusion, promote wound healing, and prevent Raynaud's phenomenon.^{2,20,49} Regional anesthesia may be limited, however, by technical difficulties, prolonged sensory blockade, unpredictable spread of local anesthetics,^{27,47,49,50} and associated with marked cardiovascular compromise.²⁷

Abnormal response to local anesthetics

On searching the published literature we identified 18 case reports describing a total of 21 regional anesthetic blocks carried out in patients with SSc^{2,18,20,23,27,48-60} ranging from dental injections to continuous intrathecal catheter techniques, and dating from 1964. Details of each block and any complications are described in Table 2.

Prolonged sensory block is the most frequently quoted complication of regional anesthesia in these patients.^{8,14,15,18,20,23,27,50,52,53} However, of the 21 blocks identified, only seven resulted in abnormal duration of anesthesia, with all patients making a full recovery within 24 hours.^{18,20,23,52,53} Six of the seven involve peripheral nerve blocks,^{18,23,52,53} with the exception of Thomson et al's case report from 1983²⁰ which describes a prolonged block following epidural anesthesia. In this case report chloroprocaine was the local anesthetic used (this drug is no longer available in the UK due to its association with neurological injury⁶¹). The six more recent case reports of neuroaxial anesthesia in patients with SSc do not report prolongation of block. Agents used were bupivacaine, ropivacaine, and prilocaine.^{27,49,50,55-57}

Several theories have been proposed for prolonged sensory blockade following regional anesthesia, which was first described by Eisele and Reitan in 1971.⁵² They reported a case of a patient with SSc who underwent an axillary block using 20 mL of lidocaine with epinephrine, in which sensory anesthesia persisted for 24 hours. They went on to test the response of subcutaneous infiltration of plain lidocaine and lidocaine with epinephrine in the same patient and discovered that the addition of epinephrine did not prolong the sensory anesthesia as much as expected. They concluded that the prolonged effects of local anesthesia in SSc were the result of poor tissue perfusion secondary to vasoconstriction.

Lewis⁵³ tested this theory further by attempting to improve tissue perfusion by first infusing low molecular weight dextran in a patient with SSc undergoing digital nerve block. Despite the infusion of dextran the nerve block lasted a total

Table 2 Summary of published regional techniques and associated complications in patients with systemic sclerosis

Reference	Regional block	Indication	LA used and dose	Complication
Gunther et al ⁵¹	Spinal	Forceps delivery	?	Nil
	Caudal	Labor analgesia	300 mg mepivacaine	Nil
Eisele and Reitan ⁵²	Axillary nerve block	Treatment bridge to assess sympathetic tone	200 mg lidocaine	Prolonged block
Lewis ⁵³	Digital nerve block	Primary anesthetic for digit amputation	50 mg lidocaine	Prolonged block
Neill ²³	Supraclavicular Brachial plexus	Used on two occasions in same patient as adjunct to GA for digit amputations	?	Prolonged block both occasions
	Sciatic nerve block	Rescue technique for severe postoperative pain following metatarsal amputation	?	Prolonged block
Thomson et al ²⁰	Lumbar epidural	Labor management	320 mg of chloroprocaine	Prolonged block
Sweeney ⁵⁴	wrist block	Multiple digit amputation	Mixture of lidocaine 1% and bupivacaine 0.25% use exact dose not specified	5 mL injected around median nerve resulting in transient severe pain and cyanosis of hand
Berth-Jones et al ¹⁸	Dental block	?	?	Prolonged block
Bailey et al ²⁷	Spinal	Primary anesthetic for LSCS	11.87 mg L-bupivacaine	Nil
Garcia-Sanchez et al ⁵⁵	Lumbar epidural	Primary anesthetic for laparotomy	85 mg L-bupivacaine	Nil
Lundborg et al ²	Continuous intrathecal catheter	Continuous ambulatory analgesia	Buprenorphine and bupivacaine infusion	Transient post-dural puncture headache and meningitis. Urinary retention and reduced motor function at doses of >20 mg/day L-bupivacaine. IT treatment lasted 861 days, 560 of which were spent at home
Greengrass et al ⁴⁸	Axillary block	Continuous ambulatory analgesia	Continuous infusion or ropivacaine 100 mg/hour	Nil
Erol ⁵⁶	Thoracic epidural	Adjunct to GA for esophageal surgery	50 mg L-bupivacaine plus infusion 2.4 mg/hour for 3 days	Nil
Sulemanji et al ⁵⁰	Lumbar epidural	Primary anesthetic technique for laparoscopic cholecystectomy	200 mg prilocaine	Difficult to position patient lateral position only
Erk et al ⁴⁹	Combined spinal epidural	Primary anesthetic technique for hip arthroplasty	12.5 mg hyperbaric intrathecal bupivacaine given only	Nil
Picozzi et al ⁵⁷	High thoracic epidural	Primary anesthetic technique for mitral valve replacement	60 mg ropivacaine plus continuous infusion of 7.5 mg/hour ropivacaine for 48 hours	Nil
Fan ⁵⁸	Interscalene block	Shoulder arthroplasty	N/A	Failed due to inability to locate plexus using a nerve stimulator
Edmunds et al ⁵⁹	Sub-Tenon's block	Cataract surgery	80 mg lidocaine, and 7.5 mg L-bupivacaine	Elevated intra-ocular pressure
Ceylan et al ⁶⁰	Combined femoral and sciatic nerve block	Primary anesthetic technique for foot amputation	22.5 mg L-bupivacaine and 20 mg lidocaine	Nil

Abbreviations: GA, general anesthesia; LSCS, lower segment cesarean section; IT, intrathecal; N/A, not applicable; LA, local anesthesia.

of 24 hours. Subcutaneous infiltration of lidocaine following infusion of sodium bicarbonate reduced the duration of sensory anesthesia by more than half. This suggested the mechanism for prolonged blockade may be more related to tissue pH diminishing the unionized portion of local anesthetics and delaying its diffusion into the nerve.

Another theory surrounding prolonged response to regional anesthesia is related to compression of the nerve by the local anesthetic fluid itself. Due to fibrosis of muscle and connective tissue, fascial planes surrounding peripheral nerves can be relatively inelastic and injection of local anesthetics can cause a rise in compartment pressure

with compression of blood and nerve supply. This was the mechanism thought to have caused transient cyanosis and prolonged anesthesia following a wrist block as observed by Sweeney⁵⁴ and a rise in intraocular pressure following a sub-Tenon's block reported by Edmunds et al.⁵⁹

The literature does not discuss whether prolonged blockade may be the result of perineural or intraneural injection, which would also explain the symptoms described by Sweeney.⁵⁴ None of the papers reporting prolonged duration of block describe how nerves were located; many may have been done using landmark techniques. The technical challenges encountered in performing peripheral regional anesthesia in SSc patients such as positioning difficulties, altered fascial planes, and altered peripheral sensation, may increase the risk of intraneural injection when using landmarks, fascial clicks, and patient reported paresthesia for location. In addition, the wide range of neurological abnormalities seen in SSc can cause abnormal nerve conduction,^{18,32,36} making location of peripheral nerves using nerve stimulators difficult.⁵⁸

Owing to the increased potential for prolonged blockade, vascular compromise, and technical difficulty with peripheral regional anesthesia, neuroaxial anesthesia, where appropriate, may be more successful, predictable, and beneficial in these patients.

Neuroaxial anesthesia in systemic sclerosis

Neuroaxial anesthesia is described in ten case reports. Single shot spinals,^{27,51} epidurals,^{20,50,51,55-57} combined spinal epidurals (CSE)⁴⁹ and continuous intrathecal catheter techniques² have all been used successfully in patients with SSc. Fortunately the back is often spared in SSc^{1,27} and of the ten neuroaxial blocks described in the case reports, technical difficulties were only reported once.⁵⁰ This was due to difficulties positioning the patient, caused by restricted joint movement and not sclerosis of the spine.

Spinal anesthesia in SSc has only been described in obstetric patients.^{27,51} Bailey et al²⁷ used a single shot spinal for urgent cesarean delivery in a nulliparous woman with SSc and preeclampsia. The use of a single shot spinal was chosen over epidural or CSE due to concerns of thrombocytopenia and risk of spinal hematoma. In this case, spinal block height reached T8 with return of full sensation 3.5 hours later, however the patient was considerably hypotensive throughout the procedure and required significant quantities of ephedrine and intravenous fluid. As vasoconstriction is a feature of SSc, patients often have a contracted intravascular

compartment^{6,20,27} and pronounced hypotension can occur secondary to anesthetic-induced vasodilatation. As seen in this case, these patients are often unresponsive to vasopressors which may worsen vasoconstriction in the upper limbs resulting in vasospastic crisis.¹⁵ Significant volumes of fluid may therefore be required to combat hypotension which can result in rebound pulmonary edema on resolution of neuroaxial blockade and subsequent return of intravascular tone. In pregnancy, risk of pulmonary edema may be further compounded by the altered cardiovascular physiology.

Refractory hypotension, in addition to concerns about the predictability of block height and the risk of high spinal block, necessitating a difficult emergency intubation, has led some authors to recommend incremental neuroaxial anesthesia via catheter techniques.^{6,27,49}

Epidural anesthesia and CSE techniques have been used successfully without major complication for peripheral and major surgery, including mitral valve surgery^{49,55-57} and offer the benefit of continued regional analgesia into the postoperative period. However, epidural catheters have been associated with fibrosis when used for prolonged periods in these patients.²

Future directions

With the relative paucity of evidence examining the efficacy and safety of regional anesthesia in SSc, it is difficult to predict future directions that may best benefit these patients. New techniques and agents, which potentially improve success rates and predictability of block characteristics, may be of benefit. Several advances made in regional anesthesia in the last two decades have focused specifically in these areas and may prove to be particularly useful in the difficult SSc patient.

Ultrasound for regional anesthesia

Ultrasound offers several advantages to the patient with SSc, the main one being direct visualization of anatomical structures.^{62,63} Unlike peripheral nerve stimulation and other landmark techniques, nerves can be blocked anywhere along their course⁶³ and may enable peripheral nerve blockade to be carried out in patients with positioning difficulties. Direct observation of the needle tip may reduce the incidence of intraneural injection and allow confirmation of spread of local anesthetic around the nerve and within the fascial plane.⁶³ Studies have demonstrated that ultrasound-guided regional anesthesia, for a range of peripheral nerve blocks, can lead to higher success rates, faster onset, and a more effective block, with a reduction in the minimum volume of local anesthetic required.⁶²⁻⁶⁶

Less is known about the role of ultrasound in assisting neuroaxial blockade. In 2008, the National Institute for Clinical Evidence published guidelines on the use of ultrasound-guided catheterization of the epidural space.⁶⁷ The guideline describes two different ways in which ultrasound can be used to facilitate epidural catheterization: prepuncture ultrasound and real time ultrasound.

Prepuncture ultrasound involves scanning the patient's back to identify neuroaxial structures and correct spinal level.^{64,68} Most literature involving ultrasound for neuroaxial anesthesia describes this technique and prepuncture ultrasound can be used to identify the midline, depth of epidural space, and optimum angle for needle insertion.^{63,64,68,69}

Real time ultrasound, or ultrasound-guided epidural catheterization, is largely described in pediatric and neonatal patients.⁶⁸ It is of limited benefit in adult patients as the neuroaxial space is a deep structure, encased in bony anatomy, through which ultrasound waves may not pass. Deeper penetration necessitates the use of curved array probes and lower scanning frequencies, which reduce image quality and needle tip visualization. Loss of resistance to air or saline remains a necessary safeguard against dural puncture and adds a further level of manual complexity to the technique.⁶³

Patients in whom real time ultrasonic guidance is most likely to be of greatest use, including adults with SSc, are the ones in whom adequate imaging is likely to be the most difficult to achieve.

The development of 3D and 4D ultrasound technology, however, may lead to more frequent use of real time ultrasound guidance for neuroaxial location. The ability to view multiple planes of a region of interest may overcome difficulties in needle location as the whole volume of the region is displayed, with the needle position within that volume continuously imaged, enabling the needle to be guided to an exact point within that volume.⁷⁰

Intraneural pressure monitoring needles

As previously discussed, local pressure effects and intraneural injection may explain some of the reports of prolonged response to local anesthetics seen in patients with SSc. Animal studies have shown that injection pressures of greater than 20 psi⁷¹ may be associated with intraneural injection, and the development of regional anesthesia block needles capable of monitoring injection pressure may provide an additional safeguard when performing regional anesthesia in patients with SSc.

Future developments in pharmacology

The development of new agents for use in regional anesthesia is currently focused on agents which have a short duration of action and may be used by the intrathecal route for day case surgery, and on those which prolong the sensory block without the need for indwelling nerve catheters and infusions. Both these developments may benefit the patient with SSc.

The search for shorter acting local anesthetics has led to a renewed interest in local ester anesthetics such as 2-chlorprocaine. The new preservative-free form of chlorprocaine (currently unavailable in the UK)⁶¹ is being used widely throughout Europe and is associated with resolution of spinal block within 60 minutes.⁷² Atricaine is a unique local ester anesthetic which contains thiopentene rings and is currently used in dentistry, but has been shown to have rapid onset and short duration of action when used for brachial plexus blocks and for intrathecal and epidural anesthesia.⁶¹ It could potentially be given in combination with catheter techniques to enable a rapidly titratable level of regional anesthesia with fast offset in patients with SSc, although there are no case reports describing its use in this way.

There have also been several advances made in liposomal delivery systems. Liposomes are microscopic lipid vesicles with a central aqueous compartment and can be used to carry lipid soluble drugs, in their lipid bilayer, or aqueous drugs in their central compartment.⁶¹ The permeability of the lipid bilayer can be modified to enable slower diffusion of local anesthetics into neural tissue, preventing redistribution and combating systemic toxicity.⁶¹ Liposomal delivery systems may obviate the need for continuous nerve catheter infusions and pumps,⁷² and provide prolonged analgesia in the postoperative and ambulatory setting to SSc patients with intractable pain.

Conclusion

SSc is a multisystem disease, which can impact on every aspect of anesthetic care. Regional anesthesia can provide excellent analgesia, promoting wound healing and preventing vasospastic crises. It can be considered a safe alternative to general anesthetic in these particularly high-risk patients. Prolonged sensory blockade has largely been seen with peripheral nerve blocks, which can be challenging to perform with nerve stimulation due to abnormal muscle and nerve physiology. As SSc frequently spares the spine, many of the reported complications and challenges of regional anesthesia in SSc are reduced with neuroaxial approaches. CSE or epidural anesthesia, which allows gradual or incremental titration of block height, may be preferable as marked

hypotension can occur following spinal anesthesia. The role of new technology, such as ultrasound and the development of new local anesthetic agents and drug delivery systems, may enable regional anesthesia, both peripheral and neuroaxial, to be performed more successfully and predictably with fewer complications.

Acknowledgments

We would like to thank Susan Cuthbertson, Dr Gillian Roberts, and Dr Richard Price for their assistance in preparing the manuscript.

Disclosure

The authors have no competing interests in this work.

References

- Albibia JB, Lam DK, Blanas N, Clokie CML, Sandor GKB. Small mouths ... big problems? A review of scleroderma and its oral health implications. *J Can Dent Assoc.* 2007;73(9):831–836.
- Lundborg CN, Nitescu PV, Appelgren LK, Curelaru ID. Progressive systemic sclerosis: intrathecal pain management. *Reg Anesth Pain Med.* 1999;24(1):89–93.
- Rose SH. Ischemic complications of radial artery cannulation: an association with a calcinosis, Raynaud's phenomenon, esophageal dysmotility, sclerodactyly and telangiectasia variant of scleroderma. *Anesthesiology.* 1993;78(3):587–589.
- LeRoy EC, Black C, Fleischmajer R, et al. Scleroderma (systemic sclerosis): classification, subsets and pathogenesis. *J Rheumatol.* 1988;15(2):202–205.
- Chiffot H, Fautrel B, Sordet C, Chatelus E, Sabila J. Incidence and prevalence of systemic sclerosis: a systematic literature review. *Semin Arthritis Rheum.* 2008;37(4):223–235.
- Roberts JG, Sabar R, Gianoli JA, Kaye AD. Progressive systemic sclerosis: clinical manifestations and anesthetic considerations. *J Clin Anesth.* 2002;14(6):474–477.
- UpToDate®.com [homepage on the internet]. Varga J. Diagnosis and differential diagnosis of systemic sclerosis (scleroderma) in adults. [updated October 6, 2009]. Available from: <http://www.uptodate.com/store>. Accessed June 8, 2011.
- Thomas E, Symmons DP, Brewster DH, Black RJ, Macfarlane GJ. National study of cause-specific mortality in rheumatoid arthritis, juvenile chronic arthritis, and other rheumatic conditions: a 20 year follow-up study. *J Rheumatol.* 2003;30(5):958–965.
- Al-Dhaheer FF, Pope JE, Ouimet JM. Determinants of morbidity and mortality in systemic sclerosis in Canada. *Semin Arthritis Rheum.* 2010;39(4):269–277.
- Tyndall AJ, Bannert B, Vonk M, et al. Causes and risk factors for death in systemic sclerosis: a study from the EULAR Scleroderma Trials and Research (EUSTAR) database. *Ann Rheum Dis.* 2010;69(10):1809–1815.
- Assassi S, Del Junco D, Sutter K, et al. Clinical and genetic factors predictive of mortality in early systemic sclerosis. *Arthritis Rheum.* 2009;61(10):1403–1411.
- Turner R, Lipshutz W, Miller W, Rittenberg G, Schumacher HR, Cohen S. Esophageal dysfunction in collagen disease. *Am J Med Sci.* 1973;265(3):191–199.
- Akesson A, Wollheim FA. Organ manifestation in 100 patients with progressive systemic sclerosis; a comparison between the CREST syndrome and diffuse scleroderma. *Br J Rheumatol.* 1989;28(4):281–286.
- Kanter G, Barash PG. Undiagnosed scleroderma in a patient with a difficult airway. *Yale J Biol Med.* 1998;71(1):31–33.
- Smoak LR. Anesthesia considerations for the patient with progressive systemic sclerosis (scleroderma). *AANA J.* 1982;50(6):548–554.
- UpToDate®.com [homepage on the internet]. Varga J. Overview of the clinical manifestations of systemic sclerosis (scleroderma) in adults. [updated September 23, 2009]. Available from: <http://www.uptodate.com/store>. Accessed June 8, 2011.
- Younker D, Harrison B. Scleroderma and pregnancy: anesthetic considerations. *Br J Anaesth.* 1985;57(11):1136–1139.
- Berth-Jones J, Coates PAA, Graham-Brown RAC, Burns DA. Neurological complications of systemic sclerosis—a report of three cases and review of the literature. *Clin Exp Dermatol.* 1990;15(2):91–94.
- Roelofse JA, Shipton EA. Anaesthesia in connective tissue disorders. *S Afr Med J.* 1985;67(9):336–339.
- Thompson J, Conklin K. Anesthetic management of a pregnant patient with scleroderma. *Anesthesiology.* 1983;59(1):69–71.
- Medsker TA, Masi AT, Rodnan GP, Benedek TG, Robinson H. Survival with systemic sclerosis (scleroderma). A life table analysis of clinical and demographic factors in 309 patients. *Ann Intern Med.* 1971;75(3):369–376.
- Medsker TA, Masi AT. Survival with scleroderma. II A life-table analysis of clinical and demographic factors in 358 male US veteran patients. *J Chronic Dis.* 1973;26(10):647–660.
- Neill RS. Progressive systemic sclerosis, prolonged sensory blockade following regional anaesthesia in association with a reduced response to systemic analgesics. *Br J Anaesth.* 1980;52(6):623–625.
- Janosik DL, Osborn TG, Moore TL, Shah DG, Kenney RG, Zuckner J. Heart disease in systemic sclerosis. *Semin Arthritis Rheum.* 1989;19(3):191–200.
- Byers RJ, Marshall DA, Freemont AJ. Pericardial involvement in systemic sclerosis. *Ann Rheum Dis.* 1997;56(6):393–394.
- Omote K, Kawamata M, Namiki A. Adverse effects of stellate ganglion block on Raynaud's phenomenon associated with progressive systemic sclerosis. *Anesth Analg.* 1993;77(5):1057–1060.
- Bailey AR, Wolmarans M, Rhodes S. spinal anesthesia for caesarean section in a patient with systemic sclerosis. *Anaesthesia.* 1999;54(4):350–371.
- Smith GB, Shribman AJ. Anesthesia and severe skin disease. *Anaesthesia.* 1984;39(5):443–455.
- Davidson-Lamb RW, Finlayson MCK. Scleroderma, complications encountered during dental anaesthesia. *Anaesthesia.* 1977;32(9):893–895.
- Campello MI, Velilla MJ, Hortells AJL, Almarcequi LC, Barrera CR, Oliveros JA. Neurological involvement in systemic sclerosis. *Rev Clin Esp.* 2003;203(8):373–377. Spanish.
- Mondelli M, Romano C, Della Porta PD, Rossi A. Electrophysiological evidence of “nerve entrapment syndromes” and subclinical peripheral neuropathy in progressive systemic sclerosis (scleroderma). *J Neurol.* 1995;242(4):185–194.
- Dyck PJB, Hunder GG, Dyck PJ. A case control and nerve biopsy study of CREST multiple mononeuropathy. *Neurology.* 1997;49(6):1642–1645.
- Schady W, Sheard A, Hassell A, Holt L, Jayson MI, Klimiuk P. Peripheral dysfunction in scleroderma. *Q J Med.* 1991;80(292):661–675.
- Hietaharju A, Jaaskelainen S, Kalimo H, Hietarinta M. Peripheral neuromuscular manifestations in systemic sclerosis (scleroderma). *Muscle Nerve.* 1993;16(11):1204–1212.
- Poncelet AN, Connolly MK. Peripheral neuropathy in scleroderma. *Muscle Nerve.* 2003;28(3):330–335.
- Tagliafico A, Panico N, Resmini E, Derchi LE, Ghio M, Martinoli C. The role of ultrasound imaging in the evaluation of peripheral nerve in systemic sclerosis (scleroderma). *Eur J Radiol.* 2011;77(3):377–382.
- Klimiuk PS, Taylor L, Baker RD, Jayson MI. Autonomic neuropathy in systemic sclerosis. *Ann Rheum Dis.* 1988;47(7):542–545.

38. Miniati S, Guiducci F, Mecacci G, Mello G, Matucci-Cerinic M. Pregnancy in systemic sclerosis. *Rheumatology*. 2008;47 Suppl 3: S16–S18.
39. Steen VD. Pregnancy in scleroderma. *Rheum Dis Clin North Am*. 2007; 33(2):345–358.
40. UpToDate®.com [homepage on the internet]. Denton CP. Overview of the treatment and prognosis of systemic sclerosis (scleroderma) in adults. [updated January 22, 2011]. Available from: <http://www.uptodate.com/store>. Accessed June 8, 2011.
41. McGaha TL, Phelps RG, Spiera H, Bona C. Halofuginone, an inhibitor of type-1 collagen synthesis and skin sclerosis, blocks transforming-growth-factor-beta-mediated Smad3 activation in fibroblasts. *J Invest Dermatol*. 2002;118(3):461–470.
42. Santiago B, Gutierrez-Cannas K, Dotor J, et al. Topical application of a peptide inhibitor of transforming growth factor-beta1 ameliorates bleomycin-induced skin fibrosis. *J Invest Dermatol*. 2005;125(3): 450–455.
43. Stratton R, Shiwen X, Martini G, et al. Iloprost suppresses connective tissue growth factor production in fibroblasts and in the skin of scleroderma patients. *J Clin Invest*. 2001;108(2):241–250.
44. Korn JH, Mayes M, Matucci Cerinic M, et al. Digital ulcers in systemic sclerosis: prevention by treatment with bosentan, an oral endothelin receptor antagonist. *Arthritis Rheum*. 2004;50(12):3985–3993.
45. Jones NF, Imbriglia JE, Steen VD, Medsger TA. Surgery for scleroderma of the hand. *J Hand Surg Am*. 1987;12(3):391–400.
46. AAGBI. Recommendations for Standards of Monitoring During Anaesthesia and Recovery. 4th Edition. 2007; Available at: <http://www.aagbi.org/sites/default/files/standardsofmonitoring07.pdf>. Accessed June 19, 2011.
47. Wetzl RG. Anaesthesiological aspects of pregnancy in patients with rheumatic diseases. *Lupus*. 2004;13(9):699–702.
48. Greengrass RA, Feinglass NG, Murray PM, Trigg SD. Continuous regional anesthesia before surgical peripheral sympathectomy in a patient with severe digital necrosis associated with Raynaud's phenomenon and scleroderma. *Reg Anesth Pain Med*. 2003;28(4): 354–358.
49. Erk G, Taspinar V, Donmez F, Ornek D. Neuroaxial anesthesia in a patient with progressive systemic sclerosis; a case presentation and review of the literature on systemic sclerosis. *BMC Anesthesiol*. 2006;6:11.
50. Sulemanji DS, Donmez A, Arslan G. Epidural anaesthesia for laparoscopic cholecystectomy in a patient with scleroderma. *Br J Anaesth*. 2006;97(5):749.
51. Gunther RE, Benson W, Harer JR. Systemic scleroderma in pregnancy. Report of a case. *Obstet Gynecol*. 1964;24(1):98–100.
52. Eisele JH, Reitan JA. Scleroderma, Raynaud's phenomenon and local anesthetics. *Anesthesiology*. 1971;34(4):386–387.
53. Lewis GBH. Prolonged regional analgesia in scleroderma. *Can Anaesth Soc J*. 1974;21(5):495–497.
54. Sweeney B. Anaesthesia and scleroderma. *Anaesthesia*. 1984;39(11): 1145.
55. Garcia-Sanchez MJ, Galdo-Abadin JR, Palacio-Rodriguez MA, et al. Anaesthetic management of a pregnant patient with CREST syndrome. *Int J Obstet Anesth*. 1999;8(2):146–147.
56. Erol DD. Thoracic epidural blockade in an elderly with achalasia due to scleroderma for thoracotomy, esophageal myotomy and cystostomy-capitonnage. *The Internet Journal of Anesthesiology*. 2006;11(1).
57. Picozzi P, Lappa A, Menichetti A. Mitral valve replacement under thoracic epidural anesthesia in an awake patient suffering from systemic sclerosis. *Acta Anaesthesiol Scand*. 2007;51(5):644.
58. Fan SW. Anesthetic management of the patient with scleroderma. *The International Student Journal of Nurse Anesthesia*. 2008;7(1):25–27.
59. Edmunds MR, Kyprianou I, Amisssah-Arthur KN, Smith G. Elevated intra-ocular pressure after sub-Tenon's anaesthesia in systemic sclerosis. *Anaesthesia*. 2010;65(3):313–314.
60. Ceylan BG, Sari AK, Ozorak O, Yavuz L, Eroglu F. Combined femoral and sciatic nerve block in a cachectic progressive systemic sclerosis case with gastrointestinal and cardiac involvement. *Agri*. 2010;22(4): 165–169. Turkish.
61. Wiles MD, Nathanson MH. Local anesthetics and adjuvants – future developments. *Anaesthesia*. 2010;65 Suppl 1:S22–S37.
62. Marhoefer P, Harrop-Griffiths W, Kettner SC, Kirchmair L. Fifteen years of ultrasound guidance in regional anaesthesia: Part 1. *Br J Anaesth*. 2010;104(5):538–546.
63. Griffin J, Nicholls B. Ultrasound in regional anaesthesia. *Anaesthesia*. 2010;65 Suppl 1:S1
64. Neal JM, Brull R, Chan VW, et al. The ASRA evidence-based medicine assessment of ultrasound-guided regional anesthesia and pain medicine: Executive summary. *Reg Anesth Pain Med*. 2010;35 Suppl 1:S1–S9.
65. McNaught A, Shastri U, Carmichael N, et al. Ultrasound reduces the minimum effective local anaesthetic volume compared with peripheral nerve stimulation for interscaline block. *Br J Anaesth*. 2010;106(1):124–130.
66. Abrahams MS, Aziz MF, Fu RF, Horn JL. Ultrasound guidance compared with electrical neurostimulation for peripheral nerve block: a systematic review and meta analysis of randomized controlled trials. *Br J Anaesth*. 2009;102(3):408–417.
67. National Institute for Health and Excellence. Ultrasound-guided catheterization of the epidural space. 2008; Available at: <http://www.nice.org.uk/IPG249>. Accessed June 19, 2011.
68. Perlas A. Evidence for the use of ultrasound in neuroaxial blocks. *Reg Anesth Pain Med*. 2010;35 Suppl 2:S43–S46.
69. Marhoefer P, Harrop-Griffiths W, Kettner SC, Kirchmair L. Fifteen years of ultrasound guidance in regional anaesthesia: Part 2 – Recent developments in block technique. *Br J Anaesth*. 2010;104(6):673–683.
70. Bedforth NM. New technologies in nerve location. *Anaesthesia*. 2010;65 Suppl 1:S13–S21.
71. Hadzic A, Dilberovic F, Shah S, et al. Combination of intraneural injection and high injection pressure leads to fascicular injury and neurologic deficits in dogs. *Reg Anesth Pain Med*. 2004;29(5):417–423.
72. Rosenberg PH. Future of regional anesthesia. *Acta Anaesthesiol Scand*. 2005;49(7):913–918.

Local and Regional Anesthesia

Publish your work in this journal

Local and Regional Anesthesia is an international, peer-reviewed, open access journal publishing on the development, pharmacology, delivery and targeting and clinical use of local and regional anesthetics and analgesics. The journal welcomes submitted papers covering original research, basic science, clinical studies, reviews & evaluations,

Submit your manuscript here: <http://www.dovepress.com/local-and-regional-anesthesia-journal>

guidelines, expert opinion and commentary, case reports and extended reports. The manuscript management system is completely online and includes a very quick and fair peer-review system, which is all easy to use. Visit <http://www.dovepress.com/testimonials.php> to read real quotes from published authors.

Dovepress