




Arab Journal of Urology
(Official Journal of the Arab Association of Urology)

www.sciencedirect.com



ONCOLOGY/RECONSTRUCTION

REVIEW

Leiomyosarcoma of the urinary bladder: A review and a report of two further cases

Nader Y. Hamadalla ^a, Usama N. Rifat ^{b,*}, Khalid C. Safi ^a,
Mustafa Mohammed ^c, Hussam Abu-Farsakh ^d

^a Jordan Hospital and Medical Center, Amman, Jordan

^b Israa Hospital, Amman, Jordan

^c Royal Alexandra Hospital, Glasgow, UK

^d First Medical Laboratory, Amman, Jordan

Received 23 January 2013, Received in revised form 25 February 2013, Accepted 16 March 2013
Available online 6 May 2013

KEYWORDS

Leiomyosarcoma;
Urinary bladder;
Outcome;
Management

ABBREVIATIONS

HPF, high-power

Abstract Objectives: To review the published cases of leiomyosarcoma of the urinary bladder and to report two further cases.

Methods: The databases Pubmed and Hinari were searched using the keywords ‘bladder’, ‘leiomyosarcoma’ and ‘smooth muscle neoplasm’. The 14 articles identified were reviewed, and we present a further two cases.

Results: Of more than 100 cases reported, 77 were reviewed. There is a lack of consensus about the standard treatment, and little is known about the natural history and prognosis of the tumour, due to its very low incidence. These tumours occur in older adults of either sex and are characterised by an aggressive behaviour. There is usually

* Corresponding author. Address: Usama Nihad Rifat, FRCSEd, FACS, Urologist and Transplant Surgeon, Emeritus Professor of Surgery (Urology), P.O. Box 941418 Amman, Jordan. Tel.: +962 65300300x1440.

E-mail address: usama.rifat@yahoo.com (U.N. Rifat).

Peer review under responsibility of Arab Association of Urology.



Production and hosting by Elsevier

fields;
FNCLCC, Fédération
Nationale des Centres
de Lutte Contre le
Cancer;
MSKCC, Memorial
Sloan Kettering Can-
cer Center

an unfavourable outcome, with the lungs being the most common site of metastasis. The two further cases we report had a different presentation and outcome.

Conclusions: Because of the limited experience with this rare tumour, there are insufficient data to suggest the optimum management strategy and prognosis.

© 2013 Production and hosting by Elsevier B.V. on behalf of Arab Association of Urology.

Introduction

Non-epithelial tumours of the urinary bladder account for <5% of overall bladder malignancies, with leiomyosarcoma representing 0.1% of bladder cancers. There are >100 cases reported in the medical literature as leiomyosarcoma, and a total of 192 cases considering all cases of bladder sarcoma. There is no consensus about the standard treatment, and because of the very low incidence, little is known about the natural history and prognosis of the tumour. Leiomyosarcomas have a poor prognosis, especially if they are of high-grade and stage [1]. Herein we review previous cases and report two new cases of bladder leiomyosarcoma.

Methods

The databases of Pubmed and Hinari were searched using the keywords 'bladder', 'leiomyosarcoma' and 'smooth muscle neoplasm'. This review includes the 14 articles identified, comprising 77 cases (Table 1 [1–12]).

Two new cases are also described below.

Case 1

A 71-year-old man presented with haematuria and a burning sensation on micturition, of a few months' duration. His PSA level was normal. He was taking an

α -adrenergic blocker and 5 α -reductase inhibitor for BPH. Urinary cytology was negative for urothelial malignant cells. CT (Fig. 1) showed a large mass at the right lower wall of the bladder, encroaching upon the bladder neck. No enlarged lymph nodes were detected on pelvic and abdominal CT. Bone scanning and chest radiography showed no lesions. Cysto-urethroscopy showed a fungating mass mainly at the right side of the bladder neck, and the mass was biopsied.

Some histopathological sections showed a spindle-cell tumour with marked atypia (Fig. 2) and pleomorphic cells, with high mitotic count of 20 per 10 high-power fields (HPF) (Fig. 3). There was necrosis, representing 20% of the tumour. The tumour reached the surface, with ulceration, and there was calcification on the surface. Immunostaining for actin was positive (Fig. 4A), for desmin showed a few positive cells (Fig. 4B), and for uroplakin and uroplakin III was negative (Fig. 4C)

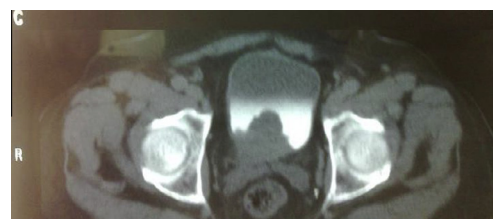

Figure 1 CT showing a large mass at the right lower wall of the bladder, encroaching upon the bladder neck.

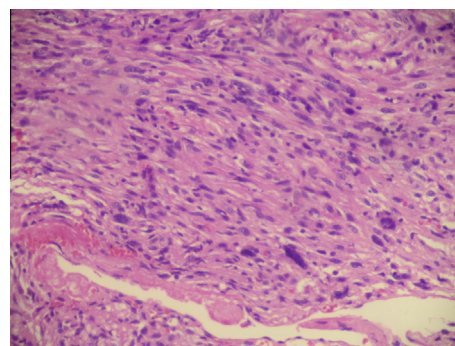


Figure 2 Microscopic findings of the leiomyosarcoma, showing spindle-shaped cells with marked atypia (Haematoxylin and eosin, $\times 400$).

Table 1 Summary of some of the previous reports.

Reference	No. of cases	Year	Category of study
1	1	2010	Case report
2	20	2010	Review
3	2	2003	Case reports
4	7	2011	Review
5	1	2011	Case report
6	1	2011	Case report
7	34	2010	Review
8	1	2009	Case report
9	1	2008	Case report
10	7	2008	Review
11	1	2010	Review
12	1	2009	Case report
Present	2	2012	Review

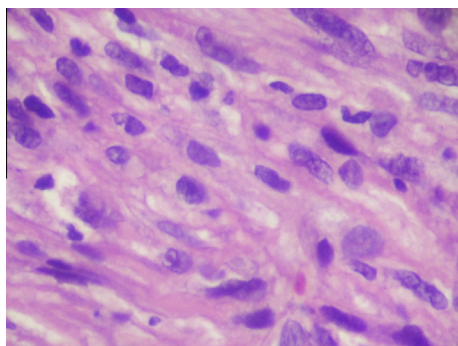


Figure 3 Microscopic findings of the leiomyosarcoma, showing pleomorphic cells with a high mitotic count of 20/10 HPF (Haematoxylin and eosin, $\times 400$).

and D). The diagnosis was high-grade leiomyosarcoma of the urinary bladder.

The patient underwent cystoprostatectomy with an ileal conduit diversion. There was a mass involving the prostate, bladder neck, and anterior and posterior bladder walls, of 8 cm in maximum dimension, with a firm whitish to yellow cut surface. Focal necrosis was identified, with an area of rupture in the anterior wall of 3.5 cm in diameter, with tumour extension. The rest of the bladder had a granular appearance with oedema and haemorrhage. The tumour was close to the seminal vesicles but not invading them. The urethral margin was free.

Microscopically there was no glandular component. The tumour cells were invading the anterior bladder wall with extravascular extension into soft tissue, reaching the resection margin. Histological sections showed a spindle-

cell tumour involving the urinary bladder wall, bladder neck and prostate, composed of interlacing bundles of spindle cells with markedly pleomorphic nuclei, prominent nucleoli and very high mitotic rate ($> 20/10$ HPF). Bizarre giant tumour cells were noted. There were multiple foci of tumour necrosis and calcification ($< 50\%$ of the surface area). The trigone was involved by malignant cells. The rest of the bladder mucosa showed oedema, congestion and chronic inflammation. The right and left seminal vesicles were free of tumour, as was the urethral resection margin, and right and left ureters. Immunohistochemical staining showed focal positive staining for S-100 protein and negative staining for cytokeratin and desmin. The tumour was classified as high-grade.

After a team discussion it was decided to treat the patient with radiotherapy, followed by chemotherapy. He received 50.4 Gy (28 fractions in two phases) over 5.6 weeks. Three months later a positron-emission tomography/CT whole-body scan showed a small nodular focal hypermetabolic lesion in the left upper lobe of the lung, suggestive of metastatic disease. After a further 3 months the chest and abdominal CT showed small nodules in the chest, of uncertain significance, but there were no abdominal or pelvic recurrences.

A year later the patient presented with a cough, and chest CT showed bilateral metastatic deposits, including the pleura, and in the left superior pulmonary vein extending to the left atrium. Further chemotherapy consisted of a combination of ifosfamide and adriamycin, with Mesna, at the usual doses, in the form of three treatment cycles. He died 2 years after the surgery, from pulmonary involvement, with no local recurrence.

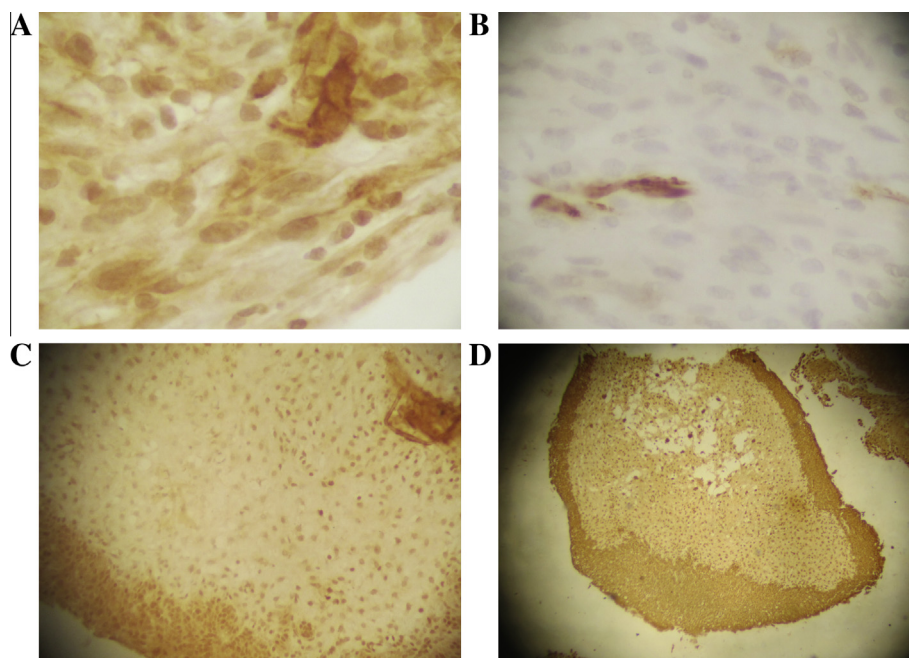


Figure 4 Immunostaining of the tumour for: (A) actin (positive); (B) desmin (a few positive cells); (C) uroplakin (negative); and (D) uroplakin III (negative).

Case 2

A 31-year-old man presented in July 2011 with dysuria of 3 months' duration. Ultrasonography showed a 4×4 cm mass at the right posterolateral aspect of the bladder, with pressure on the right ureter causing hydronephrosis. CT of the chest, abdomen and pelvis showed a well-demarcated enhancing mass of $2.8 \times 4 \times 3.2$ cm at the right posterolateral aspect of the bladder, with right hydronephrosis. Cystoscopy showed no bladder pathology and an intact urothelium. Because of the technical difficulty (unlike in renal cell carcinoma) no attempt was made to take a percutaneous biopsy and it was decided to proceed with surgery.

The tumour mass was mobile and extramural, involving the bladder and distal ureter. The patient underwent a right distal ureterectomy, partial cystectomy, and reimplantation over a JJ stent, and had an uneventful postoperative course.

The histopathological assessment showed leiomyosarcoma of the bladder wall (4.5 cm, grade II) with an intact overlying urothelium. All the margins were free of tumour, by 0.25 mm. The tumour was positive for caldesmon and desmin, and negative for myogenin. There were ≈ 22 mitotic figures per 10 HPF, indicating a high-grade tumour. No involved lymph nodes were identified, and the stage was determined as T1bNXM0.

The JJ stent was removed at 4 weeks after surgery and cystoscopy showed a normal urothelium. The bone scan was free from metastasis. The team decision was to give adjuvant chemo-radiotherapy for the close margins (0.25 mm). The patient had concomitant four cycles of ifosfamide/Mesna and doxorubicin monthly. External beam radiotherapy was given for a total of 50.4 Gy in 28 doses.

CT of the chest, abdomen and pelvis at 4 months after surgery showed no interval changes, and cystoscopy then showed that the bladder was free of tumour. The patient is living uneventfully but declined to attend for a further follow-up.

Discussion

The two cases we report had a dissimilar presentation, the first having severe symptoms like those reported previously, with haematuria being the prevailing feature. The patient underwent early diagnostic steps followed by radical surgery and adjuvant therapy. The second case presented with minimal symptoms. Imaging showed a mass at the right posterolateral aspect of the bladder with right hydronephrosis. He had partial surgery and adjuvant therapy afterwards.

Ricciardi et al. [1] reported one case of leiomyosarcoma of the bladder with an unusual presentation, resembling mostly a pelvic mass. The patient had surgery for a high-grade and high-stage tumour that had

an aggressive behaviour and a very poor prognosis. Lee et al. [2] reviewed 20 cases of bladder leiomyosarcoma, focusing on the criteria for distinguishing leiomyoma from leiomyosarcoma, and the subdivision of the latter into low- and high-grade sarcomas, largely based on mitotic activity. Tanguay et al. [3] described two cases of an interesting association between cyclophosphamide exposure and bladder leiomyosarcoma. Lee et al. [4] studied seven bladder soft-tissue sarcomas, on the basis of 28 years of experience with these tumours at one centre in Korea. Because of the rarity of these tumours clinical data are limited and the prognosis is often considered unpredictable. There is no universal agreement on the prognostic factors. Yamada et al. [5] reported one case that showed a rapid progression and a very poor prognosis (for only a month), that was different in its clinical course from those reported previously. They indicated that there is no consensus on the standard treatment for this tumour. Xu et al. [6] reported the case of a 31-year-old woman with a leiomyosarcoma of 4 cm in diameter on the left wall of the bladder, treated by a partial cystectomy. That report indicated that although bladder leiomyosarcoma has always been considered a highly aggressive tumour, partial surgery is now considered a reliable option, as it preserves function and decreases aggressiveness.

In a comprehensive review, Lindberg et al. [7] assessed 34 well-characterised leiomyosarcomas of the urinary bladder and compared the prognostic power of the Fédération Nationale des Centres de Lutte Contre le Cancer (FNCLCC) and the National Cancer Institute systems with that of one published grading scheme for this tumour from the Mayo Clinic (all cited in [7]). All available slides from 34 tumours were retrieved and evaluated.

One tumour was well-differentiated, 17 were moderately differentiated and 16 were poorly differentiated. Mitotic rates were $1 - > 30/10$ HPF (median $12/10$ HPF).

There was an adverse outcome in nine of these 17 patients. Seven of the eight patients with a clinical follow-up of < 12 months died from their disease. Overall, there was an adverse outcome in 16 of 25 (64%) cases, with metastatic disease in 13 of 25 (52%), with the lungs being the most common site of metastasis (62%).

The authors concluded that leiomyosarcoma occurs in older adults of either sex and is characterised by an aggressive behaviour, with an adverse outcome in $> 60\%$ of cases. Certain advantages of the FNCLCC system might support its more widespread adoption for future studies.

Tsujita et al. [8] reported on a 68-year-old man with a huge bladder diverticulum tumour that infiltrated the mesentery and abdominal wall, with multiple lymph node swellings in the pelvis. The tumour was partially resected using a transurethral approach, and was histo-

logically diagnosed as a malignant neoplasm with marked necrosis. The patient had a partial cystectomy with dissection of the mesentery and ileum. The pathological examination showed the tumour to be a leiomyosarcoma with mesenteric infiltration. The patient had a local recurrence with a pulmonary metastasis at 2 weeks after surgery, and died 39 days after the operation. This was the third case reported in Japan of a leiomyosarcoma in a diverticulum of the urinary bladder.

Bakaris et al. [9] reported an interesting coexistence of two distinct and separate primary tumours of the bladder, i.e. a leiomyosarcoma and a TCC (urothelial cancer). CT of the pelvis showed a bladder mass along the left anterolateral wall. The patient had a transurethral resection of the bladder, and the pathological examination showed that the mass was leiomyosarcoma. The patient then had a radical cystectomy with an ileal conduit diversion. The urinary cystectomy specimen showed an $11 \times 6 \times 5$ cm solid mass on the left anterolateral wall and two 1-cm papillary tumours with different localisation on the right and left lateral walls of the urinary bladder. The pathological examination showed that these masses were high-grade leiomyosarcoma and urothelial cancer. Seven cases of coexisting sarcoma and TCC of the urinary bladder have been reported previously.

Labanaris et al. [10] examined the records of seven patients with bladder leiomyosarcoma. Transurethral resection of the bladder tumour was the initial treatment in all patients, with leiomyosarcoma being initially diagnosed on the basis of an examination of the transurethral specimen. A low-grade tumour was evident in one patient only, with the remaining six having a high-grade tumour. The authors suggested treatment by an aggressive surgical extirpation and, when surgical resection is possible, a radical cystectomy with wide margins.

Nelius et al. [11] described a case of leiomyosarcoma presenting initially as a UTI with lower abdominal pain. A life-threatening episode of gross haematuria guided them to the final diagnosis and treatment.

Cumplido et al. [12] reported a new case of bladder leiomyosarcoma, for which partial surgery of the primary tumour followed by concomitant chemo-radiotherapy was the approach. It was emphasised that although bladder leiomyosarcoma is treated basically with radical surgery, partial surgery is currently the usual approach. There is a trend towards less aggressive surgery, with preservation of function, in tumours of e.g., the head, neck or bladder.

Sarcoma is the most frequent mesenchymal malignancy of the bladder [1] with leiomyosarcoma as the most common histology, as stated in two retrospective reviews of mesenchymal genitourinary tumours. Considering all cases reported to date (192), half were leiomyosarcomas, 20% rhabdomyosarcomas and the remainder consisted of other histology, like carcinosarcoma, angio-

sarcoma and osteosarcoma [1]. No specific risk factors have yet been identified for this tumour. In previous reports, retinoblastoma gene mutations were identified among possible causes in at least nine cases, as was the use of cyclophosphamide. Pelvic radiotherapy for other malignancies was also reported as a risk factor in the clinical history of some patients. The diagnosis can be delayed [1] because patients might have no symptoms until the tumour reaches an advanced stage and becomes locally invasive. The present first case was symptomatic, and he had haematuria that was not taken seriously before presenting to our centre. According to Rosser et al. [13] the most common clinical presentation is gross haematuria (81%). At 3 months after radical surgery the positron-emission scan showed a left upper lung lesion, and the patient died 2 years after the initial diagnosis. In the series by Mackenzie et al. [14], published in 1968, only 11 patients were alive at 3 years after surgery. Subsequent series showed that the outcome reported previously could be better than once thought [6]. The best prognostic factor appears to be the presence of tumour-free margins. However, even if the margins were disease-free, that did not determine a better outcome [1]. This concurs with our first case, who had tumour-free margins but had lung involvement that shortened his survival. The lungs, liver, bone and brain [6] are the most common sites of metastases. The overall recurrence of distant metastases is $\approx 50\%$.

Because of the very low incidence of this tumour there is no universal consensus on the treatment of these patients. The treatment should be adapted to each case, and preferably using a multimodal and/or multidisciplinary approach to the disease. A team of physicians experienced in managing soft-tissue sarcomas should make the decisions [1]. Minimally invasive approaches, such as transurethral resection or laser fulguration, in addition to chemotherapy or radiotherapy in adjuvant settings, have been used for patients with small lesions. Long-term survival rates did not differ significantly from patients undergoing more radical surgery [1].

Our second patient was treated with a right distal ureterectomy, partial cystectomy and re-implantation over a JJ stent. He had an uneventful postoperative course. Recently, more young patients with small tumours have been treated with partial cystectomy [6]. Our second patient was tumour-free and living uneventfully at the time of this report.

Reports strongly suggest that T1 or T2 Memorial Sloan Kettering Cancer Center (MSKCC) stage 1 or 2 small masses (< 4 cm) that are not in the neck and trigone of the bladder might be indications for a partial cystectomy of bladder leiomyosarcoma. Besides being beneficial, adjuvant chemo-radiotherapy is not essential immediately after a partial cystectomy. The overall local recurrence of bladder leiomyosarcoma is $\approx 16\%$, mostly recurring in the pelvis. Therefore, there should be close

monitoring with abdominopelvic CT, chest X-ray and cystoscopy, especially in the first year after surgery, and which might be conducive to the early diagnosis of tumour recurrence and metastasis. Local recurrences should be treated with systemic chemotherapy and/or pelvic external beam radiotherapy [6]. Partial rather than radical cystectomy might be a reliable option for a small bladder leiomyosarcoma (<4 cm) of a low MSKCC stage, because it might offer a similar therapeutic efficacy and a better quality of life. The second patient's tumour was $2.8 \times 4 \times 3.2$ cm, and we think that our treatment was effective and adequate at the time of surgery.

In conclusion, we agree with other authors [15] that because of the limited experience with this rare tumour, there are insufficient data to suggest an optimum management strategy and prognosis, and as we are in an exciting period of discovery about tumours [16] further options might be available in future.

Conflict of interest

None.

Source of funding

None.

References

- [1] Ricciardi E, Maniglio P, Schimberni M, Moscarini M. A case of high-grade leiomyosarcoma of the bladder with delayed onset and very poor prognosis. *World J Surgical Oncol* 2010;**8**:16.
- [2] Lee TK, Miyamoto H, Osunkoya AO, Guo CC, Weiss SW, Epstein JI. Smooth muscle neoplasms of the urinary bladder. A clinicopathologic of study 51 cases. *Am J Surg Pathol* 2010;**34**:502–9.
- [3] Tanguay C, Harvey I, Houde M, Srigley JR, Têtu B. Leiomyosarcoma of urinary bladder following cyclophosphamide therapy. A report of two cases. *Mod Pathol* 2003;**5**:512–4.
- [4] Lee G, Lee SY, Seo S, Jeon S, Lee H, Choi H, et al. Prognostic factors and clinical outcomes of urological soft tissue sarcomas. *Korean J Urol* 2011;**52**:669–73.
- [5] Yamada T, Nagai S, Kanimoto Y. Rapid progression of a urinary bladder leiomyosarcoma. Report of a case. *Case Reports Urol* 2011;**1**:532081.
- [6] Xu YF, Wang GC, Zheng JH, Peng B. Partial cystectomy. Is it a reliable option for the treatment of bladder leiomyosarcoma? *Can Urol Assoc J* 2011;**5**:E11–3.
- [7] Lindberg MR, Fisher C, Thway K, Cao D, Cheville JC, Folpe AL. Leiomyosarcoma of the urinary bladder: a clinicopathological study of 34 cases. *J Clin Pathol* 2010;**63**:708–13.
- [8] Tsujita Y, Sumitomo M, Tasaki S, Shirotake S, Hashiguchi Y, Asano T. A case of leiomyosarcoma in a huge bladder diverticulum. *Hinyokika Kiyo* 2009;**55**:761–4.
- [9] Bakaris S, Resim S, Tasci AI, Demirpolat G. A rare case of synchronous leiomyosarcoma and urothelial cancer of the bladder. *Can J Urol* 2008;**15**:3920–3.
- [10] Labanaris AP, Zugor V, Meyer B, Nützel R, Helmus S, Labanaris PG, et al. Urinary bladder leiomyosarcoma in adults. *Int Urol Nephrol* 2008;**40**:311–6.
- [11] Nelius T, Stevens J, Samathanam C, Filleur S. Leiomyosarcoma of the urinary bladder presenting as life threatening gross hematuria. *Med Oncol* 2010;**27**:562–7.
- [12] Cumplido JD, Toral Peña JC [Bladder leiomyosarcoma. Partial cystectomy and adjuvant treatment]. *Arch Esp Urol* 2009;**62**:320–2.
- [13] Rosser CJ, Slaton JW, Izawa JJ, Levy LB, Dinney CP. Clinical presentation and outcome of high-grade urinary bladder leiomyosarcoma in adults. *Urology* 2003;**61**:1151–5.
- [14] Mackenzie AR, Whitmore Jr WF, Melamed MR. Myosarcomas of the bladder and prostate. *Cancer* 1968;**22**:833–44.
- [15] Li YF, Yu CP, Wu ST, Dai MS, Lee HS. Malignant mesenchymal tumor with leiomyosarcoma, rhabdomyosarcoma, chondrosarcoma, and osteosarcoma differentiation: case report and literature review. *Diagnostic Pathol* 2011;**6**:35.
- [16] Youssef RF, Cost NG, Darwish OM, Margulis V. Prognostic markers in renal cell carcinoma. A focus on the 'mammalian target of rapamycin' pathway. *Arab J Urol* 2012;**10**:110–7.