



# A Case of Giant Cutaneous Lopez Type III Meningioma of the Scalp

Man Fung Cheng<sup>1</sup>  Ling Kit Cheung<sup>1</sup> Ernest Addy Dodoo<sup>1</sup> Yin Chung Po<sup>1</sup>

<sup>1</sup>Department of Neurosurgery, Princess Margaret Hospital, Lai Chi Kok, Hong Kong

**Address for correspondence** Man Fung Cheng, MRCP(UK), MSc, Department of Neurosurgery, Princess Margaret Hospital, 2-10 Princess Margaret Hospital Road, Lai Chi Kok, Hong Kong (e-mail: cc36mc26@yahoo.com).

J Neurol Surg Rep 2023;84:e21–e25.

## Abstract

Meningiomas are the most common central nervous system (CNS) tumors. Extracranial meningiomas are rare, constituting 2% of all meningiomas. We describe a case of Lopez type III meningioma of the scalp in a 72-year-old gentleman who had a long-standing giant scalp mass and presented with recent mild left-sided limb weakness and numbness. Magnetic resonance imaging (MRI) of the skull demonstrated a right frontoparietal tumor extending through the skull into the scalp. Tumor excision revealed World Health Organization (WHO) grade 1 meningioma. Clinicians should correlate a cutaneous skull mass and new onset of neurological symptoms. Cutaneous meningioma is an important differential diagnosis.

## Keywords

- ▶ scalp mass
- ▶ cutaneous meningioma
- ▶ Lopez classification
- ▶ extracranial extension

## Introduction

Meningiomas are neoplasms that are thought to arise from meningotheial cells.<sup>1</sup> They constitute 37.6% of all primary central nervous system (CNS) tumors and 53.3% of all benign CNS tumors.<sup>2</sup> The median age at diagnosis is 66 years and the incidence increases with age.<sup>2</sup> Meningiomas are more common in females and in the black population.<sup>1</sup> Presentations of meningiomas vary, ranging from absence of symptom and nonspecific symptoms to location related due to compression of adjacent brain or vascular structures.<sup>3</sup> Extracranial meningiomas are rare and occur mostly in the head and neck regions. Cutaneous meningiomas are recognized as three distinct clinicopathological groups according to the Lopez classification.<sup>4</sup> Diagnosis of meningiomas can be achieved by magnetic resonance imaging (MRI) or contrast-enhanced computed tomography (CT) in patients with contraindications to MRI.<sup>5</sup> Surgical excision is the main treatment. The rate of recurrence is determined by the extent of resection, defined by the Simpson grade and the WHO grade of meningiomas.<sup>6</sup>

## Case Report

A 72-year-old man who was admitted to our unit presented with a 7-year history of a scalp mass in right frontoparietal region (▶ **Fig. 1**). The mass has been growing slowly throughout the years. The patient reported no symptoms initially. In recent 3 months, he experienced mild numbness and weakness over the left side of his body. He had one episode of left neck and head muscle twitching lasting for 2 minutes. Therefore, he attended the Emergency Department and was subsequently admitted.

Physical examination revealed a right frontoparietal scalp mass. In the assessment of muscle power, the left upper and lower limbs was found to be grade 4 on the Medical Research Council (MRC) scale. There was no sensory deficit. Biceps reflex and knee jerks were normal.

CT of the brain showed a contrast-enhancing isodense mass associated with hyperostosis in the adjacent skull vault in the right frontoparietal lobe. MRI revealed a 7.0 × 9.3 × 7.7 cm (craniocaudal × width × anteroposterior) enhancing extra-axial mass at the right parietal convexity, with a dural tail.

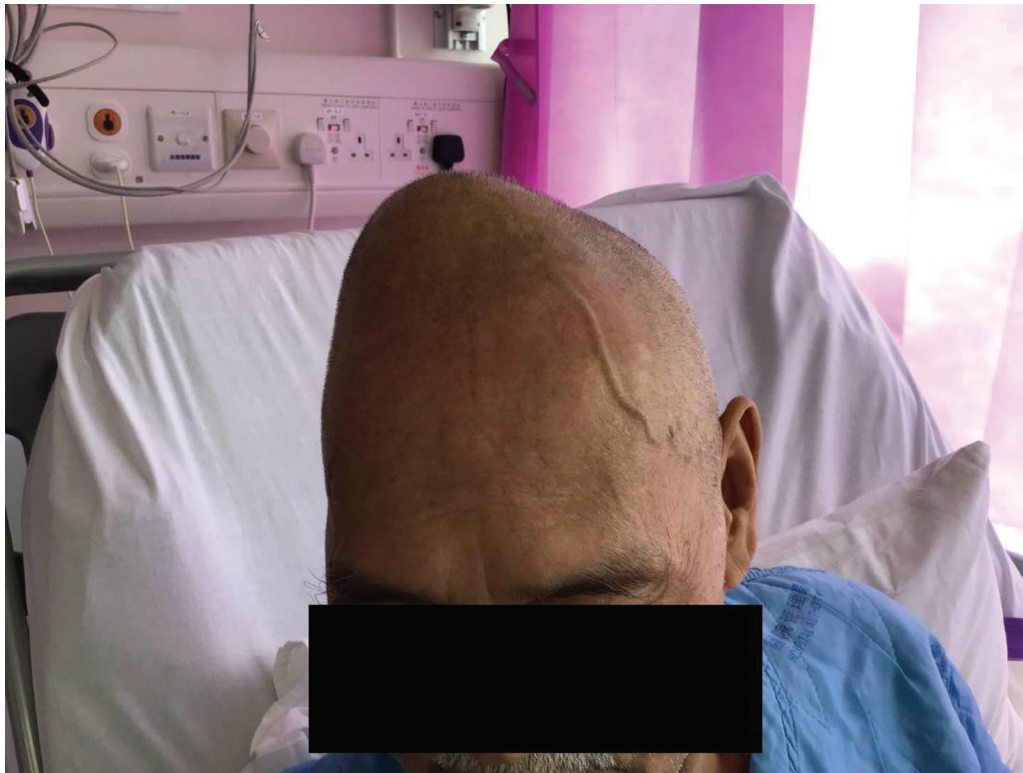received  
August 25, 2022  
accepted  
January 26, 2023

DOI <https://doi.org/10.1055/s-0043-1764322>.  
ISSN 2193-6358.

© 2023. The Author(s).

This is an open access article published by Thieme under the terms of the Creative Commons Attribution-NonDerivative-NonCommercial-License, permitting copying and reproduction so long as the original work is given appropriate credit. Contents may not be used for commercial purposes, or adapted, remixed, transformed or built upon. (<https://creativecommons.org/licenses/by-nc-nd/4.0/>)

Georg Thieme Verlag KG, Rüdigerstraße 14, 70469 Stuttgart, Germany

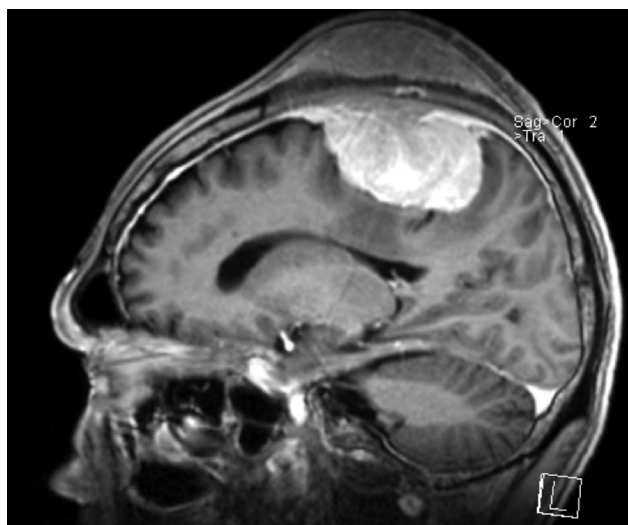

**Fig. 1** Preoperative photograph showing massive right frontoparietal scalp mass.

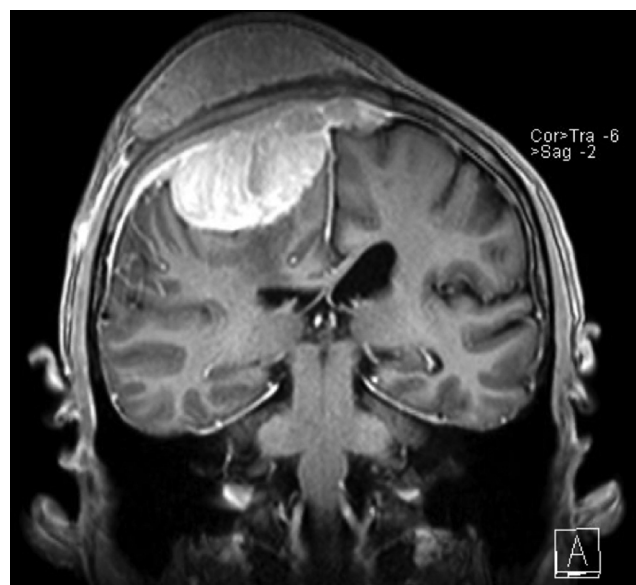
The mass crossed the midline. There was invasion into the midportion of superior sagittal sinus and the inner and outer table of the skull bone into the scalp. Mild subfalcine herniation to the left side was observed (► **Figs. 2 & 3**). The features were compatible with a large meningioma. There was bilateral superficial temporal artery (STA) hypertrophy, indicating that bilateral STAs were the major blood supply to the large cutaneous portion of the meningioma.

Right craniotomy for tumor excision and cranioplasty with bone cement were performed. The right STA was ligated

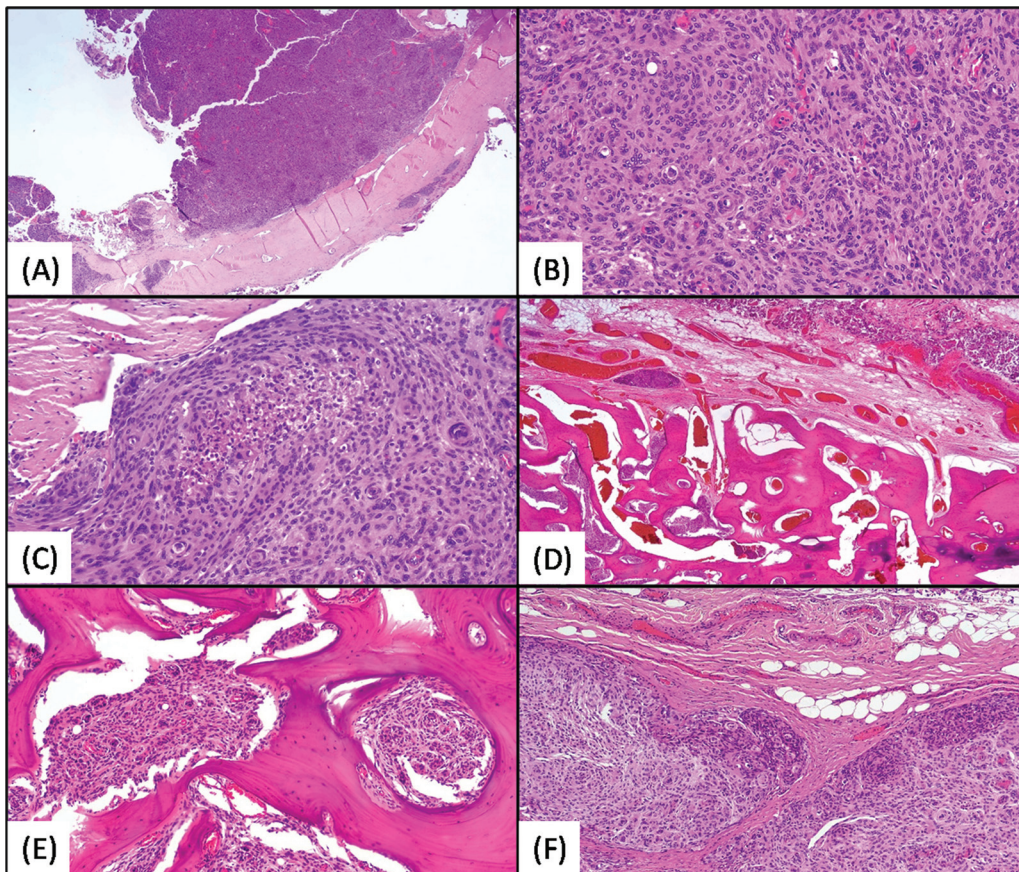
to reduce intraoperative blood loss. A stab incision was made over the preauricular region to identify the STA, followed by ligation and transection of the vessel. The diseased dura was excised and the falx was cauterized. Subtotal excision of the meningioma was achieved. The residual portions close to the bridging vein and at superior sagittal sinus were left behind. Blood loss of the surgery was less than 1 L. Postoperatively



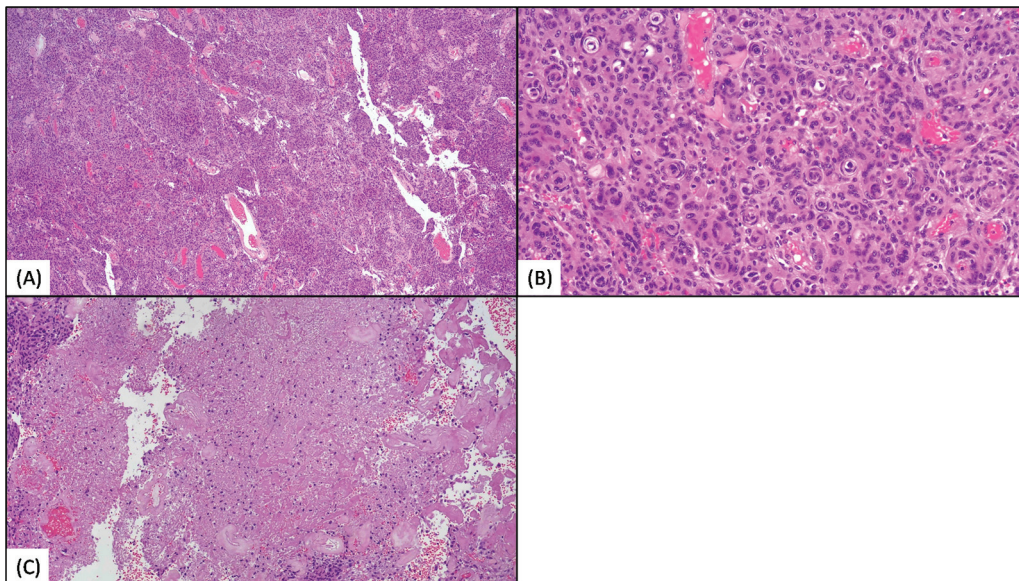
**Fig. 2** Sagittal contrast magnetic resonance imaging (MRI) showing a T2 hyperintense extra-axial mass in the right frontoparietal convexity, with a dural tail and invasion through the skull bone into the scalp.



**Fig. 3** Coronal contrast magnetic resonance imaging (MRI) of the brain showing a right frontal extra-axial mass crossing the midline, with invasion of the superior sagittal sinus. A subfalcine herniation toward the left side was seen.



**Fig. 4** The tumor at the dura mater was also composed of similar spindled cells. (A) Low magnification, 20X. (B) High magnification, 200X. (C) A small focus of necrosis was observed, 100X. The bone marrow spaces were infiltrated by tumor cells. (D) Low magnification, 20X. The bone marrow space infiltration by tumor cells. (E) High magnification, 200X. (F) Tumor cells infiltrating the subcutaneous connective tissue, 40X.



**Fig. 5** The tumor was composed of syncytial sheets of spindled cells with whorl formation. (A) Low magnification, 40X, of the tumor. (B) High magnification, 200X, of the tumor. (C) A focus of necrosis was observed, 100X.

the patient had no neurological deficit. The limb power was MRC grade 5. The modified Barthel Index (MBI) was 100 and 97, before and after surgery, respectively. Wound healing was not affected after ligation of the right STA as there was

extensive collateral blood supply over the scalp. Follow-up MRI was arranged in 6 months.

The skull bone specimen measured  $13 \times 12$  cm across and up to 1 cm in thickness. The resected skull bone showed a

bulging soft-tissue mass  $6.5 \times 7$  cm in area over the outer surface with erosion of the inner surface. The inner surface of the bone showed areas of white-yellowish erosion  $9.5 \times 9$  cm across. The dura displayed multiple nodular growths (–Fig. 4). Histological examination revealed that the brain tumor was composed of syncytial sheets of spindled cells forming fascicles and whorls. The tumor cells showed rare mitotic figures and no cytological atypia. Apart from a focal area of necrosis, no other atypical features were observed (–Fig. 5). The tumor had invaded the skull, featuring infiltration of the bone marrow spaces and subcutaneous tissue overlying the bone by tumor cells with similar morphology as those of the intracranial component. The nodular growths over the dura also showed similar tumor morphology with a focus of necrosis but no other atypical features. WHO grade 1 meningioma with extension into the overlying bone and surrounding fibroadipose tissue was confirmed.

## Discussion

We describe a rare case of Lopez type III meningioma of the scalp in a 72-year-old male. Extracranial meningiomas are uncommon, comprising 2% of all meningiomas and are more commonly seen in male patients.<sup>7</sup> The mechanisms of extracranial meningioma occurrence were summarized by Walters and colleagues: (1) direct extension of an intracranial/intraspinal meningioma through the bone foramina into the adjacent soft tissues; (2) metastatic meningioma; and (3) primary ectopic meningioma.<sup>8</sup> Cutaneous meningiomas are rare. The first case was reported in 1904.<sup>9</sup> Cutaneous meningiomas are classified into three types in the classification proposed by Lopez and colleagues in 1974<sup>4</sup>:

- *Type I: primary cutaneous meningioma.* Type I meningiomas are congenital and arise from ectopic arachnoid cells present in the cutis or subcutis as a result of developmental defect.
- *Type II: meningioma of soft tissue and skin.* Type II meningiomas are ectopic tissue meningiomas that extend to skin by contiguity. They are derived from arachnoid cells lining the spinal and cranial nerves, and are extracranial or extravertebral. They are not from neuroaxis.
- *Type III meningiomas* are a direct extension from neuroaxis into the cutis or the subcutis.

Painless soft-tissue masses on the scalp are common. The most common three diagnoses are benign lipomas, epidermoid cysts, and sebaceous cysts.<sup>10</sup> Scalp meningiomas resemble common scalp soft-tissue masses and could also be mistaken for other cutaneous lesions such as skin tag, nevus, and fibromas.<sup>11</sup> The presentation of meningiomas are often nonspecific. Common symptoms are headache (33.3–36.7%), focal cranial nerve deficit (28.8–31.3%), and seizure (16.9–24.6%). Parasagittal meningiomas may grow to substantial size before symptoms arise, which are commonly headache and Jacksonian seizures of the lower limbs.<sup>12</sup> Asymptomatic meningiomas constitute 9.4% of cases.<sup>13,14</sup> Clinicians should be aware of intracranial pa-

thologies as differential diagnoses, particularly when new neurological symptoms arise.

Meningiomas usually display homogeneous enhancement on contrast MRI. The dural tail can be seen in 72% of meningiomas.<sup>15</sup> Meningiomas usually appear isodense relative to the cerebral cortex but can be hyperdense or slightly hypodense on CT.<sup>5</sup> Detection of hyperostosis, intratumoral calcifications, and interosseous tumor growth is more sensitive by CT than MRI.<sup>6</sup>

The primary treatment option for meningioma is surgical resection. The cure rate of gross total resection (GTR) is 70 to 80%.<sup>16</sup> Limitations of GTR include tumor location and involvement of neurovascular tissue and venous sinuses.<sup>17</sup> Stereotactic radiosurgery (SRS), or fractionated radiotherapy (FRT), can be considered in WHO grade I meningiomas after subtotal total resection.<sup>6</sup> Radiation therapy (RT) is the first-line treatment for unresectable meningiomas.<sup>16</sup> WHO grade II and III meningiomas have a high risk of 5-year recurrence (30–40% and 50–80%, respectively).<sup>16</sup> Adjuvant radiotherapy is a component of initial treatment in WHO grade II and III meningiomas, after surgery. Salvage systemic therapy is offered to patients with recurrent or progressive meningiomas that do not respond to surgery or RT. Currently, there are no established chemotherapies for meningiomas. Research effort in chemotherapy and immunotherapy is robust.<sup>18</sup>

Meningiomas are vascular tumors and are prone to massive bleeding. Intraoperative bleeding may preclude careful dissection of the brain tumor plane and make achievement of Simpson I excision a challenge. Meningioma blood supply may originate from the internal carotid artery (ICA), external carotid artery (ECA), vertebral artery (VA), or a combination of these vessels. Feeders at the site of dural attachment classically supply the central region of a meningioma. The capsule is supplied by cortical or pial feeders. The ECA branches to meningioma include ascending pharyngeal artery (APA), accessory meningeal artery (AccMA), middle meningeal artery (MMA), STA, and branches from perforating transosseous occipital artery (OccA). Dural ICA branches commonly arise from the inferolateral trunk (ILT), ophthalmic artery (OPA), and the meningo-hypophyseal trunk (MHT). The dura was supplied by the VA via the posterior meningeal artery (PMA). ECA–ICA communications should also be considered.<sup>19</sup> In our case, the hypertrophied bilateral STAs signified substantial tumor blood supply from these arteries. It was anticipated preoperatively and ligation of the right STA significantly reduced blood loss. No scalp ischemia resulted. It is useful to consider important anatomy to maximize the efficacy and safety of tumor excision and to minimize operative complication.

## Conclusion

We describe a rare case of Lopez type III meningioma of the scalp. Clinicians should be aware of the relation between chronic scalp lesion and acute neurological symptoms to promptly reach the diagnosis. Knowledge of regional

anatomy is essential to optimize tumor excision and minimize surgical complications.

#### Informed Consent

Written informed consent was obtained from the patient for publication of the case.

#### Conflict of Interest

None declared.

#### Acknowledgments

We thank Dr. Tommy Ng and Dr. Frank Leung from the Department of Pathology, Princess Margaret Hospital, for the specimen slide photos and legends of description.

#### References

- Huntoon KToland AMS, Dahiya S. Meningioma: a review of clinicopathological and molecular aspects. *Front Oncol* 2020;10:579599
- Ostrom QT, Cioffi G, Gittleman H, et al. CBTRUS statistical report: primary brain and other central nervous system tumors diagnosed in the United States in 2012-2016. *Neuro-oncol* 2019;21(Suppl 5):v1-v100
- Wang N, Osswald M. Meningiomas: overview and new directions in therapy. *Semin Neurol* 2018;38(01):112-120
- Lopez DA, Silvers DN, Helwig EB. Cutaneous meningiomas: a clinicopathologic study. *Cancer* 1974;34(03):728-744
- Nowosielski M, Galldiks N, Iglseider S, et al. Diagnostic challenges in meningioma. *Neuro-oncol* 2017;19(12):1588-1598
- Goldbrunner R, Minniti G, Preusser M, et al. EANO guidelines for the diagnosis and treatment of meningiomas. *Lancet Oncol* 2016;17(09):e383-e391
- Albsoul N, Rawashdeh B, Albsoul A, et al. A rare case of extracranial meningioma in parapharyngeal space presented as a neck mass. *Int J Surg Case Rep* 2015;11:40-43
- Walters GA, Ragland RL, Knorr JR, Malhotra R, Gelber ND. Post-traumatic cutaneous meningioma of the face. *AJNR Am J Neuro-radiol* 1994;15(02):393-395
- Winkler M. Über Psammome der Haut und des Unterhautgewebes. *Virchows Arch* 1904;178:323-350
- Leung LK. Differential diagnosis of soft scalp lumps. *BMJ Case Rep* 2011;2011:bcr0720114492
- Singh SK, Ojha BK, Chandra A, Rastogi M, Husain M, Husain N. Scalp meningioma. *Indian J Dermatol* 2008;53(04):196-198
- Marosi C, Hassler M, Roessler K, et al. Meningioma. *Crit Rev Oncol Hematol* 2008;67(02):153-171
- Magill ST, Young JS, Chae R, Aghi MK, Theodosopoulos PV, McDermott MW. Relationship between tumor location, size, and WHO grade in meningioma. *Neurosurg Focus* 2018;44(04):E4
- Zouaoui S, Darlix A, Rigau V, et al; French Brain Tumor DataBase (FBTDB) Participants and Investigators with the participation of the Société française de neurochirurgie (SFNC) Club de neuro-oncologie de la SFNC Société française de neuropathologie (SFNP) Association des neuro-oncologues d'expression française (ANO-CEF) Descriptive epidemiology of 13,038 newly diagnosed and histologically confirmed meningiomas in France: 2006-2010. *Neurochirurgie* 2018;64(01):15-21
- Huang RY, Bi WL, Griffith B, et al; International Consortium on Meningiomas. Imaging and diagnostic advances for intracranial meningiomas. *Neuro-oncol* 2019;21(Suppl 1):i44-i61
- Zhao L, Zhao W, Hou Y, et al. An overview of managements in meningiomas. *Front Oncol* 2020;10:1523
- Buerki RA, Horbinski CM, Kruser T, Horowitz PM, James CD, Lukas RV. An overview of meningiomas. *Future Oncol* 2018;14(21):2161-2177
- Ogasawara C, Philbrick BD, Adamson DC. Meningioma: a review of epidemiology, pathology, diagnosis, treatment, and future directions. *Biomedicines* 2021;9(03):319
- Dubel GJ, Ahn SH, Soares GM. Contemporary endovascular embolotherapy for meningioma. *Semin Intervent Radiol* 2013;30(03):263-277