



Nanditha Sujir, Junaid Ahmed, Keerthilatha Pai, Ceena Denny, Nandita Shenoy

Challenges in Early Diagnosis of Oral Cancer: Cases Series

Izazovi u ranoj dijagnostici oralnoga karcinoma: opis slučajeva

Department of Oral Medicine and Radiology, Manipal College Of Dental Sciences, Mangalore, Manipal Acedemy of Higher Education, Manipal
Zavod za oralnu medicinu i radiologiju Stomatološkog fakulteta Manipal, Mangalore, Indija

Abstract

Oral cancer has an overall survival rate of only 50%. This prognosis is significantly improved when this disease is diagnosed and treated in its early stages. Oral cancer is usually associated with classical clinical features associated with malignancy resulting in accurate diagnosis. However, certain cases of oral cancer, especially in its early stages, can be clinically deceptive and can be misdiagnosed. There is a recent trend of changing demographics and etiology associated with oral cancer adding to the diagnostic challenges faced by the clinician. The awareness of these changing trends is needed to aid in early diagnosis of oral cancer. In this case series, we have presented three cases of patients with challenging aspects.

Received: October 21, 2017

Accepted: January 2, 2019

Address for correspondence

Junaid Ahmed, Professor
Department of Oral Medicine and
Radiology
Manipal College of Dental Sciences
Mangalore, India
Manipal Academy of Higher
Education, Manipal-576104
junaid.ahmed@manipal.edu

Key words

Oral cancer; Cell carcinoma

Introduction

Oral squamous cell carcinoma (OSCC) is the sixth most common cancer with the five-year survival rate of 50% and a dismal prognosis. The morbidity and mortality rates associated with this aggressive condition significantly improve with early diagnosis (1). The delay in diagnosis may be related to the patient (patient delay) or clinician (professional delay) (2). Although patient awareness is essential for early diagnosis of OSCC, a clinician's acumen is crucial. The clinical presentation of OSCC is usually characteristic, thus aiding in early diagnosis. In addition, OSCC is most often associated with known risk factors such as tobacco usage or it may be preceded by potentially malignant disorders¹, which raises a clinician's suspicion of malignancy. However, certain cases can be challenging to diagnose as they may have an uncommon presentation. In this case series we have presented three such cases.

Case 1

A 30 years year old female Patient with no abusive habits presented with burning sensation on the left side of the tongue which had been persisting for past 4 years. She gave a history of a lesion in the same region 4 years back, which was surgically excised by a dentist. On histopathological examination, the lesion was reported to be dysplastic. Post excision, the area had healed completely, however, occasional mild localized burning sensation persisted. Although she

Uvod

Oralni rak skvamoznih stanica (OKSS) šesti je najčešći karcinom s petogodišnjim preživljavanjem od samo 50 %. Stope morbiditeta i mortaliteta toga agresivnog stanja znatno se smanjuju u slučaju ranog dijagnosticiranja (1). Odgoda u postavljanju dijagnoze može biti u vezi s pacijentom (pacijentovo odgađanje), ili s kliničarem (profesionalna odgoda) (2). Iako je svijest pacijenta ključna za ranu dijagnozu OKSS-a, presudna je riječ kliničara. Klinički izgled OKSS-a obično je karakterističan i pomaže u ranom postavljanju dijagnoze. Iako se najčešće povezuje s poznatim rizičnim čimbenicima kao što je uživanje duhana, prije njih može se dogoditi neka potencijalna zloćudna promjena (1) koja može alarmirati kliničara. No, neki slučajevi mogu biti izazovni za dijagnosticiranje zbog neuobičajenog izgleda. U ovom radu opisana su tri takva slučaja.

Prvi slučaj

Tridesetogodišnja pacijentica bez loših navika došla je liječniku i požalila se na pečenje na lijevoj strani jezika koje traje već četiri godine. U anamnezi je navela i leziju u istom području koju je kirurški uklonio doktor dentalne medicine također prije četiri godine. Histopatološki je bila riječ o displastičnoj leziji. Nakon ekscizije područje je potpuno zacijeljelo, no katkad je osjećala blago pečenje. Iako nije mogla jasno opisati svoje simptome, pacijentica je navela promje-

wasn't clearly able to describe her symptoms, she reported of a change in intensity of the burning sensation since past 2 weeks which prompted her to seek medical attention. On examination, there was a blanched area on the ventrolateral surface of the tongue (Figure 1), the borders of which were blending imperceptibly with the surrounding mucosa. On palpation, the consistency was normal and there was no induration. No sharp teeth were associated with the lesion. The cervical lymph nodes were non-palpable. Although her previous history of dysplastic lesion raised our suspicion of malignancy, the clinical findings were not consistent with it and a provisional diagnosis of a hypersensitive scar tissue with a differential diagnosis of scar tissue superinfected with candida infection was made. The patient was prescribed Candid® mouth paint application and a monthly follow up was recommended. Over the course of the follow up there was no discernable change clinically or symptomatically. After 6 months, a slightly raised, firm, circular area was noted in the same region (Figure 2). To better delineate the lesion, advanced imaging was advised prior to incisional biopsy. MRI revealed a well-defined oval lesion along the left lateral border of the tongue at the level of 1st and 2nd molar which was hyperintense on T1weighted images (WI) and showed heterogeneous hyperintensity on T2WI. The incisional biopsy was reported to be well differentiated squamous cell carcinoma (T₁N₀M₀). The patient was referred to another center on request where she underwent partial glossectomy with removal of level I-IV lymph nodes which were benign. Surgical treatment was followed by brachytherapy. There is no evidence of recurrence after the first year of follow up.

Case 2

A 30 year old female patient with no abusive habits reported of a traumatic lesion on the right lateral aspect of her tongue which had been persisting for past 3 months. She gave a history of chronic trauma (> 6 months) due to sharp cusps of teeth with which she associated the lesion. She reported persistence of the lesion despite undergoing coronoplasty with posterior teeth in the first and fourth quadrant 2 months prior to coronoplasty. On examination, a firm nodule of approximately 0.5 cm x 0.5 cm was noted on the right lateral aspect of her tongue. Anterior to the lesion, the mucosa showed mild atrophy with white non scrapable lesion (Figure 3). A provisional diagnosis of traumatic fibroma with frictional keratosis was made. Excisional biopsy of the fibrotic lesion was advised which was reported to be well differentiated squamous cell carcinoma (T₁N₀M₀). The patient subsequently underwent partial glossectomy with removal of level I-IV lymph nodes and is currently on 4th month of follow up.

Case 3

A 56 year old medically fit female patient with no abusive habits reported of a painful growth on the right lateral aspect of her tongue which had been persisting for past 3 months. She noticed the growth after the replacement of missing 46 with a fixed partial denture (FPD) 3 months prior to the re-

nu u intenzitetu u posljednja dva tjedna, što ju je i navelo da zatraži medicinsku pomoć. Tijekom pregleda uočeno je bjelkasto područje na ventrolateralnoj površini jezika (slika 1.) s rubovima neprimjetno spojenima s okolnom mukozom. Pri palpaciji područje je bilo normalno konzistentno i nije bilo zadebljanja. U blizini nije bilo oštih zuba. Iako je anamnestički potaknula sumnje na malignost, klinički nalaz nije bio jasan pa je privremena dijagnoza glasila preosjetljivo ožiljkasto tkivo, a diferencijalnodijagnostički navedeno je moguće ožiljkasto tkivo sa suprainfekcijom kandidom. Pacijentici je propisan preparat Candid® za usnu šupljinu te je dogovorena kontrola za mjesec dana. Tijekom praćenja nije bilo značajnih promjena ni u kliničkoj slici, ni kad je riječ o simptomima. Nakon šest mjeseci u istom je području uočena lagano izdignuta čvrsta okruglasta lezija (slika 2.). Da bi se bolje opisala i ograničila, prije incizijske biopsije predloženo je napredno snimanje. Magnetska rezonancija otkrila je dobro definiranu ovalnu leziju uz lijevi lateralni rub jezika u razini prvoga i drugoga kutnjaka koji je bio jače osvijetljen na snimkama s T1 (WI) te je pokazao heterogeni hiperintenzitet na T2WI. Incizijska biopsija potvrdila da je riječ o dobro diferenciranom raku skvamoznih stanica (T₁N₀M₀). Pacijentica je upućena u drugu bolnicu gdje je obavljena parcijalna glossektomija i uklonjeni su limfni čvorovi od I do IV, koji su bili benigni. Kiruršku terapiju slijedila je brahiterapija. Godinu dana nakon zahvata nema dokaza o recidivu.

Drugi slučaj

Tridesetogodišnja pacijentica bez loših navika došla je liječniku s traumatskom lezijom desno lateralno na jeziku koja se pojavila unatrag tri mjeseca. Navela je kroničnu traumu (> 6 mjeseci) zbog oštih kvržica na zubima, što je povezivala s oteklinom. Istaknula je da je lezija perzistirala unatoč ranijoj koronoplastici lateralnih zuba u prvom i četvrtom kvadrantu prije dva mjeseca. Pri pregledu otkriven je čvor veličine 0,5 x 0,5 cm na desnoj strani jezika. Anteriorno od lezije mukoza je bila blago atrofična s bijelom lezijom koja se nije dala ukloniti (slika 3.). Privremena dijagnoza glasila je traumatski fibrom s frikcijskom keratozom. Preporučena je ekscizijska biopsija te je ustanovljeno da je riječ o dobro diferenciranom raku skvamoznih stanica (T₁N₀M₀). Pacijentici je obavljena parcijalna glossektomija i izvađeni su limfni čvorovi od I do IV. Trenutačno je liječnici prate četvrti mjesec.

Treći slučaj

Medicinski zdrava 56-godišnja pacijentica, bez loših navika, došla je liječniku zbog bolne izrasline na desnoj strani jezika koja raste unatrag tri mjeseca. Osjetila ju je nakon nadomještanja zuba 46 mostom prije tri mjeseca te je tu pojavu smatrala početkom kronične traume mostom. Pri pregledu je

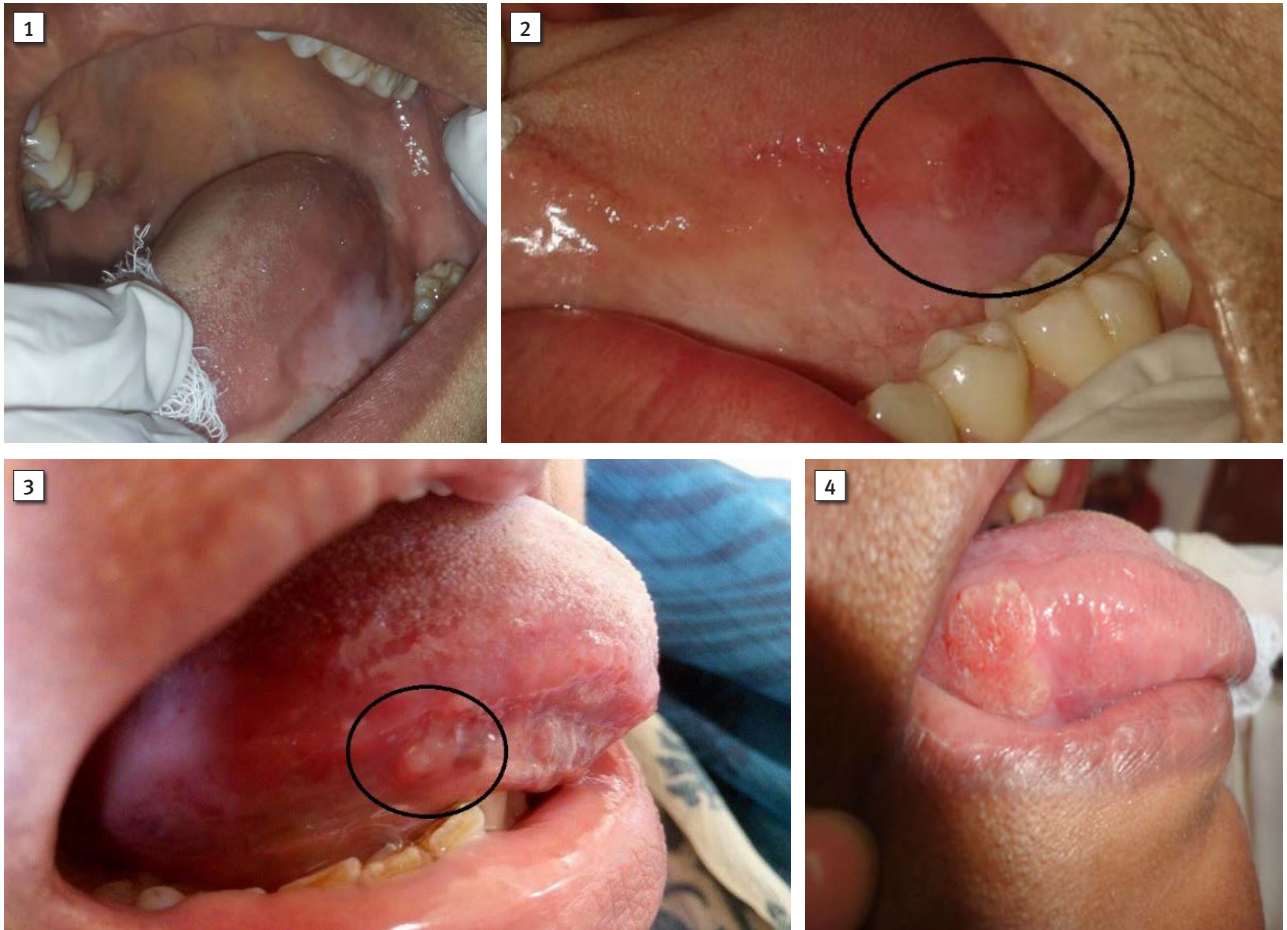


Figure 1 Case 1 first visit

Slika 1. Prvi posjet – prvi slučaj

Figure 2 Case 1 follow up visit

Slika 2. Kontrolni posjet – prvi slučaj

Figure 3 Case 2

Slika 3. Drugi slučaj

Figure 4 Case 3

Slika 4. Treći slučaj

placement and she attributed it to the initiation of the lesion to chronic trauma caused by the FPD. On examination, a nodular lesion of approximate dimension 1.5 cm X 2 cm cm was detected on the right lateral aspect of the tongue. The surface of the lesion was granular and the surrounding mucosa was erythematous. On palpation, the lesion was firm, tender and there was a mild induration. The FPD did not show any gross abnormalities. However, the lesion seemed to impinge in the area of the FPD (Figure 4). Also a single right submandibular lymph node was palpable which was oval, firm, mobile and tender, suggestive of a reactive lymphadenitis. A provisional diagnosis of traumatic fibroma was given. A differential diagnosis of squamous cell carcinoma was also given owing to the induration associated. An incisional biopsy was done and the lesion was reported to be well differentiated squamous cell carcinoma (T₁N₀M₀). The patient subsequently underwent partial glossectomy with removal of level I-IV lymph nodes recently and is on follow up.

opažena nodularna lezija veličine 1,5 x 2 cm na desnoj strani jezika. Površina je bila granulirana, a okolna mukoza eritematozna. Pri palpaciji je otekline bila čvrsta i osjetljiva te s blagom induracijom. Na mostu nije bilo znatnijih odstupanja. No, lezija je bila u projekciji samog mosta (slika 4.). Također se mogao napipati submandibularni limfni čvor koji je bio ovalan, čvrst, pomičan i osjetljiv, što je upućivalo na reaktivni limfadenitis. Postavljena je privremena dijagnoza traumatskog fibroma, a diferencijalnodijagnostički postavljena je sumnja da je riječ o raku skvamoznih stanica zbog zadebljanja. Učinjena je incizijska biopsija te je ustanovljeno da je lezija dobro diferencirani rak skvamoznih stanica (T₁N₀M₀). Obavljena je parcijalna glosektomija te su uklonjeni limfni čvorovi od I do IV. Pacijenticu trenutačno prati liječnik.

Discussion

Early diagnosis of OSCC significantly affects the associated morbidity and mortality and currently is the best method to improve patient prognosis. Risk factors associated with OSCC help the clinician to identify the patients prone to malignancy. OSCC is most commonly seen in older age group and is often associated with tobacco usage (1). In the first 2 cases mentioned above the women belonged to a much younger age group with no history of abusive habits, a population with traditionally reduced expectation of OSCC. A recent review of the literature on this topic found that there has been an increase in prevalence of oral cancer among younger individuals with no traditional risk factors (1, 3), pointing to the need to screen even young individuals for OSCC. There is also an increase in incidence of OSCC of the tongue, with it being the most common site of involvement in younger individuals. The prognosis of OSCC of the tongue is poor with the 5 year survival rate being only 33%. This can be attributed to the fact that nearly 50% of tongue malignancy would have metastasized at the time of diagnosis. For this reason, early diagnosis is extremely critical for improving the prognosis of tongue malignancies (1).

The presence of potentially malignant disorders has always helped the clinician to identify high risk individuals in whom OSCC is more likely to occur. In the first case, the patient had a history of a dysplastic lesion; therefore, the suspicion of malignancy was imperative. The second and third cases were associated with chronic dental irritation. Although it has been implicated in few epidemiologic studies on the etiopathogenesis of OSCC, confounding by alcohol and tobacco has limited its credibility (4). A recent study concludes that OSCC occurs predominantly at sites of potential dental trauma, especially in patients without other risk factors (5). In this way, chronic traumatic lesions which persist even after removing the causative agent should be subjected to histopathologic evaluation.

Molecular mechanisms of OSCC in young have been found to be similar to that of the normal variants. However, the mechanisms by which these alterations are acquired in young non-habituated individuals may be different. Some of the emerging risk factors include human papilloma virus, diet and nutrition, hormonal and immunologic modulations, and genetic susceptibility (1, 4). An assessment of these factors, although may not be feasible in routine dental practice, has gained a lot of importance in oral cancer research.

The clinical features associated with malignancy although varied, tend to be characteristic, thus making clinical diagnosis apparent. OSCC can present as a red or white lesion, chronic solitary ulcer, proliferative growth or a fissure. These lesions usually are non-tender, indurated and bleed easily on manipulation. The initial stages of malignancy are usually painless and severe pain may be associated with advanced stages of malignancy as the lesion invades into the deeper tissues.¹ These lesions may also be associated with enlarged, fixed, stony hard lymph nodes which are typical of malignancy. The clinical presentation in the above cases lacked the obvious signs of malignancy making early diagnosis chal-

Rasprava

Rano postavljanje dijagnoze OKSS-a znatno utječe na povezani morbiditet i mortalitet te je trenutačno najbolja metoda za poboljšanje bolesnikove prognoze. Rizični čimbenici povezani s tom bolešću pomažu kliničarima identificirati pacijente sklone malignosti. OKSS je najčešći u starijoj populaciji te se povezuje s uživanjem duhana (1). U prva dva opisana slučaja riječ je bila o znatno mlađim ženama koje u anamnezi nisu navele loše navike, dakle, o skupini koja se ne povezuje s OKSS-om. U novijoj literaturi ističe se porast prevalencije oralnoga karcinoma u mlađoj populaciji bez tradicionalnih rizičnih čimbenika (1, 3), što pokazuje da je potreban probir svih mladih ljudi na OKSS. Također je u porastu incidencija OKSS-a na jeziku, što je najčešće mjesto na kojemu se pojavljuje u toj populaciji. Prognoza OKSS-a jezika je loša, a petogodišnje preživljavanje iznosi samo 33 %. To se može pripisati činjenici da gotovo 50 % malignosti na jeziku već metastazira u trenutku postavljanja dijagnoze. Zato je rano otkrivanje presudno za poboljšanje prognoze (1).

Potencijalno zloćudni poremećaji uvijek su pomagali kliničarima identificirati visokorizične pojedince kod kojih je vjerojatnija pojava OKSS-a. U prvom slučaju, zato što je pacijentica u anamnezi navela displastičnu leziju, sumnja na malignost bila je logična. Drugi i treći slučaj bili su povezani s kroničnom dentalnom iritacijom. Iako se u nekoliko epidemioloških istraživanja upućivalo na povezanost s alkoholom i duhanom u etiopatogenezi, danas se smatra da je ta povezanost ograničeno vjerodostojna (4). U jednom novijem istraživanju istaknuto je da se OKSS uglavnom pojavljuje na mjestima potencijalne dentalne traume, posebno ako pacijent nema druge rizične čimbenike (5). Zato kronične traumatske lezije koje perzistiraju čak i nakon uklanjanja uzroka treba procijeniti histopatološki.

Molekularni mehanizam OKSS-a kod mladih osoba pokazao se sličnim onomu kod normalnih pojava. No, čini se da su drukčiji mehanizmi prema kojima se te promjene pojavljuju kod mladih ljudi bez loših navika. Neki od rizičnih čimbenika su humani papiloma virus, prehrana, hormonalne i imunosne promjene te genska sklonost (1, 4). Procjena tih čimbenika, iako se ne može obaviti rutinski u ordinaciji, vrlo je važna u istraživanju karcinoma.

Klinička su obilježja povezana sa zloćudnošću različita, no njihove specifičnosti čine kliničko dijagnosticiranje jednostavnim. OKSS može biti crvena ili bijela lezija, kronični izolirani ulkus, tvorba koja raste, ili čak i fisura. Te lezije obično nisu osjetljive, tvrde su i lako prokrvare. Inicijalni stadiji malignosti obično su bezbolni, a jaka bol može biti povezana s napredovalim oblicima kada lezija prodre u dublja tkiva (1). Te otekline mogu biti povezane i s povećanim, fiksiranim, tvrdim limfnim čvorovima koji su karakteristični za zloćudnost. Klinički izgled opisanih slučajeva nije imao očite znakove malignosti, što je rano otkrivanje učinilo izazovnim. U prvom slučaju lezija nije bila klinički vidljiva na prvom pregledu i tek je tijekom praćenja ustanovljena izdignuta oteklina. Sumnja o malignosti temeljila se na pacijentičnoj anamnezi ranije displastične lezije i nedostatku očitoga etiološkog čimbenika, a ne na samim kliničkim znakovima. Dru-

lenging. In the first case, the lesion was not clinically evident during the initial presentation and eventually during a follow up visit a raised lesion was seen. The suspicion of malignancy was high owing to the patient's previous history of dysplastic lesion and lack of an evident etiologic agent rather than the clinical features alone. The second case also lacked the characteristic malignant features and was evident only on histopathological examination. In the third case, although malignancy was suspected, a provisional diagnosis of chronic traumatic fibroma was given as the lesion was extremely painful with no associated bleeding and mild induration which were evident and could be associated with chronic lesions.

Various noninvasive clinical test have been introduced to aid in establishing early clinical diagnosis of such incipient lesions. These tests include vital staining, cytological studies, tissue fluoresce and other cytochemical and molecular studies. Apart from the additional cost involved, especially in the case of molecular studies, none of the techniques have shown 100% sensitivity limiting these techniques being employed for routine clinical use (6). Current evidence suggests that visual and tactile examination with biopsy is the best method for early detection of OSCC (7). This stresses the importance on the clinician's acumen as professional delays in diagnosis can occur if clinicians are unaware about the risk factors and different clinical presentations. In contrast, another factor causing professional delay is the familiarity associated with the most common presenting characteristics of OSCC, which may make the clinician likely to expect this among elderly patients with a positive habit history. Pitiphat et al (8) have shown in their study that there was a less professional delay among patients with history of smoking. Another study by Kerdpon et al (9) found no such association with abusive habits and professional delays. OSCC in young individuals with no abusive habits and with such an innocuous clinical presentation as reported here is rare. Such cases are more likely to be misdiagnosed and inappropriately managed leading to poor prognosis unless clinicians are aware of the possibility of malignancy.

The timing and technique of biopsy and its histopathological evaluation is an integral part of early detection of OSCC. Gao et al (10) in their study found that biopsy taken at the initial clinical visit or at the earliest from the initial presentation significantly reduced professional delay. However, the patients with high risk of malignancy who are on long term follow up may have to undergo multiple biopsies before definitive diagnosis can be made. It is the clinician's responsibility to identify the correct timing and correct site of biopsy in such cases. In the first case, identifying the timing and site of biopsy proved challenging and required close follow up with application of advance imaging to make a favorable decision. There is some debate involved regarding the timing of biopsy with respect to referrals. It has been pointed out that biopsy done prior to specialist referral may result in underestimation of the staging of malignancy. The study by Kaing et al showed no significant difference in professional delay among patients biopsied prior to referral and those who underwent biopsy after specialist referral. They suggested that it is suitable to carry out biopsy and imaging at the tertiary center where definitive treatment will be done (11).

gi slučaj također nije imao karakteristična maligna obilježja te je bolest učena tek na histopatološkim uzorcima. U trećem slučaju, iako se sumnjalo u zloćudnost, privremena dijagnoza kroničnoga traumatskog fibroma postavljena je zato što je lezija bila iznimno bolna, ali nije krvarila, a blago zadebljanje moglo je biti i posljedica kronične lezije.

Kao pomoć u ranijem otkrivanju takvih početnih lezija rabe se razni neinvazivni klinički testovi, a uključuju vitalno bojenje, citološke pretrage, tkivnu fluorescenciju te druge citokemijske i molekularne pretrage. Osim dodatnih troškova, posebno u slučaju molekularnih pretraga, ni jedna nije pokazala potpunu osjetljivost koja bi uputila na upotrebu tih tehnika u rutinskoj kliničkoj praksi (6). Trenutačno se prema dokazima smatra da su vizualni i taktilni pregled te biopsija najbolje metode za rano otkrivanje OKSS-a (7). To pokazuje koliko je važan kliničar zato što je odgađanje u postavljanju dijagnoze moguće samo ako on nije svjestan rizičnih čimbenika i različitih kliničkih oblika OKSS-a. Suprotno tomu, drugi čimbenik koji utječe na zakašnjenje otkrivanja jest nepoznavanje najčešćih kliničkih oblika OKSS-a jer kliničar češće očekuje takav nalaz kod starijih osoba s pozitivnom anamnezom kad je riječ o navikama. Pitiphat i suradnici (8) istaknuli su da je odgoda bila kraća kod pacijenata koji puše. Kerdpona i njegovi kolege (9) nisu, pak, pronašli takvu povezanost između loših navika i odgođenog postavljanja dijagnoze. Kod mlađih osoba, bez loših navika i neobičnoga kliničkog izgleda kao što je u ovom prikazu, OKSS je rijedak. Takvi slučajevi češće se pogrešno dijagnosticiraju i pogrešno liječe, pa je i prognoza lošija, osim ako kliničar nije svjestan moguće zloćudnosti. Trenutak u kojem se obavlja biopsija, tehnika uzimanja biopata te histopatološka procjena nedjeljivi su dio ranog otkrivanja OKSS-a. Gao i suradnici (10) smatrali su da je biopsija uzeta na inicijalnom pregledu, ili najranije tijekom prve pojave znakova, znatno skratila odgodu postavljanja dijagnoze. Visokorizični pacijenti koji se ne prate redovito možda moraju obaviti nekoliko biopsija prije nego što se postavi definitivna dijagnoza. U takvim slučajevima kliničar mora odrediti pravi trenutak i mjesto biopsije. U prvom slučaju je određivanje vremena i mjesta biopsije bilo izazovno i zahtijevalo je strogo praćenje i primjenu naprednih tehnika snimanja kako bi se donijela prava odluka. Uspoređujući upućene pacijente, raspravlja se o vremenu uzimanja biopsije. Istaknuto je da biopsije obavljene prije upućivanja specijalistima mogu rezultirati podcjenjivanjem stupnja malignosti. Kaing i suradnici nisu pronašli značajnu razliku u odgodi u postavljanju dijagnoze pacijentima kojima je biopsija učinjena prije nego što su poslani specijalistu, u usporedbi s onima kojima su biopati uzeti nakon što su bili kod specijalista. Predložili su obavljanje biopsije u tercijarnom centru gdje se provodi liječenje (11). Taj se problem pojavio kod prvog slučaja kada je ekscizijska biopsija učinjena kao dio postupka otkrivanja, nakon čega je pacijentica upućena u drugu bolnicu na liječenje zato što specijalist nije bio u stanju procijeniti stvarnu proširenost lezije iako je imao snimke magnetske rezonancije. Kada nam je to javljeno, odmah smo poslali kliničke fotografije koje su specijalistu pomogle u procjeni opsega lezije. U takvim se slučajevima uvijek preporučuje priložiti detaljne kliničke bilješke s fotografijama (uz pacijentov pri-

This issue was noted in the first case, as excisional biopsy was done as a part of the investigative procedure after which the patient was referred to another center for treatment. Due to this, the specialist was not able to discern the exact clinical extent of the lesion even though MRI images were available. When this was communicated to us, the clinical photographs were promptly sent which aided the specialist to understand the extent of the lesion. Hence, in such cases it is always advisable to supplement meticulous clinical notes with clinical photographs (obtained with patient consent). These cases also emphasize the importance of regular recall & follow up. A study by Groome et al (12) has shown that early diagnosis of OSCC is more likely in patients on regular dental check-ups. Follow up of patients with risk factors and patients who present with atypical symptoms with low suspicion of malignancy is necessary and can be lifesaving. Studies have shown that professional delay in diagnosis can vary from 4 days to 3.5 months (13). Some of the factors associated with professional delay include small tumor size, treatment given prior to definitive diagnosis, increase in number of referrals prior to definitive diagnosis and referrals by general practitioners to specialist without clear description of malignancy or suspicion of malignancy (10, 14).

Studies have shown that most often delays in diagnosis of oral malignancies are due to patient delays. One of the most common causes for delay by patients to seek medical consult is lack of awareness. Patients do not realize the seriousness of the initial symptoms. This may be related to smaller size of the initial lesion. Young patients, and those with lessened tobacco use may have lowered expectation of malignancy, thus considering initial symptoms to be harmless (14, 15). Also certain sites in the oral cavity may not be visually accessible to the patients and lesions may go unnoticed in their incipient stage. Other causes may be psychological stress or denial among patients that may result in delay to seek medical advice (15). This can be dealt with by formulating effective population awareness programs related to oral cancer. Clinicians also have an opportunity to provide patient education and habit counselling when required in their routine dental practice.

The aim of this case series was to highlight the fact that with changing population and uncommon clinical presentations of OSCC, the clinicians should remain alert for lesions of suspicious etiology since early detection of malignancy and intervention can go a long way in the management of this physically and psychologically scarring condition.

Ti slučajevi također ističu koliko su važne redovite kontrole i praćenje. Istraživanje Groome i suradnika (12) pokazalo je da je rano otkrivanje OKSS-a češće kod pacijenata koji se redovito kontroliraju. Praćenje rizičnih pacijenata i onih s netipičnim simptomima i niskom sumnjom na malignost prijeko je potrebno jer može spasiti život. Istraživanja su pokazala da odgoda može trajati od četiri dana do 3,5 mjeseca (13). Neki od čimbenika povezanih s odgodom uključuju malu veličinu tumora, liječenje provedeno prije konačne dijagnoze, povećani broj upućivanja prije konačne dijagnoze te upućivanje koje obavljaju opći doktori dentalne medicine, jasnog opisa malignosti ili sumnje na zloćudnost (10, 14). Istraživanja su pokazala da su najčešće odgode one koje traži pacijent zato što najčešće nije svjestan problema. Naime, pacijenti ne shvaćaju ozbiljnost inicijalnih simptoma, što može biti u vezi s veličinom inicijalne lezije. Mladi pacijenti te oni koji nisu česti uživatelji duhana, rjeđe očekuju zloćudnost pa početne simptome smatraju bezopasnima (14, 15). I neka mjesta u usnoj šupljini nisu vidljiva pa pacijenti jednostavno ne primjećuju lezije u početnoj fazi. Drugi razlozi mogu biti psihološki stres ili negiranje pacijenata koji zbog toga mogu odgađati medicinsku pomoć (15). To se može prevladati učinkovitim programom o razvoju svijesti u populaciji kad je riječ o raku u usnoj šupljini. Kliničari mogu pacijentima u sklopu svojega svakodnevnog rada davati savjete ako je to potrebno.

Svrha opisivanja ovih slučajeva bila je istaknuti činjenicu da, zbog promjena u demografiji i neobičnih kliničkih oblika OKSS-a, kliničari trebaju biti oprezni ako im dođe pacijent s lezijom sumnjive etiologije jer rano otkrivanje i pravodobna intervencija mogu itekako pomoći u rješavanju tih psihički i fizički mutirajućih stanja.

Sažetak

Za oralni rak prosječna je stopa preživljavanja samo 50 %. Ta se prognoza može znatno poboljšati ako se bolest dijagnosticira i liječi u ranoj fazi, a obično se povezuje s klasičnim kliničkim karakteristikama povezanima s malignošću koje rezultiraju točnom dijagnozom. No, neki slučajevi, posebno u ranim fazama, mogu biti klinički varljivi pa se i pogrešno dijagnosticiraju. No postoji noviji trend u demografskim i etiološkim obilježjima koja se povezuju s oralnim karcinomom, a za kliničara su dijagnostički izazovi. Svjesnost o tim trendovima je potrebna kako bi se oralni rak rano dijagnosticirao. Ovdje su opisana tri takva izazovna slučaja.

Zaprimljen: 21. listopada 2017.

Prihvaćen: 2. siječnja 2018.

Adresa za dopisivanje

Junaid Ahmed, Professor
Department of Oral Medicine and
Radiology
Manipal College of Dental Sciences
Mangalore, India
Manipal Academy of Higher
Education, Manipal-576104
junaid.ahmed@manipal.edu

Ključne riječi

Oralni karcinom, stanice raka

References

1. Rhodus NL. Oral cancer: leukoplakia and squamous cell carcinoma. *Dent Clin North Am.* 2005 Jan; 49(1):143-65.
2. Yu T, Wood RE, Tenenbaum HC. Delays in diagnosis of head and neck cancers. *J Can Dent Assoc.* 2008 Feb; 74(1):61.
3. Rao SV, Mejia G, Roberts-Thomson K, Logan R. Epidemiology of oral cancer in Asia in the past decade-an update (2000-2012). *Asian Pac J Cancer Prev.* 2013 Oct; 14(10), 5567-5577.
4. Warnakulasuriya S. Causes of oral cancer--an appraisal of controversies. *Br Dent J.* 2009 Nov; 207(10):471-5.
5. Perry BJ, Zammit AP, Lewandowski AW, Bashford JJ, Dragovic AS, Perry EJ, Hayatbakhsh R, Perry CF. Sites of origin of oral cavity cancer in nonsmokers vs smokers: possible evidence of dental trauma carcinogenesis and its importance compared with human papillomavirus. *JAMA Otolaryngology-Head & Neck Surgery.* 2015 Jan; 141(1):5-11.
6. Kalmar JR. Advances in the detection and diagnosis of oral precancerous and cancerous lesions. *Oral Maxillofac Surg Clin North Am.* 2006 Nov; 18(4):465-82.
7. Rethman MP, Carpenter W, Cohen EE, Epstein J, Evans CA, Flaitz CM, et al. Evidence-based clinical recommendations regarding screening for oral squamous cell carcinomas. *J Am Dent Assoc.* 2010 May; 141(5):509-20.
8. Pitiphat W, Diehl SR, Laskaris G, Cartsos V, Douglass CW, Zavras AI. Factors associated with delay in the diagnosis of oral cancer. *J Dent Res.* 2002 Mar; 81(3):192-7.
9. Kerdpon D, Sriplung H. Factors related to delay in diagnosis of oral squamous cell carcinoma in southern Thailand. *Oral Oncol.* 2001 Feb; 37(2):127-31.
10. Gao W, Guo CB. Factors related to delay in diagnosis of oral squamous cell carcinoma. *J Oral Maxillofac Surg.* 2009 Feb; 67(5):1015-20.
11. Kaing L, Manchella S, Love C, Nastri A, Wiesenfeld D. Referral patterns for oral squamous cell carcinoma in Australia: 20 years progress. *Aust Dent J.* 2016 Mar; 61(1):29-34.
12. Groome PA, Rohland SL, Hall SF, Irish J, Mackillop WJ, O'Sullivan B. A population-based study of factors associated with early versus late stage oral cavity cancer diagnoses. *Oral Oncol.* 2011 Jul; 47(7):642-7.
13. Brouha XD, Tromp DM, Koole R, Hordijk GJ, Winnubst JA, De Leeuw JR. Professional delay in head and neck cancer patients: analysis of the diagnostic pathway. *Oral Oncol.* 2007 Jul; 43(6):551-6.
14. Yu T, Wood RE, Tenenbaum HC. Delays in Diagnosis of Head and Neck Cancers. www.cda-adc.ca/jcda/vol-74/issue-1/61.htm.
15. Llewellyn CD, Johnson NW, Warnakulasuriya S. Factors associated with delay in presentation among younger patients with oral cancer. *Oral Surg Oral Med Oral Pathol Oral Radiol Endod.* 2004 Jun; 97(6):707-13.