

CASE REPORT

Malignant peripheral nerve sheath tumor of the third eyelid in a 3-year-old Rhodesian Ridgeback

Franziska vom Hagen¹, Gwendolyna Romkes¹, Olivia Kershaw² & J. Corinna Eule¹

¹Small Animal Clinic, Faculty of Veterinary Medicine, Freie Universität Berlin, Berlin, Germany

²Department of Veterinary Pathology, Faculty of Veterinary Medicine, Freie Universität Berlin, Berlin, Germany

Correspondence

J. Corinna Eule, Small Animal Clinic, Faculty of Veterinary Medicine, Freie Universität Berlin, Oertzenweg 19b, 14163 Berlin, Germany. Tel: 0049-30-838 62422; Fax: 0049-30-838 460 157; E-mail: corinna.eule@fu-berlin.de

Funding Information

No funding information provided.

Received: 1 May 2014; Revised: 28 July 2014; Accepted: 23 August 2014

Clinical Case Reports 2015; 3(1): 50–56

doi: 10.1002/ccr3.146

Key Clinical Message

A 3-year-old Rhodesian Ridgeback was presented with conjunctivitis, enlargement of the third eyelid and a dorsotemporal deviation of the right eye. A mass within the third eyelid was detected and excised. The histopathologic examination showed a malignant peripheral nerve sheath tumor, which most likely is a neurofibrosarcoma based on immunohistochemistry.

Keywords

Dog, neoplasia, nictitans, orbita, periocular.

Introduction

Exophthalmos and protrusion of the third eyelid are common clinical signs of dogs with periocular or retrobulbar diseases [1–3]. The possible causes in dogs are: orbital neoplasia, abscess, cellulitis, orbital bone lesions, vascular anomalies, cysts, salivary mucocele, noninfectious inflammatory diseases and orbital fat prolapse after trauma.

Orbital neoplasia (52%) was the most common cause of retrobulbar disease in a group of 50 dogs [4]. Within the orbit any tissue component may give rise to neoplasms [5]. Canine orbital neoplasia is predominantly primary and is typically malignant [2, 6]. Neoplasia of the third eyelid in dogs is rare [7]. Most commonly, adenoma or adenocarcinomas are present in this location [5, 7]. Other tumors of the third eyelid, that is, melanomas, squamous cell carcinomas, mast cell tumors, papillomas, and hemangiosarcomas have been described [8]. In a cat, a case of fibrosarcoma of the third eyelid has been reported [9].

Peripheral nerve sheath tumors (PNST) are a group of mesenchymal neoplasms and usually arise from peripheral nerve sheaths [10].

Neurofibrosarcomas, belonging to the group of PNST, originating primarily from periocular structures are extremely rare in humans [11]. Only a few human case reports describe orbital neurofibrosarcomas, of which one arose from the orbital lacrimal gland [12]. One case of retrobulbar neurofibrosarcoma has been described in a dog [13].

To the author's knowledge, in dogs, a case of PNST of the third eyelid has so far not been published.

Case Report

A 3-year-old male neutered Rhodesian Ridgeback dog was presented due to chronic conjunctivitis and enlargement of the third eyelid.

The owner reported that the dog was alert with normal food and water intake, and in good general health. Three weeks before the dog was presented at the clinic the owner's observed redness and serous discharge of the right eye without blepharospasm. One week before the dog was examined by the local veterinarian and a mass of the third eyelid was suspected. The dog was treated topically with gentamicin and dexamethasone ointment TID (Dexamytex[®]; Dr. Mann Pharma, Berlin, Germany), and

systemically the dog received amoxicillin (10 mg/kg BID p.os) and dexamethasone (0.1 mg/kg s.c. once; Hexadren[®]; MSD, Unterschleißheim, Germany).

Clinical and ophthalmic examination

The dog was alert and the general examination was normal except for a slightly enlarged right mandibular lymph node and also the dog did not show signs of pain upon opening the mouth.

Both eyes (OU) were held open comfortably, no discharge was present and menace response was positive. The palpebral, dazzle, and pupillary light reflexes were also positive OU. Upon inspection of the right eye (OD), an elevated third eyelid, conjunctival hyperemia and a dorso-temporal deviation of the globe were present. Retropulsion was possible, but nasal and nasoventral pulsion of the globe was limited. The oculocephalic reflex was not assessed. Tear production was 23 mm/min for the right eye (Schirmer tear test, MSD, Unterschleißheim, Germany). Closer inspection revealed that the pigmented rim of the third eyelid was displaced ~0.5 cm away from the globe due to a mass, which was present in the entire visible bulbar aspect of the third eyelid (Fig. 1). Under local anesthesia with oxybuprocaine hydrochloride eye drops (Novesine 0.4%[®]; OmniVision, Puchheim, Germany), the third eyelid was moveable and the mass seemed to extend to the base of the third eyelid. Jones I test was positive. The cornea of the right eye was clear and failed to retain fluorescein stain; in addition, the anterior chamber was also clear. The iris was homogeneously colored and the pupil of medium size was responsive to light. Lenticular changes were not observed, a fundic examination was not performed and the intraocular pressure was 22 mmHg (TonoVet[®] Icare, Helsinki, Finland). The left eye (OS) was normal, had a tear production of 24 mm/min and an intraocular pressure of 15 mmHg.

Laboratory diagnostics, surgical management, and therapy

A fine needle aspirate (24G needle, 0.55 × 25 mm, 2 mL syringe) of the third eyelid mass, obtained under local anesthesia (oxybuprocaine hydrochloride, Novesine[®] 0.4%; OmniVision GmbH, Puchheim, Germany) was not diagnostic as no cells could be retrieved from the solid mass. Cytology of a fine-needle aspirate of the ipsilateral mandibular lymph node was unremarkable. Thoracic radiographs did not reveal any signs of lung metastasis. Blood tests (complete blood count and serum biochemistry) were within normal limits except for a mild thrombocytopenia of 123×10^9 cells/L (range 150–500 × 10⁹ cells/L). As a tumor of the third eyelid was suspected, further diagnostic procedures under general anesthesia were scheduled. The systemic antibiotic treatment started by the local veterinarian was discontinued and the local treatment for the right eye was changed to eye drops containing dexamethasone, polymyxin B and neomycin TID (Maxitrol[®], Alcon, Puurs, Belgium).

A week later, the dog was presented for examination under general anesthesia. Anesthetic induction was achieved with midazolam (0.5 mg/kg, Midazolam[®]; B. Braun, Melsungen, Germany) and propofol (Narcofol[®]; CP Pharma, Burgdorf, Germany) i.v. and the dog was intubated. The mass had increased in size and the right globe was further deviated dorso-temporally. Ultrasound imaging revealed a third eyelid mass of 2.3 × 2.7 cm. The mass had a homogenous echotexture and was well delineated from the globe and orbital structures by a hyperechoic rim. The globe was shifted dorso-temporal and seemed to be nasally slightly indented by the mass. Further diagnostic imaging (computer tomography or magnetic resonance imaging) was recommended, but was refused by the owners. They decided against an

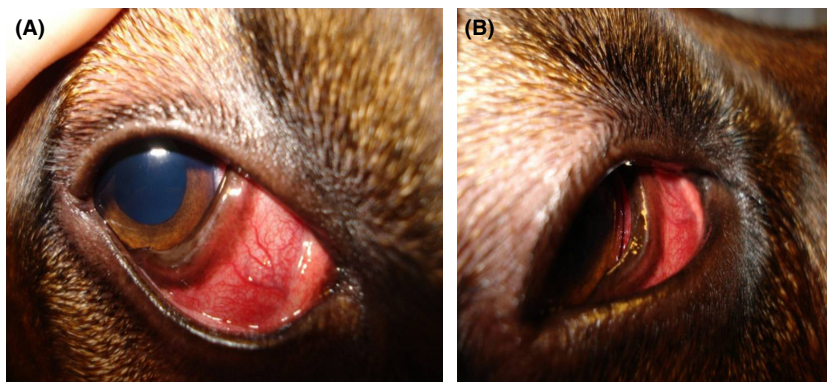


Figure 1. Clinical picture of a 3-year-old Rhodesian Ridgeback, which was presented with protrusion of the third eyelid. Upon inspection the enlargement of the nictitans and a temporodorsal deviation of the globe were present (A and B).

exenteration and gave only their consent to perform a resection of the third eyelid with the mass.

Anesthesia was maintained with levomethadone (0.5 and 0.026 mg/kg fentanyl i.v., L-Polamivet[®]; MSD, Unterschleißheim, Germany), inhalation anesthesia (isoflurane/oxygen) and mechanical ventilation was used during surgery. The skin around the eye was aseptically prepared with diluted iodine solution (0.2% in 0.9% saline solution) and the ocular surface was extensively rinsed with sterile 0.9% saline solution, in a routine fashion. First a temporal canthotomy was performed and an eyelid speculum was placed to allow better visualization. Grossly, the mass within the third eyelid was covered by conjunctiva and appeared well demarcated from the surrounding tissue. The third eyelid was grasped with a von Graefe forceps, the palpebral conjunctiva was opened and the grossly well demarcated mass was bluntly dissected with Stevens scissors from the surrounding normal tissue and from the periosteum to which the mass did not adhere. Toward the nasal canthus, the lacrimal caruncle was left intact and the palpebral conjunctiva was left about 4–5 mm to the lid margin. The lacrimal puncta and canaliculi were left intact. The tissue deep to the mass was ligated (vicryl 4/0; Ethicon, Hamburg, Germany). Following resection, grossly the mass seemed to be removed with clean margins (Fig. 2). The bleeding was stopped by local application of epinephrine solution (Adrenalin 1:1000[®]; 1 mg/mL, Infectopharm, Heppen-

heim, Germany), the conjunctiva was ventronasally closed with a continuous suture (vicryl 6/0) and the dorsonasal aspect was left open for secondary healing. The canthotomy wound was closed with a figure of eight suture (nylon 4/0, Ethilon[®]; Ethicon, Hamburg; Germany) and a temporary tarsorrhaphy was placed nasally (nylon 4/0 and two pieces of silicone tubing). The dog recovered well from anesthesia. Postoperatively the dog was treated topically on the right eye with a broad-spectrum antibiotic (polymyxin B, neomycin, gramicidin; Polyspektran[®]; Alcon, Puurs, Belgium) eye drops QID and the ocular surface was rinsed with ocular cleaning solution BID (ocular cleaning solution, Augenreiniger[®]; Albrecht, Aulendorf, Germany). Systemically the dog received amoxicillin/clavulanic acid (12.5 mg/kg BID oral, Clavaseptin[®]; Vetoquinol, Ravensburg, Germany) and carprofen (4 mg/kg SID oral, Rimadyl[®]; Pfizer, Berlin, Germany) and an Elizabethan collar was placed.

For histopathology, the tissue was fixed in 4% formalin for 24 h and representative samples were embedded in paraffin using standard laboratory procedures. Sections (3 μ m) of dewaxed tissues were stained with hematoxylin and eosin (H&E). Microscopic investigation revealed a mesenchymal, highly proliferative mass characterized by short interlacing streams, and bundles of closely packed spindle-shaped cells arranged in a storiform to herringbone pattern with few whorls (Fig. 3). Neoplastic cells had large vesiculated nuclei and the mitotic rate was high

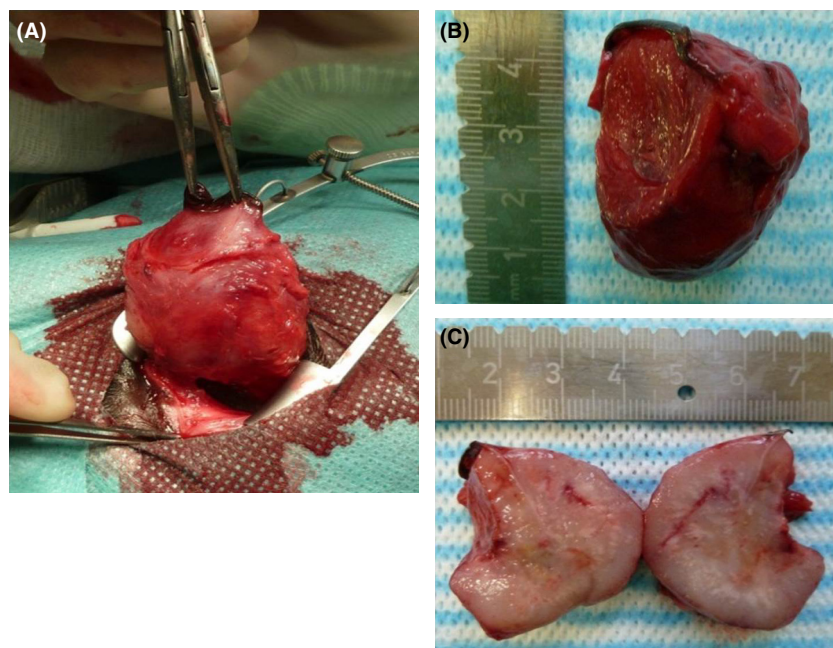


Figure 2. The third eyelid and the mass appeared grossly to be completely removed by surgery (A) and was sent for histopathologic analysis (B and C).

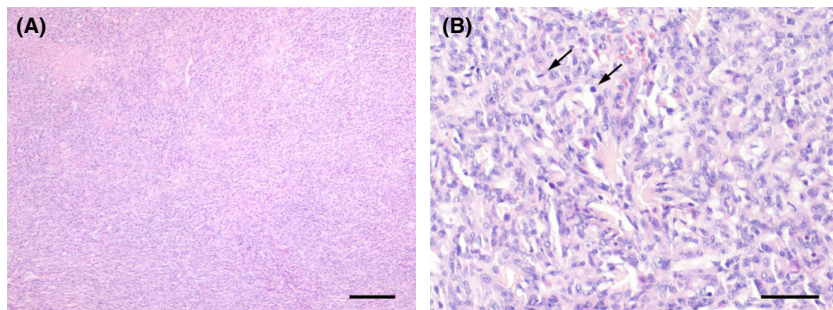


Figure 3. Low power (A) and high power (B) photomicrographs of hematoxylin and eosin stained sections of the excised tumor within the nictitans. Arrows indicate mitotic figures. Bars: 200 μm (A) and 50 μm (B).

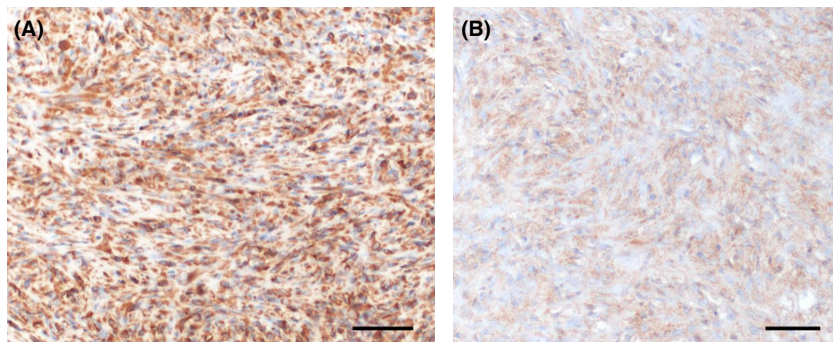


Figure 4. Immunohistochemical staining of the tumor tissue. Virtually all cells were positive for vimentin (A) and up to 50% of the cells were positive for S-100 (B). Bars: 50 μm .

with up to ten mitoses per high power field. Multifocally, there was evidence of invasion into preexisting structures and necrosis. The cartilage and gland of the third eyelid were mostly replaced by the tumor and only necrotic remnants of the cartilage were detectable. Surgical excision margins were narrow with only a small amount of normal tissue detectable in areas with invasive tumor extension.

Additionally, sections were stained immunohistochemically for vimentin (clone V9, 1:100; Dako, Hamburg, Germany), S100 (polyclonal rabbit anti-S100A, 1:800; Dako, Hamburg, Germany), glial fibrillary acidic protein (GFAP, polyclonal rabbit anti-GFAP, 1:3000; Dako, Hamburg, Germany), and cytokeratin (clones AE1/AE3, 1:500; Dako, Hamburg, Germany) to further characterize the neoplastic cells. Immunohistochemistry for vimentin, a marker staining intermediate filaments of mesodermal origin, found virtually in all the cells to be positive (Fig. 4A). Additionally, up to 50% of the cells stained positive for S-100 (Fig. 4B), indicating cells derived from the neural crest. Neurofibrosarcomas are usually positive for vimentin and S-100. Staining for GFAP, an intermediate filament expressed mainly in astrocytes and variably

in Schwann cells, was negative. An epithelial tumor origin was excluded by lack of staining for cytokeratin.

In conclusion, the histopathologic findings led to the diagnosis of a malignant PNST of the third eyelid, most likely a neurofibrosarcoma based on the immunohistochemical results.

Outcome/follow-up

One week after surgery, the dog was presented for a re-examination and the general health status was found to be normal. After the temporary tarsorrhaphy was removed, the ocular structures were inspected. The sutures of the canthotomy were in place, the wound was dry and irritation-free. The conjunctiva had healed and the examination of the eye was normal. Based on the histopathological diagnosis an exenteration with removal of the globe and all periocular soft tissue structures leaving the orbital bones covered by the eyelid skin or, if the eyelids would have been extensively resected, a caudal auricular axial pattern flap was recommended [14]. In addition, postoperative radiation therapy was advised, but the owner's refused further surgical and/or radiation

therapy. The topical treatment was continued until removal of the canthotomy sutures, which was 2 weeks after surgery and this was performed at the local veterinarian.

Due to the long distance to the university clinic the dog was not presented again. The owners reported that 7 months after the surgery a mass had reoccurred at the right eye/orbit, which was not further diagnosed. Nine months after surgery the dog developed: ataxia, incontinence, vomiting, and was subsequently euthanized at the local veterinarian. A necropsy was refused by the owners.

Discussion

The presented case of a malignant PNST, most likely a neurofibrosarcoma is unique because of its very likely primary localization in the third eyelid. Immunophenotyping was essential for the classification of the described tumor as neurofibrosarcoma.

Based on the World Health Organization (WHO) classification for soft-tissue tumors in humans these tumors are further sub grouped by being benign (BPNST) or malignant (MPNST). Further classification is based on the origin of tumor cells such as the Schwann cell for the benign Schwannomas, or the perineural fibroblast for benign neurofibromas, or the malignant neurofibrosarcomas. The classification of soft-tissue sarcomas in dogs follows the WHO scheme [15] except for cutaneous and subcutaneous soft-tissue sarcomas, which include non-brachial plexus PNST and exclude brachial plexus PNST [16]. However, some controversy about terminology and classification exists in the literature. According to [17] and [18] only two types of PNST occur in dogs: one arising in cranial or spinal nerves and the others in the cutaneous and subcutaneous tissue. According to [19] PNST may be the most common type of cutaneous and subcutaneous soft-tissue sarcomas in dogs.

Clinically, soft-tissue sarcomas and of those especially PNST and fibrosarcomas are characterized by slow growth and rare metastasis [20]. Grossly, PNST often appear encapsulated, albeit microscopically infiltrative and unencapsulated [20]. Similarly, in our case the tumor of the third eyelid grossly appeared encapsulated, but no capsule was present at light microscopy level as described for PNST [16].

Histologic hallmark of PNST are interwoven bundles of neurofibroblasts, forming whorls around collagen bundles and Antoni A and B patterns [16]. Fibrosarcomas are histologically characterized by well differentiated spindle cells in interwoven bundles with a herringbone pattern and surrounded by collagenous stroma [16]. In the tumor described here, both patterns were present and thus final differentiation by histology was not possible. Lack of

specific histological differences of these tumors is a common problem in human as well as in veterinary medicine [21, 22].

Immunohistochemistry studies have contributed to diagnostic criteria for the definition of PNST in humans and in animals. Vimentin and S-100 are used to distinguish between spindle cell tumors of non-neural and neural origin [23]. Vimentin is usually positive in PNST and fibrosarcomas [16]. While PNSTs are positive for S-100, fibrosarcomas are negative [16]. In our case up to 50% of the tumor cells expressed S-100. A variable expression of S-100 has been previously reported for PNST in dogs [21]. Astrocytes and Schwann cells express GFAP, but lack of staining does not exclude PNST as staining in these tumors can be variable [16, 21]. The staining characteristics of the tumor we describe are consistent with a PNST.

The distinction between malignant and BPNST in histopathology is based on several features, such as mitotic rate, anisocytosis, anisocaryosis, and invasiveness into the surrounding tissue. In our case, the tumor destroyed almost completely the normal tissue structure of the third eyelid, such as the third eyelid cartilage and the gland of the third eyelid. Additionally, the tumor had a high mitotic rate, was invasive and hence classified as malignant.

In conclusion, based on clinical behavior, gross and microscopic appearance, and immunophenotype, the tumor in our case was considered an MPNST, which was most likely a neurofibrosarcoma.

In canines soft-tissue sarcomas occur in middle aged to older dogs with a trend toward medium to large breed dogs [22]. Similarly, in humans, mainly adults can be affected by MPNST but rarely develops during childhood. [10] In patients with neurofibromatosis 1 (NF1) or *von Recklinghausen* disease, an autosomal dominantly inherited disorder, MPNST is the most common malignancy associated with this disease. NF1 patients with MPNST are younger at diagnosis, more males seem to be affected and outcome is poorer. Our patient did not show clinical signs of this disease, such as pigmented skin lesions or bony dysplasia.

For soft tissue sarcomas, a radical surgical resection with wide tumor-free margins can be therapeutic [24]. For orbital neoplasia, possible surgical approaches are exenteration with removal of the globe and all periocular structures, partial or total orbitectomy [25, 26]. Subsequent radiotherapy is recommended for soft tissue sarcomas, especially if the anatomic location impedes complete resection [24, 27]. Recurrence follows frequently and tumors metastasize at a low rate to the lung [24]. For soft tissue sarcomas, prognosis depends on many factors such as tumor type, tumor size, tumor location, invasiveness, histologic grade, degree of resection, and completeness of surgical margins [16].

In our case, the complete tumor seemed to be excised, but 3 cm wide-free margins were anatomically not feasible. With the histopathological diagnosis exenteration and/or postoperative radiotherapy was strongly recommended to the owners, but was refused. A poor prognosis was given. The growth of a mass at the site of surgery reported by the owners, which was not further diagnosed, was most likely a regrowth. Retrospectively, it is not clear whether the systemic symptoms leading to euthanasia 9 months postsurgery were correlated to the reoccurrence of the orbital mass.

We have described the case of a 3-year-old Rhodesian Ridgeback dog with a fast growing mass within the third eyelid. Based on the histopathological findings and immunophenotyping, it was classified as an MPNST, most likely a neurofibrosarcoma. To our knowledge, this is the first report of a tumor at this location in a dog.

Conflict of Interest

None declared.

References

1. Armour, M. D., M. Broome, G. Dell'anna, N. J. Blades, and D. W. Esson. 2011. A review of orbital and intracranial magnetic resonance imaging in 79 canine and 13 feline patients (2004–2010). *Vet. Ophthalmol.* 14:215–226.
2. Attali-Soussay, K., J. P. Jegou, and B. Clerc. 2001. Retrobulbar tumors in dogs and cats: 25 cases. *Vet. Ophthalmol.* 4:19–27.
3. Boroffka, S. A., A. M. Verbruggen, G. C. Grinwis, G. Voorhout, and P. Y. Barthez. 2007. Assessment of ultrasonography and computed tomography for the evaluation of unilateral orbital disease in dogs. *J. Am. Vet. Med. Assoc.* 230:671–680.
4. Mason, D. R., C. R. Lamb, and G. J. McLellan. 2001. Ultrasonographic findings in 50 dogs with retrobulbar disease. *J. Am. Anim. Hosp. Assoc.* 37:557–562.
5. Labelle, A. L., and P. Labelle. 2013. Canine ocular neoplasia: a review. *Vet. Ophthalmol.* 16(Suppl. 1):3–14.
6. Hendrix, D. V., and K. N. Gelatt. 2000. Diagnosis, treatment and outcome of orbital neoplasia in dogs: a retrospective study of 44 cases. *J. Small Anim. Pract.* 41:105–108.
7. Wilcock, B., and R. Peiffer Jr. 1988. Adenocarcinoma of the gland of the third eyelid in seven dogs. *J. Am. Vet. Med. Assoc.* 193:1549–1550.
8. Schäffer, E. H., S. Pfleghaar, S. Gordon, and M. Knödseder. 1994. Maligne Nickhauttumoren bei Hund und Katze. *Tierärztl. Prax.* 22:382–391.
9. Buyukmihici, N. 1975. Fibrosarcoma of the nictitating membrane in a cat. *J. Am. Vet. Med. Assoc.* 167:934–935.
10. Thway, K., and C. Fisher. 2014. Malignant peripheral nerve sheath tumor: pathology and genetics. *Ann. Diagn. Pathol.* 18:109–116.
11. Tanwar, R. K., R. Kumar, S. Malik, R. Dhir, and G. K. Rath. 1995. Orbital neurofibrosarcoma: a case report. *Indian J. Pathol. Microbiol.* 38:91–94.
12. Pattanayak, S. P., J. S. Mathur, V. Thakur, and S. Khanna. 1987. Neurofibrosarcoma of lacrimal gland. *Indian J. Ophthalmol.* 35:44–48.
13. Andrew, S. E. 1999. Orbital neurofibrosarcoma in a dog. *Vet. Ophthalmol.* 2:141–145.
14. Stiles, J., W. Townsend, M. Willis, P. A. Moore, and E. Smith. 2003. Use of a caudal auricular axial pattern flap in three cats and one dog following orbital exenteration. *Vet. Ophthalmol.* 6:121–126.
15. Koestner, A., T. Bilzer, R. Fatzer, F. Y. Schulman, B. A. Summers, and T. J. Van Winkle. 1999. World Health Organization, International histological classification of tumors of domestic animals. Armed Forces Institute of Pathology, American Registry of Pathology, Washington, DC.
16. Dennis, M. M., K. D. McSparran, N. J. Bacon, F. Y. Schulman, R. A. Foster, and B. E. Powers. 2011. Prognostic factors for cutaneous and subcutaneous soft tissue sarcomas in dogs. *Vet. Pathol.* 48:73–84.
17. Meuten, D. J. 2002. Tumors of the skin and soft tissues. Iowa State Press, Ames.
18. Tavasoly, A., J. Javanbakht, F. Khaki, E. Hosseini, A. Bahrami, M. A. Hassan, et al. 2013. Ulnar malignant peripheral nerve sheath tumour diagnosis in a mixed-breed dog as a model to study human: histologic, immunohistochemical, and clinicopathologic study. *Diagn. Pathol.* 8:86.
19. Kuntz, C. A., W. S. Dernell, B. E. Powers, C. Devitt, R. C. Straw, and S. J. Withrow. 1997. Prognostic factors for surgical treatment of soft-tissue sarcomas in dogs: 75 cases (1986–1996). *J. Am. Vet. Med. Assoc.* 211:1147–1151.
20. Liptak, J. M., and L. J. Forrest. 2007. Soft tissue sarcomas. Saunders, St. Louis, MO.
21. Chijiwa, K., K. Uchida, and S. Tateyama. 2004. Immunohistochemical evaluation of canine peripheral nerve sheath tumors and other soft tissue sarcomas. *Vet. Pathol.* 41:307–318.
22. Dernell, W. S., S. J. Withrow, C. A. Kuntz, and B. E. Powers. 1998. Principles of treatment for soft tissue sarcoma. *Clin. Tech. Small Anim. Pract.* 13:59–64.
23. Koestner, A., and R. J. Higgins. 2002. Primary tumors of the peripheral nervous system. Iowa State University Press, Ames.
24. Ehrhart, N. 2005. Soft-tissue sarcomas in dogs: a review. *J. Am. Anim. Hosp. Assoc.* 41:241–246.

25. Boston, S. E. 2010. Craniectomy and orbitectomy in dogs and cats. *Can. Vet. J.* 51: 537–540.
26. O'Brien, M. G., S. J. Withrow, R. C. Straw, B. E. Powers, and J. K. Kirpensteijn. 1996. Total and partial orbitectomy for the treatment of periorbital tumors in 24 dogs and 6 cats: a retrospective study. *Vet. Surg.* 25:471–479.
27. Ettinger, S. N. 2003. Principles of treatment for soft-tissue sarcomas in the dog. *Clin. Tech. Small Anim. Pract.* 18:118–122.