

CASE REPORT

Isolated shoulder weakness as a result of a cortical infarction in the precentral gyrus

Pouya Entezami, BS^{1*} and John A. Hopper, MD²

¹University of Toledo Medical Center, Toledo, OH, USA; ²St. Joseph Mercy Medical Center, Ann Arbor, MI, USA

Since its discovery, our understanding of the primary motor cortex has continued to evolve. The presentations of rare, isolated, motor palsies of small muscle groups have heavily contributed to the characterization of the somatotopic representation of the human body on the cortex. We present a case of localized, left shoulder small muscle group weakness secondary to ischemic cerebral infarction in the primary motor cortex. The patient experienced full recovery over several days. Strokes causing isolated shoulder weakness are rare due to the relatively small area dedicated to shoulder motor function in the precentral gyrus. However, our patient presented with a larger area of infarction than in previously reported cases, demonstrating the large individual variability that may exist within the motor cortex somatotopic map.

Keywords: *stroke; shoulder paresis; weakness*

*Correspondence to: Pouya Entezami, University of Toledo Medical Center, 3000 Arlington Avenue, Toledo, OH 43614, USA, Email: pouya.entezami@utoledo.edu

Received: 1 November 2014; Revised: 25 December 2014; Accepted: 19 January 2015; Published: 1 April 2015

The primary motor cortex in the posterior frontal lobe (Brodmann area 4) was first described by David Ferrier in 1874, who used electrical stimulation to map the cortical areas responsible for movement in monkeys (1). Since these initial findings, the description of this area has evolved to include the concept of a somatotopic map, wherein different parts of the body are represented individually on the primary motor cortex, as observed by Penfield and Boldrey (2). Though motor palsies of small muscle groups (i.e., a limited number of muscles controlled by a small area of the motor cortex) have been previously reported (3–5), these cases – particularly those with isolated shoulder palsy – are exceedingly rare. Here we describe a patient who suffered a small cortical infarction resulting in isolated shoulder weakness.

Case report

A 62-year-old right-handed male with a medical history significant for peripheral arterial disease, hypertension, and hypercholesterolemia presented approximately 24 hours after the sudden onset of isolated left upper extremity weakness while he was mowing his lawn. He noticed difficulty lifting his arm at the shoulder. He denied arthralgias or myalgias and could not recall trauma that could have precipitated his symptoms. On admission he was alert and oriented, and cooperative to examination. Visual

inspection of the left upper extremity revealed no areas of erythema or swelling; however, shoulder height on the left was one inch lower than the right. Manual muscle testing demonstrated normal 5/5 motor strength for the left fingers, hand, wrist, and elbow flexors and extensors, but 1/5 for shoulder abduction. He found the most difficulty with initiating left shoulder abduction from his side (action of the supraspinatus muscle, supplied by the subscapular nerve) but could resume abduction once his shoulder was assisted to roughly 30° of abduction. There was no weakness with shoulder adduction, internal or external rotation, or flexion. Additionally, he demonstrated weakness in the left trapezius muscle with shoulder shrug, but no concurrent weakness in the sternocleidomastoid muscle (both controlled by cranial nerve XI). Brachioradialis, biceps, and triceps reflexes were intact and symmetrical bilaterally, and his neurological examination was otherwise grossly intact, with no sensory deficits or a positive Babinski sign.

Initial non-contrast computed tomography (CT) imaging did not reveal evidence of an acute intracranial hemorrhage, and an X-ray of the shoulder was negative for acute injury or dislocation. Subsequent neurological examinations throughout the first day of admission revealed gradual improvement in the patient's motor strength. Non-contrast magnetic resonance imaging (MRI) was ordered, revealing an acute infarction on diffusion weighted MRI

(DWI), corresponding to the motor cortex in the precentral gyrus (Fig. 1).

Our patient received a CT-angiogram of the head and neck, which demonstrated severe (>90%) stenosis of the right carotid artery (Fig. 2). On day 4 of his hospital stay, the patient underwent right carotid endarterectomy with no complications and was discharged home the day after the procedure. Immediately prior to discharge, he described having returned to his baseline level of functionality, although on examination he continued to demonstrate slightly diminished, 4+/5 strength in his shoulder on abduction of the left arm.

Discussion

Our patient demonstrated painless weakness in the left trapezius, deltoid, and supraspinatus muscles. Descending signals controlling motor function originate from first-order neurons in the motor cortex in the precentral gyrus. These neurons then traverse caudally through the internal capsule, the pyramids, the medullary decussations, and ultimately down the spinal cord where they synapse onto second-order neurons in the anterior horn gray matter. From this point, peripheral nerves containing these second-order neurons carry motor signals to the shoulder muscles through the brachial plexus and its nerve roots to the various shoulder muscles.

Although initially considered, the deficit pattern seen in our patient could not be attributed to peripheral neuropathy. One important finding was the lack of sensory loss, which is possible but very unlikely in peripheral nerve lesions. The subscapular nerve supplies both the supraspinatus and infraspinatus muscles, and the skin overlying the deltoid. As the patient did not suffer from any concurrent sensory loss – and in lieu of MRI findings of cerebral infarction – the most likely etiology for this

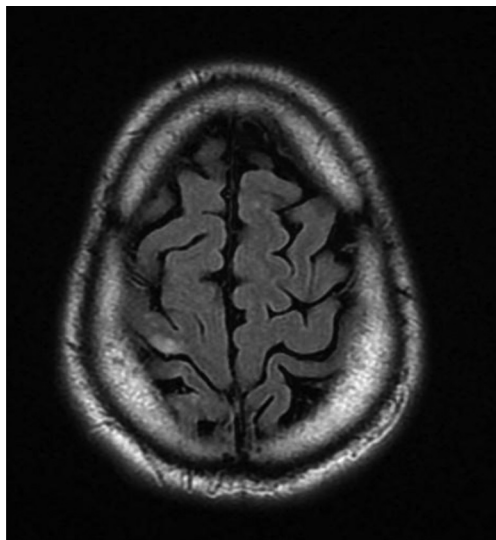


Fig. 1. Axial diffusion-weighted MRI imaging demonstrating acute ischemic infarction of the primary motor cortex.

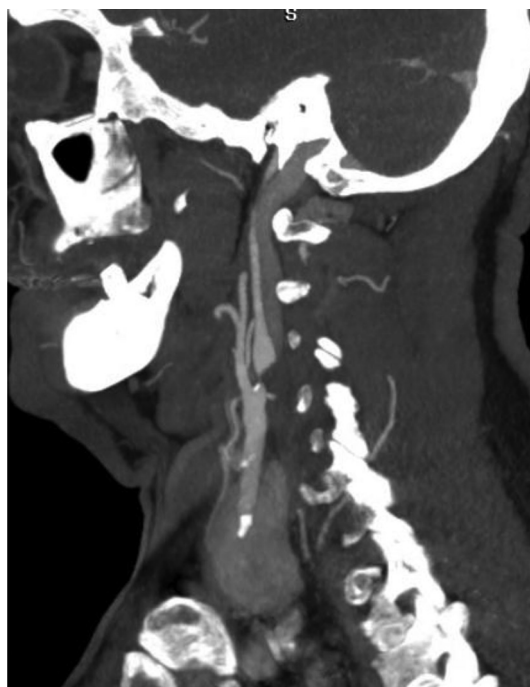


Fig. 2. Sagittal CT-angiogram showing severe stenosis of the right carotid artery.

motor weakness was deemed to be a true cerebrovascular accident rather than a peripheral nerve pathology.

The finding of isolated shoulder weakness as a result of stroke has been reported previously in six patients (6–11), three of whom regained functionality soon after the event, in a similar fashion to our patient. Recovery of proximal muscle function following a stroke is generally more rapid and complete than for distal muscles. Several mechanisms have been proposed to account for this phenomenon, including contributions from ipsilateral or contralateral corticospinal projections or polysynaptic pathways from brain regions unaffected by the stroke, which may result in a reduction or even a recovery of motor deficit suffered by the patient (6).

The acute lesion observed in our patient – corresponding to increased signal intensity on DWI – is found in the precentral gyrus; the primary motor cortex. This area is supplied by branches of the middle cerebral artery (7). Generally, the projection of the shoulder in the motor cortex is small, lending explanation to the rarity of ischemic injury presenting with isolated shoulder palsy. However, our patient had a large area of involvement on imaging, despite having no other discernible deficits. This case emphasizes the complexity of these projections on the motor cortex, as even among the small number of cases previously reported, the area of infarct is not well-defined.

Conclusions

The clinical diagnosis of an isolated motor deficit such as shoulder weakness following a stroke is difficult and

requires a high index of suspicion based on a thorough history so as to make a correct diagnosis. Significant individual differences likely exist in the somatotopic map in the motor cortex, which should be accounted for by correlating both clinical and MRI findings.

Conflict of interest and funding

The authors declare that they have no conflicts of interest concerning this article.

References

1. Ferrier D. Experiments on the brain of monkeys – No. I. *Proc R Soc Lond* 1874; 23: 409–30.
2. Penfield W, Boldrey E. Somatic motor and sensory representations in the cerebral cortex of man as studied by electrical stimulation. *Brain* 1937; 60: 389–443.
3. Phan TG, Evans BA, Huston J. Pseudounilateral palsy from a small infarct of the precentral knob. *Neurology* 2000; 54(11): 2185.
4. Kim JS, Chung JP, Ha SW. Isolated weakness of index finger due to small cortical infarction. *Neurology* 2002; 58(6): 985.
5. Kim JS. Predominant involvement of a particular group of fingers due to small, cortical infarction. *Neurology* 2001; 56(12): 1677–82.
6. Uncini A, Caporale CM, Caulo M, Ferretti A, Tartaro A, Ranieri F, et al. Isolated shoulder palsy due to cortical infarction: Localisation and electrophysiological correlates of recovery. *J Neurol Neurosurg Psychiatry* 2007; 78(1): 100–02.
7. Tsuda H, Shinozaki Y, Tanaka K, Miura Y, Kishida S, Karasawa K. Isolated shoulder palsy due to infarction of the cortical branch of the middle cerebral artery. *Intern Med* 2012; 51(16): 2217–19.
8. Tsuda H, Kubota Y, Tanaka K, Kishida S. Isolated shoulder palsy due to a cortical infarction. *Intern Med* 2011; 50(8): 947.
9. Nah HU, Park HK, Kang DW. Isolated shoulder weakness due to a small cortical infarction. *J Clin Neurol* 2006; 2(3): 209–11.
10. Komatsu K, Fukutake T, Hattori T. Isolated shoulder paresis caused by a small cortical infarction. *Neurology* 2003; 61(10): 1457.
11. Kawasaki A, Suzuki K, Takekawa H, Kokubun N, Yamamoto M, Asakawa Y, et al. Isolated shoulder palsy due to cortical infarction: A case report and literature review of clinicoradiological correlations. *J Stroke Cerebrovasc Dis* 2013; 22(8): 687–90.