

# Protective effects of *Aegle marmelos* fruit pulp on 2,4,6-trinitrobenzene sulfonic acid-induced experimental colitis

Rohit R. Ghatule, Manish K. Gautam, Shalini Goel<sup>1</sup>, Amit Singh, Vinod K. Joshi<sup>2</sup>, Raj K. Goel

Departments of Pharmacology, and <sup>2</sup>Dravyaguna, Institute of Medical Sciences, Banaras Hindu University, Varanasi, Uttar Pradesh, <sup>1</sup>Department of Pathology and Lab Medicine, Medanta - The Medicity, Gurgaon, Haryana, India

Submitted: 20-02-2013

Revised: 14-04-2013

Published: 21-02-2014

## ABSTRACT

**Background:** *Aegle marmelos* (AM) fruit has been advocated in indigenous system of medicine for the treatment of various gastrointestinal disorders, fever, asthma, inflammations, febrile delirium, acute bronchitis, snakebite, epilepsy, leprosy, myalgia, smallpox, leucoderma, mental illnesses, sores, swelling, thirst, thyroid disorders, tumours and upper respiratory tract infections.

**Objective:** The objective of this study was to study the curative effect of 50% ethanol extract of dried fruit pulp of AM (AME) against 2,4,6-trinitrobenzene sulfonic acid (TNBS)-induced experimental colitis. **Materials and Methods:** AME (200 mg/kg) was administered orally, once daily for 14 days after TNBS-induced colitis. Rats were given intracolonic normal saline or TNBS alone or TNBS plus oral AME. AME was studied for its *in vitro* antibacterial activity against Gram-negative intestinal bacteria and on TNBS-induced changes in colonic damage, weight and adhesions (macroscopic and microscopic), diarrhea, body weight and colonic levels of free radicals (nitric oxide and lipid peroxidation), antioxidants (superoxide dismutase, catalase and reduced glutathione) and pro-inflammatory marker (myeloperoxidase [MPO]) in rats. **Results:** AME showed antibacterial activity against intestinal pathogens and decreased colonic mucosal damage and inflammation, diarrhea, colonic free radicals and MPO and enhanced body weight and colonic antioxidants level affected by TNBS. The effects of AME on the above parameters were comparable with sulfasalazine, a known colitis protective drug (100 mg/kg, oral). **Conclusion:** AME shows curative effects against TNBS-induced colitis by its antibacterial activity and promoting colonic antioxidants and reducing free radicals and MPO-induced colonic damage.

**Key words:** *Aegle marmelos* fruit, antioxidants, free radicals, myeloperoxidase, 2,4,6-trinitrobenzene sulfonic acid-induced colitis

## INTRODUCTION

In ulcerative colitis, the colon becomes inflamed, often causing recurring abdominal pain including diarrhea, blood in the stool and weight loss.<sup>[1]</sup> Genetic, immunological, reactive oxygen species (ROS) and environmental factors have been reported to play an important role in the genesis of UC.<sup>[2-4]</sup>

*Aegle marmelos* (AM) (Rutaceae) is known as bael in Hindi and srīpal or bilwa in Sanskrit. AM tree is indigenous to hills and plains of Indian subcontinent and South East Asian countries. Fruits are woody-skinned, 5-15 cm in diameter

and have numerous seeds, embedded in a thick, gluey, aromatic pulp. Fruit is traditionally used to treat jaundice, constipation, chronic diarrhoea, dysentery, stomach-ache, fever, asthma, inflammations, abdominal discomfort, acidity, indigestion, ulcers, swelling.<sup>[2,5]</sup> Ethno-medicinal studies have validated its uses as anti-inflammatory, antipyretic and analgesic, anti-diarrheal, anti-diabetic, immunomodulator, antimicrobial, hepatoprotective and cardioprotective agent.<sup>[5,6]</sup> The fruit is reported to contain many bioactive compounds such as carotenoids, phenolics, alkaloids, coumarins, flavonoids and terpenoids. It also contain many vitamins and minerals including vitamin C, vitamin A, thiamine, riboflavin, niacin, calcium and phosphorus with proven antioxidant activity.<sup>[2,7]</sup>

The present work is in continuation of our earlier work on AME where we have shown its curative effects against

Access this article online

Website:

www.phcog.com

DOI:

10.4103/0973-1296.127366

Quick Response Code:



### Address for correspondence:

Prof. Raj K. Goel, Department of Pharmacology, Institute of Medical Sciences, Banaras Hindu University, Varanasi - 221 005, Uttar Pradesh, India. E-mail: rkgoelbhu50@gmail.com

acetic-acid (AA)-induced colitis in rats. The colitis produced by AA mainly is due to the direct necrotizing effect of AA leading to chronic inflammatory changes with a subsequent decrease in antioxidants and increase in free radicals and myeloperoxidase (MPO).<sup>[2]</sup> The present study evaluates the curative effects of 50% ethanol extract of dried fruit pulp of AM (AME) on 2,4,6-trinitrobenzene sulfonic acid (TNBS)-induced colitis, an immunological model of experimental colitis in rats to confirm further our earlier reported curative effect of AME against AA-induced colitis in rats.

## MATERIALS AND METHODS

### Animals

Charles-Foster albino rats (180-210 g) of either sex were obtained from the Central animal house of Institute of Medical Sciences, Banaras Hindu University, Varanasi. They were kept in the departmental animal house at 26°C ± 2°C, 44-56% RH and 10:14 h light and dark cycle for 1 week before and during the experiments. Animals were provided with standard rodent pellet diet (Pashu Aahar, Ramnagar, Varanasi) and water was given *ad libitum*. "Principles of laboratory animal care,"<sup>[2]</sup> (NIH publication no. 82-23, revised 1985) guidelines were followed. Approval from the Institutional Animal Ethical Committee was taken prior to the experimental work (vide letter No. Dean/2009-10/568 Dated 10.08.2009).

### Collection and preparation of extract

AM fruits (Big sized, unripe) were collected during months of November–March (Ayurvedic Gardens, Banaras Hindu University). Fruit pulp was cut into small pieces and dried at room temperature and powdered. 50% ethanolic extract of AM (AME) was prepared by cold decoction and dried at 40°C in an incubator and stored at –20°C. The yield was 12.7% (w/w).

### Preliminary phytochemical screening

AME was subjected to qualitative tests for the identification of carbohydrate, glycoside, alkaloid, protein and amino acids, phenolic compounds, alkaloids, flavonoids, fixed oil and fats, tannins, saponins, gum and mucilage, phytosterols following the standard methods.<sup>[8]</sup>

### Chemicals

Sulfasalazine (SAZO, 1000 mg tablet, Wallace, Mumbai, India; SS) and 2,4,6-TNBS (Sigma-Aldrich St. Louis, MO; USA) and other chemicals and reagents were used of analytical grade. Muller-Hinton agar and broth (Hi-media, Mumbai, India) was used for antibacterial activity.

### Induction of colitis and treatment protocol

Colitis was induced by intra-colonic administration of TNBS (Sigma-Aldrich St. Louis, MO; USA) to 24 h fasted rat.<sup>[9]</sup> Rats were either given intra-colonic normal saline (NS, 0.4 ml/rat, negative control) or TNBS alone (40 mg/0.4 ml of 40% ethanol/rat, control) or TNBS plus oral AME (test extract)/standard colitis protective drug, SS (100 mg/kg, SS, positive control drug).<sup>[10]</sup> Oral drugs were suspended in 0.5% carboxymethyl cellulose (CMC) in distilled water. CMC/AME /SS was given orally once daily in the volume of 1 ml/100 g body weight for a period of 14 days after the induction of colitis with TNBS.

### Pathology and histopathology

The animals were sacrificed on 15<sup>th</sup> day of the experiment with an overdose of ether. Pathological changes (macroscopic) were seen by examination of 8 cm distal part of rat colon following 0-10 scale scoring system.<sup>[2,10]</sup> Colon was examined for severity and number of ulcers in terms of tissue damage score, thickening and adhesions. A piece of the colon was removed and fixed in 10% buffered formalin and paraffin embedded and 4-6 µm thick sections. The tissue sections were stained with H and E stain for histological evaluation and examined under a microscope.

### Diarrhea and body weight

Diarrhea and body weight changes were studied at day 7 and 14 of the experiment.

### Antioxidants, free radicals and acute inflammatory marker

Antioxidants - superoxide dismutase, (SOD); catalase (CAT); and reduced glutathione (GSH),<sup>[11-13]</sup> free radicals - lipid peroxidation (LPO),<sup>[14]</sup> and nitric oxide (NO)<sup>[15]</sup> and acute inflammatory marker, MPO<sup>[16]</sup> and protein,<sup>[17]</sup> were estimated in mucosal homogenates of rat colon. SOD, CAT and MPO were expressed as mU/mg protein while GSH, LPO, NO were expressed as nmol/mg protein.

### Antimicrobial activity

Antibacterial susceptibility of AME was done against intestinal Gram-negative pathogens, *Escherichia coli* ATCC 25922, *Shigella boydii*, *Shigella sonnei*, and *Shigella flexneri* following the disk diffusion method<sup>[18]</sup> while minimum inhibitory concentration (MIC) was performed by micro dilution method.<sup>[19]</sup>

### Statistical analysis

The statistical analysis was performed by using unpaired *t*-test and one-way analysis of variance and for multiple comparisons followed by Dunnett's test.

## RESULTS

### Preliminary phytochemical screening

AME indicated the presence of many bioactive compounds viz. carbohydrate, glycoside, alkaloid, protein, amino acids, phenolic compounds, alkaloids, flavonoids, fixed oil and fats, tannins, saponins, gum and mucilage.

### Colonic mucosal damage, adhesion and weight

Rats treated with intracolonic NS and oral CMC did not show any colonic mucosal damage, inflammation or adhesion and the colonic weight was  $158.3 \pm 6.4$  mg/cm. Intracolonic TNBS plus oral CMC treated rats showed increased colonic mucosal damage score ( $5.17 \pm 0.31$ ,  $P < 0.001$ ), adhesions (5/6 rats, 83.3%) and weight to  $248.8 \pm 6.7$  mg/cm (57.2% increase,  $P < 0.001$ ) compared with NS group. Rats treated with oral AME (100, 200, and 400 mg/kg) dose-dependently showed a reduction in TNBS-induced colonic mucosal damage score (TNBS control -  $5.17 \pm 0.31$ ) by 19.9, 67.7 and 72.3% and colonic weight (TNBS control -  $248.8 \pm 6.67$  mg/cm) by 13.2, 29.1 and 32.1% respectively ( $P < 0.1$  to  $P < 0.001$ ). SS-treated rats showed a decrease in colonic damage score, colonic weight and adhesions by 77.4% ( $P < 0.001$ ), 33.5% ( $P < 0.001$ ) and 80.0% (1/6 rat) respectively compared with TNBS group. Therefore, an optimal effective dose of 200 mg/kg of AME was selected for further detailed work.

### Macroscopic and microscopic studies

NS rats showed normal colonic structures while, hydropsia, necrosis, erosion and ulceration were seen in TNBS rats. AME and SS treatments in TNBS-induced colitis rats showed a reduction in the severity of hydropsia, necrosis and ulceration compared with TNBS alone [Figure 1a-d]. Histology of colon of NS rats showed normal structure with intact mucosa, submucosa and muscularis externa. TNBS colitis rats showed eroded mucosa, crypt destruction with severe cryptitis, lymphoplasmacytic infiltrate and transmural inflammation while, TNBS-induced colitis rats treated with AME or SS showed improvement in the structures with near intact lamina propria with

mild lymphoplasmacytic infiltrate and submucosa with mild lymphomononuclear aggregate [Figure 2a-d].

### Effect on diarrhea

TNBS rats showed an increase in fecal output (control output -  $2.33 \pm 0.13$  g/100 g body weight) from the beginning of experiment (day 0) to 49.4% and 57.5% ( $P < 0.01$ ) at day 7 and 14 respectively. AME rats showed an increase in fecal output by 27.8% ( $P < 0.05$ ) and 16.9% ( $P < 0.001$ ) from day 0 indicating a decrease in fecal output by 21.6% and 40.6% compared with TNBS group at day 7 and 14 respectively. SS treated rats showed an increase in fecal output by 37.4% and 15.8% ( $P < 0.001$ ) from day 0 indicating a decrease in fecal output by 12.0% and 41.7% compared with TNBS group at day 7 and 14 respectively.

### Effect on body weight, food, and water intake

TNBS-treated rats showed a decrease in body weight from  $199.4 \pm 2.19$  g at day 0 to  $182.8 \pm 3.77$  (8.3% decrease) ( $P < 0.01$ ) and  $171.1 \pm 2.71$  (14.2% decrease) ( $P < 0.001$ ) at 7<sup>th</sup> and 14<sup>th</sup> day respectively. AME-treated rats showed an increase in body weight by 8.9% and 12.5% ( $P < 0.01$ ) while, SS treated rats showed an increase in body weight by 10.6% and 16.4% ( $P < 0.001$ ) at 7<sup>th</sup> day and 14<sup>th</sup> day respectively from day 0 weight. Mild or no change was found in the food and water intake at 7<sup>th</sup> or 14<sup>th</sup> day of study amongst the groups.

### Effect on antioxidants, free radicals and acute inflammatory marker

Intracolonic TNBS-treated rats showed a decrease in colonic mucosal antioxidants, SOD, CAT and GSH and increase in free radicals, LPO and NO and MPO levels significantly compared to intracolonic NS rats. AME and SS treatments after TNBS-induction of colitis reversed them near to NS group [Table 1].

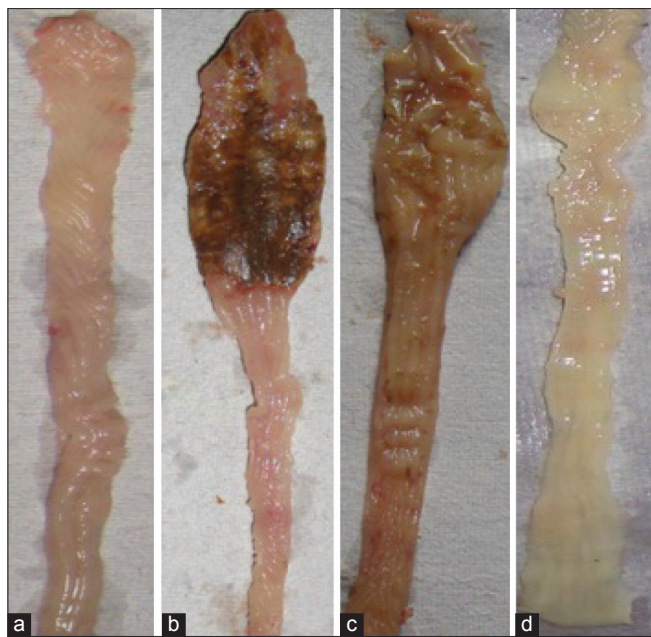
### Antimicrobial susceptibility and MIC

AME (200 mg/ml) showed zone of inhibition  $\geq 10.1$  mm while the MIC value ranged from 12.5 to 25.0 mg/ml

**Table 1: Effect of 50% ethanol extract of AM fruit pulp and SS on TNBS-induced free radicals, antioxidants and MPO contents in rat colonic mucosa**

Oral treatment (mg/kg, od × 14 days)	Anti-oxidants			Free radicals		MPO
	SOD (mU/mg protein)	CAT (mU/mg protein)	GSH (nmol/mg protein)	LPO (nmol/mg protein)	NO (nmol/mg protein)	MPO mU/mg protein
NS+1% CMC	185.4±22.1	3.38±0.21	9.71±0.71	3.81±0.22	4.77±0.25	6.83±0.37
TNBS+1% CMC	43.8±7.09*	1.28±0.06*	5.42±0.37*	10.5±0.62*	10.1±1.25*	60.9±1.42*
TNBS+AME 200	226.7±26.7 <sup>c</sup>	3.21±0.14 <sup>c</sup>	9.17±0.65 <sup>c</sup>	5.71±0.51 <sup>c</sup>	5.76±0.22 <sup>b</sup>	15.6±1.84 <sup>c</sup>
TNBS+SS 100	234.5±17.2 <sup>c</sup>	3.19±0.22 <sup>c</sup>	8.03±0.41 <sup>c</sup>	4.78±0.64 <sup>c</sup>	5.57±0.39 <sup>c</sup>	17.0±2.19 <sup>c</sup>

Results are mean±SEM (n=6). \* $P < 0.001$  compared to respective NS group (unpaired *t*-test) and <sup>b</sup> $P < 0.01$ , <sup>c</sup> $P < 0.001$  compared to respective TNBS group (one way ANOVA followed by Dunnett's test). NS: Normal saline; CMC: Carboxymethyl cellulose; LPO: Lipid peroxidation; NO: Nitric oxide; SOD: Superoxide dismutase; CAT: Catalase; GSH: Glutathione; MPO: Myeloperoxidase; AM: Aegle marmelos; SS: Sulfasalazine; TNBS: 2,4,6-trinitrobenzene sulfonic acid

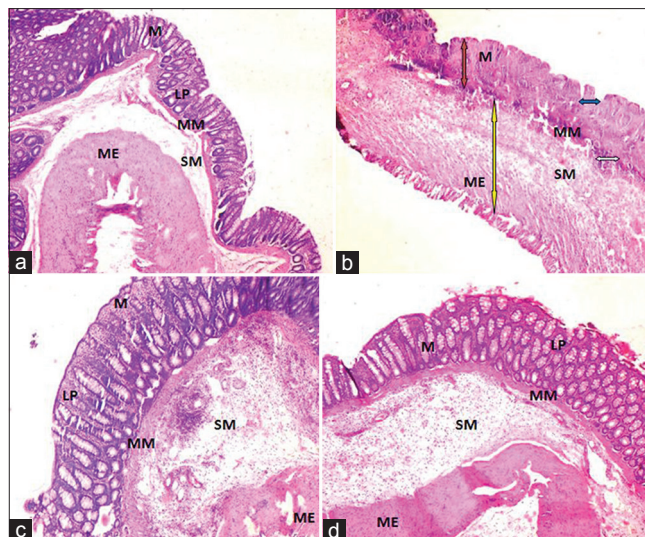


**Figure 1:** Macroscopic study of rat colonic mucosa. (a) Macroscopic changes seen in normal saline enema treated colon with oral carboxymethyl cellulose (CMC) showing normal morphology and (b-d) macroscopic changes seen in the colon of 2,4,6-trinitrobenzene sulfonic acid-induced colitis (b) treated with oral CMC showing necrosis, erosion, hydropsia and ulceration and (c) and (d) treated with AME and SS respectively showing a reduction in ulceration, hydropsia, erosion and necrosis

against intestinal bacteria, *E. coli*, *S. sonnie*, *S. boydii*, and *S. Flexneri*.

## DISCUSSION

Presently, we have now tried to justify the curative effect of AME in colitis using another immunological model of colitis induced by TNBS.<sup>[20]</sup> TNBS has been reported to induce chronic inflammation of long duration with changes in inflammatory mediators such as eicosanoids (prostaglandins, leukotrienes and platelet-activating factor), acute inflammatory marker, MPO and interleukins.<sup>[21]</sup> TNBS-induced immunological inflammatory changes led to hydropsia, necrosis, erosion and ulceration in colonic tissue as indicated by an increase in colonic mucosal damage score, adhesions and colonic weight. Histology of the colon indicated epithelial necrosis and inflammatory cell infiltration. Rats showed an increase in diarrhea after induction of colitis with TNBS. This could be due to alterations in epithelial function produced by products released from activated mast cells due to damaging effects of TNBS.<sup>[21]</sup> We also found a decrease in body weight without any alteration in the food and water intake, which could be due to changes in the gastrointestinal absorptive functions treatment with AME reduced the damage both macroscopic and microscopic induced by TNBS. This was followed by an increase in body



**Figure 2:** Photomicrographs of the rat colon (H and E,  $\times 100$ ) (a) normal saline + carboxymethyl cellulose (CMC) showing relatively normal and clear structure with intact mucosa and sub mucosa (b) 2,4,6-trinitrobenzene sulfonic acid (TNBS) + CMC showing crypt destruction with severe cryptitis (blue arrow), ulceration with eroded mucosa (brown arrow), lymphoplasmacytic infiltrate (white arrow) and transmural inflammation (Yellow arrow) (c) TNBS + AME showing regenerative mucosa with mild crypt distortion and mild lymphoplasmacytic infiltrate in the lamina propria with edematous submucosa and (d) TNBS + SS showing intact mucosa with minimal lymphoplasmacytic infiltrate in the lamina propria (M = Mucosa; SM = Submucosa; LP = Lamina propria; MM = Muscularis mucosa; ME = Muscularis externa)

weight, decrease in diarrhea, fewer incidences of adhesions and decreased lymphoplasmacytic infiltration.

TNBS-ethanol starts acute inflammation with the breaking of mucosal barrier by ethanol and allowing TNBS to cause more inflammation and other immunological reactions leading to generation of ROS, MPO, eicosanoids mediators and cytokines by inflammatory and colonic epithelial cells.<sup>[22]</sup> Experimental and clinical evidences suggest that the inflamed colon undergoes substantial oxidative stress by neutrophils derived oxidants and MPO activity, both of which contribute markedly to tissue damage during chronic intestinal inflammation.<sup>[23]</sup> Our present study showed a significant increase in MPO activity in the TNBS group, which offers a quantitative measure of disease severity and a method of assessing drug efficacy in animal models of intestinal inflammation.<sup>[24]</sup> Animal models of colitis, such as rodents exposed to TNBS exhibit increased oxidation and LPO during initiation of colitis.<sup>[25]</sup> Oxidative stress and its consequent LPO could aggravate free radicals chain reactions, disrupt the integrity of the intestinal mucosa barrier, and activate inflammatory mediators.<sup>[26]</sup> Increase in ROS production and impaired antioxidant defense mechanisms are postulated to be causative factors in inflammatory diseases. Colitis has been found to be associated with an overproduction of NO by the inducible isoform of NO synthase.<sup>[27]</sup> Therefore, decreasing

of ROS could be an important aim in treatment of colitis where antioxidants have been postulated to hasten the process of healing by destroying the free radicals.<sup>[28]</sup> Our work on free radicals and MPO and antioxidants showed that AME possessed significant antioxidant activity reducing free radicals stress and decrease in colonic MPO, which would help to prevent oxidative damage and promote the healing process.

AM fruit pulp extract showed the presence of important bioactive compounds such as carotenoids, phenolics, alkaloids, pectin, tannins, coumarins, flavonoids and terpenoids. Flavonoids are most commonly known for their antioxidant activity and reduce LPO not only by preventing or slowing the onset of cell necrosis, but also by improving vascularity. Phenolic compounds are commonly known for their antioxidant, anti-inflammatory and antimicrobial activities,<sup>[29-31]</sup> while, tannins have been reported to possess antioxidant, wound healing and antimicrobial activities.<sup>[32]</sup> Phytochemical study of AME indicated the presence of phenolic compounds, flavonoids, tannins, saponins and phytosterols, etc., which have got important pharmacological effects. Recent research has also shown that, through overlapping or complementary effects, the complex mixture of phytochemical in fruits and vegetables provides a better protective effect on health than single phytochemical.<sup>[33]</sup> The protective effects of AME may therefore, be attributed to the complex mixture of phytochemical present in AME, which have been reported to have anti-inflammatory, immunomodulatory and antimicrobial properties.<sup>[5,34,35]</sup>

Role of intestinal pathogenic microbes in colitis has been well-established and it has been shown that the number of intestinal bacteria in colitis is higher than normal and increases progressively with disease severity.<sup>[36]</sup> The activity exhibited by AME at 200 mg/ml concentration was  $\geq 10.1$  mm, which have been considered as effective antimicrobial dose<sup>[17]</sup> and this could be due to the presence of tannins and phenolic compounds in the extract, which have been reported to have antimicrobial effect.<sup>[31]</sup> However, The complex enteric immune system plays an important role in interactions between microbial antigens and immune-competent cells and this is possible that AME by virtue of its having many active bioconstituents could enhance the enteric immune system to the advantage of curing TNBS-induced colitis.

## CONCLUSION

Thus, the results of the present study with extract of fruit pulp of AME do indicate promising healing effects in TNBS-induced colitis by promoting antioxidants having a protective effect against tissue damage induced by free

radicals and MPO and it could be attributed to various active principles present in it.

## ACKNOWLEDGMENTS

This work was supported by Central Council for research in Ayurveda and Siddha (CCRAS), Department of AYUSH, Ministry of Health and Family Welfare, Government of India, New Delhi (BHU Research project no.: P-15-30).

## REFERENCES

- Hanauer SB. Inflammatory bowel disease: Epidemiology, pathogenesis, and therapeutic opportunities. *Inflamm Bowel Dis* 2006;12 Suppl 1:S3-9.
- Gautam MK, Ghatule RR, Singh A, Purohit V, Gangwar M, Kumar M, et al. Healing effects of *Aegle marmelos* (L.) correa fruit extract on experimental colitis. *Indian J Exp Biol* 2013;51:157-64.
- Ghatule RR, Goel S, Gautam MK, Singh A, Joshi VK, Goel RK. Effect of *Azadirachta indica* leaves extract on AA-induced colitis in rats: Role of antioxidants, free radicals and myeloperoxidase. *Asian Pac J Trop Dis* 2012;2:S651-7.
- Millar AD, Rampton DS, Chander CL, Claxson AW, Blades S, Coumbe A, et al. Evaluating the antioxidant potential of new treatments for inflammatory bowel disease using a rat model of colitis. *Gut* 1996;39:407-15.
- Baliga MS, Bhat HP, Joseph N, Fazal F. Phytochemistry and medicinal uses of the bael fruit (*Aegle marmelos* Correa): A concise review. *Food Res Int* 2011;44:1768-75.
- Govinda HV, Asdaq SM. Immunomodulatory potential of methanol extract of *Aegle marmelos* in animals. *Indian J Pharm Sci* 2011;73:235-40.
- Das B, Das RD. Medicinal properties and chemical constituents of *Aegle marmelos* Correa. *Indian Drug* 1995;32:93-9.
- Kokate CK. *Practical Pharmacognosy*. New Delhi, India: Vallabh Prakashan; 2010. p. 17-26.
- Morris GP, Beck PL, Herridge MS, Depew WT, Szewczuk MR, Wallace JL. Hapten-induced model of chronic inflammation and ulceration in the rat colon. *Gastroenterology* 1989;96:795-803.
- Gautam MK, Goel S, Ghatule RR, Singh A, Nath G, Goel RK. Curative effect of *Terminalia chebula* extract on acetic acid-induced experimental colitis: Role of antioxidants, free radicals and acute inflammatory marker. *Inflammopharmacology* 2012; E-publication ahead of print. Available from: <http://www.springerlink.com/doi/10.1007/s10787-012-0147-3>. [Last accessed on 2012 Sep 07].
- Kakkar P, Das B, Viswanathan PN. A modified spectrophotometric assay of superoxide dismutase. *Indian J Biochem Biophys* 1984;21:130-2.
- Aebi HU. Catalase. In: *Methods in Enzymatic Analysis*. New York: Academic Press; 1983. p. 276-86.
- Sedlak J, Lindsay RH. Estimation of total, protein-bound, and nonprotein sulfhydryl groups in tissue with Ellman's reagent. *Anal Biochem* 1968;25:192-205.
- Ohkawa H, Ohishi N, Yagi K. Assay for lipid peroxides in animal tissues by thiobarbituric acid reaction. *Anal Biochem* 1979;95:351-8.
- Miranda KM, Epsley MG, Wink DA. A rapid, simple spectrophotometric method for simultaneous detection of nitrate and nitrite. *Biol Chem* 2001;5:62-71.
- Bradley PP, Priebat DA, Christensen RD, Rothstein G.

- Measurement of cutaneous inflammation: Estimation of neutrophil content with an enzyme marker. *J Invest Dermatol* 1982;78:206-9.
17. Lowry OH, Rosebrough NJ, Farr AL, Randall RJ. Protein measurement with the Folin phenol reagent. *J Biol Chem* 1951;193:265-75.
  18. Gautam MK, Gangwar M, Nath G, Rao CV, Goel RK. *In-vitro* antibacterial activity on human pathogens and total phenolic, flavonoid contents of *Murraya paniculata* (L.) leaves. *Asian Pac J Trop Biomed* 2012;2:S1660-3.
  19. Wiegand I, Hilpert K, Hancock RE. Agar and broth dilution methods to determine the minimal inhibitory concentration (MIC) of antimicrobial substances. *Nat Protoc* 2008;3:163-75.
  20. Chamulitrat W. Desulfonation of a colitis inducer 2,4,6-trinitrobenzene sulfonic acid produces sulfite radical. *Biochim Biophys Acta* 1999;1472:368-75.
  21. Stein J, Ries J, Barrett KE. Disruption of intestinal barrier function associated with experimental colitis: Possible role of mast cells. *Am J Physiol* 1998;274:G203-9.
  22. Zea-Iriarte WL, Makiyama K, Goto S, Murase K, Urata Y, Sekine I, *et al.* Impairment of antioxidants in colonic epithelial cells isolated from trinitrobenzene sulphonic acid-induced colitis rats. Protective effect of rebamipide. *Scand J Gastroenterol* 1996;31:985-92.
  23. Harris ML, Schiller HJ, Reilly PM, Donowitz M, Grisham MB, Bulkley GB. Free radicals and other reactive oxygen metabolites in inflammatory bowel disease: Cause, consequence or epiphenomenon? *Pharmacol Ther* 1992;53:375-408.
  24. Krawisz JE, Sharon P, Stenson WF. Quantitative assay for acute intestinal inflammation based on myeloperoxidase activity. Assessment of inflammation in rat and hamster models. *Gastroenterology* 1984;87:1344-50.
  25. Girgin F, Karaoglu O, Erkuş M, Tüzün S, Ozütemiz O, Dinçer C, *et al.* Effects of trimetazidine on oxidant/antioxidant status in trinitrobenzenesulfonic acid-induced chronic colitis. *J Toxicol Environ Health A* 2000;59:641-52.
  26. Kaplan M, Mutlu EA, Benson M, Fields JZ, Banan A, Keshavarzian A. Use of herbal preparations in the treatment of oxidant-mediated inflammatory disorders. *Complement Ther Med* 2007;15:207-16.
  27. Martín MC, Martínez A, Mendoza JL, Taxonera C, Díaz-Rubio M, Fernández-Arquero M, *et al.* Influence of the inducible nitric oxide synthase gene (NOS2A) on inflammatory bowel disease susceptibility. *Immunogenetics* 2007;59:833-7.
  28. Halliwell B. Albumin – An important extracellular antioxidant? *Biochem Pharmacol* 1988;37:569-71.
  29. Evans RC, Miller N, Paganga G. Antioxidant properties of phenolic compounds. *Trends Plant Sci* 1997;2:152-9.
  30. Kazłowska K, Hsu T, Hou CC, Yang WC, Tsai GJ. Anti-inflammatory properties of phenolic compounds and crude extract from *Porphyrta dentata*. *J Ethnopharmacol* 2010;128:123-30.
  31. Puupponen-Pimiä R, Nohynek L, Meier C, Kähkönen M, Heinonen M, Hopia A, *et al.* Antimicrobial properties of phenolic compounds from berries. *J Appl Microbiol* 2001;90:494-507.
  32. Riedl KM, Carando S, Alessio HM, McCarthy M, Hagerman AE. Antioxidant activity of tannins and tannin-protein complexes: Assessment *in vitro* and *in vivo*. *Free Radic Food* 2002;14:188-200.
  33. Eberhardt MV, Lee CY, Liu RH. Antioxidant activity of fresh apples. *Nature* 2000;405:903-4.
  34. Arul V, Miyazaki S, Dhananjayan R. Studies on the anti-inflammatory, antipyretic and analgesic properties of the leaves of *Aegle marmelos* Corr. *J Ethnopharmacol* 2005;96:159-63.
  35. Patel P, Asdaq SM. Immunomodulatory activity of methanolic fruit extract of *Aegle marmelos* in experimental animals. *Saudi Pharm J* 2010;18:161-5.
  36. Swidsinski A, Ladhoff A, Perntaler A, Swidsinski S, Loening-Baucke V, Ortner M, *et al.* Mucosal flora in inflammatory bowel disease. *Gastroenterology* 2002;122:44-5.

**Cite this article as:** Ghatule RR, Gautam MK, Goel S, Singh A, Joshi VK, Goel RK. Protective effects of *Aegle marmelos* fruit pulp on 2,4,6-trinitrobenzene sulfonic acid-induced experimental colitis. *Phcog Mag* 2014;10:S147-52.

**Source of Support:** This work was supported by Central Council for research in Ayurveda and Siddha (CCRAS), Department of AYUSH, Ministry of Health & Family Welfare, Government of India, New Delhi (BHU Research project no.: P-15-30, **Conflict of Interest:** None declared.