

# Mandibular metastasis from a pulmonary squamous cell carcinoma

Access this article online

Website:  
www.amsjournal.com

DOI:  
10.4103/2231-0746.133086

Quick Response Code:



Vikas Dhupar, Francis Akkara, Rahul D. Kamat, Omkar Shetye  
Department of Oral and Maxillofacial Surgery, Goa Dental College and Hospital,  
Bambolim, Goa, India

Address for correspondence:

Dr. Rahul D. Kamat, Department of Oral and Maxillofacial Surgery,  
Goa Dental College and Hospital, Bambolim - 403 202, Goa, India.  
E-mail: rahul567dk@gmail.com

## ABSTRACT

Metastatic tumors to the jaws and oral tissues are rarely encountered, accounting for less than 1% of all malignant tumors affecting the mouth. Although, metastasis to the mandible from a pulmonary carcinoma is extremely rare, when it does occur it mimics more common pathoses such as odontogenic cysts, osteomyelitis, space infections making its diagnosis even more challenging. Metastasis should be taken into account especially in patients with chronic history of smoking and sudden onset of paresthesia. The rarity of such cases has also resulted in there being no definitive consensus on managing them.

**Keywords:** Metastasis, odontogenic infection, pulmonary carcinoma

## INTRODUCTION

Bronchogenic carcinoma represents one of the most lethal malignancies world-wide. It usually arises from dysplasia of squamous epithelium of the bronchi and is strongly associated with cigarette smoking. Lung cancer continues to be one of the leading causes of mortality in the Middle East, Africa and the Asian subcontinent due to high incidence of cigarette smoking seen in these parts of the world.<sup>[1]</sup>

Squamous cell carcinomas accounts for approximately 30% of all non-small cell carcinoma of the lungs.<sup>[2]</sup> Approximately 9-30% of patients with lung cancer develop bone metastases, leading to significant morbidity and mortality. The estimated incidence of metastasis from primary elsewhere to oral and maxillofacial region ranges from 1% to 3% respectively.<sup>[3]</sup>

Lung carcinomas are characterized by their insidious onset, difficulty in detection, early metastatic spread and poor prognosis at the time of presentation.

The present case describes a metastatic lung carcinoma that had invaded the mandible and surrounding soft-tissue, which was

being treated as a case of odontogenic space infection before being referred to our institute due to non-resolving nature of the swelling.

## CASE REPORT

The present case report is about a 51-year-old female patient reported to our department with complaints of non-resolving swelling over right side of the face and a dull, continuous, aching pain in the mandibular right posterior region radiating to the right ear.

She gave a history of loss of appetite, weight loss and persistent non-productive cough over a period of past 6-8 weeks. Her mouth opening had progressively worsened over the past 2-3 months affecting her nutritional status.

She was a chronic smoker since past 30 years with a 5 bidis/day history of tobacco use. Her past medical history was not significant.

The patient gave no history of trauma. The patient had been seeking treatment from a general practitioner who had carried out

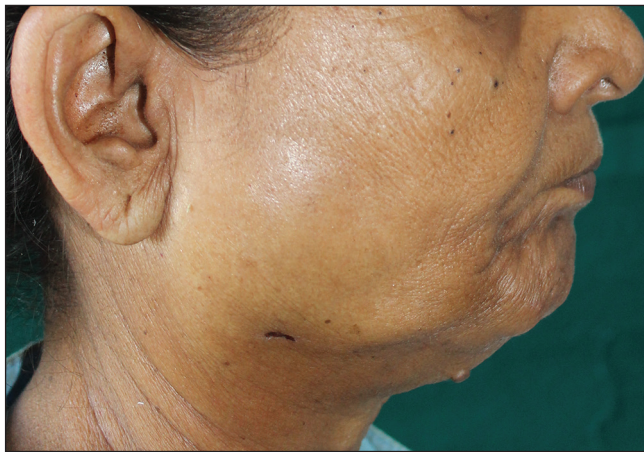
incision and drainage suspecting the swelling to be a massetric space infection and had planned for extraction of her posterior teeth at a later date on improvement of mouth opening. The patient also gave a history of altered sensation on the right side of her lower lip.

General examination revealed Grade III clubbing with a characteristic parrot beak appearance of her nails.

On local examination, there was gross facial asymmetry with a single diffuse swelling over right preauricular region extending up to the lower border of the mandible. The skin overlying the swelling had a taut and shiny appearance [Figure 1].

On palpation, the swelling was firm, non-tender and fluctuant. There was no lymphadenopathy.

Intra oral examination revealed poor oral hygiene and carious teeth present in all four quadrants.



**Figure 1:** Diffuse swelling over right masseteric region with loss of overlying skin creases, scar of incision along lower border of mandible suggestive of incision and drainage done 6 days back

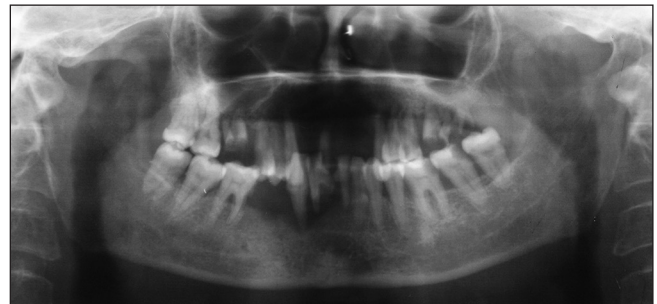The only relevant finding on routine blood examination was an elevated erythrocyte sedimentation rate of 40 mm.

The orthopantomogram revealed multiple carious teeth suspected to be the possible cause of infection [Figure 2]. The clinical differential diagnosis at this stage included massetric space infection, salivary gland tumor, primary carcinoma of oral cavity, chronic non-suppurative osteomyelitis.

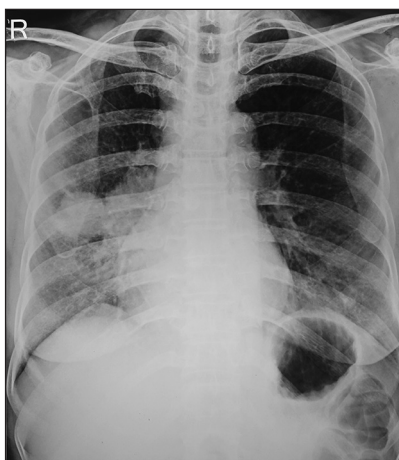The non-resolving nature of the swelling even after extraction of foci of infection and the patient's history made us investigate the general status of the patient. Following which chest X-ray and contrast enhanced computed tomography (CECT) of thorax was advised.

The chest X-ray (posteroanterior view) revealed a nodular opacity in right M2, L2 measuring approximately 6 cm × 4 cm with right hilar prominence strongly suggestive of bronchogenic carcinoma [Figure 3].

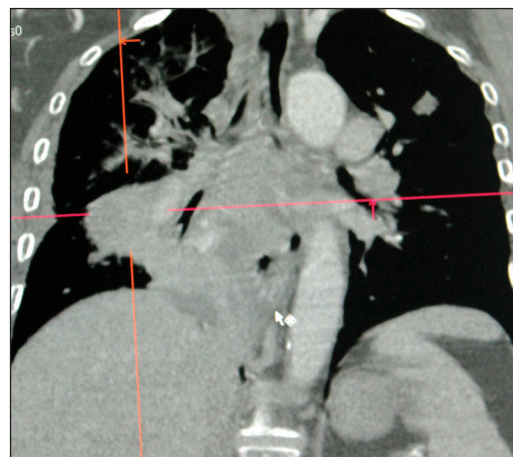
Diagnosis of pulmonary carcinoma was considered when CECT of thorax was suggestive of bronchogenic carcinoma with mediastinal lymphadenopathy and adjacent lymphangitis carcinomatosa [Figure 4].



**Figure 2:** Orthopantomogram shows the presence of ill-defined radiolucency extending from sigmoid notch up to the lower border of mandible



**Figure 3:** Chest X-ray (postero-anterior view) demonstrates nodular opacity at the level of 5<sup>th</sup> and 6<sup>th</sup> rib with hilar prominence



**Figure 4:** This image is a coronal slice of contrast enhanced computed tomography scan showing heterogenous mass in the right middle lobe with tracheal deviation and adjacent lymphangitis carcinomatosa

On further investigating, fine-needle aspiration cytology (FNAC) of the swelling over the right masseteric region showed malignant squamous cells arranged singly and in groups conclusive of metastasis from a poorly differentiated squamous cell carcinoma [Figure 5].

A FNAC was selected over conventional incisional biopsy as it had several advantages as a diagnostic modality of being quick, reliable and safe. Elimination of tissue embedding or sectioning with this technique allowed for a more rapid diagnosis than with surgical biopsy.

A computed tomographic scan of the mandible was carried out to see for the extent of bony involvement which revealed an oval shaped osteolytic lesion over the right side of the ramus of the mandible with thinning out of posterior border of the ramus measuring approximately 8 cm × 4 cm in greatest diameter [Figure 6].

The axial and coronal slices of the computed tomographic scan revealed perforation of buccal and lingual cortices of ramus of the mandible on the right side with minimal expansion of buccal and lingual cortex [Figures 7 and 8].

A definitive diagnosis of pulmonary squamous cell carcinoma was arrived at following CT guided FNAC of tumor mass in the right lung [Figure 9] which was consistent with the cytopathologic findings of the metastatic lesion.

The patient upon definitive diagnosis of pulmonary squamous cell carcinoma was started on Cisplatin based palliative chemotherapy. Although, partial regression of primary tumor was present, relapse with worsening of symptoms was observed 6 months after diagnosis was established. Unfortunately, the patient was lost to follow-up following 6 months after chemotherapy after being discharged from our unit.

## DISCUSSION

Pulmonary squamous cell carcinoma is generally a centrally located lung carcinoma that has been classified histologically by World Health Organization into four broad categories: Clear cell, small cell, papillary and basaloid. Metastasis is defined as the transfer of disease cells from one organ or part to another site not directly connected with it.<sup>[4,5]</sup>

Metastasis of lung cancer to the craniofacial region is not a common characteristic of this tumor. After variable periods of growing within the lung parenchyma, the tumor usually invades the vascular and lymphatic channels, thereby metastasizing to regional lymph nodes and distant sites. The main mechanism proposed for metastatic spread to the oral region is backflow through the venous system.<sup>[6]</sup> Whereas bone, liver, adrenal and brain constitute most frequent sites of distant metastasis, the maxillofacial skeleton is usually spared.

Meyer and Shklar reviewed 2400 oral malignancies during a 12 year period and found only 25 metastatic tumors; this figure represents 1% of oral malignancies. A review of the

pertinent literature reveals that skeletal metastases may be detected in 70-85% of patients who die of malignant disease, especially in those with breast, lung, or prostate cancer, with only 1% of these involving the jaws.<sup>[7]</sup> It has been thought that the infrequency of observed metastasis to the jaws is due to a lack of symptoms, a failure to include the mandible and maxilla in skeletal surveys and a failure to examine the jaws fully at autopsy.

A review of recent literature suggests that apart from the lungs, metastasis to the maxillofacial skeleton can also occur from distant primary tumor sites like carcinoma of the cervix.<sup>[8]</sup>

According to Clausen and Poulsen, metastases to the jaws is more common in females with posterior mandible being the most common site and mean age of presentation being 55.6 years.<sup>[9]</sup>

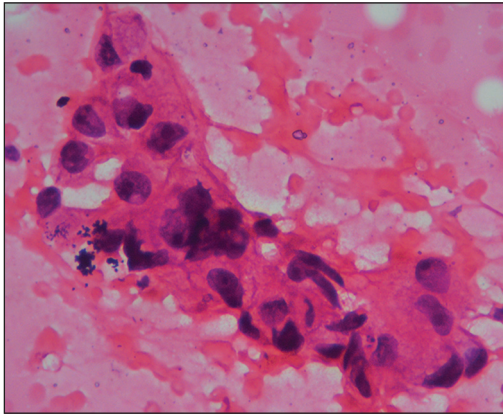
A study by Abraham *et al.*, reviewed facial pain in pulmonary carcinoma patients and found that in 31 cases the common symptom of the patients was atypical unilateral facial pain, although, there was no metastatic lesion in the mandible. The most frequent locations of pain were the ear, the jaw and the temporal region, 61% occurring on the right and 39% on the left side. In most instances, the onset of pain preceded other symptoms suggestive of malignancy by 1-48 months. The pain resolved or partially remitted in most patients following treatment of the carcinoma.<sup>[10]</sup>

Diagnostic features of metastatic bone disease may not be present in all cases. Nearly 33% of the patients present with radiographic findings. Absence of any radiographic change on plain films should not exclude a malignant change and bony involvement of tumors metastatic to the jaws. Although, whole body scintigraphy can detect widespread disease with an increased uptake of tracer in the affected area, we could not carry out this test as the patient refused this diagnostic procedure.

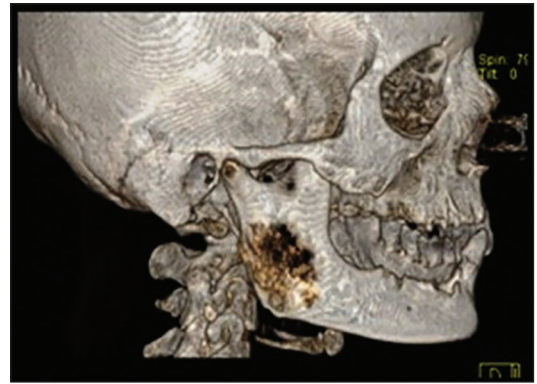
Metastatic tumors are a diagnostic dilemma as most patients present with a non-specific complaint, the lesions are centrally located in jawbones and radiographs are usually inconclusive.<sup>[10]</sup> Consequently metastatic invasions are erroneously treated as more common pathoses such as odontogenic cysts, osteomyelitis and benign tumors or as lesions of infective or traumatic origin, as was the case in our patient whose complaint was swelling on the right side of the face which was suspected and treated for 2 weeks to be an infection of odontogenic origin.

The prognosis of patients with metastasis from a primary tumor is poor with a median survival rate of less than 6 months. In our case, the patient received palliative cisplatin based chemotherapy. Although, partial regression of primary tumor was observed, the disease had relapsed with worsening of patient's symptoms 6 months after definitive diagnosis.

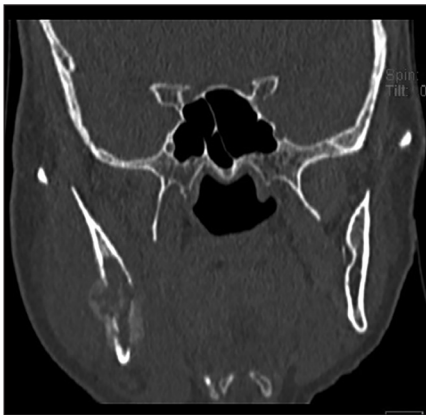Unfortunately, bronchogenic carcinoma has no obvious pathognomonic signs or symptoms. Detection of the case is usually done during an investigation of a complaint which is not related to the respiratory system.



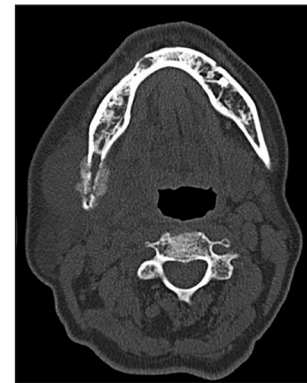**Figure 5:** Cellular aspirate of metastatic tumor showing atypical epithelial cells with altered nuclear:cytoplasmic ratio (H and E, ×100)



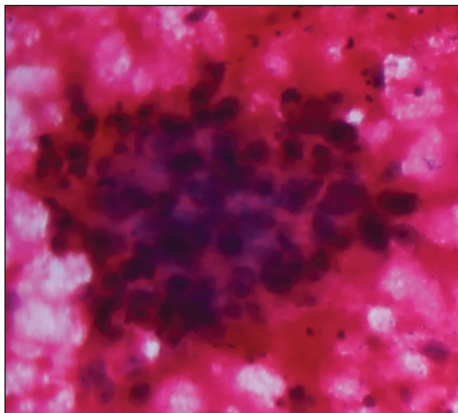
**Figure 6:** Three dimensional reconstruction demonstrating destruction of buccal cortex over the right side ramus of the mandible



**Figure 7:** Coronal slices of computer tomographic scan showing perforation of buccal and lingual cortices with inhomogeneous mass extending into surrounding soft-tissue



**Figure 8:** Axial slices of computer tomographic scan showing perforation of buccal and lingual cortices with inhomogeneous mass extending into surrounding soft-tissue



**Figure 9:** Photomicrograph of lung lesion showing pulmonary squamous cell carcinoma (H and E, ×100)

Although, it seems to be overzealous to suspect the presence of metastatic disease in every patient with jaw pain, a selected subgroup of individuals, i.e., patients with chronic history of smoking or patients who complain of sudden onset of paresthesia not responding to conventional management, should undergo specific investigations to rule out a neoplastic basis of complaint.

## REFERENCES

1. Perez-Moreno P, Brambilla E, Thomas R, Soria JC. Squamous cell carcinoma of the lung: Molecular subtypes and therapeutic opportunities. *Clin Cancer Res* 2012;18:2443-51.
2. Nonaka D. A study of  $\Delta$ Np63 expression in lung non-small cell carcinomas. *Am J Surg Pathol* 2012;36:895-9.
3. Yasar F, Oz G, Dolanmaz D, Akgünlü F. Mandibular metastasis in a patient with pulmonary adenocarcinoma. *Dentomaxillofac Radiol* 2006;35:383-5.
4. Rossi G, Marchioni A, Sartori G, Longo L, Piccini S, Cavazza A. Histotype in Non-small lung cancer therapy and staging: The emerging role of an old and underrated factor. *Curr Respir Med Rev* 2007;3:69-77.
5. Dorland WA. *Dorland's Illustrated Medical Dictionary*. 30<sup>th</sup> ed. Philadelphia, PA: Elsevier Saunders; 2003. p. 1138.
6. Marx RE, Stern D. *Oral and Maxillofacial Pathology: A Rationale for Diagnosis and Treatment*. Chicago, IL: Quintessence; 2003. p. 822-6.
7. Meyer I, Shklar G. Malignant tumors metastatic to mouth and jaws. *Oral Surg Oral Med Oral Pathol* 1965;20:350-62.
8. Ram H, Kumar M, Bhatt ML, Shadab M. Oral metastases from carcinoma of cervix. *BMJ Case Rep* 2013;13.
9. Clausen F, Poulsen H. Metastatic carcinoma of the jaws. *Acta Pathol Microbiol Scand* 1963;57:361-74.
10. Abraham PJ, Capobianco DJ, Cheshire WP. Facial pain as the presenting symptom of lung carcinoma with normal chest radiograph. *Headache* 2003;43:499-504.

**Cite this article as:** Dhupar V, Akkara F, Kamat RD, Shetye O. Mandibular metastasis from a pulmonary squamous cell carcinoma. *Ann Maxillofac Surg* 2014;4:103-6.

**Source of Support:** Nil, **Conflict of Interest:** None declared.