



Episcleritis as a possible presenting sign of the novel coronavirus disease: A case report

Wael Otaif^a, Abdulaziz Ismail Al Somali^b, Ahmed Al Habash^{c,*}

^a Department of Ophthalmology, King Khalid University, Abha, Saudi Arabia

^b Department of Ophthalmology, King Faisal University, Al Ahsa, Saudi Arabia

^c Department of Ophthalmology, College of Medicine, King Fahd Hospital of the University, Imam Abdulrahman Bin Faisal University, Dammam, Saudi Arabia

ARTICLE INFO

Keywords:
COVID-19
SARS-CoV-2
Episcleritis
Ocular
Coronavirus

ABSTRACT

Purpose: In this report, we describe a case of episcleritis that appeared to be the first sign of the novel coronavirus disease (COVID-19).

Observations: A 29-year-old man with no prior medical condition presented with a complaint of redness and foreign body sensation in his left eye, which started two days before his consultation. He had no history of decreased vision, pain, photophobia, discharge, ocular surgery, or trauma. He had no symptoms in his fellow eye nor did he have any systemic symptoms. External examination of his left eye revealed a sectoral nasal conjunctival and episcleral injection and a clear cornea. There was no scleral edema. A diagnosis of episcleritis was made based on clinical grounds and topical fluorometholone 0.1% was started. Three days later, the patient presented with headache, shortness of breath, cough, and fever (39.2 °C). Real-time fluorescence polymerase chain reaction test of his nasopharyngeal swab returned a positive result for COVID-19. The patient was then admitted for observation and supportive therapy. After five days, fever, respiratory and ocular symptoms were markedly improved and the patient was discharged and advised to isolate at home for 14 days.

Conclusions and importance: This is the first report that describes episcleritis as a possible presenting sign of COVID-19. Understanding the association between ocular signs/symptoms and COVID-19 can aid in the diagnosis of the viral infection and can help in limiting its transmission.

1. Introduction

The coronavirus disease (COVID-19) was initially reported in Wuhan City (Hubei Province, China) in December 2019, and has since spread worldwide causing a global pandemic. This disease is caused by a novel virus known as the severe acute respiratory syndrome coronavirus 2 (SARS-CoV-2).¹ SARS-CoV-2 can be transmitted via respiratory droplets that come in contact with the mucosal surface of the mouth, nose, or eyes.² Although COVID-19 primarily involves the respiratory tract, involvement of the gastrointestinal tract and ocular tissues has been reported.^{3,4}

A recent case report illustrated that SARS-CoV-2 RNA can be detected in the conjunctival swab of a confirmed COVID-19 patient; this finding indicates that viral conjunctivitis can be one of the early signs of COVID-19.⁵ Additionally, a number of reports suggested that patients who had SARS-CoV-2 infection presented with conjunctivitis as the first symptom after contact with a confirmed COVID-19 patient.^{6,7} However,

only a limited number of researches have been conducted to elaborate the impact of SARS-CoV-2 infection on the ocular tissues.⁸

To the best of our knowledge, this is the first report describing a case of episcleritis as a possible presenting sign of COVID-19.

1.1. Case report

A 29-year-old man with no prior medical condition presented with a complaint of redness and foreign body sensation in his left eye, which started two days before his consultation. He had no history of decreased vision, pain, photophobia, or discharge; he also had no prior history of similar condition, ocular surgery or trauma. He had no symptoms in his fellow eye nor did he have any systemic symptoms. External examination of his left eye revealed a sectoral nasal conjunctival and episcleral injection and a clear cornea. (Fig. 1). There was no scleral edema. A diagnosis of episcleritis was made based on phenylephrine blanching test which was performed using 10% phenylephrine hydrochloride; the

* Corresponding author.

E-mail address: ahmedalhabash@gmail.com (A. Al Habash).

<https://doi.org/10.1016/j.ajoc.2020.100917>

Received 23 June 2020; Received in revised form 8 August 2020; Accepted 2 September 2020

Available online 8 September 2020

2451-9936/© 2020 The Authors.

Published by Elsevier Inc.

This is an open access article under the CC BY-NC-ND license

(<http://creativecommons.org/licenses/by-nc-nd/4.0/>).

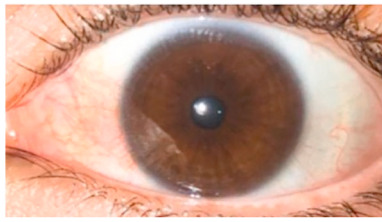


Fig. 1. External photograph of the left eye showing episcleritis with sectoral nasal injection of the conjunctiva and episclera.

results showed blanching of the engorged conjunctival and superficial episcleral vessels. Intraocular pressure was 17 mmHg in the affected eye, and the fundus examination was unremarkable. The patient was prescribed a topical preservative-free lubricant along with fluorometholone ophthalmic suspension, USP 0.1% (FML®, Allergan, Inc, Irvine, CA, USA) four times a day for one week. Three days later, the patient reported headache, shortness of breath, cough, and fever (39.2 °C). Real-time fluorescence polymerase chain reaction test of his nasopharyngeal swab returned a positive result for COVID-19. The patient was then admitted for observation and supportive therapy was initiated consisting of vitamin supplements, oral azithromycin 500mg once daily, and oral paracetamol 1g three times per day, in addition to topical fluorometholone 0.1% treatment. After five days, fever, respiratory and ocular symptoms were markedly improved and the patient was discharged and advised to isolate at home for 14 days.

2. Discussion

The present case illustrates episcleritis as a possible first manifestation of COVID-19. Based on our scientific literature review, this is the first report of episcleritis as the first presenting sign of COVID-19.

Episcleritis is a common and self-limiting inflammatory condition of the episclera. Most cases of episcleritis are idiopathic in nature; however, an association between episcleritis and systemic disease has found in less than one third of patients who have episcleritis.⁹ Episcleritis has also been described as an ocular manifestation of viral diseases like Ebola, herpes zoster, and hepatitis C.^{10–12} Recently, a published case report demonstrated episcleritis, which developed after the onset of systemic symptoms, as one of the ocular manifestations and a possible complication of COVID-19.¹³

The spread of COVID-19 is an ongoing global health pandemic. Considering its life-threatening respiratory complications, most of the published research on it mainly focused on its effects on the pulmonary system. However, extra-pulmonary COVID-19 manifestations are clinically important as they can be a potential mode of transmission and are included in the mechanisms underlying the pathogenicity of SARS-CoV-2.²

Presently, our understanding of the clinical spectrum of the ocular manifestations of COVID-19 is limited. Although it has been reported to be associated with viral conjunctivitis, other possible ocular presentations have not been widely reported yet.^{6,8} A previous case series reported that 12 out of 38 COVID-19 patients developed ocular symptoms like epiphora, chemosis, and conjunctival hyperemia; two out of these patients presented with these ocular signs as the first sign of the disease.¹⁴ Bostanci Ceran et al. investigated the ocular findings of confirmed COVID-19 cases and found that 2 out of 93 patients had episcleritis.¹⁵ In addition, Lu et al.⁷ discuss the case of Dr Guangfa Wang who, while working with COVID-19 patients complained of red eyes a few days before the onset of COVID-19 symptoms. The fact that he had been wearing an N95 mask but no eye protection gave rise to concerns that the infection may have gained entry via his ocular route. This scenario has some similarities with the present case, in which, he is a doctor and he is wearing a face mask without eye protective measures and the symptoms of COVID-19 started three days after the onset of episcleritis.

This presentation of ocular features followed by pulmonary symptoms suggests a link between the ocular and systemic manifestations, and lack of eye protection is a possible risk factor for transmission.

Understanding the association between ocular signs/diseases and COVID-19 can aid in its diagnosis and can help in limiting the transmission of the disease. Considering the limited number of studies on COVID-19 and its relationship with ocular tissues, further studies are needed to clarify this relationship and understand its pathogenesis.

Patient consent

Written consent to publish this case has not been obtained. This report does not contain any personal identifying information.

Funding

No funding or grant support.

Authorship

All authors attest that they meet the current ICMJE criteria for Authorship.

Declaration of competing interest

The following authors have no financial disclosures: WO, AS, and AH.

Acknowledgements

None.

References

- Cascella M, Rajnik M, Cuomo A, Dulebohn SC, Di Napoli R. *Features, Evaluation and Treatment Coronavirus (COVID-19)*. StatPearls Publishing; 2020. Available at <http://www.ncbi.nlm.nih.gov/pubmed/32150360>. Accessed June 17, 2020.
- Guo YR, Cao QD, Hong ZS, et al. The origin, transmission and clinical therapies on coronavirus disease 2019 (COVID-19) outbreak- an update on the status. *Mil Med Res.* 2020;7(1):1–10. <https://doi.org/10.1186/s40779-020-00240-0>.
- Yeo C, Kaushal S, Yeo D. Enteric involvement of coronaviruses: is faecal–oral transmission of SARS-CoV-2 possible? *Lancet Gastroenterol Hepatol.* 2020;5(4):335–337. [https://doi.org/10.1016/S2468-1253\(20\)30048-0](https://doi.org/10.1016/S2468-1253(20)30048-0).
- Loon SC, Teoh SCB, Oon LLE, et al. The severe acute respiratory syndrome coronavirus in tears. *Br J Ophthalmol.* 2004;88(7):861–863. <https://doi.org/10.1136/bjo.2003.035931>.
- Chen L, Liu M, Zhang Z, et al. Ocular manifestations of a hospitalised patient with confirmed 2019 novel coronavirus disease. *Br J Ophthalmol.* 2020;104(6):1–4. <https://doi.org/10.1136/bjophthalmol-2020-316304>.
- Important coronavirus updates for ophthalmologists - American Academy of Ophthalmology. Available at <https://www.aao.org/headline/alert-important-coronavirus-context>. Accessed June 18, 2020.
- Lu CW, Liu XF, Jia ZF. 2019-nCoV transmission through the ocular surface must not be ignored. *Lancet.* 2020;395(10224):e39. [https://doi.org/10.1016/S0140-6736\(20\)30313-5](https://doi.org/10.1016/S0140-6736(20)30313-5).
- Zhang X, Chen X, Chen L, et al. The evidence of SARS-CoV-2 infection on ocular surface. *Ocul Surf.* 2020;18(3):360–362. <https://doi.org/10.1016/j.jtos.2020.03.010>.
- Tappeiner C, Walscheid K, Heiligenhaus A. Diagnosis and treatment of episcleritis and scleritis. *Ophthalmologie.* 2016;113(9):797–810. <https://doi.org/10.1007/s00347-016-0344-3>.
- Hebert EH, Bah MO, Etard JF, et al. Ocular complications in survivors of the Ebola outbreak in Guinea. *Am J Ophthalmol.* 2017;175:114–121. <https://doi.org/10.1016/j.ajo.2016.12.005>.
- Yawn BP, Wollan PC, St Sauver JL, Butterfield LC. Herpes zoster eye complications: rates and trends. *Mayo Clin Proc.* 2013;88(6):562–570. <https://doi.org/10.1016/j.mayocp.2013.03.014>.
- Gill K, Ghazianian H, Manch R, Gish R. Hepatitis C virus as a systemic disease: reaching beyond the liver. *Hepatal Int.* 2016;10(3):415–423. <https://doi.org/10.1007/s12072-015-9684-3>.

13. Méndez Mangana C, Barraquer Kargacin A, Barraquer RI. Episcleritis as an ocular manifestation in a patient with COVID-19. *Acta Ophthalmol.* 2020;1–2. <https://doi.org/10.1111/aos.14484>.
14. Wu P, Duan F, Luo C, et al. Characteristics of ocular findings of patients with coronavirus disease 2019 (COVID-19) in hubei Province, China. *JAMA Ophthalmol.* 2020;138(5). <https://doi.org/10.1001/jamaophthalmol.2020.1291>.
15. Bostanci Ceran B, Ozates S. Ocular manifestations of coronavirus disease 2019. *Graefe's Arch Clin Exp Ophthalmol.* 2020. <https://doi.org/10.1007/s00417-020-04777-7>.