

Bedside Clinical Hand-held Ultrasound in an Internal Medicine Department: The "Bed Med-US" Experience of Codogno and its Clinical Utility in the Management of Diagnosis and Therapy in 1007 Patients




Authors

Francesco Giangregorio , Emilio Mosconi, Maria Grazia Debellis, Eliana Palermo, Stella Provini, Manuela Mendoza, Laura Ricevuti, Ciro Esposito

Affiliations

Internal Medicine, Codogno Hospital, Codogno, Italy

Key words

internal medicine, BED MED-US, point-of-care ultrasound, multi-site ultrasound, handheld ultrasound

received 29.05.2023

accepted after revision 22.10.2023

published online 2024

Bibliography

Ultrasound Int Open 2024; 10: a21961599

DOI 10.1055/a-2196-1599

ISSN 2199-7152

© 2024. The Author(s).

This is an open access article published by Thieme under the terms of the Creative Commons Attribution-NonDerivative-NonCommercial-License, permitting copying and reproduction so long as the original work is given appropriate credit. Contents may not be used for commercial purposes, or adapted, remixed, transformed or built upon. (<https://creativecommons.org/licenses/by-nc-nd/4.0/>)

Georg Thieme Verlag KG, Rüdigerstraße 14,
70469 Stuttgart, Germany

Correspondence

Dr. Francesco Giangregorio

Codogno Hospital

Internal Medicine

Via Marconi 1

26900 Codogno

Italy

Tel.: +39 0377565668

fjiangre@me.com

ABSTRACT

Purpose Handheld ultrasound (HH-US) answers simple clinical questions in emergencies. We performed conventional US with HH-US at the patient's bedside (BED) during a medical visit (MED) (BED MED-US). The purpose of this prospective study is to estimate BED MED-US reliability, its clinical impact in helping the clinician to formulate correct diagnoses, and its ability to save time and money.

Materials and Methods 1007 patients (519 M; age:76.42) were assessed (from March 2021 to November 2022) in one or more districts. Final diagnosis was determined with clinical and reference tests (chest RX/CT, abdominal CT, endoscopy, etc.). Sensitivity, specificity, LR+ and LR-, and corresponding AUROC were evaluated. HH-US diagnoses were classified as: confirmation (HH-US revealed the sonographic signs that confirmed the clinical diagnosis) (CO), exclusion (HH-US excluded the presence of the ultrasound signs of other pathologies, in the clinical differential diagnosis) (EX), etiological (HH-US reaches diagnosis in clinically doubtful cases) (ET), or clinically relevant incidental (HH-US diagnoses that change the patient's process completely) (INC).

Results HH-US reliability: true-pos: 752; true-neg: 242; false-pos: 7; false-neg: 6 (sens: 99.1 %, spec: 97.6 %, LR+ : 98.5; LR-: 00.15, AUROC: 0.997); clinical impact: CO-diagnosis: 21 %; EX: 25%; ET: 47 %; INC: 7 %; saved time and money: approximately 35,572 minutes of work and 9324 euros.

Conclusion BED MED-US is a reliable clinical imaging system, with an important clinical impact both in diagnosis (etiological in 47 %, incidental in 7 %) and in the management of personnel resources.

Introduction

Point-of-care ultrasonography (POCUS) is defined as the acquisition, interpretation, and immediate clinical integration of ultrasonographic imaging performed by a treating clinician at the patient's bedside rather than by a radiologist or cardiologist [1].

Low-cost handheld ultrasound (HH-US) systems that are connected to a smartphone or tablet by means of sophisticated wireless technology have become readily available to clinicians. Furthermore, applications are limited by lack of user training, difficul-

ty in maintaining ultrasound competencies, access to equipment for optimal imaging, and limitations in quality control [2].

Physical examination remains the mainstay of modern medicine [3], and the stethoscope plays a central role in this [4]. However, handheld ultrasonography has recently started playing an increasing role. Nonetheless, the stethoscope should always remain part of the physical examination and ultrasound should be used in addition, not as a replacement.

First experiences with HH-US were described in the cardiologic area: Handheld echocardiography performed by a medical internist, as an extension of the physical examination of patients with heart failure, is a valid and safe test that helps to significantly increase diagnostic performance [5]. An ultrasound-augmented cardiac physical examination can be taught in traditional medical education, and it has the potential to improve bedside diagnosis and patient care [6]. Both physical examination and clinical ultrasound deserve their place in the evaluation of patients. Finally, the addition of POCUS to standard physical examination techniques in cardiovascular medicine will result in an ultrasound-augmented cardiac physical examination that reaffirms the value of bedside diagnosis [7].

Handheld ultrasound systems used at the bedside (BED) of the patient during the medical examination (MED) make ultrasound easier (US). The purpose of this prospective study is to evaluate the reliability of BED MED-US, its clinical impact, and the saving of time and human resources (by avoiding the round trip of the patient from the ward to the ultrasound room).

Materials and Methods

1007 consecutive patients (519 males, 488 females, mean age: 76.4 +/- 14.8, range: 18–101), consecutively admitted to our internal medicine department from March 2021 to November 2022 underwent BED MED-US evaluation of one or more regions, depending on clinical presentation and clinical needs. Every patient was evaluated in one or more regions depending on the clinical need. The number of examinations and the location of the ultrasound examination(s) (abdominal, thoracic, lower or upper extremities) were determined by the clinical picture at presentation and/or patient history. Gold standard diagnosis: clinical and other reference tests depending on single specific diagnosis (clinical and laboratory tests for acute heart failure, CHEST X-ray, or CHEST CT for pneumonia, clinical, fibroscan, and laboratory tests for cirrhosis, gastroscopy or colonoscopy for gastrointestinal cancers or inflammatory diseases, spiral CT and/or RMN for hepatic, renal, pancreatic, bladder lesions; clinical and laboratory test for urinary tract infections, etc.). Second look was performed in 18 cases with a high-end machine (Esaote MyLab X9) and in 51 cases, at bedside, with MINDRAY MX9, followed by contrast-enhanced ultrasound. In all cases HH-US B-MODE ultrasound showed correct visualization and diagnosis, with results similar to those of a recent review [8]. HH-US color Doppler (where employed) appeared equally comprehensive for the study of the great vessels as recently demonstrated [9], while it was less efficient for the tissue microvasculature. The patients' clinical characteristics are described in ► **Table 1**.

Our ultrasound examination

Beside ultrasound was performed by a single skilled operator (with approximately 30 years of ultrasound experience) during the clinic visit, using a handheld system (CERBERO version 3.0, ATL Milan, Italy). This system is composed of a portable ultrasound probe, comprising a miniconvex probe (abdominal and cardiologic) and a linear probe. It uses two types of Wi-Fi and a USB connection. It works with a mobile app that is compatible with most iOS, Android, and Windows devices. Images are transmitted via internal 5 G Wi-Fi. No external networks are required.

Statistics

We evaluated true-positive diagnoses (corresponding positive US and final diagnoses), true-negative ones (corresponding negative US and final diagnoses), false-positive diagnoses (false-positive US diagnosis and final negative diagnosis), and false-negative diagnoses (false-negative US diagnosis and final positive diagnosis), and evaluated sensitivity, specificity, likelihood ratio +, and likelihood ratio based on Bayes' theorem [10]. The confidence interval is calculated using the continuity-corrected score method described by Newcombe [11]. Finally, the respective area under the curve of the receiver operating characteristic (AU-ROC) was calculated.

Ultrasound scans completed the clinical examination resulting in 4 types of diagnosis: Confirmation diagnosis (Co) (HH-US revealed sonographic signs confirming the clinical diagnosis) (► **Fig. 1**), exclusion diagnosis (Ex) (HH-US excluded the presence of ultrasound signs of other pathologies in the clinical differential diagnosis) (► **Fig. 2**), etiological diagnosis (HH-US was able to demonstrate the correct diagnosis when clinical tests were unclear) (► **Fig. 3**), and clinically relevant incidental diagnosis [12] (for short: "incidental diagnosis") (Inc) (HH-US detected benign or malignant findings that changed the patient's diagnosis and prognosis completely) (► **Fig. 4, 5**)

Finally, the time (and money) that were saved by avoiding the transport of patients to the ultrasound room were calculated. We recorded the minutes needed to transport patients from the bed in the hospital ward to the ultrasound room by running tests with a wheelchair and a stretcher from each room and calculating the round trip times in minutes. Based on the number of beds in the report, we evaluated the time required to transport an autonomous or bedridden patient from each bed. The level of autonomy of each patient was then reported. We simulated the time needed to move the patient to a wheelchair or stretcher, to transport them from the room to the ultrasound area, and to return them to their room. It should be noted here that the ultrasound area is located outside the ward about 30 meters from the entrance and that the ward consists of two wings situated at a 90-degree angle, with the longer wing being about 120 meters and the other about 35 meters.

Autonomous patients needed only one transport worker, while bedridden patients required two people to carry the stretcher. Finally, the cost of each minute saved with respect to patient transport was calculated by multiplying the number of minutes by the average cost per minute of a social health worker in Lombardy (0.27 euros per minute; this value is obtained by dividing the hourly cost average salary equal to 16.25 euros) [13]. Other aspects of "time and money savings" (avoiding other examinations, cost of other examinations, subsequent lengthening of waiting lists, inconven-

► **Table 1** demographic and diagnostic characteristics of patient.

TYPES OF DISEASES	PA-TIENTS	MEAN AGE	%
CHEST DISEASES	437	81.34	43.40%
ACUTE HEART FAILURE	251	82.25	24.93%
PNEUMONIA	132	79.95	13.11%
CHRONIC OBSTRUCTIVE PULMONARY DISEASE	23	81.96	2.28%
PULMONARY EMBOLISM	14	81.36	1.39%
ACUTE PLEURITIS	7	80.85	0.70%
PLEURAL MESOTHELIOMA	5	76.80	0.50%
LUNG CANCER	5	82.80	0.50%
ABDOMINAL DISEASES	434	71.36	43.10%
CIRRHOSIS	59	69.56	5.86%
URINARY TRACT INFECTIONS	48	75.96	4.77%
INTESTINAL SUBOCCLUSION SECONDARY TO COPROSTASIS	43	82.45	4.27%
CHOLELITHIASIS	40	75.69	3.97%
ACUTE GASTROENTERITIS	38	76.40	3.77%
ACUTE DIVERTICULITIS	29	78.79	2.88%
KIDNEY STONES	25	70.48	2.48%
GASTROINTESTINAL CANCERS	24	74.79	2.38%
INFECTIOUS ILEITIS	20	73.70	1.99%
PANCREATIC CANCERS	18	78.80	1.79%
KIDNEY CANCERS	17	73.30	1.69%
URINARY BLADDER OVERDISTENSION	13	83.31	1.29%
ACUTE PANCREATITIS	12	60.92	1.19%
INFLAMMATORY BOWEL DISEASES	11	40.54	1.09%
HEPATOCELLULAR CARCINOMA	10	63.10	0.99%
ACUTE CHOLECYSTITIS	10	85.40	0.99%
ACUTE RENAL FAILURE	9	72.90	0.89%
BOWEL OBSTRUCTION	8	80.30	0.79%
ENDOCRINOLOGIC DISEASES	54	74.32	5.36%
DIABETES MELLITUS	35	72.3	3.48%
HYPOTHYROIDISM	16	75.40	1.59%
HYPERTHYROIDISM	3	68.3	0.30%
VASCULAR DISEASES	40	72.83	3.97%
DEEP VEIN THROMBOSIS	36	73.57	3.57%
ANGINA ABDOMINIS	3	71	0.30%
LOWER LIMB ARTERIAL OCCLUSION	1	67	0.10%
NEUROLOGIC DISEASES	28	78.68	2.78%
MAJOR STROKE	14	78.43	1.39%
MINOR STROKE	9	79.00	0.89%
CEREBRAL HEMORRHAGE	3	83.4	0.30%
MENIERE'S SYNDROME	2	84.5	0.20%
SYSTEMIC DISEASES	14	78.63	1.39%
SEPSIS	10	80.3	0.99%
LYMPHOMA	3	56.33	0.30%
SYSTEMIC LUPUS ERYTHEMATOSUS	1	67.3	0.10%

ience for the patient, shortening of hospital stays, etc.) are not considered in this paper. The economic calculation relates to the simple saving of time (and money) in comparison with the execution of a conventional US examination in an ultrasound room.

Results

In total, 1103 BED MED-US examinations were performed: 1007 in acute settings; 96 for follow-up (these were excluded from analysis). 456 acute BED MED-US were performed in a single region, 429 in two regions, 122 in three regions. The diagnosis sites were as follows: 442 chest, 432 abdominal, 33 neurologic, 31 vascular, 21 endocrinologic, 19 integumentary, 19 musculoskeletal, 6 systemic diseases, 4 hematologic diseases.

We performed an ultrasound examination to solve clinical questions and, whenever possible, abdominal US was also included.

We correlated the ultrasound result with the final clinical diagnosis: 752 true positives; 242 true negatives; 7 false positives; 6 false negatives (sens: 99.1%, spec: 97.6%, LR+: 98.5; LR-: 0.015) (► **Table 2**). The corresponding receiver operating characteristic (ROC) curve of ► **Table 2** was calculated with the Excel calculator [14], with the area under the curve (AUROC) corresponding to 0.997 (confidence interval: MIN: 0.993-MAX: 1.002; SEauc: 0.0027) (► **Fig. 6**). One possible bias of this study is that the clinician who performed US has about 30 years of ultrasound experience.

The clinical impact of BED MED-US was evaluated (► **Table 3**): confirmation diagnosis was obtained in 214/1007 cases (21%) (with 45.80% being cardiologic diagnoses); exclusion diagnosis in 249/1007 cases (25%) (with 26.9% being gastroenteric diagnoses); etiological diagnosis in 475/1007 cases (47%) (with 31.58% being gastroenteric, 26.73% (127/475) cardiovascular, and 24.8% respiratory diagnoses); the incidental diagnosis was "irrelevant" in more than 50% of cases (296 gallbladder calculi (29.4%), 270 hepatic and renal cysts (26.8%)), but "clinically relevant" in 7% of cases (69/1007) (62.31% gastroenteric diagnoses) with 33 being benign relevant diagnoses (20 abdominal, 10 thoracic, 2 endocrinologic, 1 vascular) (3.2%) and 36 being cancers (30 abdominal, 6 thoracic) (3.58%).

We calculated that BED MED-US makes it possible to save approximately 34,532 minutes of work and 9324 euros (► **Table 4**).

Discussion

HH-US is a real-time examination that can be performed wherever the patient is. It can answer simple and focused medical questions regarding organ- or symptom-related issues. It is an excellent adjunct to the physical examination in emergency departments where patient screening and disposition are needed or in daily clinical practice where bedside imaging information may be required. Simple clinical questions may be answered by implementing rapidly performed and focused examination protocols [7], as already documented in the fields of emergency medicine, critical care, cardiology, anesthesiology, rheumatology, obstetrics, neonatology, gynecology, gastroenterology, and many other specialties [15]. In the last few years several medical and surgical subspecialties have adopted POCUS protocols to rule in or rule out certain conditions using an algorithmic approach. Common protocols include BLUE

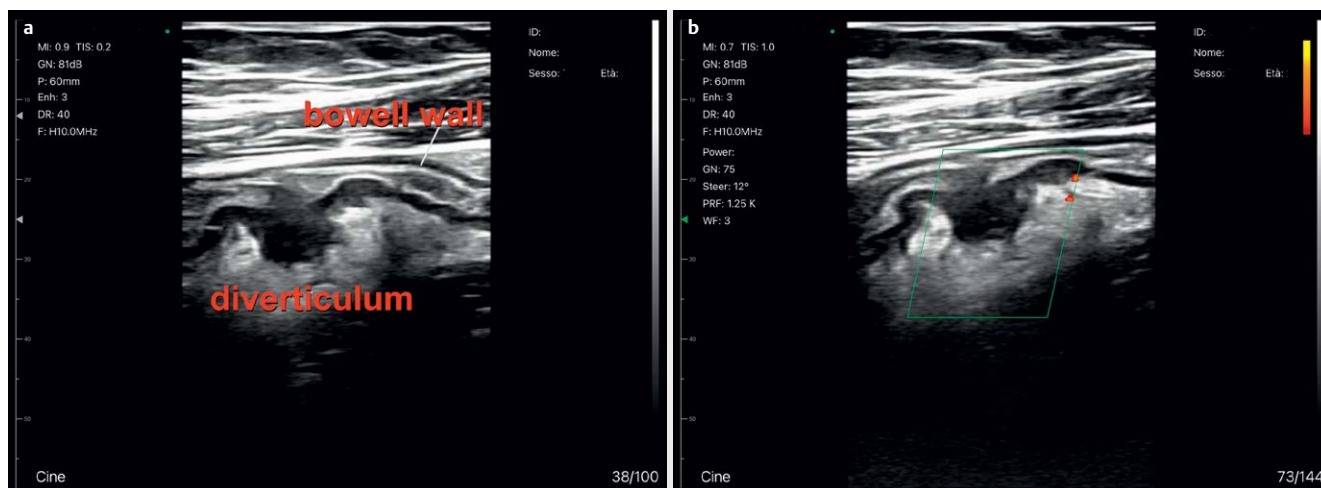


Fig. 1 A case of confirmation diagnosis: 78-year-old man is hospitalized for pain in the left iliac fossa and fever; abdominal examination shows severe pain on deep palpation in the left iliac fossa; palmar ultrasound demonstrates (a) the presence of outpouring of the sigmoid wall, with its thickening, thickening of the mesentery; on power Doppler (b) presence of flow inside the mesentery, near the diverticulum, a sign of acute inflammation.

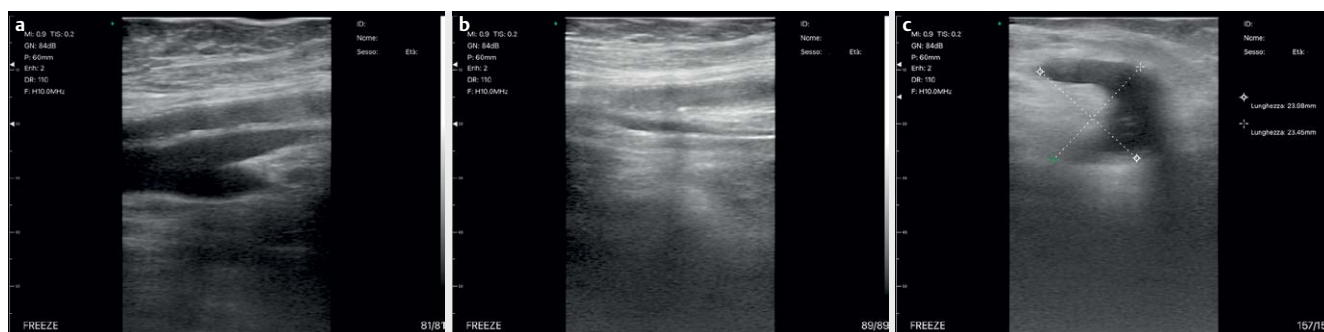


Fig. 2 A case of exclusion diagnosis: female, 83 years old, comes to the emergency room for dyspnea with a clinical picture of acute heart failure; after hospitalization in the internal medicine ward, objective finding of hard but not sore calf. Venous BED MED-US of the lower limbs is performed, which excludes (Fig. 2A: normal US and Fig. 2B: compression US) deep vein thrombosis with demonstration of Baker's cyst (Fig. 2C).

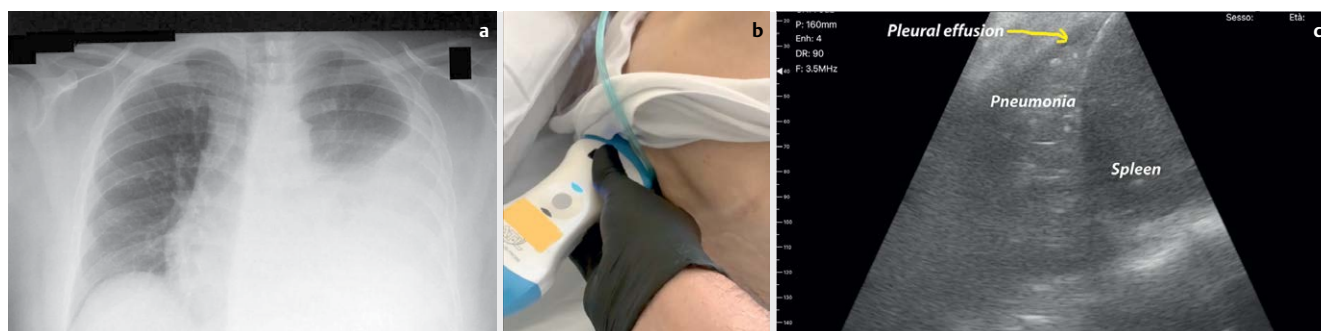

Fig. 3 A case of etiological diagnosis: female, 89 years old; resident of a retirement home; patient affected by senile dementia and therefore non-cooperative; she comes to the emergency room with dyspnea and fever; on X-ray left pleural effusion (a), but without signs of pneumonia; after hospitalization in the internal medicine department, pulmonary objectivity is not possible due to the clinical conditions and the poor compliance of the patient (b); on MED MED-US large basal pneumonia (c).

(Bedside Lung Ultrasound in Emergency) for acute respiratory failure [16], FAST (Focused Assessment with Sonography in Trauma) for peritoneal free fluid [17], RUSH (Rapid Ultrasound for Shock and Hypotension) for shock [18, 19], and CLUE (Cardiovascular Limited Ultrasound Examination) for heart failure [20]. These protocols

offer a logical POCUS workflow for specific clinical scenarios and provide a foundation for integrating POCUS findings in clinical decision-making.

This “clinical tool” is able to reduce clinical overtesting and testing can likely be reduced without a negative impact on patients

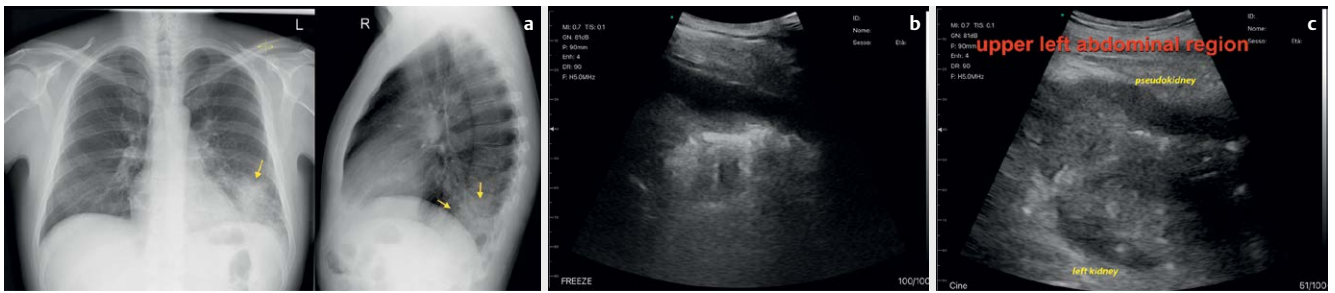


Fig. 4 A case of incidental diagnosis: 64-year-old male; for a few days he has had fever and stinging pain in the left pulmonary base, with a sense of weight in the left side. In the emergency department, blood chemistry tests revealed microcytic anemia and high inflammation indexes. Chest X-ray (a) demonstrates pneumonia at the base of the left lung. Upon entering the ward, after the visit, he undergoes thoracic and abdominal ultrasound. BED MED-US confirmed left basal pneumonia (b) but diagnosed an unexpected expansive lesion of the colonic splenic flexure (c), such as colon cancer at that site, later confirmed by colonoscopy.

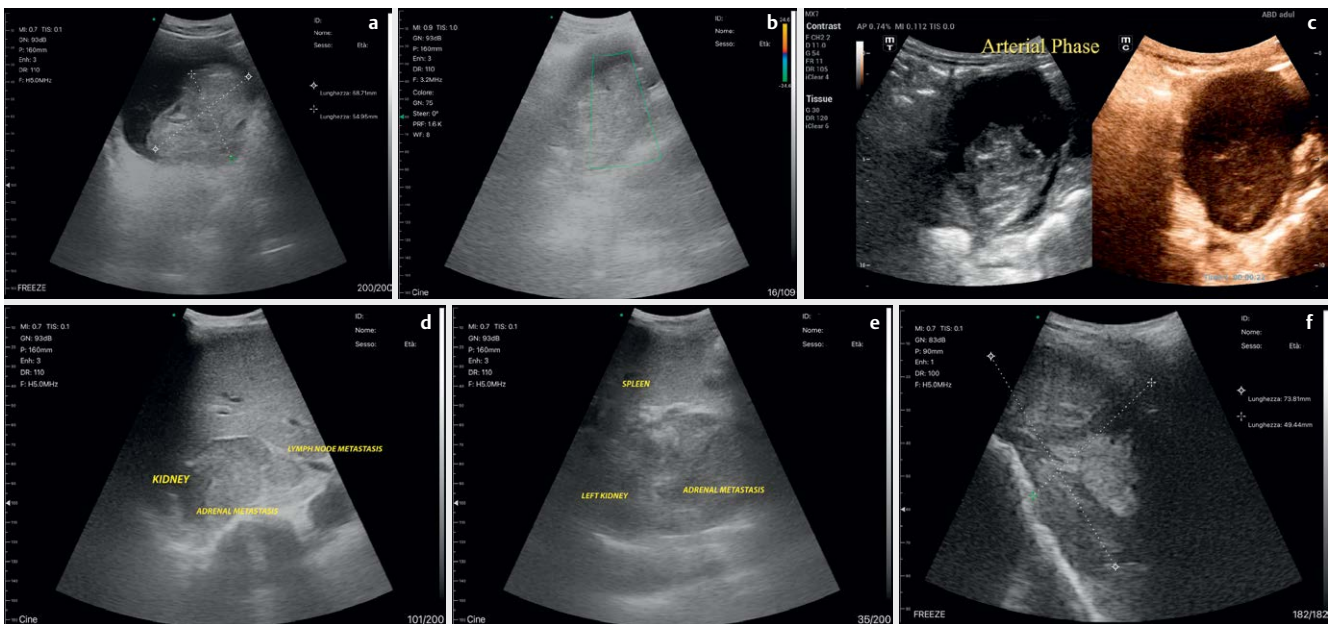


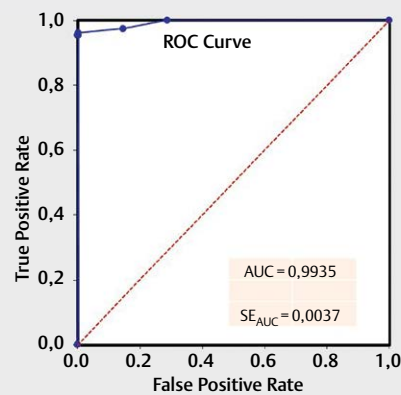
Fig. 5 A case of incidental diagnosis (the ultrasound data allows the clinician to perform clinical reasoning that leads to an unexpected diagnosis). 78-year-old man, smoker, on anticoagulant therapy for chronic atrial fibrillation; he was admitted to the emergency room for an episode of macrohematuria. US reveals a big bladder lesion (a); power Doppler (b) and then CEUS (performed at patient's bedside with portable MINDRAY MX7) (c) demonstrate non-vascularization inside this lesion, like in the case of a big clot; abdominal ultrasonography demonstrates bilateral adrenal and lymph node lesions in the abdomen with kidney infiltration and consequent bleeding from invasion of the arch arteries and renal calices (demonstrated subsequently by spiral CT) (d and e). Chest US reveals the initial cause: a big pulmonary lesion (f).

[21]. Subsequently, POCUS is not simply considered a diagnostic algorithm but rather a tool used by a skilled clinician at the bedside to guide clinical decisions in real time. Experience regarding the following has been described: acute dyspnea [22, 23] not only in the emergency setting but also in the sub-acute internal medicine area [24–26], acute heart failure, and cardiogenic shock [27, 28]. The use of multi-organ ultrasound by intensivists, emergency doctors, and anesthetists to decrease costs and the utilization of other tests and to aid decision-making in real time has previously been well documented [29]. The use of POCUS in an internal medicine ward is associated with a significant reduction in echocardiograms, chest X-rays, chest CT scans, and abdominal ultrasound examinations [30].

A recent review showed that HH-US devices could be a reliable tool for evaluating peripheral lung diseases [31, 32]. In the abdominal area, even if there are currently no reviews, previous experience has shown the clinical use of HH-US in different abdominal specialties (gastroenterology [33–36], urology [37], nephrology [38], geriatrics [39], pediatrics [40], and vascular surgery [41]). HH-US has also been used by primary care physicians [2, 42] for at-home or out-of-hospital patients, Medicare Wellness patients [43], and for in-home palliative care [44]. In 2019, the European Federation of Societies for Ultrasound in Medicine and Biology (EFSUMB) published an official position paper regarding HH-US in abdominal, chest, cardiac and pediatric US [45]. For distinct clinical questions, handheld devices may be a valuable supplement to physical exam-

► **Table 2** Comparison of ultrasound and FINAL diagnosis (clinical, instrumental, etc.): Incidence of true-positive (TP) diagnosis and true-negative (TN) diagnosis was high; US obtained only 6 false-positive (FP) and 7 false-negative (FN) diagnoses in a population of 1007 pts (n). Percentage (p) of Sens, Spec, Prev, TP.ve and TN.ve (with lower and upper limits) were evaluated. (*) The confidence interval is calculated by the method of scoring with the correction for continuity described by Newcombe [11].

	TP diagnosis	FP diagnosis	TN diagnosis	FN diagnosis		
Ultrasound diagnosis	752	6	242	7		
FINAL DIAGNOSIS	758	-	249	-		
	Diagnosis (n)	p	Lower limit	Upper limit	q	z (*)
Sensitivity (Sens)	1007	0.99	0.98	1.00	0.01	1.96
Specificity (Spec)	1007	0.98	0.96	0.98	0.02	1.96
Prevalence (Prev)	1007	0.75	0.73	0.78	0.25	1.96
TP	1007	0.99	0.98	1.00	0.01	1.96
TN	1007	0.97	0.96	0.98	0.03	1.96



Sensitivity	Specificity	P pre-test	LR+	LR-	P post-test+	P post-test-
0,991	0,976	0,003	98,500	0,015	0,229	0,000

► **Fig. 6** Corresponding Receiver Operating Characteristic (ROC) Curve of ► **Table 2** was obtained with Excel calculator (Fig. based on data from [14]), with the Area Under the Curve (AUROC) corresponding to 0.997 (confidence interval: MIN: 0.993-MAX: 1.002; SEauc: 0.0027).

ination. The American Institute of Ultrasound in Medicine (AIUM) prepared practice parameters for the performance of point-of-care ultrasound [46].

Our prospective experience demonstrates that, in expert hands, BED MED-US is an effective, safe, and inexpensive imaging technique that can help clinicians during the daily medical examination (sens: 99.1%, spec: 97.6%, LR+: 98.5; LR-: 0.015). These data may be distorted by a background bias, namely the operator has 30 years of ultrasound experience. However, this method has proved to be highly effective with minimal false negatives and false positives. The data becomes even more important when referring to the use of a palm-sized device.

However, HH-US is a complementary tool and it currently cannot be used in place of traditional US. In fact, it is impossible to perform a comprehensive ultrasound examination with HH-US because of the lack of spectral Doppler, tissue Doppler, and other spe-

cific technologies (shear wave, contrast-enhanced US, 3D reconstructions, etc.) offered by conventional devices with full features [31], which transform simple conventional ultrasound into “multiparametric” ultrasound in some sectors (such as hepatology [47], gastroenterology [48], urology [49], etc.)

In recent years, the international literature has shown increasing interest in “overall” diagnostic ultrasound. Authors have turned their focus from POCUS to multi-organ US and whole-body ultrasound (WB-US).

Multi-organ POCUS provides relevant diagnostic information that complements traditional physical examination and facilitates therapy adjustment regardless of the cause of admission. Multi-organ POCUS, to be useful, needs to be systematically integrated into the decision-making process in internal medicine [50–53].

WB-US can be used to improve the speed and accuracy of the evaluation of an increasing number of organ systems in critically ill

► **Table 3** Type of ultrasonographic diagnosis in comparison with its site (apparatus).

SITE (AND CORRESPONDING APPARATUS)	TYPES OF DIAGNOSIS								TOTAL
	CONFIRMATION	CONFIRMATION (%)	EXCLUSION	% EXCLUSION	ETIOLOGICAL	ETIOLOGICAL (%)	INCIDENTAL	INCIDENTAL (%)	
CHEST DISEASES	115	11.42%	66	6.55%	245	24.33%	16	1.59%	442
CARDIOVASCULAR SYSTEM	98	9.73%	24	2.38%	127	12.61%	4	0.40%	253
RESPIRATORY SYSTEM	17	1.69%	42	4.17%	118	11.72%	12	1.19%	189
ABDOMINAL DISEASES	81	8.04%	112	11.12%	189	18.77%	50	4.97%	432
GASTROENTERIC SYSTEM	75	7.45%	67	6.65%	150	14.90%	43	4.27%	335
GENITAL SYSTEM	1	0.10%			7	0.70%	1	0.10%	9
URINARY SYSTEM	5	0.50%	45	4.47%	32	3.18%	6	0.60%	88
NEUROLOGIC DISEASES			32	3.18%	1	0.10%			33
VASCULAR DISEASES	9	0.89%			21	2.09%	1	0.10%	31
ARTERIES	5	0.50%			2	0.20%			7
VEINS	4	0.40%			19	1.89%	1	0.10%	24
ENDOCRINOLOGIC DISEASES	5	0.50%	4	0.40%	10	0.99%	2	0.20%	21
INTEGUMENTARY SYSTEM DISEASES	3	0.30%	10	0.99%	6	0.60%			19
MUSCULOSKELETAL DISEASES	1	0.10%	18	1.79%					19
SYSTEMIC DISEASES			6	0.60%					6
HEMATOLOGICAL DISEASES			1	0.10%	3	0.30%			4
TOTAL	214	21.25%	249	24.73%	475	47.17%	69	6.85%	1007

patients. Cardiac and abdominal ultrasound can be used to identify the mechanisms and etiology of hemodynamic instability. In hypoxemia or hypercarbia, lung ultrasound can rapidly identify the etiology of the condition, with an accuracy that is equivalent to that of computed tomography. For encephalopathy, ocular ultrasound and transcranial Doppler can identify elevated intracranial pressure and midline shift. Renal and bladder ultrasound can identify the mechanisms and etiology of renal failure. Ultrasound can also improve the accuracy and safety of percutaneous procedures and should currently be used routinely for central vein catheterization and percutaneous tracheostomy [54]. Furthermore, ultrasound guidance is used increasingly to perform the following six bedside procedures that are core competencies of hospitalists: abdominal paracentesis, arterial catheter placement, arthrocentesis, central venous catheter placement, lumbar puncture, and thoracentesis. It's necessary to standardize procedures [55].

However, evidence is still inadequate, and more research is needed regarding the abdominal and pleural use of handheld ultrasound with more standardized comparisons, using only blinded reviewers [8].

The system has proved to be reliable but the most important clinical aspect is clinical utility. Internal medicine patients are complex, because they have multiple comorbidities, and sometimes they also have poor compliance (due to advanced age) during the execution of the physical examination and/or instrumental tests.

In these settings, BED MED-US is quickly able to provide the clinician at the bedside with "ultrasound information" that the doctor

immediately translates into clinical data that is useful for a precise diagnosis. For the first time, our experience demonstrated that ultrasound information is able not only to answer a single clinical question but also to help the doctor with regard to clinical reasoning and confirmation of a clinical diagnosis (► Fig. 1) or exclusion of other possible diagnoses (► Fig. 2). However, the best results were achieved in the search for the etiological diagnosis (► Fig. 3) and clinically relevant incidental diagnosis (► Fig. 4 and 5).

The percentage of etiological diagnoses was slightly higher in the abdomen than in the cardiological or pulmonary regions. However, abdominal ultrasound has shown a high incidence of incidental diagnoses. It can be concluded that abdominal ultrasound, at least in internal medicine departments, should be performed routinely, even independently of the clinical picture.

The term incidental diagnosis is usually defined as the detection of an abnormality in a symptomatic patient that is not apparently related to the patient's symptoms [12]. The vast majority of incidentalomas will be a normal variant or an incidental benign finding (from 3% and up to 50% depending on the imaging method and sites [56]). However, a rare but possibly malignant incidental finding can be detected [12]. We did not consider "incidentalomas" that were irrelevant for the management of the patient (gallbladder calculi: 29.4%, hepatic and renal cysts: 26.8%). We only considered those that clinically modified the patient's diagnostic and/or therapeutic procedure: 3.2% of causes were benign and 3.6% were malignant. Recently, it was demonstrated that an "incidental cancer"

► **Table 4** This table demonstrates the number of patients for every room of our department, the number of minutes saved with respect to round trip transporting of patients, and the costs consequently saved based on the use of a single operator (for self-sufficient patients) (1) or two (2) operators (for bedridden patients the cost of each minute saved for patient transport was calculated by multiplying the number of minutes by the average cost per minute of a social health worker in Lombardy (0.27 euros per minute) (This value is obtained by dividing the hourly cost average wage equal to 16.25 euros) [13].

	PATIENTS	MINUTES	COSTS (euros)
ROOM	1		
OPERATOR(S)			
1	30	628	169.56
2	25	1068	288.36
TOTAL	55	1696	457.92
TOTAL MINUTES FOR TRANSPORT (single operator)	10–11 min		
TOTAL MINUTES FOR TRANSPORT (ROUND TRIP) (single operator)	20–22 min		
TOTAL MINUTES FOR TRANSPORT (ROUND TRIP) (two operators)	40–44 min		
ROOM	2		
OPERATOR(S)			
1	24	594	160.38
2	27	1364	368.28
TOTAL	51	1958	528.66
TOTAL MINUTES FOR TRANSPORT (single operator)	12–13 min		
TOTAL MINUTES FOR TRANSPORT (ROUND TRIP) (single operator)	24–26 min		
TOTAL MINUTES FOR TRANSPORT (ROUND TRIP) (two operators)	48–52 min		
ROOM	3		
OPERATOR(S)			
1	29	850	229.50
2	35	2020	545.40
TOTAL	64	2870	774.90
TOTAL MINUTES FOR TRANSPORT (single operator)	14–15 min		
TOTAL MINUTES FOR TRANSPORT (ROUND TRIP) (single operator)	28–30 min		
TOTAL MINUTES FOR TRANSPORT (ROUND TRIP) (two operators)	56–60 min		
ROOM	4		
OPERATOR(S)			
1	20	658	177.66
2	29	1920	518.40
TOTAL	49	2578	696.06
TOTAL MINUTES FOR TRANSPORT (single operator)	16–17 min		
TOTAL MINUTES FOR TRANSPORT (ROUND TRIP) (single operator)	32–34 min		
TOTAL MINUTES FOR TRANSPORT (ROUND TRIP) (two operators)	64–68 min		
ROOM	5		
OPERATOR(S)			
1	11	396	106.92
2	12	864	233.28
TOTAL	23	1260	340.20
TOTAL MINUTES FOR TRANSPORT (single operator)	18–19 min		
TOTAL MINUTES FOR TRANSPORT (ROUND TRIP) (single operator)	36–38 min		
TOTAL MINUTES FOR TRANSPORT (ROUND TRIP) (two operators)	72–76 min		
ROOM	6		
OPERATOR(S)			
1	24	988	266.76
2	31	2532	683.64
TOTAL	55	3520	950.40

► **Table 4** Continued.

	PATIENTS	MINUTES	COSTS (euros)
TOTAL MINUTES FOR TRANSPORT (single operator)	21 min		
TOTAL MINUTES FOR TRANSPORT (ROUND TRIP) (single operator)	42 min		
TOTAL MINUTES FOR TRANSPORT (ROUND TRIP) (two operators)	84 min		
ROOM	7		
OPERATOR(S)			
1	15	600	162.00
2	11	880	237.60
TOTAL	26	1480	399.60
TOTAL MINUTES FOR TRANSPORT (single operator)	20 min		
TOTAL MINUTES FOR TRANSPORT (ROUND TRIP) (single operator)	40 min		
TOTAL MINUTES FOR TRANSPORT (ROUND TRIP) (two operators)	80 min		
ROOM	8		
OPERATOR(S)			
1	13	468	126.36
2	17	1224	330.48
TOTAL	30	1692	456.84
TOTAL MINUTES FOR TRANSPORT (single operator)	19 min		
TOTAL MINUTES FOR TRANSPORT (ROUND TRIP) (single operator)	38 min		
TOTAL MINUTES FOR TRANSPORT (ROUND TRIP) (two operators)	76 min		
ROOM	9		
OPERATOR(S)			
1	29	900	243.00
2	32	1980	534.60
TOTAL	61	2880	777.60
TOTAL MINUTES FOR TRANSPORT (single operator)	10–11 min		
TOTAL MINUTES FOR TRANSPORT (ROUND TRIP) (single operator)	20–22 min		
TOTAL MINUTES FOR TRANSPORT (ROUND TRIP) (two operators)	40–42 min		
ROOM	10		
OPERATOR(S)			
1	25	678	183.06
2	33	1780	480.60
TOTAL	58	2458	663.66
TOTAL MINUTES FOR TRANSPORT (single operator)	9–10 min		
TOTAL MINUTES FOR TRANSPORT (ROUND TRIP) (single operator)	18–20 min		
TOTAL MINUTES FOR TRANSPORT (ROUND TRIP) (two operators)	36–40 min		
ROOM	11		
OPERATOR(S)			
1	37	850	229.50
2	27	1236	333.72
TOTAL	64	2086	563.22
TOTAL MINUTES FOR TRANSPORT (single operator)	8–9 min		
TOTAL MINUTES FOR TRANSPORT (ROUND TRIP) (single operator)	16–18 min		
TOTAL MINUTES FOR TRANSPORT (ROUND TRIP) (two operators)	32–36 min		
ROOM	12		
OPERATOR(S)			
1	30	574	154.98
2	29	1104	298.08
TOTAL	59	1678	453.06

► **Table 4** Continued.

	PATIENTS	MINUTES	COSTS (euros)
TOTAL MINUTES FOR TRANSPORT (single operator)	7–8 min		
TOTAL MINUTES FOR TRANSPORT (ROUND TRIP) (single operator)	14–16 min		
TOTAL MINUTES FOR TRANSPORT (ROUND TRIP) (two operators)	28–32 min		
ROOM	13		
OPERATOR(S)			
1	23	344	92.88
2	29	868	234.36
TOTAL	52	1212	327.24
TOTAL MINUTES FOR TRANSPORT (single operator)	6–7 min		
TOTAL MINUTES FOR TRANSPORT (ROUND TRIP) (single operator)	12–14 min		
TOTAL MINUTES FOR TRANSPORT (ROUND TRIP) (two operators)	24–28 min		
ROOM	14		
OPERATOR(S)			
1	23	308	83.16
2	43	1104	298.08
TOTAL	66	1412	381.24
TOTAL MINUTES FOR TRANSPORT (single operator)	5–6 min		
TOTAL MINUTES FOR TRANSPORT (ROUND TRIP) (single operator)	10–12 min		
TOTAL MINUTES FOR TRANSPORT (ROUND TRIP) (two operators)	20–24 min		
ROOM	15		
OPERATOR(S)			
1	21	228	61.56
2	34	756	204.12
TOTAL	55	984	265.68
TOTAL MINUTES FOR TRANSPORT (single operator)	4–5 min		
TOTAL MINUTES FOR TRANSPORT (ROUND TRIP) (single operator)	8–10 min		
TOTAL MINUTES FOR TRANSPORT (ROUND TRIP) (two operators)	16–20 min		
ROOM	16		
OPERATOR(S)			
1	24	216	58.32
2	30	544	146.88
TOTAL	54	760	205.20
TOTAL MINUTES FOR TRANSPORT (single operator)	3–4 min		
TOTAL MINUTES FOR TRANSPORT (ROUND TRIP) (single operator)	6–8 min		
TOTAL MINUTES FOR TRANSPORT (ROUND TRIP) (two operators)	12–16 min		
ROOM	17		
OPERATOR(S)			
1	27	184	49.68
2	33	456	123.12
TOTAL	60	640	172.80
TOTAL MINUTES FOR TRANSPORT (single operator)	2–3 min		
TOTAL MINUTES FOR TRANSPORT (ROUND TRIP) (single operator)	4–6 min		
TOTAL MINUTES FOR TRANSPORT (ROUND TRIP) (two operators)	8–12 min		
ROOM	18		
OPERATOR(S)			
1	24	130	35.10
2	36	352	95.04
TOTAL	60	482	130.14

► **Table 4** Continued.

	PATIENTS	MINUTES	COSTS (euros)
TOTAL MINUTES FOR TRANSPORT (single operator)	2–3 min		
TOTAL MINUTES FOR TRANSPORT (ROUND TRIP) (single operator)	4–6 min		
TOTAL MINUTES FOR TRANSPORT (ROUND TRIP) (two operators)	8–12 min		
ROOM	19		
OPERATOR(S)			
1	20	640	172.80
2	14	896	241.92
TOTAL	34	1536	414.72
TOTAL MINUTES FOR TRANSPORT (single operator)	11 min		
TOTAL MINUTES FOR TRANSPORT (ROUND TRIP) (single operator)	22 min		
TOTAL MINUTES FOR TRANSPORT (ROUND TRIP) (two operators)	44 min		
ROOM	20		
OPERATOR(S)			
1	17	510	137.70
2	14	840	226.80
TOTAL	31	1350	364.50
TOTAL MINUTES FOR TRANSPORT (single operator)	10 min		
TOTAL MINUTES FOR TRANSPORT (ROUND TRIP) (single operator)	20 min		
TOTAL MINUTES FOR TRANSPORT (ROUND TRIP) (two operators)	40 min		
TOTAL			
OPERATOR(S)			
1	466	10744	2901.00
2	541	23788	6423.00
TOTAL	1007	34532	9324.00

was identified in 4% of a general population by several image techniques [57] and this finding is very similar to our experience (3.6%).

The use of BED MED-US in difficult cases, i. e., cases in which ultrasound information, guided by clinical reasoning, quickly leads to etiological or incidental diagnoses that are otherwise clinically impossible, merits a separate discussion (► **Fig. 5**).

In addition to being effective and clinically useful, ultrasound performed at the bedside saves time and human resources. In our experience, we have saved about 575 hours of work just for the transport of patients from the ward to the ultrasound room and about 9,300 euros.

This study has many limitations. Although it was prospective, it was performed in a single center, and there was only a single operator with vast ultrasound experience. The real clinical impact should be reevaluated in multicenter studies and also with less skilled staff.

Finally, official regulations regarding the use of handheld ultrasound in medical departments by internists vary, and the degree to which POCUS has been integrated is variable worldwide. In Europe, POCUS is considered a core competency [58], while in Canada, POCUS is recommended only as part of an expanded curriculum [59]. Regardless of these curricular differences, what has emerged over time is the consistent recognition of the importance of POCUS in the practice of clinical medicine by regulatory bodies

and professional societies both on the national level (e. g., Society for Hospital Medicine, USA [60]) and the international level (e. g., WINFOCUS [61]).

Conflict of Interest

The authors declare that they have no conflict of interest.

References

- [1] Diaz-Gomez JL, Mayo PH, Koenig SJ. Point-of-Care Ultrasonography. *N Engl J Med* 2021; 385: 1593–1602. DOI: 10.1056/NEJMr1916062
- [2] Shaddock L, Smith T. Potential for Use of Portable Ultrasound Devices in Rural and Remote Settings in Australia and Other Developed Countries: A Systematic Review. *J Multidiscip Healthc* 2022; 15: 605–625. DOI: 10.2147/JMDH.S359084
- [3] Elder AT, McManus IC, Patrick A et al. The value of the physical examination in clinical practice: an international survey. *Clin Med (Lond)* 2017; 17: 490–498. DOI: 10.7861/clinmedicine.17-6-490
- [4] [Anonym]. The Centennial of the Stethoscope. *JAMA* 2016; 315: 2738. DOI: 10.1001/jama.2015.17091

- [5] Lopez-Palmero S, Bolivar-Herrera N, Lopez-Lloret G et al. Diagnostic utility of handheld ultrasonography as an extension of the physical examination of patients with heart failure. *Revista clinica espanola* 2015; 215: 204–210. DOI: 10.1016/j.rce.2015.01.015
- [6] Kimura BJ, Shaw DJ, Amundson SA et al. Cardiac Limited Ultrasound Examination Techniques to Augment the Bedside Cardiac Physical Examination. *J Ultrasound Med* 2015; 34: 1683–1690. DOI: 10.7863/ultra.15.14.09002
- [7] Kimura BJ. Point-of-care cardiac ultrasound techniques in the physical examination: better at the bedside. *Heart* 2017; 103: 987–994. DOI: 10.1136/heartjnl-2016-309915
- [8] Rykkje A, Carlsen JF, Nielsen MB. Hand-Held Ultrasound Devices Compared with High-End Ultrasound Systems: A Systematic Review. *Diagnostics (Basel)* 2019; 9: 61. DOI: 10.3390/diagnostics9020061
- [9] Duminuco A, Cupri A, Massimo R et al. Handheld Ultrasound or Conventional Ultrasound Devices in Patients Undergoing HCT: A Validation Study. *J Clin Med* 2023; 12: 520. DOI: 10.3390/jcm12020520
- [10] Menten J, Lesaffre E. A general framework for comparative Bayesian meta-analysis of diagnostic studies. *BMC Med Res Methodol* 2015; 15: 70. DOI: 10.1186/s12874-015-0061-7
- [11] Newcombe RG. Two-sided confidence intervals for the single proportion: comparison of seven methods. *Statistics in medicine* 1998; 17: 857–872. DOI: 10.1002/(sici)1097-0258(19980430)17:8<857::aid-sim777>3.0.co;2-e
- [12] Kirkpatrick C, Evans R, Parker P et al. Incidental Findings on General Medical Ultrasound (US) Examinations. In: *British Medical Ultrasound Society (BMUS). third Edition ed* <https://www.bmus.org/policies-statements-guidelines/professional-guidance/guidance-pages/incidental-findings/>; British Medical Ultrasound Society (BMUS) 2021; 38.
- [13] INDEED. A quanto ammonta uno stipendio da Oss (Brescia, Lombardia)? In *Internet* <https://it.indeed.com/career/oss/salaries/Brescia--Lombardia>
- [14] Watkins MW. An EXCEL program for calculating and graphing the Receiver Operating Characteristic (ROC) [Computer software]. State College, PA: Ed & Psych Associates; 2000
- [15] Dietrich CF, Goudie A, Chiorean L et al. Point of Care Ultrasound: A WFUMB Position Paper. *Ultrasound Med Biol* 2016. DOI: 10.1016/j.ultrasmedbio.2016.06.021
- [16] Lichtenstein DA, Meziere GA. Relevance of lung ultrasound in the diagnosis of acute respiratory failure: the BLUE protocol. *Chest* 2008; 134: 117–125. DOI: 10.1378/chest.07-2800
- [17] Scalea TM, Rodriguez A, Chiu WC et al. Focused Assessment with Sonography for Trauma (FAST): results from an international consensus conference. *J Trauma* 1999; 46: 466–472. DOI: 10.1097/00005373-199903000-00022
- [18] Perera P, Mailhot T, Riley D et al. The RUSH exam: Rapid Ultrasound in SHock in the evaluation of the critically ill. *Emerg Med Clin North Am* 2010; 28: 29–56, vii. DOI: 10.1016/j.emc.2009.09.010
- [19] Weingarten SD, Duque D, Nelson B. The RUSH exam: Rapid Ultrasound for Shock and Hypotension. In: *EMCrit website*: 2016.
- [20] Kimura BJ, Shaw DJ, Agan DL et al. Value of a cardiovascular limited ultrasound examination using a hand-carried ultrasound device on clinical management in an outpatient medical clinic. *Am J Cardiol* 2007; 100: 321–325. DOI: 10.1016/j.amjcard.2007.02.104
- [21] Koch C, Roberts K, Petrucci C et al. The Frequency of Unnecessary Testing in Hospitalized Patients. *Am J Med* 2018; 131: 500–503. DOI: 10.1016/j.amjmed.2017.11.025
- [22] Zanobetti M, Scorpiniti M, Gigli C et al. Point-of-Care Ultrasonography for Evaluation of Acute Dyspnea in the ED. *Chest* 2017; 151: 1295–1301. DOI: 10.1016/j.chest.2017.02.003
- [23] Gaber HR, Mahmoud MI, Carnell J et al. Diagnostic accuracy and temporal impact of ultrasound in patients with dyspnea admitted to the emergency department. *Clin Exp Emerg Med* 2019; 6: 226–234. DOI: 10.15441/ceem.18.072
- [24] Dalen JE. Cardiac Examination: Stethoscope or Pocket Echo-Why Not Both? *Am J Med* 2016; 129: 649–650. DOI: 10.1016/j.amjmed.2016.01.055
- [25] Mozzini C, Di Dio Perna M, Pesce G et al. Lung ultrasound in internal medicine efficiently drives the management of patients with heart failure and speeds up the discharge time. *Intern Emerg Med* 2018; 13: 27–33. DOI: 10.1007/s11739-017-1738-1
- [26] Perrone T, Maggi A, Sgarlata C et al. Lung ultrasound in internal medicine: A bedside help to increase accuracy in the diagnosis of dyspnea. *European journal of internal medicine* 2017; 46: 61–65. DOI: 10.1016/j.ejim.2017.07.034
- [27] Price S, Platz E, Cullen L et al. Expert consensus document: Echocardiography and lung ultrasonography for the assessment and management of acute heart failure. *Nat Rev Cardiol* 2017; 14: 427–440. DOI: 10.1038/nrcardio.2017.56
- [28] Mancusi C, Carlino MV, Sforza A. Point-of-care ultrasound with pocket-size devices in emergency department. *Echocardiography* 2019; 36: 1755–1764. DOI: 10.1111/echo.14451
- [29] Narasimhan M, Koenig SJ, Mayo PH. A Whole-Body Approach to Point of Care Ultrasound. *Chest* 2016; 150: 772–776. DOI: 10.1016/j.chest.2016.07.040
- [30] Barchiesi M, Bulgheroni M, Federici C et al. Impact of point of care ultrasound on the number of diagnostic examinations in elderly patients admitted to an internal medicine ward. *European journal of internal medicine* 2020; 79: 88–92. DOI: 10.1016/j.ejim.2020.06.026
- [31] Haji-Hassan M, Lenghel LM, Bolboaca SD. Hand-Held Ultrasound of the Lung: A Systematic Review. *Diagnostics (Basel)* 2021; 11: 1381. DOI: 10.3390/diagnostics11081381
- [32] Buda N, Kosiak W, Welnicki M et al. Recommendations for Lung Ultrasound in Internal Medicine. *Diagnostics* 2020; 10: 597. DOI: 10.3390/diagnostics10080597
- [33] Bots S, De Voogd F, De Jong M et al. Point-of-care intestinal ultrasound in IBD patients: disease management and diagnostic yield in a real-world cohort and proposal of a point-of-care algorithm. *Journal of Crohn's & Colitis* 2022; 16: 606–615. DOI: 10.1093/ecco-jcc/jjab175
- [34] Costantino A, Piagnani A, Nandi N et al. Reproducibility and diagnostic accuracy of pocket-sized ultrasound devices in ruling out compensated cirrhosis of mixed etiology. *Eur Radiol* 2022; 32: 4609–4615. DOI: 10.1007/s00330-022-08572-2
- [35] Rispo A, Calabrese G, Testa A et al. Hocus Pocus: the Role of Hand-held Ultrasonography in Predicting Disease Extension and Endoscopic Activity in Ulcerative Colitis. *Journal of Crohn's & colitis* 2023; 17: 1089–1096. DOI: 10.1093/ecco-jcc/jjad024
- [36] Rispo A, de Sire R, Mainenti PP et al. David Against Goliath: Direct Comparison of Handheld Bowel Sonography and Magnetic Resonance Enterography for Diagnosis of Crohn's Disease. *Inflamm Bowel Dis* 2023; 29: 563–569. DOI: 10.1093/ibd/izac116
- [37] Moussaoui G, Zakaria AS, Negrean C et al. Accuracy of Clarius, Handheld Wireless Point-of-Care Ultrasound, in Evaluating Prostate Morphology and Volume Compared to Radical Prostatectomy Specimen Weight: Is There a Difference between Transabdominal vs Transrectal Approach? *J Endourol* 2021; 35: 1300–1306. DOI: 10.1089/end.2020.0874
- [38] Galindo P, Gasca C, Argaiz ER et al. Point of care venous Doppler ultrasound: Exploring the missing piece of bedside hemodynamic assessment. *World J Crit Care Med* 2021; 10: 310–322. DOI: 10.5492/wjccm.v10.i6.310
- [39] Frohlich E, Beller K, Muller R et al. Point of Care Ultrasound in Geriatric Patients: Prospective Evaluation of a Portable Handheld Ultrasound Device. *Ultraschall in Med* 2020; 41: 308–316. DOI: 10.1055/a-0889-8070

- [40] Musolino AM, Buonsenso D, Massolo AC et al. Point of care ultrasound in the paediatric acute care setting: Getting to the 'heart' of respiratory distress. *J Paediatr Child Health* 2021; 57: 318–322. DOI: 10.1111/jpc.15308
- [41] Gupta A, Kindarara DM, Chun KC et al. Accuracy of Point-of-Care Ultrasound in Follow Up Abdominal Aortic Aneurysm Imaging. *Vascular and endovascular surgery* 2022; 15385744221099093. DOI: 10.1177/15385744221099093
- [42] Vilanova-Rotllan S, Kostov B, Giner Martos MJ et al. Feasibility study of abdominal ultrasound using hand-held devices in homecare services. *Medicina clinica* 2022; 158: 361–365. DOI: 10.1016/j.medcli.2021.03.038
- [43] Rosborough TK, Becker JS, Desautels CN et al. An Ultrasound Screening Exam During Medicare Wellness Visits May Be Beneficial. *J Ultrasound Med* 2022; 41: 1069–1076. DOI: 10.1002/jum.15788
- [44] Lo H, Eder N, Boten D et al. Handheld Ultrasound (HHUS): Potential for Home Palliative Care. *Ultrasound Int Open* 2022; 8: E68–E76. DOI: 10.1055/a-1999-7834
- [45] Nielsen MB, Cantisani V, Sidhu PS et al. The Use of Handheld Ultrasound Devices - An EFSUMB Position Paper. *Ultraschall Med* 2019; 40: 30–39. DOI: 10.1055/a-0783-2303
- [46] [Anonym]. AIUM Practice Parameter for the Performance of Point-of-Care Ultrasound Examinations. *J Ultrasound Med* 2019; 38: 833–849. DOI: 10.1002/jum.14972
- [47] Grgurevic I, Tjesic Drinkovic I, Pinzani M. Multiparametric ultrasound in liver diseases: an overview for the practising clinician. *Postgraduate medical journal* 2019; 95: 425–432. DOI: 10.1136/postgradmedj-2018-136111
- [48] Puca P, Del Vecchio LE, Ainora ME et al. Role of Multiparametric Intestinal Ultrasound in the Evaluation of Response to Biologic Therapy in Adults with Crohn's Disease. *Diagnostics (Basel)* 2022; 12: 1991. DOI: 10.3390/diagnostics12081991
- [49] Jager A, Postema AW, Mischi M et al. Clinical Trial Protocol: Developing an Image Classification Algorithm for Prostate Cancer Diagnosis on Three-dimensional Multiparametric Transrectal Ultrasound. *Eur Urol Open Sci* 2023; 49: 32–43. DOI: 10.1016/j.euros.2022.12.018
- [50] Casado-Lopez I, Tung-Chen Y, Torres-Arrese M et al. Usefulness of Multi-Organ Point-of-Care Ultrasound as a Complement to the Decision-Making Process in Internal Medicine. *J Clin Med* 2022; 11: 2256. DOI: 10.3390/jcm11082256
- [51] Cid-Serra X, Hoang W, El-Ansary D et al. Clinical Impact of Point-of-Care Ultrasound in Internal Medicine Inpatients: A Systematic Review. *Ultrasound Med Biol* 2022; 48: 170–179. DOI: 10.1016/j.ultrasmedbio.2021.09.013
- [52] Cid-Serra X, Roysse A, Canty D et al. Clinical relevance of a multiorgan focused clinical ultrasound in internal medicine. *Ultrasound J* 2022; 14: 16. DOI: 10.1186/s13089-022-00269-3
- [53] Radonjic T, Popovic M, Zdravkovic M et al. Point-of-Care Abdominal Ultrasonography (POCUS) on the Way to the Right and Rapid Diagnosis. *Diagnostics (Basel)* 2022; 12: 2052. DOI: 10.3390/diagnostics12092052
- [54] Denault A, Canty D, Azzam M et al. Whole body ultrasound in the operating room and intensive care unit. *Kor J Anesthesiol* 2019; 72: 413–428. DOI: 10.4097/kja.19186
- [55] Lucas BP, Tierney DM, Jensen TP et al. Credentialing of Hospitalists in Ultrasound-Guided Bedside Procedures: A Position Statement of the Society of Hospital Medicine. *J Hosp Med* 2018; 13: 117–125. DOI: 10.12788/jhm.2917
- [56] O'Sullivan JW, Muntinga T, Grigg S et al. Prevalence and outcomes of incidental imaging findings: umbrella review. *BMJ* 2018; 361: k2387. DOI: 10.1136/bmj.k2387
- [57] Koo MM, Rubin G, McPhail S et al. Incidentally diagnosed cancer and commonly preceding clinical scenarios: a cross-sectional descriptive analysis of English audit data. *BMJ open* 2019; 9: e028362. DOI: 10.1136/bmjopen-2018-028362
- [58] Torres-Macho J, Aro T, Bruckner I et al. Point-of-care ultrasound in internal medicine: A position paper by the ultrasound working group of the European federation of internal medicine. *European journal of internal medicine* 2020; 73: 67–71. DOI: 10.1016/j.ejim.2019.11.016
- [59] Ma IWY, Arishenkoff S, Wiseman J et al. Internal Medicine Point-of-Care Ultrasound Curriculum: Consensus Recommendations from the Canadian Internal Medicine Ultrasound (CIMUS) Group. *Journal of general internal medicine* 2017; 32: 1052–1057. DOI: 10.1007/s11606-017-4071-5
- [60] Soni NJ, Schnobrich D, Mathews BK et al. Point-of-Care Ultrasound for Hospitalists: A Position Statement of the Society of Hospital Medicine. *J Hosp Med* 2019; 14: E1–E6. DOI: 10.12788/jhm.3079
- [61] Neri L, Storti E, Lichtenstein D. Toward an ultrasound curriculum for critical care medicine. *Crit Care Med* 2007; 35: S290–304. DOI: 10.1097/01.CCM.0000260680.16213.26