

# Therapeutic results in stage I Wilms' tumors in children – 15 years of surgical experience

Sabina Szymik-Kantorowicz<sup>1</sup>, Wiesław Urbanowicz<sup>2</sup>, Marcin Surmiak<sup>3</sup>, Janusz Sulisławski<sup>2</sup>

<sup>1</sup>Department of Pediatric Surgery Collegium Medicum Jagiellonian University in Cracow; Institute of Clinical Pharmacy Jagiellonian University Collegium Medicum in Cracow, Poland

<sup>2</sup>Department of Pediatric Urology Collegium Medicum Jagiellonian University in Cracow, Poland

<sup>3</sup>Laboratory of Molecular Biology and Clinical Genetics Collegium Medicum Jagiellonian University in Cracow, Poland

## KEY WORDS

nephron-sparing surgery ▶ simple nephrectomy  
▶ stage I Wilms' tumor

## ABSTRACT

**Introduction.** Progress in the therapeutic management of Wilms' tumors (WT) in children has resulted in the fact that presently, almost all children with stage I and favorable histology diseases have a chance for a cure.

**The aim of the study.** The objective of the report is an analysis of therapeutic results in children with unilateral stage I Wilms' tumors depending on the extent of tumor resection.

**Material and methods.** The analysis included children treated between 1993 and 2008 under the Polish Wilms' Tumor Study, initially following the protocol SIOP 93-01 (patients treated up to 2002) and subsequently SIOP 2001. Following neoadjuvant chemotherapy, depending on tumor size and tumor response to treatment, the children were qualified for a radical nephrectomy, simple nephrectomy, or nephron-sparing surgery. Following surgical treatment, all the children were subjected to adjuvant chemotherapy in keeping with the therapeutic protocol obligatory at the time.

**Results.** Within the 15 years, 111 children with Wilms' tumor were treated; the group included 43 children with stage I disease, which constituted 38.9% of the total number. Radical nephrectomies were performed in three (6.98%) children, simple nephrectomies in 32 (74.42%), and nephron-sparing surgery in eight (18.6%). Regardless of the employed surgical treatment modality, all the children are alive and none have demonstrated recurrent disease. The mean post-treatment completion follow-up period is 73 months (median value, 68 months).

**Conclusion.** A simple nephrectomy and, whenever possible, nephron-sparing surgery represents sufficient treatment in 93% of children with stage I Wilms' tumor. To improve qualification for surgical treatment we propose the employment of NSS for stage Ia Wilms' tumors and SN for stage Ib Wilms' tumors.

tailored therapeutic modality. Thanks to multicenter investigations carried out for a prolonged period in large groups of subjects, mostly to NWTS (National Wilms' Tumor Studies) and SIOP (Société Internationale d'Oncologie Pédiatrique), more than 80% of children diagnosed with Wilms' tumor can look forward to long-term survival at 20 years from diagnosis [1]. In stage I and favorable histology disease, at present almost all children have a chance of a cure.

Surgical resection continues to be an essential element of combined therapy in WT. Both the therapeutic protocol SIOP-2001 and the NWTS-5 protocol recommend in children with unilateral kidney tumor a radical nephrectomy combined with resection of all suspicious lymph nodes or a biopsy of lymph nodes at the level of renal vessels even if they do not seem to be invaded. Nephron-sparing surgery (NSS) is recommended in children with bilateral WT, tumors involving a solitary kidney, and in patients with syndromes predisposing to further renal malignancies [2, 3, 4]. Both protocols do not recommend NSS for treatment of localized unilateral nephroblastoma, yet they allow for such a procedure in the case of small tumors [1, 5]. Both protocols lack unambiguous recommendations to NSS management.

The objective of the report is the analysis of therapeutic results achieved in children with unilateral stage I Wilms' tumors depending on the extent of surgical resection.

## MATERIAL AND METHODS

The analysis included 43 children with unilateral stage I Wilms' tumors classified in keeping with the SIOP criteria, treated by the same team between January 1993 and December 2008. Previously, the same team had based their therapeutic management of children with WT on the NWTS protocols. The change in strategy was associated with the authors joining the Polish Wilms' Tumor Study (PWTS), which adopted a uniform management policy in kidney tumors based on the SIOP 93-01 (patients treated up to 2002) and SIOP-2001 protocols.

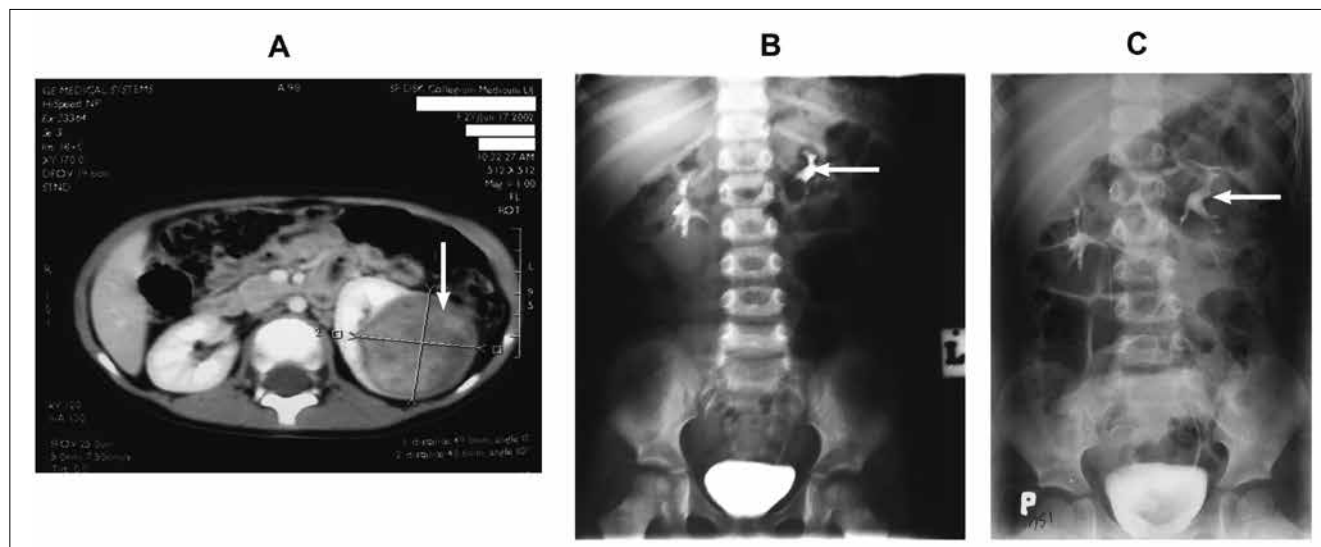
In all the children, the diagnosis was established based on a physical examination and imaging studies (abdominal ultrasonography, chest X-ray in two projections, abdominal CT scan), commencing the treatment from neoadjuvant chemotherapy. No preliminary tumor biopsies were performed. In case of diagnostic doubts, children with locally advanced disease were qualified for primary surgical treatment. All the children with localized disease received neoadjuvant chemotherapy with vincristin (VCR) and actinomycin D (AMD) administered over 4 weeks.

Following the completion of the preliminary treatment, the tumor size was assessed by ultrasound or, in children qualified for NSS, a CT scan was performed followed by an intravenous pyelogram (IVP) (Fig. 1).

The decision regarding the extent of surgery took into consideration tumor size and tumor response to chemotherapy. In children with large tumors and a poor response to neoadjuvant chemotherapy, radical nephrectomies (RN) were performed – the

## INTRODUCTION

Wilms tumor (WT, nephroblastoma) is not only the most common kidney tumor in children, but also one of the best-understood tumors with respect to its clinical course, differences in cellular structure, and the resultant selection of an adequately



**Fig. 1.** Left sided Wilms Tumor: A. Tumor in middle part of the kidney – CT. B. Deformation of the middle and lower calyx – Urography. C. Postoperative Urography with middle calyx depletion after tumor resection.

kidney was resected together with the tumor, perirenal fat tissue, and Gerota's fascia.

Children with tumors smaller in size and a very good response to chemotherapy were qualified for simple nephrectomies (SN), i.e. resection of the tumor-containing kidney along with the perirenal fat, leaving intact the non-tumorous adrenal gland and Gerota's fascia.

A less numerous group was composed of small tumors, which shrank even more following neoadjuvant treatment. Nevertheless, tumor shrinkage in size was not as apparent as in the group of children qualified for simple nephrectomies. Children with such tumors were qualified for nephron-sparing surgery (NSS). Three patients from this group were presented in a PWTS communication during the XXXVII SIOP conference [6]. Depending on the location of the tumor within the kidney and technical possibilities, NSS was represented by a heminephrectomy, polar resection or an atypical enucleation-resembling resection. Resections were performed maintaining the renal blood flow using a harmonic scalpel or the LigaSure vessel sealing system. Taking advantage of the neoadjuvant therapy-strengthened pseudocapsule, the tumor resection was performed through the normal kidney parenchyma leaving a 2 mm margin of healthy tissue. The section width achieved by employing a harmonic scalpel was 1-2 mm. Thus, the combined margin did not exceed 5 mm

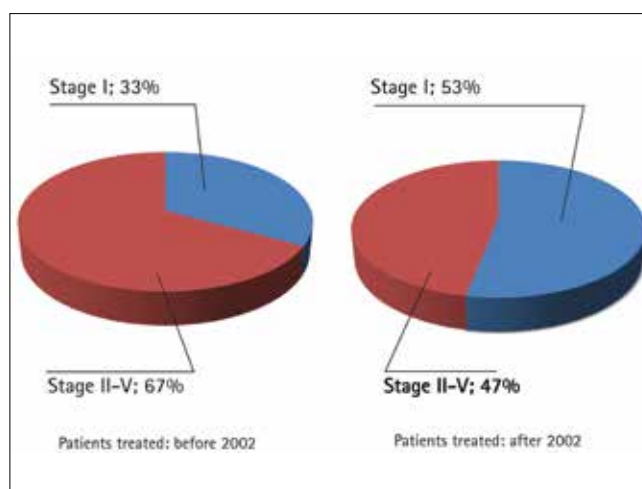
Regardless of the extent of tumor resection, all the children were operated on from the transperitoneal approach.

After completion of surgical treatment, the children received adjuvant chemotherapy depending on tumor histology and the therapeutic protocol employed at the time. None of the patients were treated by irradiation therapy.

### Statistical analysis

Statistical analyses were carried out using Statistica 8 (StatSoft Polska).

In case of quantitative variables, the results were presented as mean values, standard deviations, median values, and the first and third quartiles. Qualitative variables were described by an absolute number of cases in particular groups. To validate the hypotheses on correlations between qualitative variables, the authors used the chi-square test and the Fisher's exact test. The significance level for all analyses was  $p < 0.05$ . The results are presented in the form of figures and tables.



**Fig.2.** Percent of patients with stage I vs. patients with stage II-V treated before and after year 2002. m

## RESULTS

Within the 15-year period, 111 children with WT were treated; the group included 43 patients with stage I disease. Up to 2002, 79 children were managed, including 26 with stage I Wilms' tumor, and since 2003 – 32 patients, of whom 17 had stage I disease. Thus, in the first period, children with stage I WT constituted 33% of the total number of patients in that period, but in the second period, they accounted for as many as 53% of the patients in that period, and the difference is statistically significant (Fig. 2).

Stage I Wilms' tumors were somewhat more frequent in girls as compared to boys (F:M ratio of 26:17, ns), but there were no differences in the left versus right kidney involvement (21 : 22).

Radical nephrectomies were performed in three (6.98%) children, while NSS involved eight (18.6%), and simple nephrectomies – 32 (74.42%) children.

One child from the NSS group did not receive neoadjuvant chemotherapy. This 5-month old infant had bilateral duplicated pyelocalyceal systems and a solid-cystic mass in the upper pole of the left kidney. Primary surgical procedures were also performed in ten children from the simple nephrectomy group.

**Table 1a.** Patient's age at the time of diagnosis of Wilms' tumor with different surgery type groups (NSS – nephron-sparing surgery, SN – simple nephrectomy, RN – radical nephrectomy)

Type of surgery	Mean age (months)	Number of cases	Standard deviation	Q25	Median age (months)	Q75
NSS	37.875	8	44.4	9.0	21.50000	60.0
SN	29.86	32	33.05	7.0	18.50000	50.0
RN	60.0	3	31.75	36.0	48.00000	96.0
Total	33.45	43	35.3	7.0	19.0	52.0

**Table 1b.** Patient's age at the time of diagnosis of Wilms' tumor with different surgery type groups (without patients with metachronic tumors)

Type of surgery	Mean age (months)	Number of cases	Standard deviation	Q25	Median age (months)	Q75
NSS	14.5	6	9.22497	7.0	15.0	24.0
SN	29.86	32	33.05546	7.0	18.5	50.0
RN	60	3	31.74902	36.0	48.0	96.0
Total	29.82	41	31.8	7.0	19.0	48.0

Five of them were below 6-months of life, two presented with paraneoplastic symptoms associated with renin or erythropoietin release, in one child the parents refused their consent for chemotherapy, and two infants had ambiguous imaging results. All the children from the radical nephrectomy group received neoadjuvant chemotherapy.

The mean age at tumor diagnosis was 33.5 months (Table 1a). The group of NSS children included two patients after unilateral nephrectomies due to WT in whom, five and eight years following treatment completion, metachronic Wilms' tumors were detected in the remaining kidneys. These patients were older than the other children and for this reason they were excluded from calculations of age at the onset of disease for the entire group (Table 1b). As it clearly follows from Table 1b, the majority of nephron-sparing resections were performed in infants, while radical nephrectomies were predominantly performed in older children.

Table 2 illustrates tumor size at the time of diagnosis and after neoadjuvant chemotherapy in the NSS group according to resection type. The resected tumors were round or oval in shape; the last digit represents the height of the tumor in the kidney, which did not exceed 4-cm.

Intermediate-risk nephroblastomas predominated among all the resected tumors; in only one child, a high-risk Wilms' tumor was noted. Tumor histology for each type of surgical treatment is presented in Table 3. A remarkable observation involved radical nephrectomies performed in three children with clinically advanced-stage tumors, which responded poorly to neoadjuvant chemotherapy, but were found to be favorable in final histopathology.

Regardless of the type of resection, all the children have survived, none have relapsed, and the mean follow-up period after completion of oncological treatment is 73 months for the entire group of children with stage I disease (Table 4). One child from the NR group was reoperated due to early mechanical ileus of the gastrointestinal tract.

**Table 4.** Follow-up of Wilms' tumor patients with different type of surgery

Type of surgery	Mean (months)	Number of cases	Standard deviation	Q25	Median (months)	Q75
NSS	51.0	8	34.05	22.0	49.0	78.5
NS	84.37	32	42.69	57.5	77.0	110.0
NR	39.66	3	18.45	24.0	35.0	60.0
Total	75.0	43	42.6	46.0	68.0	99.0

**Table 2.** Tumor size before and after neoadjuvant chemotherapy in patients with nephron-sparing surgery and different resection type

Patient	Tumor size before treatment (cm)	Tumor size after chemotherapy (cm)	Resection type
1	4 x 3 x 5	2 x 3 x 3	atypical
2	6 x 4.5 x 5	3 x 2 x 2	heminephrectomy
3	5 x 5 x 5	–	heminephrectomy
4	6 x 6.5 x 7	5 x 3.5 x 4	atypical
5	7 x 7 x 8	5 x 5 x 4	polar
6	5 x 4 x 4	3 x 3 x 3	atypical
7	3 x 2 x 2.5	2 x 2 x 2	heminephrectomy
8	6 x 6 x 8	3.5 x 2.5 x 2	polar

**Table 3.** Number of patients with different type of surgery and histology risk

Type of surgery	Histology risk		
	Low	Intermediate	High
NSS	1	7	0
SN	11	20	1
RN	2	1	0
Total	14	28	1

## DISCUSSION

Therapeutic management of Wilms' tumors according to SIOP is a combined therapy consisting of neoadjuvant chemotherapy, radical nephrectomy, and adjuvant treatment entailing chemotherapy and radiotherapy. Particular elements of therapeutic management have strictly defined time frames, type and size of dose depending on stage of the disease and tumor histology. The SIOP 5 and 9 protocols have unambiguously established the type of and

benefits derived from neoadjuvant chemotherapy [7]. Subsequent research programs have concentrated predominantly on changes in the intensity of adjuvant therapy [8, 9]. These programs aim at selecting patients in whom adjuvant chemotherapy may be minimized, and such individuals in whom the treatment has to be intensified in order to increase the potential for a cure.

A significant element of oncological treatment in Wilms' tumor is its resection. Both the SIOP and NWTS programs recommend a management standard consisting in a radical nephrectomy with a selective lymphadenectomy. Lack of surgical radicalness is associated with intensification of adjuvant therapy and the risk of local recurrent disease. Thanks to randomized trials, our knowledge of the clinical course, differences in tumor cellular structure, genetic determinations, and neoadjuvant and adjuvant chemotherapies in Wilms' tumor has recently markedly increased. Progress in diagnostic imaging methods allows for a precise definition of the extent of the disease. Taking advantage of this body of knowledge, surgical treatment should also be minimized whenever possible or maximized in higher-risk tumors. As it follows from the presented material, regardless of the extent of tumor resection, therapeutic results for stage I Wilms' tumor are very good. All the presented children have survived and none have relapsed. Thus, which resection extent is appropriate for children with the same stage disease? From the viewpoint of a surgeon, what we lack is a simple definition of tumor size that would determine technical possibilities of resection. In renal cell carcinoma (RCC) the obligatory standard is the TNM classification, where T represents tumor size in centimeters [10]. No such value is given in nephroblastoma, and the terms "small tumor" or "large tumor" do not provide enough information for a precise selection of the extent of resection. All the descriptive determinations result anyway from tumor size and its location within the kidney [5, 11, 12, 13]. Based on the material collected by the authors and on data reported by others, small tumors may be defined as those with a diameter (or height in oval tumors) of up to 4-cm since at this tumor size a nephron-sparing resection may be safely performed [14]. The size is analogous as in the case of RCC tumors, which may be qualified for NSS, and their stage is classified as T1a [15, 16]. Tumor resection in nephroblastomas greater than 5-cm in diameter may be associated with lack of oncological radicalness or with leaving intact too small a volume of functional renal parenchyma in a child. We believe that the remaining tumors that meet the stage I criteria (hypothetical T1b stage) may be qualified for a simple nephrectomy, which is in accordance with the opinions of other authors [17, 18]. In the presented materials, three children had radical nephrectomies performed, with the decision based on tumor size and a poor response to neoadjuvant chemotherapy. In retrospective analysis, the treatment should be regarded as overly aggressive, especially in light of the fact that tumor histology indicated low or intermediate risk. Yet, the group was too small to draw any unequivocal conclusions. As it follows from investigations carried out by SIOP, tumor response to neoadjuvant therapy has a prognostic value since tumors with unfavorable histology frequently progress, while tumors of a low grade of malignancy are characterized by a weak response to treatment [19].

In the opinion of the present authors, the issue of appropriate qualification for surgical treatment will be intensified in the future, as an increasing number of children report for treatment with lower stage disease. Children with stage I Wilms' tumor treated up to 2002 accounted for 33% of the total number of patients, while in subsequent years, they constituted as many as 53%, thus representing the predominant stage. Improvement in pediatric care with readily available ultrasonography has increased the number of early-diagnosed tumors. This is true especially in infants, in whom

preservation of bilateral kidney function prevents hyperfiltration and protects them against potential renal failure in adult life [20].

## CONCLUSIONS

The authors believe that radical nephrectomy is an overly aggressive treatment modality in children with stage I Wilms' tumor. Performing a simple nephrectomy is sufficient and is possible in every case, and nephron-sparing surgery does not decrease the chance of a cure and may dramatically improve patients' quality of life in the future [21, 22]. To improve qualification for surgical treatment we propose the employment of NSS for stage Ia Wilms' tumors and SN for stage Ib Wilms' tumors.

## REFERENCES

1. Kaste SC, Dome JS, Babyn PS, et al: *Wilms tumour: prognostic factors, staging, therapy and late effects*. *Pediatr Radiol* 2008; 38: 2-17.
2. Davidoff AM, Giel DW, Jones DP, et al: *The feasibility and outcome of nephron-sparing surgery for children with bilateral Wilms' tumor*. *Cancer* 2008; 112: 2061-2070.
3. McNeil DE, Langer JC, Choyke P, DeBaun MR: *Feasibility of partial nephrectomy for Wilms tumor in children with Beckwith-Wiedemann Syndrome who have been screened with abdominal ultrasonography*. *J Pediatr Surg* 2002; 37: 57-60.
4. Ritchey ML: *Renal sparing surgery for Wilms' tumor*. *J Urol* 2005; 174: 1172-1173.
5. Ko EY, Ritchey ML: *Current management of Wilms' tumor in children*. *J Pediatr Urology* 2008; 20: 1-10.
6. Sawicz-Birkowska K, Baglaj M, Apoznanski W, et al: *Partial nephrectomy in management of unilateral Wilms' tumour – report of 10 cases*. *Pediatr Blood Cancer* 2005; 45: 385-386.
7. Tournade MF, Com-Nougue C, de Kraker J, et al: *Optimal duration of pre-operative chemotherapy in unilateral and nonmetastatic Wilms' tumor in children older than 6 months: results of the Ninth International Society of Pediatric Oncology Wilms' Tumor Trial and Study*. *J Clin Oncol* 2001; 19: 488-500.
8. Tournade MF, Com-Nougue C, Voute PA, et al: *Results of the Sixth International Society of Pediatric Oncology Wilms' Tumor Trial and Study: a risk-adapted therapeutic approach in Wilms' tumor*. *J Clin Oncol* 1993; 11: 1014-1023.
9. de Kraker J, Graf N, van Tinteren H, et al: *Reduction of postoperative chemotherapy in children with stage I intermediate-risk and anaplastic Wilms' tumor (SIOP 93-01 trial): a randomized controlled trial*. *Lancet* 2004; 364: 1229-1235.
10. Ng CS, Wood CG, Silverman PM, et al: *Renal cell carcinoma: diagnosis, staging and surveillance*. *AJR* 2008; 191: 1220-1232.
11. Urban CE, Lackner H, Schwinger W, et al: *Partial nephrectomy in well-responding stage I Wilms' tumors: report of three cases*. *Pediatr Hematol Oncol* 1995; 12: 143-152.
12. Haecker FM, Schweinitz D, Harms D, et al: *Partial nephrectomy for unilateral Wilms' tumor: results of Study SIOP 93- 01/ GPOH*. *J Urology* 2003; 170: 939- 944.
13. Moorman-Voestermans CG, Aronson DC, et al: *Is partial nephrectomy appropriate treatment for unilateral Wilms' tumor?* *J Pediatr Surg* 1998; 33 (2): 165-170.
14. Apoznanski W, Sawicz-Birkowska K, Baglaj M, et al: *Is nephron-sparing surgery in the treatment of unilateral Wilms' tumor justified?* *Adv Clin Exp Med* 2008; 17: 77-82.
15. Hirao Y, Fujimoto K, Yoshii M, et al: *Non-ischemic nephron-sparing surgery for small renal cell carcinoma: complete tumor enucleation using a micro-wave tissue coagulator*. *J Clin Oncol* 2002; 32: 95-102.
16. Bensalah K, Crepel M, Patard JJ: *Tumor size and nephron-sparing surgery: does it still matter?* *Eur Urology* 2008; 53: 691-693.

17. Zani A, Schiavetti A, Gambino M, et al: *Long-term outcome of nephron-sparing surgery and simple nephrectomy for unilateral localized Wilms' tumor.* J Urology 2005; 173: 946- 948.
18. Cozzi D A, Zani A: *Nephron-sparing surgery in children with primary renal tumor: Indications and results.* Sem Pediatr Surg 2006; 15: 3-9.
19. Qra I, van Tinteren H, Bergeron C, de Kraker J: *Progression of localised Wilms' tumour during preoperative chemotherapy is an independent prognostic factor: A report from SIOP 93-01 nephroblastoma trial and study.* Eur J Cancer 2007; 43: 131-136.
20. Cozzi F, Schiavetti A, Morini F, et al: *Renal function adaptation in children with unilateral renal tumors treated with nephron sparing surgery or nephrectomy.* J Urol 2005; 174: 1404-1408.
21. Thompson RH, Boorjian SA, Lohse CM, et al: *Radical nephrectomy for pT1a renal masses may be associated with decreased overall survival compared with partial nephrectomy.* J Urol 2006; 179: 468-473.
22. Clark A T, Breau RH, Morash C, et al: *Preservation of renal function following partial or radical nephrectomy using 24- hour creatinine clearance.* Eur Urology 2008; 54: 143-152.

#### Correspondence

Wiesław Urbanowicz  
Department of Pediatric Urology  
265, Wielicka Street  
30-665 Cracow, Poland  
phone : +48 12 658 20 11 int. 1590  
jansul@poczta.fm