

- BCR-ABL(IS) or log reduction from the baseline level? *Leuk Res* 2013;37:1035-40.
12. Druker BJ, Guilhot F, O'Brien SG, et al. Five-year follow-up of patients receiving imatinib for chronic myeloid leukemia. *N Engl J Med* 2006;355:2408-17.
 13. Fava C, Kantarjian H, Cortes J. Molecular resistance: an early indicator for treatment change? *Clin Lymphoma Myeloma Leuk* 2012;12:79-87.
 14. Stanoszek LM, Crawford EL, Blomquist TM, Warns JA, Willey PF, Willey JC. Quality control methods for optimal BCR-ABL1 clinical testing in human whole blood samples. *J Mol Diagn* 2013;15:391-400.
 15. Cross NC, White HE, Müller MC, Saglio G, Hochhaus A. Standardized definitions of molecular response in chronic myeloid leukemia. *Leukemia* 2012;26:2172-5.

A case of *Pneumocystis jiroveci* pneumonia after bendamustine-based chemotherapy for refractory diffuse large B-cell lymphoma

TO THE EDITOR: *Pneumocystis jiroveci* is a potential cause of virulent pneumonia in patients with impaired immunity, especially cell-mediated immunity. Increasing emphasis on prophylaxis using trimethoprim-sulfamethoxazole (TMP-SMX) has resulted in a decreasing incidence of *Pneumocystis jiroveci* pneumonia (PJP) in some diseases, such as human immunodeficiency virus (HIV) infection and lymphocytic leukemia. However, there are no standard guidelines for PJP prophylaxis in patients with other lymphoproliferative disorders. We report a case of PJP that occurred after a course of rituximab-bendamustine (RB) chemotherapy without TMP-SMX prophylaxis in a patient with refractory diffuse large B-cell lymphoma (DLBCL). We also review

the literature on PJP in connection with bendamustine-containing chemotherapy.

This patient was a 74-year-old man with DLBCL and a history of 8 cycles of R-CHOP (rituximab, cyclophosphamide, vincristine, doxorubicin, prednisolone) chemotherapy for stage IV DLBCL. Although he initially showed partial response to treatment, a significant proportion of lesions persisted after chemotherapy. Moreover, disease progression was noted 1 month after completion of first-line chemotherapy. Because the patient was deemed ineligible for high-dose chemotherapy, RB chemotherapy (rituximab 375 mg/m² on day 1 and bendamustine 90 mg/m² on days 2-3 q 28 days) was prescribed. After the first cycle of RB, the patient presented with fever. Chest radiography showed consolidation in both lung fields (Fig. 1A). A sequentially-performed chest computed tomography (CT) scan revealed ground-glass opacities in both lungs (Fig. 2). The white blood cell and absolute neutrophil counts were 3,820/μL and 1,940/μL, respectively. Lymphocyte fraction was 34%. The CD4 lymphocyte count was not assessed. Serum immunoglobulin (Ig) G level was 850 mg/dL (700-1,600). C-reactive protein level was 107.04 mg/L. The results of a respiratory viral study with nasal swab and serologic evaluation for mycoplasma and chlamydia were negative. Serum lactate dehydrogenase level was 911 IU/L. Arterial blood gas measurement on room air revealed hypoxemia (PaO₂: 45.5 mmHg).

Empirical treatment was initiated using piperacillin and tazobactam. Based on the clinical course and chest CT finding, TMP-SMX (15 mg/kg) was initiated to target a possible *Pneumocystis jiroveci* infection. Prednisolone (1 mg/kg) was added to treat hypoxia. The sputum polymerase chain reaction (PCR) test was positive for *Pneumocystis jiroveci*. Because of the patient's high oxygen demand and delirious mental status, we could not confirm the organism through broncho-alveolar lavage, but repeated sputum PCR tests were consistently positive for *Pneumocystis jiroveci*. After 10 days of TMP-SMX therapy, PCR testing showed negative conversion with radiologic improvement (Fig. 1B). However,

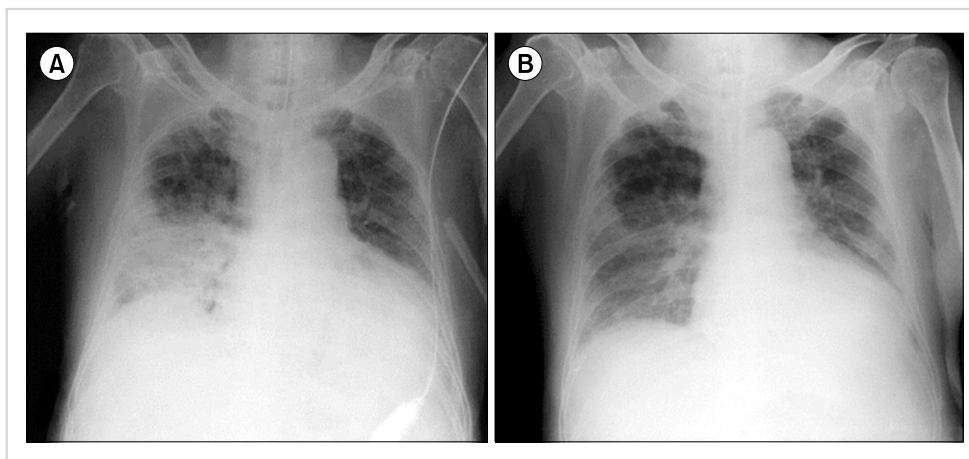


Fig. 1. A chest X-ray showed consolidation in right lower lung field (A). Followed-up chest X-ray which was performed 10 days after TMP-SMX treatment showed interval regression of consolidation in right lung field (B).

the patient's condition rapidly deteriorated after this transient improvement. Eventually, the patient died despite intensive treatment.

PJP is one of the most serious opportunistic infections among immunocompromised patients with lymphoproliferative disorders. In particular, long-term use of corticosteroids or chemotherapy with fludarabine has been recognized as a risk factor for PJP based on clinical experience and data from clinical studies [1]. Therefore, for patients with the aforementioned risk factors, prophylaxis with TMP-SMX is recommended. However, in the case of DLBCL patients treated with R-CHOP chemotherapy, prophylaxis with TMP-SMX is not routinely used. Generally, prophylaxis is recommended in immunocompromised adult pa-

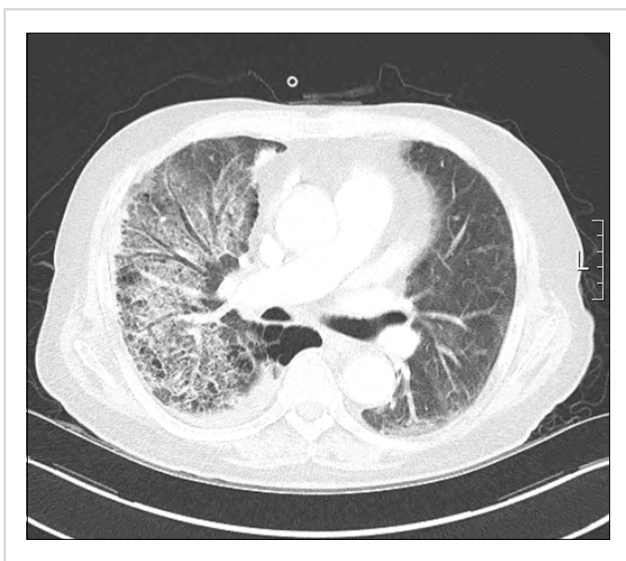


Fig. 2. A chest computed tomography (CT) scan revealed newly noted diffuse and multifocal patchy ground glass opacity and consolidation in both lungs (right side predominant).

tients without HIV when the risk of PJP is greater than 3.5% [2]. However, according to a few reports, the incidence of PJP after rituximab-based chemotherapy in DLBCL patients was just 2-3% [3]. Some studies, however, have reported a significantly increased incidence (6-13%) of PJP during dose-dense R-CHOP (q 14 days), but it is believed that this increased incidence is due to dose-dense steroids rather than the cytotoxic agents in the R-CHOP regimen. Consequently, there is no consensus about the necessity of routine prophylaxis with TMP-SMX in DLBCL patients treated with R-CHOP.

According to the National Comprehensive Cancer Network guidelines, RB chemotherapy is recommended for patients with relapsed/refractory DLBCL but who are not eligible for high-dose chemotherapy. Bendamustine is a unique alkylating agent with anti-metabolic activity and a favorable toxicity profile and is effective in a wide range of lymphoproliferative disorders. However, there have been no large-scale analyses of PJP and bendamustine-containing chemotherapy. According to one review, PJP was identified in only 2 (1.1%) of 176 patients [4]. Most subsequent trials of RB in lymphoma patients did not specify the incidence of PJP in the safety profile, although a few studies described pneumonia as a significant complication [5]. Given that a diagnosis of PJP may be difficult to make, it is possible that the actual incidence is under-estimated.

In practice, a few case studies have reported PJP during bendamustine-containing chemotherapy (Table 1). In 2 of the cases, the low absolute lymphocyte or low CD4 counts of the host were underlined. Ito *et al.* [10] noted that CD4+ cell count decreased significantly while serum Ig level showed modest change in patients with relapsed or refractory low grade B-cell lymphoma during RB chemotherapy. Based on these results, the authors concluded that RB therapy was related to impaired cell-mediated immunity, leading to an increased risk of intracellular organism infections including *Pneumocystis jiroveci*. Some physicians

Table 1. Clinical characteristics of 5 cases of *Pneumocystis jiroveci* pneumonia during bendamustine-containing chemotherapy.

	Case [6]	Case [7]	Case [8]	Case [9]	Present case
Age/Gender	48/F	75/M	47/F	89/F	74/M
Diagnosis	Breast cancer	Marginal zone lymphoma	Breast cancer	DLBCL	DLBCL
Treatment before bendamustine	Heavily pre-treated	No	Unavailable	R-COP, 2 cycles	R-CHOP, 8 cycles
Bendamustine-containing protocol	Bendamustine (150 mg/m ² for 2 d q 4 wk)	Rituximab (375 mg/m ²) + bendamustine (90 mg/m ² for 2 d) q 4 wk	Bendamustine (100-120 mg/m ²) + erlotinib (150 mg)	Bendamustine (120 mg/m ² for 2 d q 4 wk)	Rituximab (375 mg/m ²) + bendamustine (90 mg/m ² for 2 d) q 4 wk
WBC	-	-	-	4,800	3,820
Lymphocyte (%) or ALC	-	-	<100/μL	4%	34%
CD4 T-cell count	<200/μL	-	14	74	-
Anti-PJP therapy	TMP-SMX, steroids	TMP-SMX	TMP-SMX	-	TMP-SMX, steroids
Outcomes	Death	Resolved	Death	Death	Death

Abbreviations: DLBCL, Diffuse large B-cell lymphoma; TMP-SMX, trimethoprim-sulfamethoxazole; R-COP, rituximab, cyclophosphamide, vincristine, prednisolone; R-CHOP, rituximab, cyclophosphamide, adriamycin, vincristine, prednisolone; ALC, absolute lymphocyte count; PJP, *Pneumocystis jiroveci* pneumonia.

have suggested monitoring lymphocyte or CD4 counts for patients receiving bendamustine. For example, Brugger and Ghielmini [11] recommend bimonthly monitoring of CD4-helper T-cell counts during bendamustine-containing chemotherapy and initiation of PJP prophylaxis for patients with counts of $<200/\mu\text{L}$. When deciding whether to employ prophylactic treatment, it is also important to consider concomitant drugs, patient age, underlying diseases, and previous chemotherapy history.

As bendamustine is increasingly used in lymphoma patients, physicians should be aware of its potentially serious infectious complications. Considering the fatality rate of PJP, prophylaxis and monitoring for PJP are required for patients on bendamustine chemotherapy who are elderly, heavily pre-treated, or currently in a refractory/relapsed status.

**Jeonghoon Ha, Yunhwa Jung, Yunduk Jung,
Sanbin Lee, Yoonseo Lee, Insook Woo**

Division of Hematology-Oncology, Department of Internal Medicine, Yeouido St Mary's Hospital, The Catholic University of Korea, College of Medicine, Seoul, Korea

Correspondence to: Jeonghoon Ha

*Division of Hematology-Oncology, Department of Internal Medicine, Yeouido St Mary's Hospital, 10, 63-ro, Yeongdeungpo-gu, Seoul 07345, Korea
E-mail: hajhoon@catholic.ac.kr*

Received on Feb. 17, 2015; Revised on Mar. 27, 2015; Accepted on Apr. 20, 2015

<http://dx.doi.org/10.5045/br.2016.51.1.61>

Authors' Disclosures of Potential Conflicts of Interest

No potential conflicts of interest relevant to this article were reported.

REFERENCES

- Obeid KM, Aguilar J, Szpunar S, et al. Risk factors for Pneumocystis jirovecii pneumonia in patients with lymphoproliferative disorders. *Clin Lymphoma Myeloma Leuk* 2012;12:66-9.
- Green H, Paul M, Vidal L, Leibovici L. Prophylaxis of Pneumocystis pneumonia in immunocompromised non-HIV-infected patients: systematic review and meta-analysis of randomized controlled trials. *Mayo Clin Proc* 2007;82:1052-9.
- Kurokawa T, Kaya H, Yoshida T. Two cases of Pneumocystis jirovecii pneumonia with non-Hodgkin's lymphoma after CHOP-based chemotherapy containing rituximab. *J Clin Exp Hematol* 2010;50:159-62.
- Cheson BD, Friedberg JW, Kahl BS, Van der Jagt RH, Tremmel L. Bendamustine produces durable responses with an acceptable safety profile in patients with rituximab-refractory indolent non-Hodgkin lymphoma. *Clin Lymphoma Myeloma Leuk* 2010;10:452-7.
- Kahl BS, Bartlett NL, Leonard JP, et al. Bendamustine is effective therapy in patients with rituximab-refractory, indolent B-cell non-Hodgkin lymphoma: results from a Multicenter Study. *Cancer* 2010;116:106-14.
- Klippstein A, Schneider CP, Sayer HG, Höffken K. Pneumocystis carinii pneumonia as a complication of bendamustine monotherapy in a patient with advanced progressive breast cancer. *J Cancer Res Clin Oncol* 2003;129:316-9.
- Carter SJ, Bernstein SH, Friedberg JW, Barr PM. Pneumocystis jirovecii pneumonia as a complication of bendamustine in a patient receiving bendamustine plus rituximab for marginal zone lymphoma. *Leuk Res* 2011;35:e223-4.
- Reinbolt RE, Alam S, Layman R, Shapiro C, Lustberg M. Pneumocystis jirovecii pneumonia in an atypical Host. *Clin Breast Cancer* 2012;12:138-41.
- Hosoda T, Yokoyama A, Yoneda M, et al. Bendamustine can severely impair T-cell immunity against cytomegalovirus. *Leuk Lymphoma* 2013;54:1327-8.
- Ito K, Okamoto M, Ando M, et al. Influence of rituximab plus bendamustine chemotherapy on the immune system in patients with refractory or relapsed follicular lymphoma and mantle cell lymphoma. *Leuk Lymphoma* 2015;56:1123-5.
- Brugger W, Ghielmini M. Bendamustine in indolent non-Hodgkin's lymphoma: a practice guide for patient management. *Oncologist* 2013;18:954-64.

Oligosecretory multiple myeloma: a case report

TO THE EDITOR: Approximately 95–97% of myelomas are of the secretory type, i.e., they exhibit monoclonal (M) band in the γ region on either urine or serum protein electrophoresis [1, 2]. Non-secretory myelomas were first described in 1958 by Serre, and they constitute 1–5% of myelomas. These do not show M band on serum or urine immunofixation electrophoresis. However, on immunohistochemistry (IHC), 85% of non-secretory myelomas stain for cytoplasmic M protein, indicating immunoglobulin synthesis. The remaining 15% are non-producers. The proposed pathophysiology for non-secretory multiple myeloma includes diminished immunoglobulin synthesis, secretion defects, and rapid immunoglobulin degradation, either intracellularly or extracellularly [3]. With newer serum free light chain (FLC) assays, approximately three-fourths of these non-secretory myelomas were found to have elevated FLC levels and/or abnormal FLC ratios [4]. These cases may be considered to be minimally secretory, hyposecretory, or oligosecretory. Since these patients do not present with classical multiple myeloma symptoms, diagnoses may be delayed. We hereby present a case of non-secretory myeloma with increased kappa (κ) FLC levels, i.e., an oligosecretory myeloma. The rare and unique clinical presentation of this case prompted us to report this case. We also discuss the diagnostic and