



Case Report

Giant sacral aneurysmal bone cyst treated with endovascular embolization

Samuel Sequeira Lemos¹, Diogo Belo¹, Filipe Veloso Gomes²

¹Department of Neurosurgery, Hospital Santa Maria, Centro Hospitalar Lisboa Norte, ²Radiology Unit, Centro Hospitalar Lisboa Central, Lisboa, Portugal.

E-mail: *Samuel Sequeira Lemos - samuelemos@gmail.com; Diogo Belo - belo.diogo@gmail.com; Filipe Veloso Gomes - fvgomes@gmail.com



*Corresponding author:

Samuel Sequeira Lemos,
Department of Neurosurgery,
Hospital Santa Maria, Lisboa,
Portugal.

samuelemos@gmail.com

Received: 15 August 2023

Accepted: 16 September 2023

Published: 20 October 2023

DOI

10.25259/SNI_685_2023

Quick Response Code:



ABSTRACT

Background: Spine aneurysmal bone cysts (SABC) are osteolytic tumor-like lesions with cystic, blood-filled cavities that represent 15% of all primary spinal bone tumors. The sacrum is a rare site for SABC, and sacral lesions typically carry higher morbidity rates. Here, a 19-year-old female with a large primary multisegmental sacral SABC was successfully managed with 2-staged endovascular embolization.

Case Description: A 19-year-old female presented with progressive worsening of axial lumbosacral pain, and a left L5/S1 radiculopathy. The lumbosacral computed tomography and magnetic resonance studies showed a large (10 cm [AP] × 11 cm [Tr] × 12 cm [CC]) heterogeneous, osteolytic lesion containing multiple fluid-fluid levels. The biopsy confirmed the diagnosis of a primary SABC. She was treated with a 2-staged endovascular embolization that resolved her pain. This was followed by radiographic confirmation of occlusion of the SABC.

Conclusion: A 19-year-old female presented with an atypical SABC that was successfully managed with 2-staged endovascular embolization.

Keywords: Embolization, Endovascular treatment, Sacral aneurysmal bone cyst, Spine

INTRODUCTION

Most spine aneurysmal bone cysts (SABC) occur in patients under 20 years of age. They typically present with focal pain and neurological deficits reflecting their locations. SABC represent 15% of all primary bone spine tumors, and only rarely involve the sacrum (i.e., 3%).^[8] Computed tomography (CT)/magnetic resonance (MR) studies typically document multiple cyst-fluid levels within the posterior elements or vertebral body at a single spinal level. However, sacral lesions are often multisegmental and extend into the sacral canal. Their treatment, consisting variably of biopsy, curettage, excision, embolization, and/or denosumab, is more problematic.^[1,5,7-11,13] Here, a 19-year-old female following MR/CT studies and a biopsy-proven sacral SABC was successfully treated with 2-staged endovascular embolization.

CASE DESCRIPTION

A 19-year-old female presented 6 months of worsening, nocturnal, lumbosacral and left-sided L5/S1 pain, and weakness. The CT scan showed an extensive (i.e., 10 cm [AP] × 11 cm [Tr] × 12 cm [CC]) heterogeneous lytic lesion containing multiple cysts with fluid levels in the sacrum

This is an open-access article distributed under the terms of the Creative Commons Attribution-Non Commercial-Share Alike 4.0 License, which allows others to remix, transform, and build upon the work non-commercially, as long as the author is credited and the new creations are licensed under the identical terms.

©2023 Published by Scientific Scholar on behalf of Surgical Neurology International

with attendant cortical destruction and invasion of the sacral canal. The lesion extended anteriorly to the sacrum into the pelvic cavity (i.e., with ill-defined borders), laterally into the iliac bones, superiorly into the L5 vertebral body, and inferiorly into S4 [Figures 1a-c]. On MR imaging (MRI), the inhomogeneous cysts were filled with moderate/high signal intensities (i.e., fluid levels on T1/T2 images), separated by multiple septae [Figure 1d].

Biopsy and pathology

Percutaneous biopsies performed at multiple lesion locations yielded the diagnosis of a primary SABC (i.e., typical histological pattern for ABC and with no precursor lesion identified).

Two-Stage endovascular embolization

Digital subtraction angiography of the infrarenal aorta identified feeders from the posterior rami of both internal

iliac arteries, (i.e., mainly from the left) [Figure 2]. The first endovascular embolization included; (1) arteriography of the left internal iliac artery with super-selective catheterization of 2 rami, (2) followed by infusion of 500 μm polyvinyl alcohol (PVA) particles. The patient's axial/radicular pain dramatically improved enabling her to ambulate and undergo physiotherapy. Although the 6-week post-embolization contrast CT showed signs of healing (i.e., partial peripheral ossification without lesion growth), we elected to perform a 2nd endovascular embolization that included; (1) microcatheterization of feeders from the posterior rami of both internal iliac arteries and (2) followed by embolization with 355–500 μm PVA particles. Each treatment required 2 days of hospitalization. She sustained no complications from either procedure.

Postoperative course

Postoperatively, although the left-sided L5/S1 motor deficit remained, the patient's pain significantly improved. Multiple

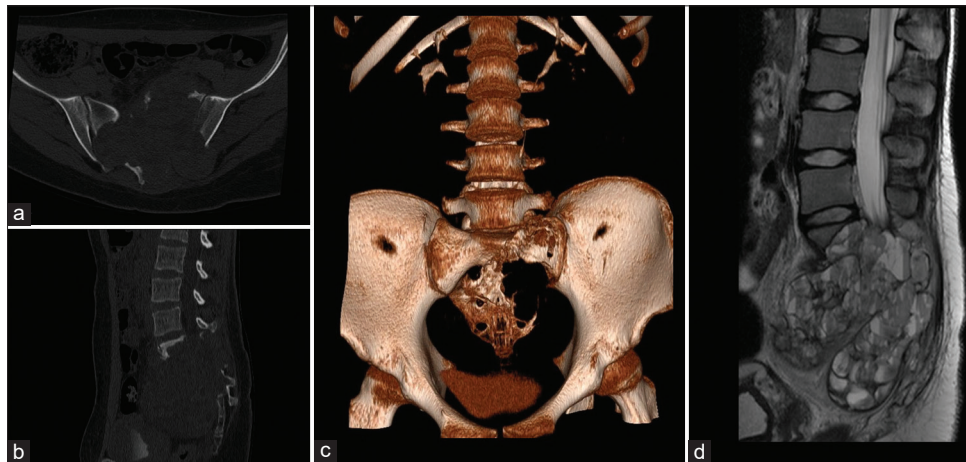


Figure 1: (a) Computed tomography (CT) axial view, (b) sagittal view, and (c) 3D reconstruction showing an extensive sacral lytic lesion extending to the iliac bones. (d) T2 magnetic resonance imaging (MRI) sagittal view showing multiple cystic cavities with fluid levels extending into the sacral canal and peritoneal cavity.

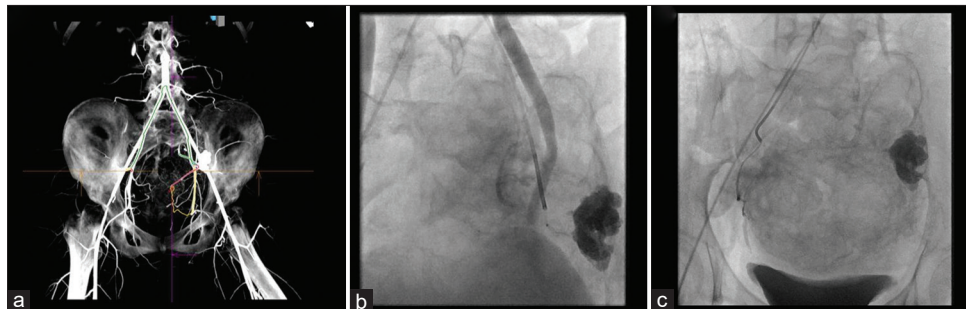


Figure 2: (a) Intra-Arterial computerized tomography (CT) with 3D reconstruction identifying culprit arterial branches. (b) Digital subtraction angiography (DSA) showing catheter and microcatheter tip with stasis in one of the arterial branches. Gross calcification of the aneurysmal bone cysts (ABC) is seen on the left. (c) DSA showing a branch from the right internal iliac artery which was super selectively catheterized and embolized with polyvinyl alcohol particles (PVA) particles.

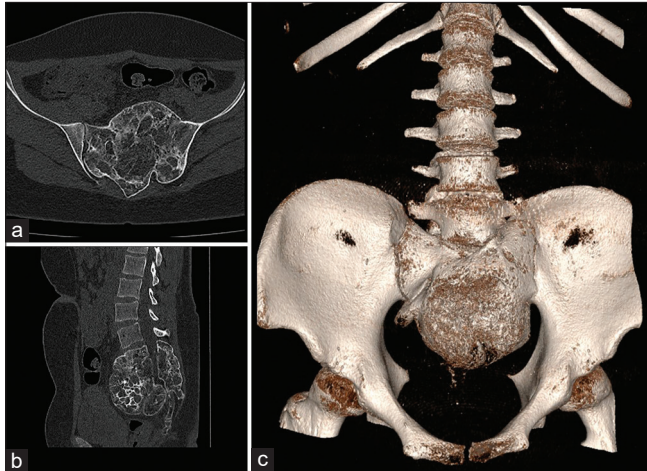


Figure 3: (a) Non-contrast computerized tomography (CT) axial view, (b) sagittal view and, (c) 3D reconstruction at 24 months post treatment showing signs of healing (ie bone formation within the aneurysmal bone cysts (ABC) and peripheral sclerotic bony changes).

follow-up CT exams obtained up to 2 years later showed progressive healing, (i.e., bone formation within the ABC and peripheral sclerotic bony changes) [Figure 3].

DISCUSSION

Here, a 19-year-old female demonstrated L5/S1 pain, and motor deficits attributed to a sacral SABC (i.e., L5–S4 with a total volume of 680 cm³). This SABC extended into the iliac bones, sacral canal, and peritoneal cavity (i.e., Enneking type 3 lesion with an aggressive invasion of adjacent tissues).^[4] Our literature review yielded 7 retrospective series and 5 case reports of sacral SABC; these lesions are often multisegmental and can grow to impressive dimensions thus resulting in significant neurological deficits (i.e., myeloradiculopathy/paraparesis with sphincter dysfunction) [Tables 1 and 2].

Increase in endovascular arterial embolization of sacral ABC to limit morbidity of surgery

The large extent of SABC, associated with increased perioperative morbidity (i.e., risks of gross total *en bloc* excision or curettage resulting in life-threatening intraoperative bleeding, and/or significant neurologic deficits) has prompted greater interest in alternative treatment with endovascular arterial embolization. We identified 14 sacral ABC cases from the literature that were successfully treated with SAE (i.e., spinal arterial embolization) performed in 1–3 stages; the most significant improvement usually occurred within the first few days following the first embolization stage.^[2,3,6,12] In our SABC case, to minimize the risk associated with surgery, we performed a 2-staged endovascular embolization procedure. Although a significant positive clinical response

Table 1: Case reports on sacral ABCs.

Case	Reference	Age (years)	Clinical presentation	Duration of symptoms (months)	Location	Volume (cm ³)/ Dimensions (d1*d2*d3)	Treatment	Complications	Recurrence	Follow-up time (years)
1	Pomonis et al., 1996 ^[11]	17	Sac P, Rad P, BB Dysf	3	S1-S3	NA	SAE+Surgery	No	NA	NA
2	Pogoda et al., 2003 ^[10]	17	Abdominal mass, Paresis	1	L5-S2	1406* (16x12x14)	SAE+Surgery	Over-bleeding	No	3
3	Han et al., 2009 ^[5]	22	Sac P	12	S1-S5	250* (8.2x7.4x7.8)	SAE+Surgery	No	No	NA
4	Doss et al., 2014 ^[3]	16	Sac P, Rad P	4	S3-S4	NA	SAE	No	No	1.5
5	Pelle et al., 2014 ^[9]	5	Sac P, BB Dysf	12	L4-S3	150* (76*51*74)	Denosumab	No	NA	NA
6	Present case	19	Sac P, Rad P, Paresis	9	L5-S4	680 (12*11*10)	SAE	No	No	2

*When volume not reported it was calculated with the ellipsoid formula (Volume=R1xR2xR3xπx4/3). NA: Non-applicable, SAE: Selective arterial embolization, Sac: Sacral, Rad: Radicular, P: Pain, W: Weakness, BB: Bladder/Bowel, DysF: Dysfunction, d: Diameter/axis, ABC: Aneurysmal bone cysts

Table 2: Cases on sacral ABCs reported on retrospective series.

Case Series	Reference	Number of sacral cases	Clinical presentation	Duration of symptoms (mos)	Location	Size/Volume	Treatment	Complication	Recurrence	Follow-up
1	Cristofaro <i>et al.</i> , 1992 ^[2]	2 cases	NA	NA	NA	NA	SAE (n=2)	No	No	6 and 16 mos
2	De Kleuver <i>et al.</i> , 1998 ^[7]	4 cases	Rad signs (n=4)	Mean: 10 Range: (3–18)	US (n=2) MS (n=2)	NA	CUR (n=4)	PreSac plexus lesion	No	Mean: 5.4 Range: (1.5–12) years
3	Papagelopoulos <i>et al.</i> , 2001 ^[8]	12 cases	Sac P (n=12) Rad P (n=3) Paresis (n=2) BB DysF (n=3)	Mean: 7	Often MS encasement NS (n=6)	NA	CUR (n=12) Pre SAE (n=1) Adj. RT (n=2)	Sciatic neuropathy; Sac osteomyelitis; small bowel obstruction/ adhesion	NA	NA
4	Brastianos <i>et al.</i> , 2009 ^[1]	10 cases	Sacral P (n=10) Rad P (n=3) Paresis (n=2) BB DysF (n=4)	NA	NA	NA	RES on caudal SacABC (n=5) CUR on cranial SacABC (n=5) pre-SAE (n=4)	BB DysF after SAE+CUR	Recurrence (n=4)	Mean: 3 Range: (2–12) years
5	Rossi <i>et al.</i> , 2013 ^[12]	5 cases	NA	NA	NA	d<5 cm (w2); d>5 cm (n=5)	SAE (n=5)	NA	No	Range: (0.9–5) years
6	Zileli <i>et al.</i> , 2013 ^[13]	6 cases	Sac P (n=6) Rad P (n=4) Paresis (n=3)	Mean: 10.6 Range: (1–24)	NA	NA	ST RES (n=3) Total RES (n=3)	Over-bleeding (n=2)	“Alive with disease” (n=3)	Mean: 7.4 Range: (4–12) years
7	Henrichs <i>et al.</i> , 2016 ^[6]	6 cases	Sacral P (n=5) Rad P (n=2) Paresis (n=1) BB DysF (n=1)	NA	All MS	Mean: 145.5 cm ³ Range: (25.34–365.20 cm ³)	SAE (n=6)	Worsen sciatica →Surgery	No	Mean: 3 Range (1.1–4.7) years

Most are retrospective series with mixed cases with other locations included. NA: Non-applicable, SAE: Selective arterial embolization, US: Unisegmental, MS: Multisegmental, RES: Resection, Rad: Radicular, P: Pain, Sac: Sacral, BB: Bladder/Bowel, DysF: Dysfunction, Mos: Months, CUR: Curettage, NS: Neural structures, d: Diameter/axis, Pre SAE: Preoperative SAE, ST: Subtotal, SacABC: Sacral aneurysmal bone cyst, Adj.: Adjuvant, RT: Radiotherapy, n: Number of patients

was obtained after the first procedure, we chose to perform second SAE 6 weeks later. Notably, the patient continued to neurologically improve over the next 2 years, whereas the postoperative contrast CT studies confirmed progressive healing of the SABC lesion.

CONCLUSION

We successfully treated a 19-year-old female's large multisegmental sacral ABC with 2-staged endovascular embolization.

Declaration of patient consent

Patient's consent not required as patient's identity is not disclosed or compromised.

Financial support and sponsorship

Nil.

Conflicts of interest

There are no conflicts of interest.

Use of artificial intelligence (AI)-assisted technology for manuscript preparation

The author(s) confirms that there was no use of artificial intelligence (AI)-assisted technology for assisting in the writing or editing of the manuscript and no images were manipulated using AI.

REFERENCES

1. Brastianos P, Gokaslan Z, McCarthy EF. Aneurysmal bone cysts of the sacrum: A report of ten cases and review of the literature. *Iowa Orthop J* 2009;29:74-8.
2. De Cristofaro R, Biagini R, Boriani S, Ricci S, Ruggieri P,

- Rossi G, *et al.* Selective arterial embolization in the treatment of aneurysmal bone cyst and angioma of bone. *Skeletal Radiol* 1992;21:523-7.
3. Doss VT, Weaver J, Didier S, Arthur AS. Serial endovascular embolization as stand-alone treatment of a sacral aneurysmal bone cyst. *J Neurosurg Spine* 2014;20:234-8.
4. Enneking WF. A system of staging musculoskeletal neoplasms. *Clin Orthop Relat Res* 1986;204:9-24.
5. Han HJ, Lee SG, Park CW, Yoo CJ, Kim WK. Huge aneurysmal bone cyst of the sacrum. *Korean J Spine* 2009;1:35-9.
6. Henrichs MP, Beck L, Gosheger G, Streitbueger A, Koehler M, Heindel W, *et al.* Selective arterial embolisation of aneurysmal bone cysts of the sacrum: A promising alternative to surgery. *Fortschr Röntgenstr* 2016;188:53-9.
7. Kleuver M, van der Heul RO, Veraart BE. Aneurysmal bone cyst of the spine. *J Pediatr Orthop B* 1998;7:286-92.
8. Papagelopoulos PJ, Choudhury SN, Frassica FJ, Bond JR, Unni KK, Sim FH. Treatment of aneurysmal bone cysts of the pelvis and sacrum. *J Bone Joint Surg Am* 2001;83:1674-81.
9. Pelle DW, Ringler JW, Peacock JD, Kampfschulte K, Scholten DJ 2nd, Davis MM, *et al.* Targeting receptor-activator of nuclear kappaB ligand in aneurysmal bone cysts: Verification of target and therapeutic response. *Transl Res* 2014;164:139-48.
10. Pogoda P, Linhart W, Priemel M, Rueger JM, Amling M. Aneurysmal bone cysts of the sacrum. Clinical report and review of the literature. *Arch Orthop Trauma Surg* 2003;123:247-51.
11. Pomonis S, Machera M, Sakellariadis N, Grammenou M, Anagnostopoulos D, Kelekis D. Giant aneurysmal bone cyst of the sacrum. *Neuroradiol J* 1996;9:619-22.
12. Rossi G, Rimondi E, Bartalena T, Gerardi A, Alberghini M, Staals EL, *et al.* Selective arterial embolization of 36 aneurysmal bone cysts of the skeleton with N-2-butyl cyanoacrylate. *Skeletal Radiol* 2009;39:161-7.
13. Zileli M, Isik HS, Ogut FE, Is M, Cagli S, Calli C. Aneurysmal bone cysts of the spine. *Eur Spine J* 2013;22:593-601.

How to cite this article: Lemos SS, Belo D, Gomes FV. Giant sacral aneurysmal bone cyst treated with endovascular embolization. *Surg Neurol Int* 2023;14:373.

Disclaimer

The views and opinions expressed in this article are those of the authors and do not necessarily reflect the official policy or position of the Journal or its management. The information contained in this article should not be considered to be medical advice; patients should consult their own physicians for advice as to their specific medical needs.