

Case Report

Five years follow-up of implant-prosthetic rehabilitation on a patient after mandibular ameloblastoma removal and ridge reconstruction by fibula graft and bone distraction

Giacomo Oteri¹, Francesco Saverio De Ponte², Michele Pisano¹, Marco Cicciù³

¹Departments of Odontostomatology, ²Maxillofacial Surgery and ³Human Pathology, University of Messina, ME, Italy

ABSTRACT

This case report presents a combination of surgical and prosthetic solutions applied to a case of oral implant rehabilitation in post-oncologic reconstructed mandible. Bone resection due to surgical treatment of large mandibular neoplasm can cause long-span defects. Currently, mandibular fibula free flap graft is widely considered as a reliable technique for restoring this kind of defect. It restores the continuity of removed segment and re-establishes the contour of the lower jaw. However, the limited height of grafted fibula does not allow the insertion of regular length implants, therefore favouring vertical distraction osteogenesis as an important treatment choice. This report presents a patient affected by extensive mandibular ameloblastoma who underwent surgical reconstruction by fibula free flap because of partial mandibular resection. Guided distraction osteoneogenesis technique was applied to grafted bone, in order to obtain adequate bone height and to realize a prosthetically guided placement of 8 fixtures. After osseointegration, the patient was rehabilitated with a full arch, screw-retained prosthetic restoration. At five-years follow up, excellent integration of grafted tissue, steady levels of bone around the fixtures and healthy peri-implant tissues were reported.

Key Words: Ameloblastoma, dental implants, distraction, osteogenesis

Received: November 2011
Accepted: February 2012

Address for correspondence:
Dr. Marco Cicciù,
Department of Oral Surgery
and Odontostomatology,
Messina University School
of Dentistry, Via Consolare
Valeria, 98100 Messina, Italy.
E-mail: acromarco@yahoo.it

INTRODUCTION

Mandibular ameloblastoma is a rare, benign neoplasm of odontogenic epithelium described for the first time by Broca (1868) as adamantinoma, and then re-coined by Churchill (1934). Ameloblastoma accounts for about 1% of all tumors of the jaw, and it is mainly encountered during three to five decades of life.^[1] Histologically, it is of six types: Follicular, plexiform, granular, basal, desmoplastic and acanthomatous.^[2] Many benign lesions cause mandibular swellings, and these can be divided into those of odontogenic

and nonodontogenic origin. Lesions include ameloblastoma, radicular cyst, dentigerous cyst, keratocystic odontogenic tumor, central giant cell granuloma, fibro-osseous lesions and osteomas.^[3] The most common tumor of odontogenic origin is ameloblastoma, which develops from epithelial cellular elements and dental tissues in their various phases of development. It is a slow-growing, persistent, and locally aggressive neoplasm of epithelial origin. Its peak incidence is in the third to fourth decades of life and has an equal sex distribution. It is often associated with an unerupted third molar.^[4] It may be detected during the course of routine radiography.

The maxillary mandibular ratio of ameloblastoma is 5 to 1, in favor for the mandible. Its most common site of occurrence is the mandibular molar region. More than 50% of recurrence appears within the first 5 years after primary surgery. Even though ameloblastomas are well studied and documented, little is known about

Access this article online



Website: www.drj.ir

their malignant features.^[5,6] Leading clinical symptoms such as painless swelling and slow growth are non-characteristic. Ameloblastomas of the mandible occur 12 years earlier than those of the maxilla. Ameloblastomas occur most frequently in the molar region of the mandible. In Blacks, ameloblastomas occur more frequently in the anterior region of the jaws. Radiologically, 50% of ameloblastomas appear as multilocular radiolucent lesions with sharp delineation. Histologically, one-third are plexiform, one-third follicular; other variants such as acanthomatous ameloblastoma occur in older patients.^[7-9]

The vast majority of ameloblastomas arise in the mandible, and the majority of these are found in the angle and ramus region. There are three forms of ameloblastomas, namely multicystic, peripheral, and unicystic tumors.^[10] Multicystic ameloblastoma is the most common variety and represents 86% of cases. Peripheral tumors are odontogenic tumors, with the histological characteristics of intraosseous ameloblastoma that occur solely in the soft tissues covering the tooth-bearing parts of the jaws. Unicystic tumors include those that have been variously referred to as mural ameloblastomas, luminal ameloblastomas, and ameloblastomas arising in dentigerous cysts.^[11] The goal of treatment of ameloblastoma is to achieve complete excision and appropriate reconstruction. Surgeons have adopted different techniques for autogenous grafting including “free flaps” with microvascular anastomosis during the recent years. Microsurgical transfers of free bone grafts can reconstruct mandible defects with an immediate source of blood supply to the graft. The free vascularized fibula flap is considered as the treatment of choice in mandibular reconstruction for extensive bone defects resulting from trauma, infection or tumor resections.^[12] Since 1989, when Hidalgo first used the free vascularized fibula flap as a new method for reconstruction of the mandible, it has become an effective and safe procedure, giving excellent results both functionally and esthetically.^[13] The fibula flap presents many advantages such as good length, constant geometry, proper dimensions for implant placement, double periosteal and medullary blood supply allowing multiple osteotomies, correct contouring, an adequate pedicle length even if it is underlined a donor site morbidity. Bone thickness, height and its bi-cortical structure seems to be ideal for long-term implant prosthetic rehabilitation.^[14,15] However, because of its limited height compared with the height of the

mandible, vertical distance between the reconstructed segment and the occlusal plane can be considerable. This could be a particular problem in the dentate mandible, especially when rehabilitation with dental implants is contemplated. Insufficient bone height leads to overloading of osseointegrated implants and may influence the long-term success of the prosthetic restoration.^[16-18] Distraction osteogenesis is performed in cases of vertical resorption of edentulous jaws to improve bone volume for dental implant placement. This technique provides a very good quality of the new-formed bone, with adequate characteristics for implant osseointegration.^[18] The different steps of the surgical and prosthetic procedures are reported here.

CASE REPORT

A 66-year-old female was referred by another center to the author for management of a large swelling in the anterior mandibular area. The first clinical investigation showed a large tissue mass and extension of the lesion, and a more ominous growth was suspected. OPT radiographic investigation underlined a picture of soap-bubble shape endosseous mandibular lesion. Intra-operative biopsy revealed histo-pathologic features of ameloblastoma. Surgical team decided for a segmental mandibulectomy from third right molar to second left premolar area and for a simultaneous fibula free flap reconstruction of the defect. Gilbert technique was the approach chosen for shin operation. The bone segment taken was osteotomized in order to re-establish the contour of the mandible. Terminal anastomosis between fibular vessels and cervical ones was performed micro-surgically [Figures 1-8].

Fibula graft was finally fixed to the mandibular bone by osteosynthesis metallic plates and screws. The latter was removed four months later. Despite uneventful outcome of the free flap placement, the bone height was inadequate to receive an implants-supported oral rehabilitation. Hence osteotomy and distraction-osteoneogenesis were performed until bone levels become acceptable.

Pre-surgical determination of optimum location, angulation and depth to place fixtures provides adequate implant treatment planning.

Operative phases included oral impression, plaster study model, realization of a diagnostic waxing and of a radiological radiopaque stent, tooth and mucosa supported.

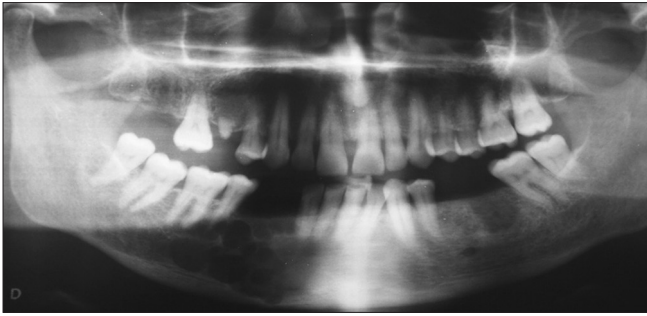


Figure 1: Preoperative dental X-ray. Typical ameloblastoma features are reported on the right side of the mandible

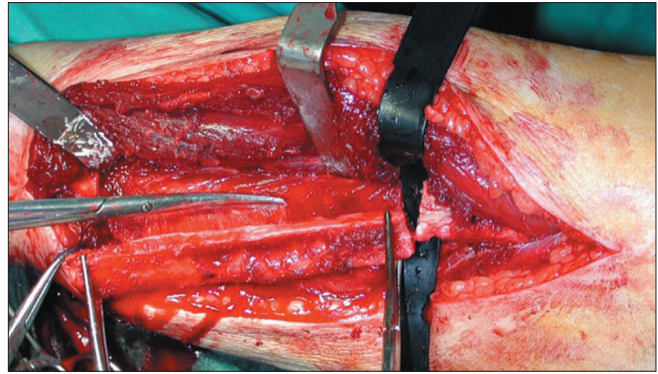

Figure 2: Free vascularized graft harvested from fibula

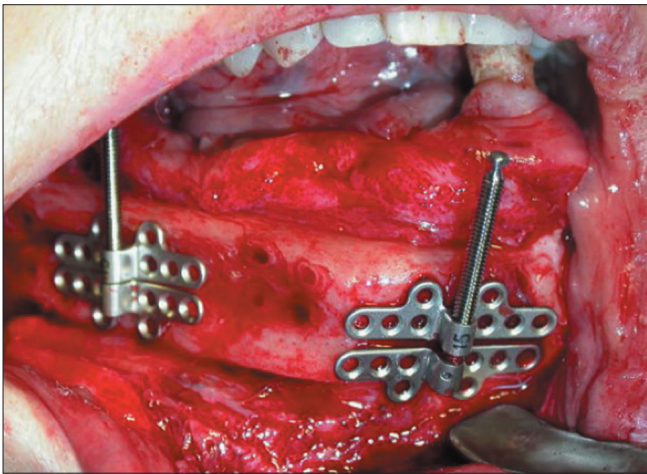


Figure 3: Distractor positioned on the fibula buccal portion

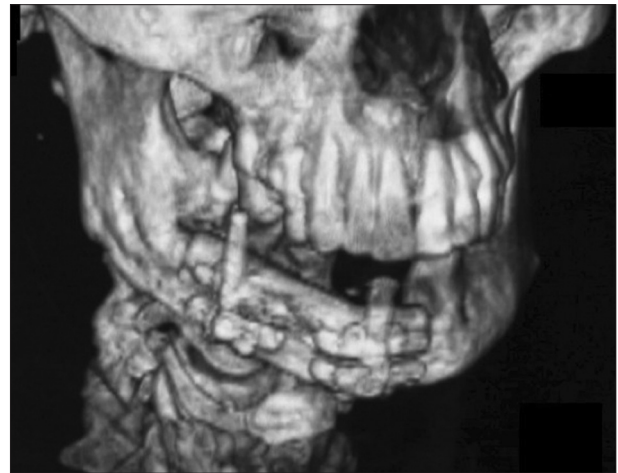

Figure 4: TC of jaw after the distractor positioning. Step one of the distraction osteogenesis

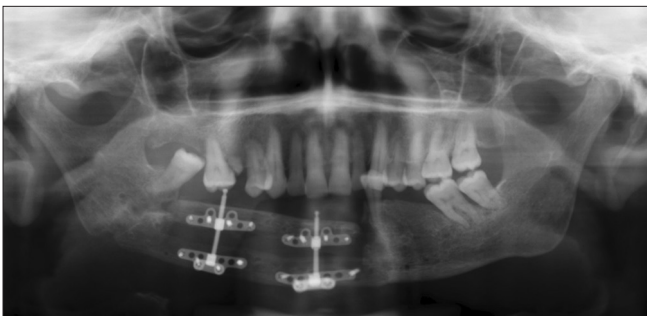

Figure 5: Distraction osteogenesis phase. Second radiographic control

The patient was processed to CT Dentascan dressing the radiological stent. TC acquisition allows to a 3D reconstruction of the mandibular arch and of the radiological stent verifying the correlation between the long axis of tooth and the grafted bone.

The placement of six fixtures ($\text{\O} 4 \text{ mm} \times 15 \text{ mm}$ Astra Tech Implants) in fibula grafted bone was planned, besides the insertion of two implants ($\text{\O} 4 \text{ mm} \times 11 \text{ mm}$ Astra Tech Implants) in native bone was considered, one of these positioned on post-extractive alveolus of second premolar and the other one distally.

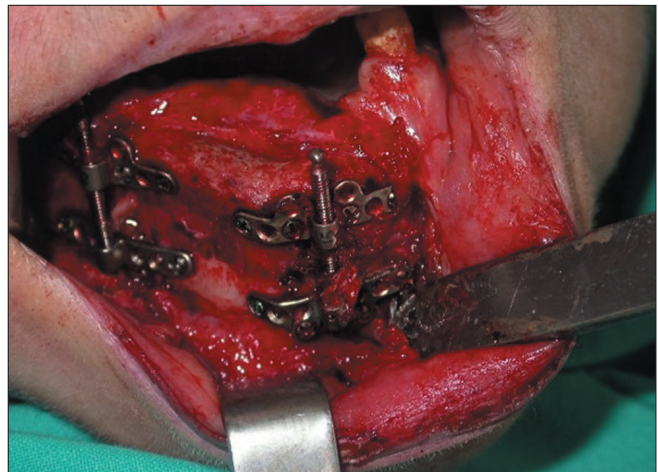

Figure 6: A full thickness flap was elevated and then the distractor was removed. Frontal view

Based on the previous analysis, the surgical stent - tooth and mucosa supported - was created.

Surgical placement of fixtures has been performed on the patient under conscience sedation. A two-stage approach involving the raising of muco-periosteal

flap and drill preparation of surgical implant side was chosen as the surgical protocol [Figures 9-11].

After six months, healing implant-necks were exposed in oral cavity, healing screws were allocated and elastomer oral impression was made in order to obtain master plaster model.

Besides, plaster transfer guide was made to verify the correct laboratory phases and passive fit of abutments and oral implants.

Metallic sovrastructure was realized and CRESCO™ system was utilized to achieve a passive fit of the prosthetic product manufactured. CRESCO™ is a computer-aided method involving laser cuts and welding of the metallic framework, thereby avoiding stress in fixture prosthetic interface.

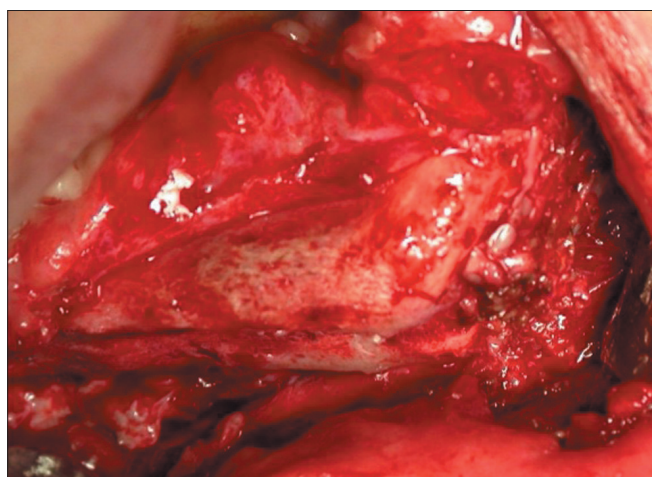


Figure 7: Bone exposure. A good amount of bone volume has been obtained after bone distraction

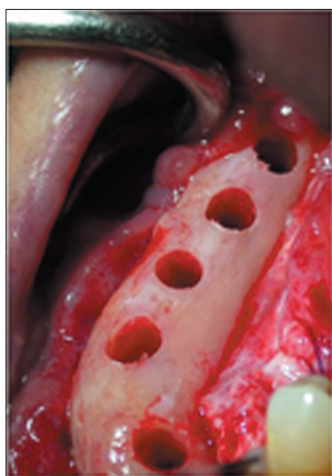

Figure 9: Surgical phase of dental implants placement. The blood in the holes underlines how the grafted bone is vital and integrated

Framework was finally orally tested and passive fit was achieved. On the basis of correct occlusal registration, a composite tooth was modeled and screw-retained prosthetic restoration was delivered to the patient.

The mandibular defect subsequent to the surgical resection of an ameloblastoma, consisting of hard and soft tissue loosening, was successfully corrected by fibula free flap. Adequate bone width was achieved by a prosthetic-driven vertical osteo-distraction. These surgical procedures made possible a prosthetically guided implant rehabilitation of the case. The patient was rehabilitated by a screw-retained prosthetic restoration, the passive fit of the manufactured product was ensured by Cresco system method.

Clinical and functional assessments, as well as quality of life and denture satisfaction were evaluated. Follow-up at five years confirmed the optimal integration of grafted tissue and the steady levels of bone around the fixtures. Peri-implant soft tissues show a healthy status, with the limited presence of keratinized mucosa. Follow-up at five years also proves the absence of unpassive prosthetic complications like unscrewing or alterations of composites covering [Figures 12-14].

Hence chewing and speech functions of the patient were restored. The esthetic and functional outcomes of the case restituted an acceptable quality of life to the patient.

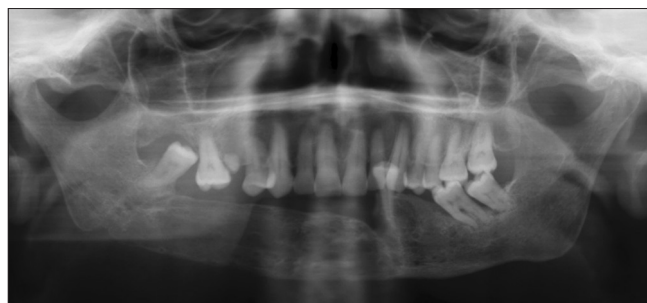

Figure 8: Radiographic control after distraction osteogenesis. Vertical augmentation of the bone is significant

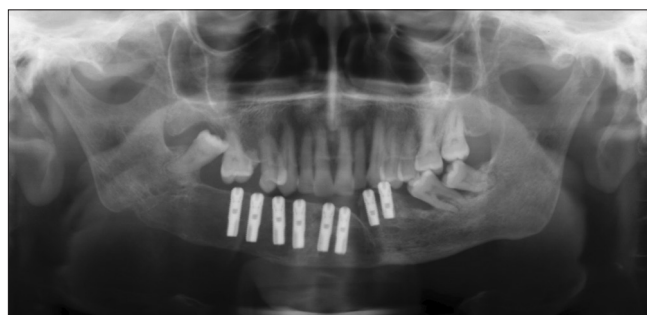

Figure 10: Radiographic control of the implant positioned

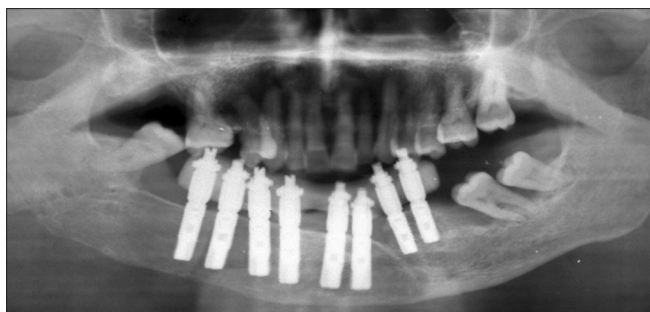


Figure 11: OPT image shows the dental implants with the abutments and the provisional prosthetic restoration

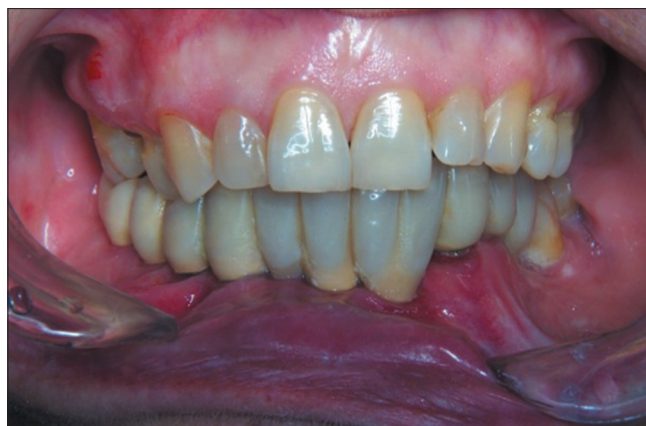

Figure 12: Clinical image of the provisional resin prosthetic restoration

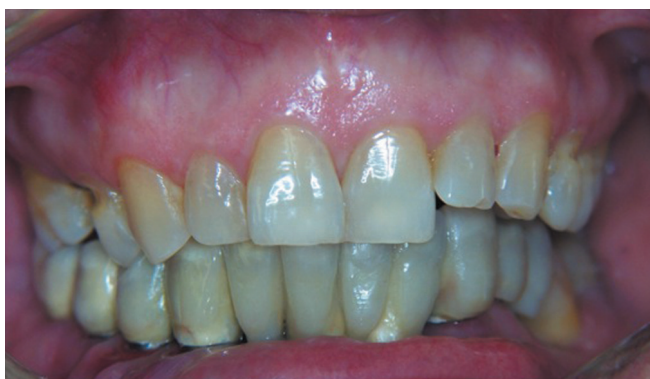

Figure 13: Five-years follow up of final prosthesis restoration. Clinical control

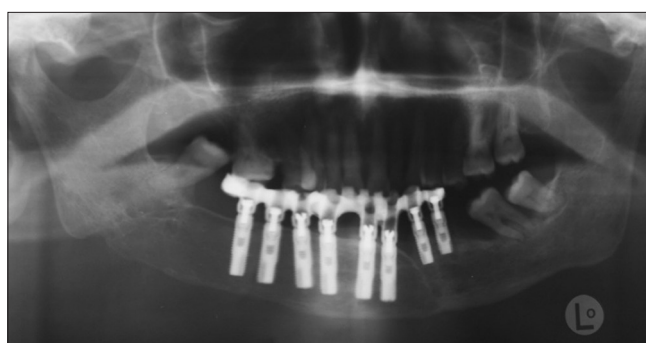


Figure 14: Five-years follow up of final prosthesis restoration. Radiographic control

DISCUSSION

Reconstruction of the large bone defect of the jaws using the reconstructive technique with free vascularized fibula flaps is a promising alternative to the commonly used techniques with no vascularized bone grafts. The use of free vascularized grafts has become a reliable and predictable technique during the last years. However, the procedure requires a team experienced with free vascularized tissue transfers. The graft choice for the reconstruction of continuity defects of the mandible following tumor resection can be directed to bone grafts, re vascularized free flaps or bank homologous bone, or growth factor.^[19-21]

The fibula is one of the favorite flaps in head and neck surgery for the reconstruction of defects in the mandible and the maxilla, because free flaps do not show significant resorption after the reconstructive procedure and before implant placement. Moreover, the vascularized graft is characterized by an immediate connection with vital tissue (blood supply). This is a relevant advantage that could lead to consider free flaps as the first choice in mandibular reconstruction.

Several authors have presented their results for the

reconstruction of large jaws defects.^[21,22] All the cases presented in the literature showed several advantages of using the free vascularized fibula flap such as correction of vertical height and intermaxillary relation, bicortical insertion of dental implants, less resorption and fewer problems with soft tissue healing because of the vascularity of the flap in comparison to non vascularized free bone grafts. The results of this study also confirm the same advantages.

On the other hand, the free vascularized fibula graft is characterized by limited bone height. The loss of vertical bone height, which results in an unfavorable crown-root ratio, is only one of the several disadvantageous factors. An acceptable result in function and esthetics might be achieved with the combination of inlay and onlay grafts. In this case, authors address this problem via distraction osteogenesis on the fibula graft.

Distraction osteogenesis is a predictable technique used in order to increase the ridge volume before dental implant placement. This technique is really useful for rebuilding soft and hard tissues volume at

the same time. Distraction osteogenesis for generating bone and soft tissue can be applied to craniofacial reconstruction, including orthognathic surgery, cleft lip and palate reconstruction, new mandibular condyle regeneration, a dent alveolar unit reconstruction for dental implants. Regardless of the surgical procedure, the following basic Ilizarov principles are the key to post op clinical success:

- Minimal periosteal stripping when osteotomy of the bone site is performed
- Latency period: 3, 5, or 7 days, depending on the surgical site
- Distraction rate: 1.0 mm per day (0.5–2.0 mm)
- Distraction rhythm: Continuous force application is best, yet device activation bid is more practical and allows for better patient compliance
- Consolidation: Until a cortical outline can be seen by radiographic investigation across the distraction gap, usually 6 weeks.

Careful follow-up is mandatory during the entire distraction process, including the time of post distraction ossification. Wound dehiscence problems can occur. Local wound care, including antibiotics and antimicrobial mouth rinses, alleviates this problem.^[23-25]

After thorough literature analyses, the surgical team have chosen the most favorable technique for solving this complex case. A combination of several techniques may be underlined during the therapeutic steps of this case. Results from this study, by a five-year follow-up control, showed that bone grafts re vascularized flaps are both a reliable means for the rehabilitation of resected patients with osseointegrated implants and implant borne prostheses. Clinical and radiographic examinations revealed no problems related to implant stability. On follow up, there was no implant loss recorded. This finding was surprising considering the fact that implant loss mainly occurs in the first year due to lack of osseointegration or infection. The use of vascularized bone grafts seems to have contributed to the high rate of implant survival. Moreover, after implant placement, very limited resorption of peri-implant bone was found even at 60 months follow up control. Success rates of implants in the present study can be compared favorably with other cases reported in the literature about implants placed in reconstructed mandibles.

Recent techniques involving vertical distraction of the fibula for atrophic ridge secondary reconstructions^[16,26-29] might help minimize the

disadvantages of current concepts of masticatory rehabilitation with dental implants in fibula-free flaps, solving the problem about the use of short dental implants for this kind of bone reconstruction procedure.

CONCLUSION

The results obtained in this study, without the loss of implants at a long-term follow up, prove the combination of surgical and prosthetic techniques as a valuable choice for the reconstruction of maxillofacial defects including severe atrophy of the maxilla. Moreover, this case report underlines that the combination of several surgical techniques may be helpful in order to give good esthetics and function to patients who need large bone reconstruction after tumor removal.

REFERENCES

1. Rekhi B, Saxena S. Cytomorphology of basal cell types of solid ameloblastoma: A case report. *J Cytol* 2006;23:83-5.
2. Grucia B, Stauffer E, Buser D, Bornstein M. Ameloblastoma of follicular, plexiform, and acanthomatous type in the maxillary sinus: A case report. *Quintessence Int* 2003;34:311-4.
3. Kahairi A, Ahmad RL, Wan Islah L, Norra H. Management of large mandibular ameloblastoma - A case report and literature reviews. *Arch Orofac Sci* 2008;3:52-5.
4. Gerzenshtein J, Zhang F, Caplan J, Anand V, Lineaweaver W. Immediate mandibular reconstruction with microsurgical fibula flap transfer following wide resection for ameloblastoma. *J Craniofac Surg* 2006;17:178-82.
5. Reichart PA, Philipsen HP, Sonner S. Ameloblastoma: Biological profile of 3677 cases. *Eur J Cancer B Oral Oncol* 1995;31B:86-99.
6. Navarro CM, Principi SM, Massucato EM, Spoto MR. Maxillary unicystic ameloblastoma. *Dentomaxillofac Radiol* 2004;33:60-2.
7. Roos RE, Raubenheimer EJ, van Heerden WF. Clinicopathological study of 30 unicystic ameloblastomas. *J Dent Assoc S Afr* 1994;49:559-62.
8. Konouchi H, Asaumi J, Yanagi Y, Hisatomi M, Kawai N, Matsuzaki H, *et al.* Usefulness of contrast enhanced-MRI in the diagnosis of unicystic ameloblastoma. *Oral Oncol* 2006;42:481-6.
9. Kim SG, Jang HS. Ameloblastoma: A clinical, radiographic, and histopathologic analysis of 71 cases. *Oral Surg Oral Med Oral Pathol Oral Radiol Endod* 2001;91:649-53.
10. Philipsen HP, Reichart PA. Classification of odontogenic tumors and allied lesions. *Odontogenic tumors and allied lesions*. London: Quintessence Pub. Co. Ltd; 2004. p. 21-3.
11. Chana JS, Chang YM, Wei FC, Shen YF, Chan CP, Lin HN, *et al.* Segmental mandibulectomy and immediate free fibula osteoseptocutaneous flap reconstruction with endosteal implants: An ideal treatment method for mandibular ameloblastoma. *Plast Reconstr Surg* 2004;113:80-7.

12. Cordeiro PG, Disa JJ, Hidalgo DA, Hu QY. Reconstruction of the mandible with osseous free flaps: A 10-year experience with 150 consecutive patients. *Plast Reconstr Surg* 1999; 104:1314-20.
13. Hidalgo DA. Fibula free flap: A new method of mandible reconstruction. *Plast Reconstr Surg* 1989;84:71-9.
14. Hayater JP, Cawood JJ. Oral rehabilitation with endosteal implants and free flaps. *Int J Oral Maxillofac Surg* 1996;25:3-12.
15. Moscoso JF, Keller J, Genden E, Weinberg H, Biller HF, Buchbinder D, *et al.* Vascularized bone flaps in oromandibular reconstruction. A comparative anatomic study of bone stock from various donor sites to assess suitability for enosseous dental implants. *Arch Otolaryngol Head Neck Surg* 1994;120:36-43.
16. Chiapasco M, Brusati R, Galioto S. Distraction osteogenesis of a fibular revascularized flap for improvement of oral implant positioning in a tumor patient: A case report. *J Oral Maxillofac Surg* 2000;58:1434-40.
17. Eski M, Turegun M, Deveci M, Gokce HS, Sengezer M. Vertical distraction osteogenesis of fibular bone flap in reconstructed mandible. *Ann Plast Surg* 2006;57:631-6.
18. Klesper B, Lazar F, Siessegger M, Hidding J, Zöller JE. Vertical distraction osteogenesis of fibula transplants for mandibular reconstruction-A preliminary study. *J Craniomaxillofac Surg* 2002;30:280-5.
19. Bähr W, Lessing R. The response of midfacial bone in sheep to loaded osteosynthesis screws in pretapped and nontapped implant sites. *J Oral Maxillofac Surg* 1992;50:1289-94.
20. Bähr W, Coulon JP. Limits of the mandibular symphysis as a donor site for bone grafts in early secondary cleft palate osteoplasty. *Int J Oral Maxillofac Surg* 1996;25:389-93.
21. Herford AS, Cicciù M. Recombinant human bone morphogenetic protein type 2 jaw reconstruction in patients affected by giant cell tumor. *J Craniofac Surg* 2010;21:1970-5.
22. Koshima I, Hosoda M, Ohta S, Moriguchi T, Soeda S, Nakayama Y, *et al.* Free vascularized iliac osteomusculocutaneous flaps based on the lateral circumflex femoral system for repair of large mandibular defects. *Ann Plast Surg* 1994;33:581-8.
23. Nakayama B, Matsuura H, Hasegawa Y, Ishihara O, Hasegawa H, Torii S. New reconstruction for total maxillectomy defect with a fibula osteocutaneous free flap. *Br J Plast Surg* 1994;47:247-9.
24. Ilizarov GA, Matveenko VN, Gaïdamak AN, Ir'ianov IuM. Formation of an organic matrix in the traction method of bone regeneration and characteristics of its mineralization in experimental tibia lengthening. *Vopr Med Khim* 1982;28:27-33.
25. Ilizarov GA, Ir'ianov IuM, Migalkin NS, Petrovskaia NV. Ultrastructural characteristics of elastogenesis in the major arteries of the canine hindlimb during leg lengthening. *Arkh Anat Gistol Embriol* 1987;93:94-8.
26. Aronson J, Harrison BH, Stewart CL, Harp JH Jr. The histology of distraction osteogenesis using different external fixators. *Clin Orthop Relat Res* 1989;241:106-16.
27. Rohner D, Bucher P, Kunz C, Hammer B, Schenk RK, Prein J. Treatment of severe atrophy of the maxilla with the prefabricated free vascularized fibula flap. *Clin Oral Implants Res* 2002;13:44-52.
28. Rohner D, Tan BK, Song C, Yeow V, Hammer B. Repair of composite zygomatico-maxillary defects with free bone grafts and free vascularized tissue transfer. *J Craniomaxillofac Surg* 2001;29:337-43.
29. Nocini PF, Wangerin K, Albanese M, Kretschmer W, Cortelazzi R. Vertical distraction of a free vascularized fibula flap in a reconstructed hemimandible: A case report. *J Craniomaxillofac Surg* 2000;28:20-4.

How to cite this article: Oteri G, De Ponte FS, Pisano M, Cicciù M. Five years follow-up of implant-prosthetic rehabilitation on a patient after mandibular ameloblastoma removal and ridge reconstruction by fibula graft and bone distraction. *Dent Res J* 2012;9:226-32.

Source of Support: Nil, **Conflict of Interest:** None declared.