

The effect of intravitreal bevacizumab (Avastin[®]) on ocular pulse amplitude in neovascular age-related macular degeneration

Ehud Rechtman¹
Ingeborg Stalmans²
Joseph Glovinsky¹
Christophe Breusegem²
Joseph Moisseiev¹
Joachim Van Calster²
Alon Harris³

¹Goldschleger Eye Institute, Sheba Medical Center, Ramat Gan, Israel; ²Department of Ophthalmology, University Hospitals Leuven, Leuven, Belgium; ³Department of Ophthalmology, Indiana University, Indianapolis, IN, USA

Purpose: To evaluate the effect of intravitreal (IVT) bevacizumab in neovascular age-related macular degeneration (AMD) on global choroidal hemodynamics, as measured by ocular pulse amplitude (OPA).

Methods: This was a two-center prospective study (Sheba Medical Center, Israel, and University Hospitals Leuven, Belgium). AMD patients who required IVT bevacizumab (1.25 mg/0.05 mL; first or repeated) were examined three times: at days 0 (prior to injection), 7 (± 3), and 28 (± 7) postinjection. At each visit, OPAs of both eyes were measured using the Pascal dynamic contour tonometer (DCT). A paired *t*-test between preoperative and postoperative OPA was conducted. Pearson correlation was used to evaluate the influence of various measured parameters on DCT–OPA.

Results: A total of 38 neovascular AMD patients were recruited, and 30 patients were included in the final analysis (18 females and 12 males; age 78.8 ± 5.82 years [mean \pm standard deviation]). A good correlation was found throughout the study between the DCT–intraocular pressure (IOP) and Goldmann IOP and between DCT–IOP and DCT–OPA. No change in OPA of bevacizumab-treated eyes was found between the visits (2.24 ± 0.73 , 2.2 ± 0.86 , and 2.23 ± 0.73 mm Hg at visits 1, 2, and 3, respectively; paired *t*-test: $P = 0.77$ between visits 1 and 2, $P = 0.98$ between visits 1 and 3). No correlations were found between DCT–OPA and age, heart rate, systemic blood pressure, axial length, keratometry readings, and central corneal thickness.

Conclusions: OPA, an indirect measure of global choroidal hemodynamics, remains unchanged following IVT off-label bevacizumab. This finding adds to the growing evidence regarding the safety profile of bevacizumab in AMD treatment.

Keywords: macular degeneration, choroid, blood flow, ocular pulse amplitude, bevacizumab

Introduction

There is evidence that retinal pigment epithelium (RPE)-secreted vascular endothelial growth factor-A (VEGF-A) is essential to maintain a normal functioning, fenestrated choriocapillaris in order to nourish the RPE and outer retina.^{1,2} In spite of this, VEGF blockage, either by US Food and Drug Administration-approved ranibizumab (Lucentis[®], [Genentech Inc., San Francisco, CA, USA]) or off-label bevacizumab (Avastin[®], [Genentech Inc., San Francisco, CA, USA]), is currently the most common treatment modality for neovascular age-related macular degeneration (AMD).

Although the pathogenesis of neovascular AMD is under debate, ischemic hypoxia may play a significant role in it, as various studies have already demonstrated altered choroidal filling in AMD.^{3–12} An indirect method to assess global choroidal circulation, which accounts for 85% of the total ocular circulation, is by measuring the ocular pulse amplitude (OPA).^{13–15} OPA, which mainly originates from choroidal hemodynamic

Correspondence: Ehud Rechtman
Goldschleger Eye Institute,
Sheba Medical Center,
Ramat Gan 52621, Israel
Tel +972 52 2528871
Fax +972 9 7403669
Email ehudrechtman@gmail.com

changes during the cardiac cycle, was previously found to be lower in neovascular AMD compared with nonneovascular AMD, as well as controls.¹² Intravitreal (IVT) ranibizumab and bevacizumab have a global effect on the amount of all isoforms of active ocular VEGF-A. Therefore, in this susceptible neovascular AMD population, repeated IVT injections of these anti-VEGF drugs, in addition to their effect on pathologic choroidal neovascularization (CNV), may also damage the normal choroidal microvasculature, especially the choriocapillaris. Of special interest are two recent prospective studies that evaluated the aqueous humor levels of different cytokines, including VEGF, in neovascular AMD population and controls, at baseline and following repeated ranibizumab¹⁶ and bevacizumab.¹⁷ Both studies have found anti-VEGF therapy to significantly decrease intraocular VEGF levels. Also, the study with the greater patient cohort (28 AMD eyes, 28 controls)¹⁶ found intraocular VEGF at baseline to be significantly higher in neovascular AMD eyes compared with control eyes undergoing cataract operation ($P = 0.033$).

The purpose of this study was to evaluate the effect of IVT bevacizumab in neovascular AMD on global choroidal hemodynamics, as measured by OPA.

We hypothesized that OPA values would be transiently reduced 1 week following IVT bevacizumab with a recovery to preinjection values 4 weeks post-treatment. This was based on recent IVT pharmacokinetics studies that found bevacizumab terminal half-life to be 4.32 days in a rabbit model¹⁸ and between 6.7 and 10 days in AMD patients.^{19,20}

Methods

A total of 38 patients with active subfoveal/juxtafoveal CNV/AMD were recruited for this two-center prospective study conducted at Goldschleger Eye Institute, Sheba Medical Center, Israel, and University Hospitals Leuven, Belgium. Written informed consent was obtained from all participants. The study adhered to the tenets of the Declaration of Helsinki and was approved by the Institutional Review Board in both the hospitals. Table 1 summarizes the study inclusion/exclusion criteria.

Patients were tested over three study visits: 1) on the day of the IVT bevacizumab treatment, prior to the injection; 2) 1 week (± 3 days) postinjection; and 3) 4 weeks (± 7 days) postinjection. Table 2 summarizes the tests performed in each of the study visits. Prepupil dilation intraocular pressure (IOP) was initially tested twice (the mean of the two measurements was taken for analysis) in both eyes of each study patient with a calibrated Goldmann applanation tonometer (GAT). This was

Table 1 Inclusion/exclusion criteria

Inclusion criteria

1. Male or female aged 50 years or over 50 years
2. Between 0 and 12 prior IVT bevacizumab treatments for subfoveal or juxtafoveal choroidal neovascularization due to AMD in the treated eye
3. Willing and able to sign an informed consent form

Exclusion criteria

1. A history or signs and symptoms of any retinal or optic nerve disease, except AMD with or without mild hypertensive retinopathy
2. In the bevacizumab-treated eye, prior other anti-VEGF (pegaptanib or ranibizumab), photodynamic therapy, and/or IVT triamcinolone acetonide, during the last 3 months
3. Any AMD treatment except AREDS formulation for the fellow eye during the last 3 months
4. History of ocular surgery with the exception of uneventful extracapsular cataract extraction with posterior chamber intraocular lens
5. History of ocular laser treatment, with the exception of YAG capsulotomy for posterior capsule opacification
6. Cataract or other media opacity precluding adequate fundus visualization of both eyes

Abbreviations: AMD, age-related macular degeneration; AREDS, Age-Related Eye Disease Study; IVT, intravitreal; VEGF, vascular endothelial growth factor; YAG, yttrium aluminum garnet.

immediately followed by IOP and OPA measurements with the Pascal dynamic contour tonometer (Pascal DCT, Swiss Microtechnology AG, Port, Switzerland; slit-lamp-mounted, self-calibrating, 1-g appositional force, 100-Hz sampling rate, 7-mm tip diameter, 1.2-mm pressure sensor diameter) in both eyes. Up to three DCT measurements were taken in order to have one good-quality measurement (quality level 1 to 2). In cases in which none of the three measurements was of quality level 1 or 2, the data from the better quality measurement were taken for analysis. In order to eliminate insufficient test quality OPA measurements, those patients whose best-quality DCT measurement in at least one visit was no better than 5 (worst quality) were excluded from the final analysis.

Statistical analysis was performed with SPSS statistical software package, version 10 (SPSS Inc, Chicago, IL, USA). A paired *t*-test between preinjection and postinjection OPAs at 1 and 4 weeks was performed to evaluate the effect of bevacizumab on OPA. Similar comparisons were performed for the fellow eye, which served as a negative control. Univariate Pearson correlation was used to evaluate the influence of various measured parameters (Table 2) on the DCT–IOP and DCT–OPA.

Results

One patient could not attend visit 2 and was removed from the study analysis. All other 37 patients with neovascular AMD

Table 2 Schedule of visits and procedures

	Pre-treatment	Visit 1	Visit 2	Visit 3
	Clinic visit/day of injection	On the day of IVT bevacizumab	A week (± 3 days) post-IVT bevacizumab	4 weeks (± 7 days) post-IVT bevacizumab
Recruitment	×			
Medical/ocular history	×			
HR and BP ¹		×	×	×
VA ²		×	×	×
IOP with GAT followed by IOP and OPA with DCT ³		×	×	×
Biomicroscopic examination, FA, and OCT results from the clinical notes ⁴	As seen on the preinjection visit	×	×	As seen during the clinical visit at this day
Axial length, K reading, and CCT of both eyes ⁵			×	
			During any of the three study visits	

Notes: ¹HR and systemic BP were measured after 5 min of rest, in a sitting position; ²VA test of both eyes, using the patient's glasses for distance and through a pinhole, on a Snellen chart; ³IOP with GAT; IOP and OPA with Pascal DCT; ⁴Biomicroscopic examination at each visit; last FA test prior to study entry; OCT at baseline and at the end of the study; ⁵Axial length and corneal curvature (K reading) measurements using IOL Master (Carl Zeiss AG, Feldbach, Switzerland); CCT measurements with an ultrasonic pachymeter (mean of three readings within a range of $\pm 5 \mu\text{m}$ was taken for analysis).

Abbreviations: BP, blood pressure; CCT, central corneal thickness; DCT, dynamic contour tonometer; FA, fluorescein angiography; GAT, Goldmann applanation tonometer; HR, heart rate; IOP, intraocular pressure; IVT, intravitreal; K, keratometry; OCT, optical coherence tomography; OPA, ocular pulse amplitude; VA, visual acuity.

completed the study. In the final analysis, the data of seven of these patients were excluded. Six patients were excluded due to inadequate DCT quality measurements (best-quality measurement with DCT in at least one visit = 5), and one patient was excluded due to severe systemic hypertension in one of the visits (which may change the OPA value). The final analysis was therefore conducted on data from 30 patients, 15 patients from each center.

The age of the study population was 78.8 ± 5.82 years (mean \pm standard deviation [SD]; range: 69–92). Of the 30 study patients, 18 patients were female. A total of 13 patients had been treated for systemic hypertension, and one patient had been treated for type 2 diabetes mellitus without retinopathy.

Mean visual acuity at baseline was 0.634 ± 0.409 ([logMAR (mean \pm SD); Snellen equivalent 20/85]) in the bevacizumab-treated eye and 0.766 ± 0.626 ([logMAR (mean \pm SD); Snellen equivalent 20/118]) in the fellow eye. Table 3 summarizes the ocular characteristics of the

Table 3 Ocular characteristics

	Study eye	Fellow eye
Axial length (mm; mean \pm SD)	23.45 ± 0.87	23.53 ± 1.07
Keratometry reading (D; mean \pm SD)	43.38 ± 1.62	43.47 ± 1.5
Central corneal thickness (μm ; mean \pm SD)	552.93 ± 36.26	553.43 ± 38.76
Pseudophakia (no. of eyes/total)	14/30	11/30

Abbreviation: SD, standard deviation.

30 participants. Ninety percent of the bevacizumab-treated eyes had subfoveal CNV, and half of the lesions were of the occult type. At baseline, the prior number of IVT bevacizumab treatments was 2.17 ± 2.53 (mean \pm SD; range: 0–9; 12 treatment naive; no eye received prior ranibizumab), and only four of the treated eyes received prior photodynamic therapy with verteporfin. Table 4 summarizes the bevacizumab-treated eyes' visual acuity, GAT–IOP, DCT–IOP, and DCT–OPA in all visits.

Among all IOP/OPA–DCT measurements in the final analysis (best measurement of each eye in each visit), 58.0% had a quality score of 1 (best), 21.2% with a quality score of 2, 19.2% with a quality score of 3, and only 1.6% with a quality score of 4. Good correlation was found between the DCT–IOP and GAT–IOP measurements throughout the study, with slightly higher values obtained with the DCT (Table 4 and Figure 1). DCT–IOP and DCT–OPA measurements showed Gaussian distributions, which eliminated the need to convert them into logarithmic units. A positive correlation was found between DCT–OPA and DCT–IOP (Figure 2).

This study did not find any significant change in bevacizumab-treated eye DCT–OPA from visits 1 to 2 (paired *t*-test, $P = 0.77$) and from visits 1 to 3 (paired *t*-test $P = 0.98$; Table 4). Because OPA is dependent on IOP, the change in the DCT–OPA/DCT–IOP ratio was also evaluated in order to isolate the pulsatile blood flow component. No change in OPA/IOP ratio was found between visits 1 and 2 or between visits 1 and 3 (bevacizumab-treated eye, *t*-test: $P = 0.377$ for visits 1–2; $P = 0.679$ for visits 1–3).

Table 4 Bevacizumab-treated eyes' VA, IOP, and OPA during the study

Visit #	logMAR (mean ± SD) (Snellen equivalent)	IOP (mean ± SD)	OPA (mm Hg; mean ± SD) (range)
Visit 1 (baseline)	0.634 ± 0.409 (~20/85)	14.02 ± 3.09 (GAT) 15.36 ± 2.78 (DCT)	2.24 ± 0.73 (0.8–3.6)
Visit 2 (day 7 ± 3)	0.581 ± 0.335 (~20/76)	13.95 ± 2.37 (GAT) 14.39 ± 2.25 (DCT)	2.20 ± 0.86 (1–4.5)
Visit 3 (day 28 ± 7)	0.612 ± 0.417 (~20/82)	13.90 ± 2.55 (GAT) 15.17 ± 2.79 (DCT)	2.23 ± 0.73 (0.7–3.6)

Abbreviations: DCT, dynamic contour tonometer; GAT, Goldmann applanation tonometer; IOP, intraocular pressure; OPA, ocular pulse amplitude; SD, standard deviation; VA, visual acuity.

No correlations were found between DCT–OPA and age, heart rate, systolic/diastolic/mean systemic blood pressure, axial length, keratometry readings, and central corneal thickness.

Discussion

Earlier studies using different techniques, such as fluorescein angiography, indocyanine green angiography, laser Doppler flowmetry, color Doppler imaging, and Langham ocular blood flowmetry (Langham OBF), have found altered ocular hemodynamics in AMD patients.^{3–12} Among these earlier studies, Mori et al, using the Langham OBF, which measures the IOP, OPA, and pulsatile OBF, found neovascular AMD patients to have significantly lower OPA and calculated pulsatile OBF as compared with nonneovascular AMD, as well as controls.¹² Also, a recent study by Boltz et al found low subfoveal choroidal perfusion and low fundus pulsation amplitude (as assessed by laser Doppler flowmetry and laser interferometry, respectively) to be risk factors for

the development of CNV in the fellow eye of patients with unilateral CNV.²¹

Today, data supporting a causal role for VEGF in ocular neovascularization, including neovascular AMD, are extensive.²² A recent AMD/ranibizumab prospective human study, with 1-year follow-up, has found aqueous humor VEGF levels in treatment-naïve eyes with recent neovascular AMD to be double those of age-matched controls (median 85.57 and 41.54 pg/mL, respectively; $P = 0.033$).¹⁶ A month following the first ranibizumab treatment, intraocular VEGF was below the detection level in 85% of eyes.¹⁶ A redetection in VEGF levels below detection was only measured after treatment with a previous injection 1 month before.¹⁶ Another recent study has evaluated the effect of three consecutive IVT 1.25-mg bevacizumab injections, every 7 (±2) weeks, on the aqueous humor level of different cytokines, including VEGF.¹⁷ In that study, the mean ± SD aqueous humor level of VEGF was 68.0 ± 32.1 pg/mL at baseline in the AMD group and 51.2 ± 33.4 pg/mL in

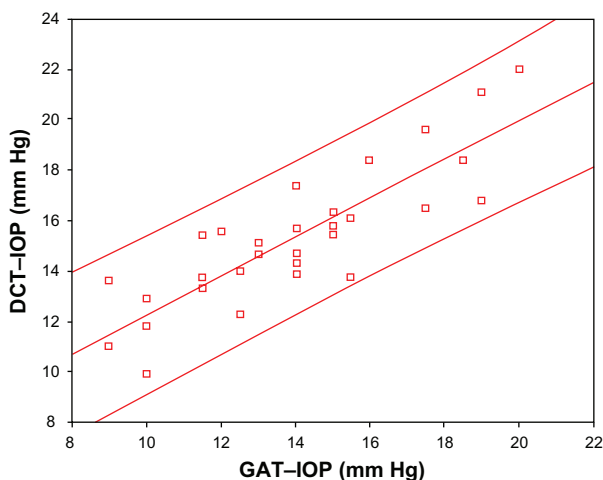


Figure 1 The correlation between IOP measurements obtained by GAT and DCT (bevacizumab-treated eyes, at baseline). Regression line (central) and 95% confidence boundaries (top and bottom lines; Pearson correlation $r = 0.85$, $P < 0.001$). DCT–IOP values were slightly higher than GAT–IOP (IOP difference: 1.35 mm Hg; Paired t -test: $P < 0.001$).

Abbreviations: DCT, dynamic contour tonometer; GAT, Goldmann applanation tonometer; IOP, intraocular pressure.

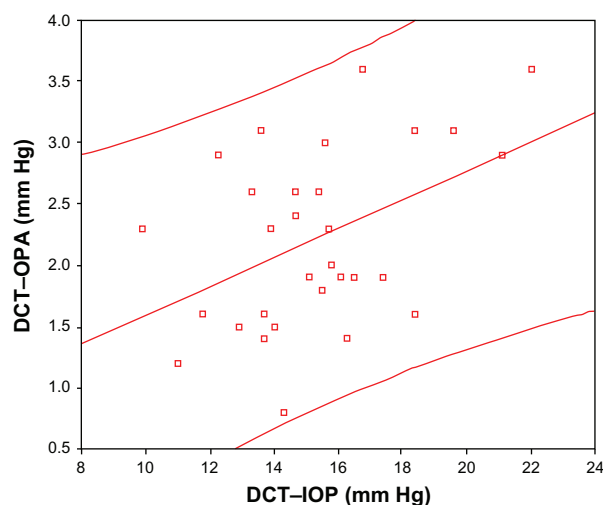


Figure 2 The correlation between DCT–IOP and DCT–OPA (bevacizumab-treated eyes, at baseline). Regression line (central) and 95% confidence boundaries (top and bottom lines). DCT–OPA showed positive correlation to DCT–IOP (Pearson correlation: $r = 0.44$, $P = 0.014$).

Abbreviations: DCT, dynamic contour tonometer; IOP, intraocular pressure; OPA, ocular pulse amplitude.

the control group ($P=0.131$). The VEGF level was significantly reduced to 26.3 ± 19.0 pg/mL after the first IVT bevacizumab injection ($P=0.028$) and to 25.2 ± 12.8 pg/mL after the second injection compared with the baseline value ($P=0.005$).¹⁷

In light of recent reports, there is evidence to suggest that RPE-secreted VEGF constitutively signals normal choroidal endothelial cells *in vivo*.^{1,2} It is believed that this paracrine communication mediates the maintenance of a normally functioning, fenestrated, and quiescent choriocapillaris in the adult, which is required to nourish the RPE and outer retina, including the photoreceptor cells.¹ In tissue culture, multiple retinal cell types produce VEGF and increase production under hypoxic conditions in the microenvironment.²² Fenestrated vessels appear to be especially sensitive to VEGF withdrawal.^{23–26} In an animal study using adult mice, VEGF inhibition resulted in transient capillary regression in the normal choroid plexus, pancreatic islets, thyroid, adrenal cortex, pituitary, small intestinal villi, and epididymal adipose tissue.²⁵ In another study, conditional inactivation of VEGF expression in the RPE in mice eyes resulted in the absence of choroid. Instead, underneath the RPE, dense collagenous tissue resembling sclera was observed.²

Early penetration studies using full-length anti-VEGF antibodies, similar to bevacizumab and the Fab fragment ranibizumab, seemed to indicate that the full-length antibody penetrates the retina poorly, whereas the Fab fragment penetrated the neurosensory retina well.²⁷ This has led Genentech to focus their clinical neovascular AMD studies on ranibizumab alone. However, recent penetration studies refute the earlier findings, demonstrating bevacizumab to have a rapid and full thickness neurosensory retina penetration.^{28–30} Peters et al have recently reported that IVT 1.25 mg of bevacizumab to eyes of monkeys caused ultrastructural changes in the choriocapillaris.³¹ In their study, a significant reduction of choriocapillaris endothelial cell fenestrations was seen as early as 24 hours after injection, and their number increased again after 2 weeks. On day 14, after IVT bevacizumab, the effect in closing endothelial cell fenestrations was already diminished, but there were still significantly fewer fenestrations than those in untreated eyes. Furthermore, the Peters et al study provided an indication of choriocapillaris perfusion disturbances. Although severe photoreceptor damage was rare, they have raised this as a potential risk of bevacizumab.

At present, little is known about the effect of bevacizumab on the histological morphology of CNV in humans. Recently, the histological findings in a single surgically excised membrane from a patient with repeated IVT bevacizumab treatments who developed an RPE tear have been reported.³²

The authors described a specimen that consisted of a largely fibrotic choroid, an irregular Bruch's membrane, and an avascular subretinal RPE proliferation set in a fibrous tissue. The most striking observation in the tissue was the lack of capillaries both in the choroid and in the CNV elements.

The results of the currently ongoing National Eye Institute Comparisons of Age-Related Macular Degeneration Treatments Trials (CATT),³³ with head-to-head comparisons regarding the clinical efficacy and safety of ranibizumab and bevacizumab, are expected to be published in 2012. However, this trial will not address the potential subclinical side effects of transiently altered choroidal circulation.

Pascal DCT is a new tonometer designed to measure IOP and OPA, and hence it can also provide choroidal hemodynamics global data, mainly on the pulsatile choroidal component. As opposed to the Langham OBF, DCT does not, at present, calculate the pulsatile OBF value from OPA. On the other hand, DCT is more accurate than Langham OBF in measuring the IOP and OPA and was recently shown to have good concordance with intracameral IOP.³⁴ Recent studies show IOP measurements by DCT to be highly concordant with IOP readings obtained from GAT.^{35–37} Our study findings are in agreement with the literature, showing good correlation between the DCT–IOP and GAT–IOP measurements throughout the study, with slightly higher values with the Pascal DCT. Also, our study found a positive correlation between DCT's OPA and IOP, similar to the reports in literature.^{38,39} Previous studies, however, conducted on younger subjects^{38–41} have found a negative correlation between axial length and OPA. Romppainen et al and McBrien and Gentle have suggested that this may be due to inherently reduced scleral rigidity in myopic eyes, resulting in less resistance to enlargement of the pulsatile volume.^{40,42} Our study did not find such a negative correlation between axial length and OPA. This result may be due to the lack of patients having high myopia in our study (mean \pm SD axial length of 23.45 ± 0.87 mm, which represents an overall emmetropic population). Another possible explanation for our result is that the scleral rigidity in elderly people with AMD is higher than that in the younger subjects who participated in the previous studies. Support for this comes from Pallikaris et al,⁴³ who found a significant positive correlation between the rigidity coefficient and age, as well as from Friedman et al,⁴⁴ who found an increased scleral rigidity in AMD subjects as compared with controls. There are little data available regarding the normal values of DCT–OPA in the aged population. In the Grieshaber et al study, where the mean age of the 29 subjects was 64.0 ± 8.3 years (mean \pm SD; range 43–80 years), OPA values were 2.3 ± 0.9 mm Hg (mean \pm SD).³⁹

In the Stalmans et al study, the mean age of the 22 controls was 68.5 ± 8.9 years, and the mean OPA values were around 3.4 ± 1.6 mm Hg.⁴⁵ Our study population was much older than those in the two aforementioned studies (78.8 ± 5.82 years; mean \pm SD), and OPA values were 2.24 ± 0.73 mm Hg (mean \pm SD) at baseline. Because no published study has yet evaluated DCT–OPA in the elderly population, it is difficult to conclude whether patients with neovascular AMD have lower than normal DCT–OPA values, as found with the Langham OBF.¹²

In a review of the literature, no prior study has yet evaluated the effect of bevacizumab or any other anti-VEGF treatment on OPA in AMD or in any other ocular disease. In this study, IVT off-label bevacizumab, at a 1.25 mg/0.05 mL dose, was not found to cause a global choroidal hemodynamic deficit, as measured by the DCT–OPA and DCT–OPA/IOP ratio 1 and 4 weeks following treatment. There may be several plausible explanations to these findings. It is possible that the amount of bevacizumab that reached the choriocapillaris within the first week post-IVT bevacizumab is not sufficient to cause a significant transient choriocapillaris regression to alter the choroidal resistivity to blood flow and to affect the OPA. It is also possible that some choriocapillaris damage does occur, but the larger choroidal vessels are not affected, and hence global choroidal circulation, as measured by OPA, does not significantly change. In addition, the number of patients in this study was relatively small ($n = 30$), which therefore allows us only to conclude that no massive effect of IVT bevacizumab on the DCT–OPA and DCT–OPA/IOP ratio appears to be present. A more subtle hemodynamic effect of bevacizumab might be picked up only in a much larger study. Ideally, such a study should recruit only treatment-naïve patients and have a long follow-up.

Because OPA is mainly the result of global choroidal pulsation, it may not be the most sensitive way to assess the possibility of bevacizumab-related choroidal hypoperfusion abnormalities in the macular area. To test the latter possibility, other techniques, such as semiquantitative indocyanine green angiography, may be used.⁴⁶

The results of this pilot study may add data to the safety profile of IVT bevacizumab, which is widely used in ophthalmology despite the lack of any phase III clinical trial data. Although the VEGF-inhibiting effect of ranibizumab and bevacizumab is transient, potential future anti-VEGF slow release devices still possess the risk of causing transient or even permanent choriocapillaris/RPE/outer retina damage through their constant elimination of VEGF, which may be

lower than the minimum amount needed for maintaining a properly functioning choriocapillaris.

This study has several major limitations. Apart from its small patient cohort, it recruited patients with a different number of previous bevacizumab injections (only 12 patients were treatment naïve), and it had a relatively short follow-up.

Dozens of ranibizumab/bevacizumab IVT injections may be given to a single eye over a period of years. This may result in cumulative damage. A future study with a long follow-up, in which only anti-VEGF-naïve patients will be recruited, can best assess the possibility of such cumulative hemodynamic damage. In this regard, two recent studies evaluating the potential electroretinographic effects of repeated ranibizumab/bevacizumab injections have been published. Zayit-Soudry et al have evaluated the long-term retinal toxicity of nine consecutive ranibizumab and bevacizumab biweekly injections in rabbits.⁴⁷ They found electroretinographic and visual-evoked potential responses of the experimental and control eyes to be similar in amplitude and pattern throughout the follow-up period.⁴⁷ Also, histopathologic evaluation by Zayit-Soudry et al yielded similar results, and no retinal damage was observed in the experimental and control eyes of all rabbits.⁴⁷ Pedersen et al conducted a 6-month prospective pilot human study on 26 eyes of 26 previously treatment-naïve patients with neovascular AMD receiving IVT injections with 1.25 mg bevacizumab.⁴⁸ All patients were examined with multifocal and full-field electroretinography (ERG). In full-field ERG, they found a decrease in cone photoreceptor function at 3 months, which was normalized at 6 months compared with baseline. Their results do not show any conclusive signs of global retinal toxicity after 6 months.⁴⁸ Instead, multifocal ERG showed improvement in photoreceptor function with no sign of focal toxicity in the central retina.⁴⁸ Other studies have looked at the effect of repeated anti-VEGF on IOP. In a retrospective study, Adelman et al have found a 3.45% rate (4/116 patients) of sustained elevated IOP after multiple IVT injections of bevacizumab 1.5 mg/0.06 mL and/or ranibizumab 0.5 mg/0.05 mL.⁴⁹ None of the four patients had a previous diagnosis or family history of glaucoma/ocular hypertension (OHT). Two patients developed OHT after recent IVT ranibizumab and two patients after recent IVT bevacizumab injection.⁴⁹ A similar retrospective study by Good et al has found an increased rate of sustained elevation in IOP in patients receiving IVT bevacizumab (9.9%) versus those receiving IVT ranibizumab (3.1%) ($P = 0.049$).⁵⁰ Of interest is the finding that the median number of injections prior to peak IOP for the patients who

developed sustained elevated IOP was 5, which was lower than the median number of injections for eyes without sustained IOP elevation ($P = 0.002$).⁵⁰

These repeated anti-VEGF injections' side effects clearly demonstrate the need for choroidal hemodynamic studies following multiple anti-VEGF procedures.

Another potential limitation of the study is the lower visual acuity of the patients' fellow eyes, which served as a control (mean \pm SD of logMAR 0.766 ± 0.626 in the fellow eyes as compared with 0.634 ± 0.409 in the study eye). These fellow eyes' low vision was due to advanced nonneovascular/nonactive neovascular AMD. Ideally, control eyes should have normal retinal and choroidal vasculature, but this would have required a much larger study cohort with an age- and gender-matched non-AMD population.

In summary, this small and relatively short-term pilot study in a neovascular AMD population found that OPA, an indirect measure of global choroidal hemodynamics, remains unchanged following IVT bevacizumab. This favorable hemodynamic outcome strengthens the safety profile of bevacizumab off-label use in ophthalmology. Further studies are needed.

Disclosure

The authors report no conflicts of interest in this work.

References

- Saint-Geniez M, Maldonado AE, D'Amore PA. VEGF expression and receptor activation in the choroid during development and in the adult. *Invest Ophthalmol Vis Sci*. 2006;47(7):3135–3142.
- Marneros AG, Fan J, Yokoyama Y, et al. Vascular endothelial growth factor expression in the retinal pigment epithelium is essential for choriocapillaris development and visual function. *Am J Pathol*. 2005;167(5):1451–1459.
- Böker T, Fang T, Steinmetz R. Refractive error and choroidal perfusion characteristics in patients with choroidal neovascularization and age-related macular degeneration. *Ger J Ophthalmol*. 1993;2(1):10–13.
- Remulla J, Gaudio A, Miller S, Sandberg MA. Foveal electroretinograms and choroidal perfusion characteristics in fellow eyes of patients with unilateral neovascular age-related macular degeneration. *Br J Ophthalmol*. 1995;79(6):558–561.
- Zhao J, Frambach D, Lee PP, Lee M, Lopez PF. Delayed macular choriocapillary circulation in age-related macular degeneration. *Int Ophthalmol*. 1995;19(1):1–12.
- Chen JC, Fitzke FW, Pauleikhoff D, Bird AC. Functional loss in age-related Bruch's membrane change with choroidal perfusion defect. *Invest Ophthalmol Vis Sci*. 1992;33(2):334–340.
- Pauleikhoff D, Chen JC, Chisholm IH, Bird AC. Choroidal perfusion abnormality with age-related Bruch's membrane change. *Am J Ophthalmol*. 1990;109(2):211–217.
- Piguat B, Palmvang IB, Chisholm IH, Minassian D, Bird AC. Evolution of age-related macular degeneration with choroidal perfusion abnormality. *Am J Ophthalmol*. 1992;113(6):657–663.
- Grunwald JE, Hariprasad SM, DuPont J, et al. Foveolar choroidal blood flow in age-related macular degeneration. *Invest Ophthalmol Vis Sci*. 1998;39(2):385–390.
- Friedman E, Krupsky S, Lane AM, et al. Ocular blood flow velocity in age-related macular degeneration. *Ophthalmology*. 1995;102(4):640–646.
- Ciulla TA, Harris A, Chung HS, et al. Color Doppler imaging discloses reduced ocular blood flow velocities in nonexudative age-related macular degeneration. *Am J Ophthalmol*. 1999;128(1):75–80.
- Mori F, Konno S, Hikichi T, Yamaguchi Y, Ishiko S, Yoshida A. Pulsatile ocular blood flow study: decreases in exudative age-related macular degeneration. *Br J Ophthalmol*. 2001;85(5):531–533.
- Spraul CW, Lang GE, Ronzani M, Högel J, Lang GK. Reproducibility of measurements with a new slit lamp-mounted ocular blood flow tonograph. *Graefes Arch Clin Exp Ophthalmol*. 1998;36(4):274–279.
- Alm A, Bill A. Ocular circulation. In: Moses R, Hat W, editors. *Adler's Physiology of the Eye*. St Louis (MO): Mosby; 1992:6.
- Langham ME, Farrell RA, O'Brien V, et al. Noninvasive measurement of pulsatile blood flow in the human eye. In: Lambrou GN, Greve EL, editors. *Ocular Blood Flow in Glaucoma*. Amsterdam: Kugler and Ghedini; 1989.
- Funk M, Karl D, Georgopoulos M, et al. Neovascular age-related macular degeneration: intraocular cytokines and growth factors and the influence of therapy with ranibizumab. *Ophthalmology*. 2009;116(12):2393–2399.
- Roh MI, Lim SJ, Ahn JM, Lim JB, Kwon OW. Concentration of cytokines in age-related macular degeneration after consecutive intravitreal bevacizumab injection. *Graefes Arch Clin Exp Ophthalmol*. 2010;248(5):635–640.
- Bakri SJ, Snyder MR, Reid JM, et al. Pharmacokinetics of intravitreal bevacizumab (Avastin). *Ophthalmology*. 2007;114(12):855–859.
- Zhu Q, Ziemssen F, Henke-Fahle S, et al. Vitreous levels of bevacizumab and vascular endothelial growth factor-A in patients with choroidal neovascularization. *Ophthalmology*. 2008;115(10):1750–1755.
- Csaky KG, Gordiyenko N, Rabena MG, Avery RL. *Invest Ophthalmol Vis Sci*. 2007;48:ARVO E-Abstract 4936.
- Boltz A, Luksch A, Wimpfing B, et al. Choroidal blood flow and progression of age-related macular degeneration in the fellow eye in patients with unilateral choroidal neovascularization. *Invest Ophthalmol Vis Sci*. 2010;51(8):4220–4225.
- Adamis AP, Shima DT. The role of vascular endothelial growth factor in ocular health and disease. *Retina*. 2005;25(2):111–118.
- Ferrara N, Damico L, Shams N, Lowman H, Kim R. Development of ranibizumab, an anti-vascular endothelial growth factor antigen binding fragment, as therapy for neovascular age-related macular degeneration. *Retina*. 2006;26(8):859–870.
- Yuan F, Chen Y, Dellian M, Safabakhsh N, Ferrara N, Jain RK. Time-dependent vascular regression and permeability changes in established human tumor xenografts induced by an anti-vascular endothelial growth factor/vascular permeability factor antibody. *Proc Natl Acad Sci U S A*. 1996;93(25):14765–14770.
- Kamba T, Tam BY, Hashizume H, et al. VEGF-dependent plasticity of fenestrated capillaries in the normal adult microvasculature. *Am J Physiol Heart Circ Physiol*. 2006;290(2):H560–H576.
- Inai T, Mancuso M, Hashizume H, et al. Inhibition of vascular endothelial growth factor (VEGF) signaling in cancer causes loss of endothelial fenestrations, regression of tumor vessels, and appearance of basement membrane ghosts. *Am J Pathol*. 2004;165(1):35–52.
- Mordenti J, Cuthbertson RA, Ferrara N, et al. Comparisons of the intraocular tissue distribution, pharmacokinetics, and safety of 125I labeled full-length and Fab antibodies in rhesus monkeys following intravitreal administration. *Toxicol Pathol*. 1999;27(5):536–544.
- Shahar J, Avery RL, Heilweil G, et al. Electrophysiologic and retinal penetration studies following intravitreal injection of bevacizumab (Avastin). *Retina*. 2006;26(3):262–269.
- Heiduschka P, Fietz H, Hofmeister S, et al. Penetration of bevacizumab through the retina after intravitreal injection in the monkey. *Invest Ophthalmol Vis Sci*. 2007;48(6):2814–2823.
- Pieramici DJ, Rabena MD. Anti-VEGF therapy: comparison of current and future agents. *Eye (Lond)*. 2008;22(10):1330–1336.

31. Peters S, Heiduschka P, Julien S, et al. Ultrastructural findings in the primate eye after intravitreal injection of bevacizumab. *Am J Ophthalmol*. 2007;143(6):995–1002.
32. Gibran SK, Sachdev A, Stappler T, Newsome R, Wong D, Hiscott P. Histological findings of a choroidal neovascular membrane removed at the time of macular translocation in a patient previously treated with intravitreal bevacizumab treatment (Avastin). *Br J Ophthalmol*. 2007; 91(5):602–604.
33. Comparison of age-related macular degeneration treatments trials: Lucentis-Avastin trial (CATT). ClinicalTrials.gov identifier: NCT00593450.
34. Boehm AG, Weber A, Pillunat LE, Koch R, Spoerl E. Dynamic contour tonometry in comparison to intracameral IOP measurements. *Invest Ophthalmol Vis Sci*. 2008;49(6):2472–2477.
35. Kaufmann C, Bachmann LM, Thiel MA. Comparison of dynamic contour tonometry with Goldmann applanation tonometry. *Invest Ophthalmol Vis Sci*. 2004;45(9):3118–3121.
36. Halkiadakis I, Patsea E, Chatzimichali K, et al. Comparison of dynamic contour tonometry with Goldmann applanation tonometry in glaucoma practice. *Acta Ophthalmol*. 2009;87(3):323–328.
37. Barleon L, Hoffmann EM, Berres M, Pfeiffer N, Grus FH. Comparison of dynamic contour tonometry and Goldmann applanation tonometry in glaucoma patients and healthy subjects. *Am J Ophthalmol*. 2006; 142(4):583–590.
38. Kaufmann C, Bachmann LM, Robert YC, Thiel MA. Ocular pulse amplitude in healthy subjects as measured by dynamic contour tonometry. *Arch Ophthalmol*. 2006;124(8):1104–1108.
39. Grieshaber MC, Katamay R, Gugleta K, Kochkorov A, Flammer J, Orgül S. Relationship between ocular pulse amplitude and systemic blood pressure measurements. *Acta Ophthalmol*. 2009;87(3):329–334.
40. Romppainen T, Kniestedt C, Bachmann LM, Stürmer J. Ocular pulse amplitude: a new biometrical parameter for the diagnose of glaucoma? [German]. *Ophthalmologe*. 2007;104(3):230–235.
41. Benavente-Pérez A, Hosking SL, Logan NS, Broadway DC. Ocular blood flow measurements in healthy human myopic eyes. *Graefes Arch Clin Exp Ophthalmol*. 2010;248(11):1587–1594.
42. McBrien NA, Gentle A. Role of the sclera in the development and pathological complications of myopia. *Prog Retin Eye Res*. 2003;22(3): 307–338.
43. Pallikaris IG, Kymionis GD, Ginis HS, Kounis GA, Tsilimbaris MK. Ocular rigidity in living human eyes. *Invest Ophthalmol Vis Sci*. 2005; 46(2):409–414.
44. Friedman E, Ivry M, Ebert E, Glynn R, Gragoudas E, Seddon J. Increased scleral rigidity and age-related macular degeneration. *Ophthalmology*. 1989;96(1):104–108.
45. Stalmans I, Harris A, Vanbellingen V, Zeyen T, Siesky B. Ocular pulse amplitude in normal tension and primary open angle glaucoma. *J Glaucoma*. 2008;17(5):403–407.
46. Harris A, Ciulla TA, Pratt LM, et al. The effects of dorzolamide on choroidal and retinal perfusion in non-exudative age related macular degeneration. *Br J Ophthalmol*. 2003;87(6):753–757.
47. Zayit-Soudry S, Zemel E, Loewenstein A, Perlman I. Safety evaluation of repeated intravitreal injections of bevacizumab and ranibizumab in rabbit eyes. *Retina*. 2010;30(4):671–681.
48. Pedersen KB, Møller F, Sjølie AK, Andréasson S. Electrophysiological assessment of retinal function during 6 months of bevacizumab treatment in neovascular age-related macular degeneration. *Retina*. 2010; 30(7):1025–1033.
49. Adelman RA, Zheng Q, Mayer HR. Persistent ocular hypertension following intravitreal bevacizumab and ranibizumab injections. *J Ocul Pharmacol Ther*. 2010;26(1):105–110.
50. Good TJ, Kimura AE, Mandava N, Kahook MY. Sustained elevation of intraocular pressure after intravitreal injections of anti-VEGF agents. *Br J Ophthalmol*. 2010 Aug 11. Doi: 10.2174/1874364101004010028. [Epub ahead of print].

Clinical Ophthalmology

Publish your work in this journal

Clinical Ophthalmology is an international, peer-reviewed journal covering all subspecialties within ophthalmology. Key topics include: Optometry; Visual science; Pharmacology and drug therapy in eye diseases; Basic Sciences; Primary and Secondary eye care; Patient Safety and Quality of Care Improvements. This journal is indexed on PubMed

Submit your manuscript here: <http://www.dovepress.com/clinical-ophthalmology-journal>

Dovepress

Central and CAS, and is the official journal of The Society of Clinical Ophthalmology (SCO). The manuscript management system is completely online and includes a very quick and fair peer-review system, which is all easy to use. Visit <http://www.dovepress.com/testimonials.php> to read real quotes from published authors.