

Outcomes of Cement in Cement Revision, in Revision Total Hip Arthroplasty

Abhijeet Kumar^{1*}, Martyn Porter¹, Nikhil Shah¹, Chakshu Gaba², Paul Siney¹

¹Wrightington, Wigan and Leigh NHS Foundation Trust, Wigan, United Kingdom; ²Institute of Dental Sciences, Bareilly, India

Citation: Kumar A, Porter M, Shah N, Gaba C, Siney P. Outcomes of Cement in Cement Revision, in Revision Total Hip Arthroplasty. Open Access Maced J Med Sci. 2019 Dec 15; 7(23):4059-4065. https://doi.org/10.3889/oamjms.2019.710

Keywords: Cement-in-cement revision; Hip Arthroplasty; Hip Revision; Revision Arthroplasty

***Correspondence:** Abhijeet Kumar, Wrightington, Wigan and Leigh NHS Foundation Trust, Wigan, United Kingdom. E-mail: abhijeet232@gmail.com

Received: 29-Oct-2019; **Revised:** 19-Nov-2019; **Accepted:** 20-Nov-2019; **Online first:** 12-Dec-2019

Copyright: © 2019 Abhijeet Kumar, Martyn Porter, Nikhil Shah, Chakshu Gaba, Paul Siney. This is an open-access article distributed under the terms of the Creative Commons Attribution-NonCommercial 4.0 International License (CC BY-NC 4.0)

Funding: This research did not receive any financial support

Competing Interests: The authors have declared that no competing interests exist

Abbreviations: THA-Total Hip Arthroplasty; THR-Total Hip Replacement; ROM-Range of motion; ORIF-Open Reduction Internal Fixation

Abstract

BACKGROUND: The cement-in-cement femoral revision technique involves removing a femoral component from a well-fixed femoral cement mantle and cementing a new stem into the original mantle. This technique, when carried out for the correct indications, is fast, relatively inexpensive and carries a reduced short-term risk for the patient compared with conventional way of removing well-fixed cement.

AIM: To analyze the effectiveness of cement in cement revision of the femoral stem while performing a revision Total Hip Arthroplasty (THA).

METHODS: We analyzed a consecutive series of 79 patients who underwent a cement in cement revision THA between June-2015 to June-2018. All the patients were retrospectively analysed for operative time, complications, clinical and radiological outcomes.

RESULTS: Average age was 76 years (49-86). The mean follow-up was 16.2 months (12-45). The average operative time was 184.6 (90-290) minutes. Most common indication was cup loosening in 28 patients (42.4%), dislocation in 14 patients (21.2%) and stem loosening in 12 patients (18.2%) Nine patients (11%) had one or more complications. Pre-operatively, 10 patients (13%) had lucency at the cement bone interface. Recent review has shown that 8 of these patients' radiographs have remained unchanged, and in 2 of them there is a slight progression of lucency. Common post op clinical complaints were persistent pain and abductor weakness. Five (6.3%) patients required a re-revision. Most of the patients had a good or satisfactory outcome. No stems showed radiological loosening.

CONCLUSION: The cement-in-cement technique for revision of the femoral component gave promising results and had the advantages of speed, less blood or bone stock loss, less risk of femoral perforation or fracture, decreased financial costs and reduced post op morbidity.

Introduction

In revision total hip arthroplasty (THA), disengaging a well secured femoral component from the femoral cement mantle is a complex and technique sensitive procedure. The process of removal of bonded cement can often result in iatrogenic injury to the host bone, greater chances of bleeding and delayed recovery [1].

To overcome these risk factors, a technique called cement-in-cement revision total hip arthroplasty (THA) is used which involves the removal of a femoral component leaving behind an intact cement mantle, followed by replacement with a new cemented femoral component into the original cement mantle. This technique is widely used to gain access to acetabular

component, to replace an injured femoral part, to modify the length or version of a femoral component or to treat a Vancouver B1 periprosthetic fracture with an intact cement mantle [2]. The technique cement-in-cement includes removal of the old prosthesis, surface preparation of the original cement mantle, followed by drying and insertion of fresh cement onto the old one in order to fix a new prosthesis [3], [4].

There are studies reported in literature suggesting that the new cement mantle is stronger and its shear strength is about 94% of the old one [5], [6]. However, there are studies which suggest that it is difficult to maintain the surface of cement clean and dry, therefore, moisture contamination decreased the shear strength to 85% [3]. Thus, cement in cement technique is not in very common use in all the centres involved with hip arthroplasty [7].

However, there are studies in favour of this technique. In the year 1993, Liebermann et al., [8] in his study highlighted a total of 19 cases of cement within cement femoral revision and found positive results after a period of five years. This was one of the first studies performed on this technique. More recently there have been other studies that have been performed around different parts of the world with larger numbers and longer follow up that have shown encouraging results [4], [9]. Because of promising results with this technique, indications were extended to our unit as well for the use of this technique in revision hip arthroplasty.

So, the aim of the present study is to evaluate the effectiveness of cement-in-cement revision of the femoral stem while performing a revision THA. Through this study we aim to present our results in terms of clinical, radiological, and functional outcomes in the patients undergoing hip revision through this technique with an average follow-up of 3.62 years. We also aimed to evaluate if there was any increase in the rate of intra-operative complications with this technique.

Methods

This is a retrospective study analyzing a consecutive series of 79 cement-in-cement revision Total hip arthroplasties in 75 patients that we undertook in the time period of June 2014-June 2017. All the surgeries were performed in a single centre which is tertiary level referral centre. The patients were identified from the hospital database. The patients admitted in the trust are coded for demographics, diagnosis, and surgical management. Specific codes were applied by the coding department of the trust for characteristics such as hip arthroplasty, revision, in-cement revision, and date of admission. These patients were then analyzed for both post-operative clinical function and radiological outcomes as well as any intra-operative complications.

Patients having a follow-up of less than 2 years were excluded from the study. Therefore, patients undergoing a cement-in-cement revision with a complete clinical and radiological follow-up of at least 2 years were only included in the study. The surgeries were undertaken by a single unit of hip surgeons, all of them were either consultants or fellows in hip surgery. Patients revised for infection were excluded from the study as these cases were not treated by the in-cement revision technique.

The most common indication for revision was acetabular component failure/ aseptic loosening. 38 (51%) hips were revised due to this reason. The common indications for revising the femoral component in these cases were 1) To gain access

and facilitate exposure of the acetabular component, 2) If there was evidence of concomitant femoral component loosening, and 3) if the femoral component appeared to be mal-aligned. Twenty (26%) hips were revised due to instability-either subluxation or dislocation (to modify the version/offset if the femoral component), and 12 (16%) due to aseptic loosening of the femoral component. Other less common indications peri-prosthetic fracture in 4 patients, loss of bone stock in 2 patients, femoral stem fracture in 2 patients and unexplained pain in 1 patient.

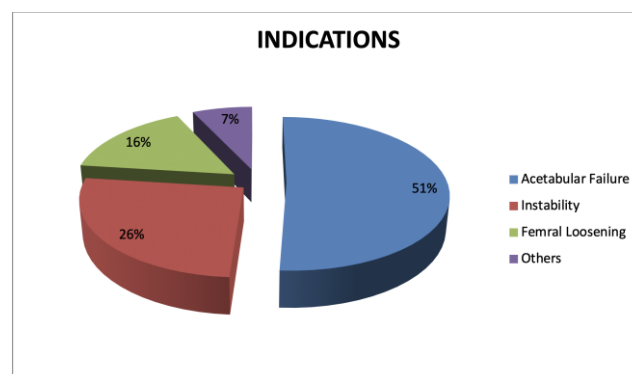


Figure 1: Indications for Hip Revision

The average time of the revision was 12.5 years from the primary surgery (9 months-22 years). This cement-in-cement revision was the first revision in 67 cases (87%) and second revision in 12 cases (13%). C-Stem were used for revision of the stem in 63 cases (80.5%), Exeter stem in 10 cases (12%), C Stem AMT in 4 cases (5%), and Charnley modular prosthesis in 2 cases (2.5%). A variety of femoral stems were removed, most of them were Charnley's prosthesis and C-Stem, others included Exeter, and C-Stem AMT. Most of the patients were operated with posterior approach to the hip joint (95%). Transtrochanteric approach was used in 4 cases. In all the cases the new femoral component used was either the same size or one size smaller to ensure adequate cement mantle. The type of cement used was dependant on the surgeon preference and not dependant on the existing cement type. On many occasions there was no documentation of the cement that was used in the previous surgery.

Clinical and radiological data were collected until the latest follow-up, in the form of radiographs and clinic letters. Patients were reviewed preoperatively, at six weeks and six months post-operatively and annually thereafter. Clinical function of the patients was evaluated for pain, functional outcome, activity restriction, limp, and range of motion of the hip joint. These were documented on the clinic letters at each follow-up visit either in the orthopaedic clinic or with the physiotherapists. Clinical outcome of the patients were evaluated using the Charnley modification of Merle d'Aubigné and Postelscore [10]. Patients scoring 13-16 were considered to have a

good outcome, and patients with a score of 17-18 were considered excellent outcome. Operation notes were used to assess the operative time, estimated blood loss, difficulty of the procedure or complications if any.

Trust PACS system was accessed to evaluate patients' radiology in the form of radiographs. A-P and lateral radiographs of the patient's operated hip were obtained on each follow-up visit. Each radiograph was assessed by two observers reaching a consensus. The radiograph images were stored digitally in the PACS (Patient Archiving and Communication System-General Electric, Amersham, UK). Radiographic analysis was done by taking into consideration, the cement mantle, deficiencies in the mantle, stem subsidence, and presence of radiolucent lines/areas. The cement mantle on the radiographs was analyzed and classified according to Barrack's classification [11]. The deficient mantle was described and recorded according to Gruen zones [12]. The subsidence of the femoral stem was measured in millimetres using Fowler's technique [13]. Radiolucent lines were defined as an area of ≥ 2 mm of lucency occupying $> 50\%$ of any Gruen zone.

Statistical analysis was performed using the SPSS software, version 17.0 (SPSS Inc., Chicago, Illinois) using Wilcoxon's signed ranks test for non-parametric paired data. The level of significance was set at a p-value of less than 0.05, which was adjusted for multiple testing using Bonferroni's method [14].

The operated 79 cases were included for a survival analysis with Kaplan-Meier [15] survival curves. These were analyzed with 95% confidence intervals with endpoints for revision due to aseptic loosening of the stem and revision due to failure from any other cause, i.e., infection, dislocation, aseptic loosening of the stem or acetabular component, fracture etc. There were no cases that were lost to follow-up and hence, the worst-case curve recommended by Bland [13] was not required.

The local research and ethics committee of the institution reviewed and approved this study prior to its initiation.

Operative Technique

The patients were positioned lateral with a flowtron under the contralateral leg. Posterior approach was followed for most of the patients making use of or extending the previous incisions (4 out of 79 patients were operated using trochanteric osteotomy). Antibiotics were given during the time of induction as per trust policy. The hip was dislocated posteriorly and superiorly. The femur was gradually released anteriorly and delivered out of the wound. Once satisfactory exposure had been obtained, the head was knocked out and fluid was sent for culture and sensitivity. Samples from the stem and the acetabulum were also sent later for culture and

sensitivity.

The femoral component was removed by initially removing cement from the shoulder of the prosthesis, gradually working towards the proximal 1/3 of the prosthesis if the stem was well fixed. Moreland stem extractor was generally used to take off the stem completely.

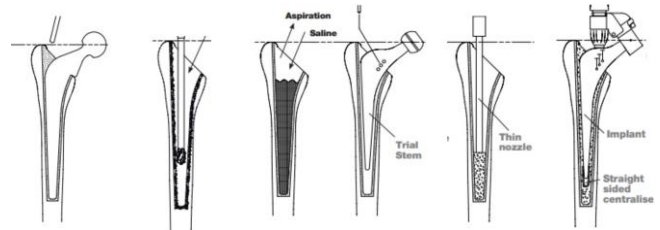


Figure 2: Operative Technique

The cement-bone-interface was meticulously inspected for any signs of loosening, fracture or presence of fibrous tissue. If the integrity of the interface was compromised due to any reason the procedure was abandoned for an appropriate revision procedure.

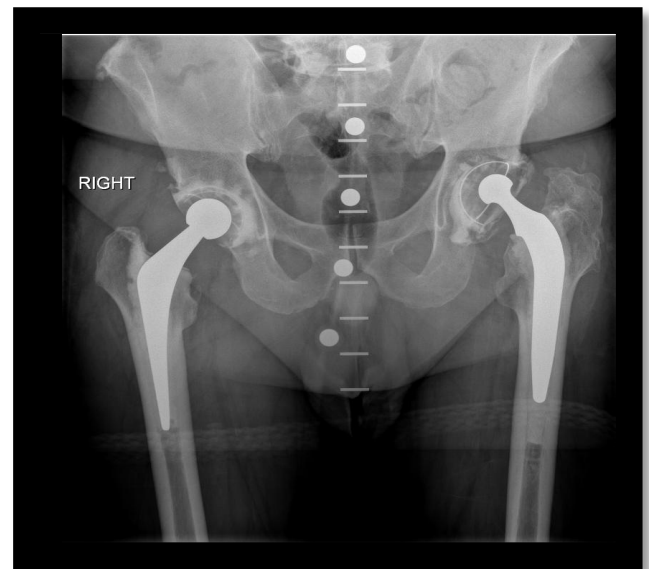


Figure 3: Pre-operative Radiograph

The reconstruction was performed with a stem which fitted into the existing mantle, which in this series, most of the time was C-stem, with the same or smaller size as compared to the original stem. If the anteversion was required to be changed, the original mantle was reshaped with a burr or chisel to optimize the fit and anteversion as required. A trial reduction was performed to assess the stability of the inserted prosthesis. The canal was prepped by washing with pulse lavage and then drying with the a suction cannula inserted deep into the canal and then finally with the help of a ribbon gauze. The stability of the construct was checked by taking the hip into the extremes of range of motion. Standard closure was

performed in layers. Patients were allowed to weight bear as tolerated as soon as possible after the surgery.

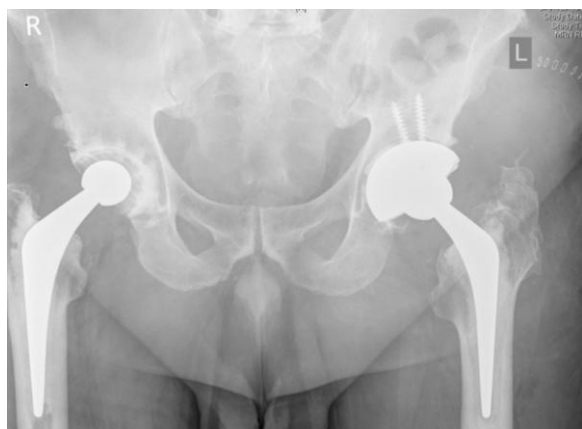


Figure 4: Immediate Post-operative (Left)

The above radiographs are of a 59 year old gentleman operated previously for bilateral hip replacements, with the left hip being revised for acetabular component loosening. The femoral component was revised as well due to evidence of intra-operative loosening of the femoral stem.

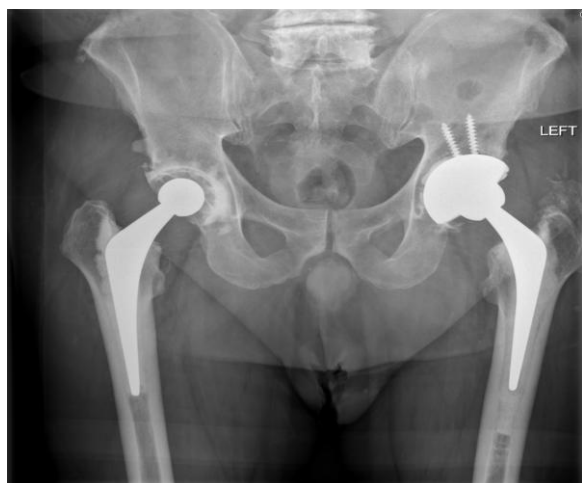

Figure 5: 3.5 years Post-operative

Results

Of the 75 patients, 47 (63%) were males and 28 (37%) were females. Average age of the cohort at the time of surgery was 76 years (39-86). The mean follow-up was 3.62 years (2.1-5.1 years). Mean time of the revision from the index surgery was 12.5 years (9 months-22 years). The average operative time was 184.6 (90-290) minutes. Most of the patients had a good or satisfactory outcome. No stems showed signs of aseptic radiological loosening.

Post-operatively after the cement-in-cement revision, when comparing the clinical function of the patients with regards to the Merle D'Aubigne and modified Postel scoring, 73 cases (92.5%) had a good to excellent outcome (significantly better as compared to the pre-operative score, $p < 0.05$). These criteria were uniform while assessing the patients pre-operatively or in the post-operative period either in the surgeon's clinic or by the physiotherapists. 6 patients (7.5%) complained of persistent pain and abductor weakness, however, their symptoms were still improved compared to their pre-operative status and they did not require any further procedure.

Barrack cement mantle grading was assessed both pre-operative and post-operatively. Pre-operatively 15 hips (19%) were graded Grade C or D according to the Barrack's cement mantle classification. Post-operatively 6 hips (7.5%) were graded Grade C or D according to the Barrack's cement mantle classification. However, this difference was not statistically significant, $p > 0.3$.

Complications

Nine cases (11%) had one or more complications. Two cases were complicated by instability of the hip joint, with the hip dislocating on at least 2 or more occasions. Two cases had an infection, one of them was a superficial infection which was treated with antibiotics and the other patient required a 2-stage revision with antibiotics. Two cases had a peri-prosthetic fracture, one of which was a Vancouver-A treated conservatively, and the other was a Vancouver-B1 treated with an ORIF around the femoral stem. One patient had a sciatic nerve palsy which showed a full recovery at 15 months. One patient had a fracture of the C-stem, 3 years after the revision, who was revised with a new femoral component. Only one patient had an intra-operative fracture which was treated with cerclage wire and delayed weight bearing post-operatively.

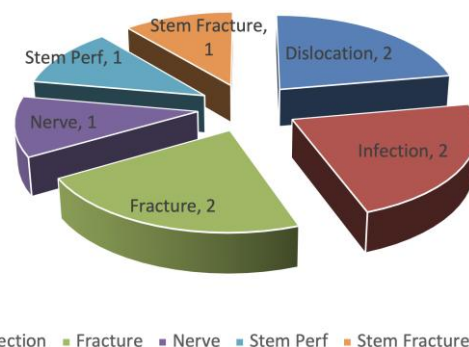


Figure 6: Complications Following Cement-in-Cement Revision

Pre-operatively, 10 patients (13%) had

lucency at the cement bone interface. Recent review has shown that the radiolucencies that were filled with cement at revision did not recur or develop. One patient had new onset lucency at cement-bone interface. This patient also had an intra-operative fracture that was fixed (as mentioned above). This lucency however was stable and has not progressed to a stage of loosening.

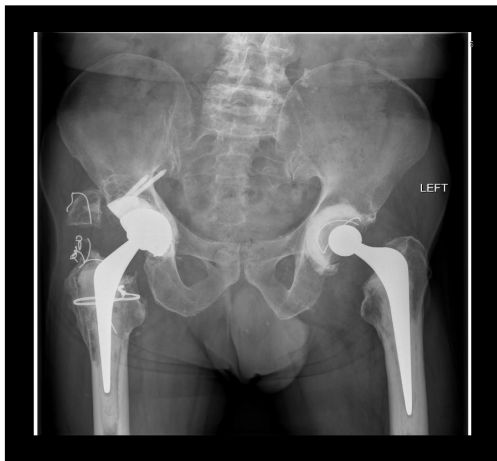
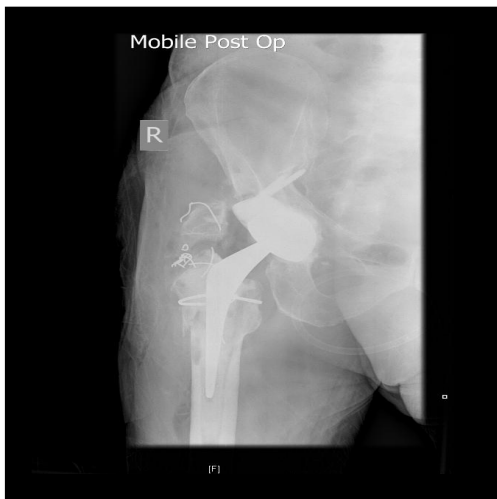
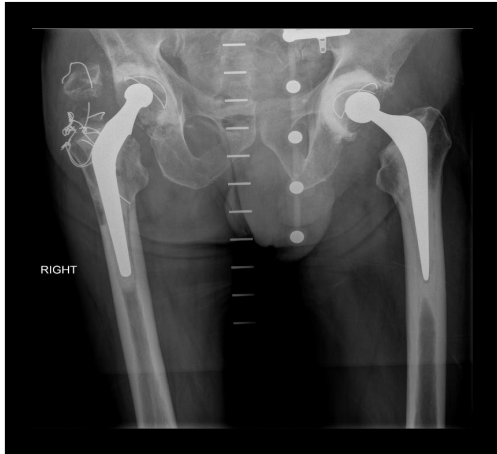Figure 7: Complications- Pre-op Right side (top); Complications- Intra-op fracture treated with Circlage Cable (middle); Complications-3 Years post-op (bottom)

Survivorship Analysis

There was no revision in our study due to aseptic loosening. The Kaplan-Meier survival for this group was therefore 100% (95% CI 91 to 100). The survival rate for revision for all causes (aseptic loosening of the acetabulum/femur, instability, infection, etc.) was 92% (85.4 to 96.9) at 10 years.

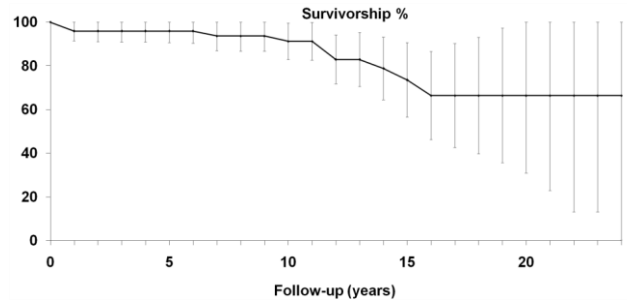


Figure 8: Survivorship Analysis Re-revision

A total of 6 hips (7.5%) needed a further revision, but none due to aseptic loosening of the stem of the femur. The mean time to the second revision was 36.83 months (15-57 months). None of the hips who were revised after a previous first revision had to be re-revised until the last follow-up. The indications for the further revisions were dislocation in 2 cases, and 1 each for infection, peri-prosthetic fracture, stem perforation, and femoral component fracture. These cases required a further cement-in-cement revision which again are doing well both clinically and radiologically.

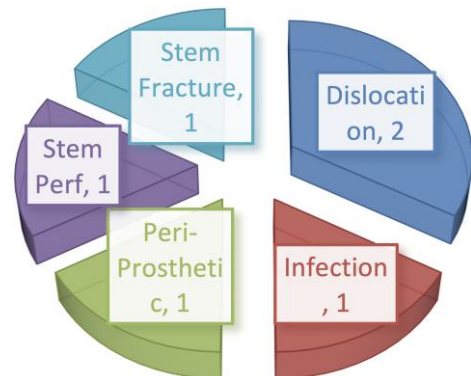


Figure 9: Re-revisions

Discussion

This study of cement-in-cement hip revisions is one of the largest in terms of numbers with a long-term follow-up of clinical and radiological outcomes, showing a very good survivorship at 10 years. There was no evidence of aseptic loosening in the revised cases requiring a further procedure. The school of thought against this technique have been concerned about the durability of the prosthesis and the shear

strength that the cement can sustain after this technique [16], however, our results concur with the studies that have shown good outcome with low failure rate in short to medium term.

The idea of inserting a new prosthesis into an intact cement mantle was first suggested in 1978 to overcome the risks of removing old well bonded cement. These risks range from simple bone loss or perforation to more complex fracture [17]. The removal of femoral cement to permit the placement of an uncemented part is a time consuming procedure requiring the preparation of a cortical window or an extended trochanteric osteotomy thereby, demanding the use of long-stemmed components that are distally fixed. This leads to the extension of the zone of injury into the femoral canal making any sort of revision technique difficult. We feel that to overcome all these issues, cement-in-cement procedure is a very good alternative. Also, there are the obvious advantages of being able to adjust the stem offset and version which allow the hip to be fixed in a more stable position at the time of acetabular revision. Another advantage is that the rate of intra-operative complications in this study was close 1%, which is less when compared to other techniques of revision hip arthroplasty [18].

There have been previous studies at a few other centres that have also achieved positive results with this revision technique [4], [9], [19]. There have also been recent studies postulating its use in conversion of hemiarthroplasty to THA [20]. The results of Duncan et al., in 2009 demonstrated a considerable improvement in hip function scores post-operatively in their study which analyzed 136 hips with a mean follow-up of 8 years, with no cases having aseptic loosening at the cement-bone interface [21]. The study of Staniford et al., in 2017 again showed encouraging results with this technique in their study of 51 patients with a follow-up of close to 7 years. They reported significant improvement in Oxford Hip Scores and Harris Hip scores and their study did not have any revisions due to aseptic loosening of the stem [22].

Although it is possible to re-insert the existing prosthesis, in our study none of the surgeons preferred to do so, to prevent the risk of early fatigue failure in the future. The procedures were performed by a single unit of hip surgeons, a combination of consultants in hip surgery as well as fellows/trainees of hip surgery under supervision, highlighting the fact that this technique is easily disseminated to the trainees as well and not very complicated as compared to complex hip revisions. In the 6 patients who required re-revision, the cement-in-cement technique was used wherever the femoral component was revised, and were doing well clinically and radiologically until the latest follow-up. The stems used in the operations were C stem, C stem AMT, Charnley stem and Exeter stem according to the preference and familiarity of the surgeon. The complications or clinical/radiological results with each

of the stems individually were comparable and statistically insignificant from each other.

In a lot of cases, the cement used during the index surgery was not recorded. In this study whilst performing the revision, the use of cement was mostly dependant on the surgeon preference. The cements used were Copal, CMW1, CMW2 and Palacos. The complications and clinical results were again comparable when a subgroup analysis was performed within the individual cement types and were found to be statistically insignificant from each other. Also, the use of these cement types when mixed with a different cement type during the index surgery did not seem to have any adverse effects. Again, the use of any antibiotics mixed with cement didn't seem to predispose the hip to any complications clinically or radiologically. There is also evidence in biomechanical in vitro studies regarding the fact that mixing of different brands of cement does not cause any inadvertent complications at the cement-bone or metal-cement interfaces [5]. Different brands of cements even when they are mixed, all form a solid block of PMMA (Polymethylmethacrylate), thus serving the same purpose. Thus, it would appear acceptable to mix different cement types when carrying out the revision as per the preference of the surgeon.

In our study the most common indication for performing this procedure was the removal of femoral component to facilitate acetabular exposure, revision of the stem to change version, offset or leg length, and aseptic loosening of the femoral stem. The major contraindications to this technique are radiological loosening present at the cement bone interface and infection. If there was pre-op evidence of cement loosening below the lesser trochanter, then this procedure was not carried out. Assessment of the cement mantle and the cement-bone interface is an important pre-operative step before taking the final decision of performing the cement-in-cement revision.

The number of cases requiring hip revisions is on an upward trend and thus we feel that the results of this study and technique are relevant to today's practice. This trend is only predicted to go further up carrying along with it an increasing economic burden on the healthcare system. This particular technique described in the above research presents a cost and time-effective option for revision hip arthroplasties in suitable patients.

Limitations: This study has a few limitations; firstly having larger numbers with a longer follow-up would make the results of this study more powerful and improve its reproducibility. Secondly, we have calculated the survivorship using the Kaplan-Meier analysis using the mean follow-up in the study (taking also into account the minimum follow-up of 2 years). The data is then extrapolated up to 10 years, to predict the survivorship at the 10 year point.

In conclusion, the technique of cement-in-

cement revision in our study and group of patients has shown promising results. It has the advantage of being relatively quicker. There is less blood loss and less bone stock loss associated with this procedure. There is less risk of femoral perforation or a fracture. There is also the advantage of decreased financial costs and reduced post op morbidity. The skill is also easily transferrable and can be performed by surgeons of different levels of experience. In the modern day scenario with revision arthroplasties on the rise, this technique is definitely something worth considering for carefully selected patients.

References

- Quinlan JF, O'Shea K, Doyle F, Brady OH. In-cement technique for revision hip arthroplasty. *The Journal of bone and joint surgery. British volume.* 2006; 88(6):730-3. <https://doi.org/10.1302/0301-620X.88B6.17037> PMID:16720764
- Holt G, Hook S, Hubble M. Revision total hip arthroplasty: the femoral side using cemented implants. *International orthopaedics.* 2011; 35(2):267-73. <https://doi.org/10.1007/s00264-010-1167-5> PMID:21165618 PMCID:PMC3032104
- Li P, Ingle P, Dowell J. Cement-within-cement revision hip arthroplasty; should it be done? *The Journal Of Bone And Joint Surgery. British Volume.* 78-B, 1996:809-811. <https://doi.org/10.1302/0301-620X.78B5.0780809>
- Cnudde PH, Kärrholm J, Rolfson O, Timperley AJ, Mohaddes M. Cement-in-cement revision of the femoral stem: analysis of 1179 first-time revisions in the Swedish Hip Arthroplasty Register. *The bone & joint journal.* 2017; 99(4_Supple_B):27-32. <https://doi.org/10.1302/0301-620X.99B4.BJJ-2016-1222.R1> PMID:28363891
- Weinrauch PC, Bell C, Wilson L, Goss B, Lutton C, Crawford RW. Shear properties of bilaminar polymethylmethacrylate cement mantles in revision hip joint arthroplasty. *The Journal of arthroplasty.* 2007; 22(3):394-403. <https://doi.org/10.1016/j.arth.2006.04.010> PMID:17400096
- Keeling P, Prendergast PJ, Lennon AB, Kenny PJ. Cement-in-cement revision hip arthroplasty: an analysis of clinical and biomechanical literature. *Archives of orthopaedic and trauma surgery.* 2008; 128(10):1193-9. <https://doi.org/10.1007/s00402-007-0470-0> PMID:17940780
- Weber KL, Callaghan JJ, Goetz DD, Johnston RC. Revision of a failed cemented total hip prosthesis with insertion of an acetabular component without cement and a femoral component with cement. A five to eight-year follow-up study. *JBJS.* 1996; 78(7):982-4. <https://doi.org/10.2106/00004623-199607000-00002> PMID:8698734
- Lieberman JR, Moeckel BH, Evans BG, Salvati EA, Ranawat CS. Cement-within-cement revision hip arthroplasty. *The Journal of bone and joint surgery. British volume.* 1993; 75(6):869-71. <https://doi.org/10.1302/0301-620X.75B6.8245073>
- Mandziak DG, Howie DW, Neale SD, McGee MA. Cement-within-cement stem exchange using the collarless polished double-taper stem. *The Journal of arthroplasty.* 2007; 22(7):1000-6. <https://doi.org/10.1016/j.arth.2007.06.001> PMID:17920472
- Ugino FK, Righetti CM, Alves DP, Guimarães RP, Honda EK, Ono NK. Evaluation of the reliability of the Modified Merle d'Aubigné and Postel Method. *Acta ortopedicabrasileira.* 2012; 20(4):213-7. <https://doi.org/10.1590/S1413-78522012000400004> PMID:24453605 PMCID:PMC3718401
- Barrack RL, Mulroy Jr RD, Harris WH. Improved cementing techniques and femoral component loosening in young patients with hip arthroplasty. A 12-year radiographic review. *The Journal of bone and joint surgery. British volume.* 1992; 74(3):385-9. <https://doi.org/10.1302/0301-620X.74B3.1587883>
- Gruen TA, McNeice GM, Amstutz HC. "Modes of failure" of cemented stem-type femoral components: a radiographic analysis of loosening. *Clinical orthopaedics and related research.* 1979; 141:17-27. <https://doi.org/10.1097/00003086-197906000-00002>
- Fowler JL, Gie GA, Lee AJ, Ling RS. Experience with the Exeter total hip replacement since 1970. *The Orthopedic Clinics of North America.* 1988; 19(3):477-89.
- Prescott RJ. Book Review: An Introduction To Medical Statistics. Martin Bland, Oxford University Press, Oxford, 1995. *Statistics in Medicine.* 1997; 16(19):2262-3. [https://doi.org/10.1002/\(SICI\)1097-0258\(19971015\)16:19<2262::AID-SIM659>3.0.CO;2-Q](https://doi.org/10.1002/(SICI)1097-0258(19971015)16:19<2262::AID-SIM659>3.0.CO;2-Q)
- Kaplan EL, Meier P. Estimarea neparametrica a observatiilor incomplete. [Nonparametric estimation from incomplete observations]. *Journal of American de Statistical Association.* 1958; 53(282):457-81. <https://doi.org/10.1080/01621459.1958.10501452>
- AGoto K, Kawanabe K, Akiyama H, Morimoto T, Nakamura T. Clinical and radiological evaluation of revision hip arthroplasty using the cement-in-cement technique. *The Journal of bone and joint surgery. British volume.* 2008; 90(8):1013-8. <https://doi.org/10.1302/0301-620X.90B8.20388> PMID:18669955
- Callaghan JJ, Rosenberg AG, Rubash HE, editors. *The adult hip.* Lippincott Williams & Wilkins; 2007.
- Issack PS, Guerin J, Butler A, Marwin SE, Bourne RB, Rorabeck CH, Barrack RL, Di Cesare PE. Intraoperative complications of revision hip arthroplasty using a porous-coated, distally slotted, fluted femoral stem. *Clinical Orthopaedics and Related Research®.* 2004; 425:173-6. <https://doi.org/10.1097/00003086-200408000-00024> PMID:15292804
- Mandziak DG, Howie DW, Neale SD, McGee MA. Cement-within-cement stem exchange using the collarless polished double-taper stem. *The Journal of arthroplasty.* 2007; 22(7):1000-6. <https://doi.org/10.1016/j.arth.2007.06.001> PMID:17920472
- Mounsey EJ, Williams DH, Howell JR, Hubble MJ. Revision of hemiarthroplasty to total hip arthroplasty using the cement-in-cement technique. *The bone & joint journal.* 2015; 97(12):1623-7. <https://doi.org/10.1302/0301-620X.97B12.35814> PMID:26637675
- Duncan WW, Hubble MJ, Howell JR, Whitehouse SL, Timperley AJ, Gie GA. Revision of the cemented femoral stem using a cement-in-cement technique: a five-to 15-year review. *The Journal of bone and joint surgery. British volume.* 2009; 91(5):577-82. <https://doi.org/10.1302/0301-620X.91B5.21621> PMID:19407288
- Sandiford NA, Jameson SS, Wilson MJ, Hubble MJ, Timperley AJ, Howell JR. Cement-in-cement femoral component revision in the multiply revised total hip arthroplasty: results with a minimum follow-up of five years. *The bone & joint journal.* 2017; 99(2):199-203. <https://doi.org/10.1302/0301-620X.99B2.BJJ-2016-0076.R1> PMID:28148661