

# Osseous Defects Seen in Patients with Anterior Shoulder Instability

Nobuyuki Yamamoto, MD, Eiji Itoi, MD

*Department of Orthopaedic Surgery, Tohoku University School of Medicine, Sendai, Japan*

Shoulder surgeons need to be aware of the critical size of the glenoid or humeral osseous defects seen in patients with anterior shoulder instability, since the considerable size of osseous defect is reported to cause postoperative instability. Biomechanical studies have identified the size of the osseous defect which affects stability. Since engagement always occurs between a Hill-Sachs lesion and the glenoid rim, when considering the critical size of the Hill-Sachs lesion, we have to simultaneously consider the size of the glenoid osseous defect. With the newly developed concept of the glenoid track, we are able to evaluate whether a large Hill-Sachs lesion is an “on-track” or “off-track” lesion, and to consider both osseous defects together. In case of an off-track Hill-Sachs lesion, if the glenoid defect is less than 25%, no treatment is required. In this case, the Latarjet procedure or arthroscopic remplissage procedure can be a treatment option. However, if the glenoid defect is more than 25%, treatment such as bone grafting is required. This will convert an off-track lesion to an on-track lesion. After the bone graft or Latarjet procedure, if the Hill-Sachs lesion persists as off-track, then further treatment is necessitated. In case with an on-track Hill-Sachs lesion and a less than 25% glenoid defect, arthroscopic Bankart repair alone is enough.

**Keywords:** *Shoulder, Biomechanics, Bony defect*

The incidence of the glenoid and humeral osseous defects is very high in patients with recurrent anterior dislocation of the shoulder.<sup>1-4)</sup> Recent clinical studies<sup>5,6)</sup> pointed out that these osseous defects cause postoperative instability. Shoulder surgeons need to be aware of the critical size of these osseous defects since the surgical procedure depends on the size of the glenoid or the humeral osseous defect. Biomechanical studies using cadaveric shoulders have identified what size of the osseous defect affects the stability, and in which position of the arm.<sup>7-9)</sup> In this review article, we mainly introduce the recent studies related to the glenoid and humeral osseous defects seen in patients with anterior shoulder instability. In addition, we describe the diagnosis and the treatment strategy for the osseous defects that need to be treated.

## WHEN IS THE GLENOID OR HUMERAL OSSEOUS DEFECT CREATED?

Although the glenoid and humeral osseous defects are common injuries associated with anterior dislocation of the shoulder,<sup>10,11)</sup> there have been no reports demonstrating when these osseous defects occur. Some believe that they are created at the time of dislocation, whereas some state that they occur during reduction or a little later after dislocation. Kroner et al.,<sup>12)</sup> in a large-scale epidemiological study of 250,000 subjects, investigated the mechanism of injury in 216 patients with anterior shoulder dislocation. They found that the most common mechanism of injury (46% of all injuries) was a blow against the shoulder. However, there was no description of the specific arm position in their report. Recently, the arm positions have been studied from video analysis, which demonstrates that the dislocation occurred in positions other than abduction and external rotation.<sup>13,14)</sup>

A Hill-Sachs lesion (HSL) in patients with chronic anterior dislocation of the shoulder is greater than that

Received April 12, 2015; Accepted May 26, 2015

Correspondence to: Nobuyuki Yamamoto, MD

Department of Orthopaedic Surgery, Tohoku University School of Medicine, 1-1 Seiryomachi, Aoba-ku, Sendai 980-8574, Japan

Tel: +81-22-717-7245, Fax: +81-22-717-7248

E-mail: koyomoe@med.tohoku.ac.jp

Copyright © 2015 by The Korean Orthopaedic Association

This is an Open Access article distributed under the terms of the Creative Commons Attribution Non-Commercial License (<http://creativecommons.org/licenses/by-nc/4.0>) which permits unrestricted non-commercial use, distribution, and reproduction in any medium, provided the original work is properly cited.

Clinics in Orthopedic Surgery • pISSN 2005-291X eISSN 2005-4408

seen in patients with acute dislocation.<sup>15)</sup> A recent report indicated that the HSL was significantly larger if the time from dislocation until reduction exceeded 5 hours.<sup>16)</sup> Considering these reports, we may be able to state that the HSL is created when the humeral head is compressed against the glenoid rim after the dislocation, and it increases as the compression time lengthens. Clinicians must understand that when patients who sustain dislocation come to an emergency room, their shoulders are adducted and internally rotated. Based on these facts, it can be speculated that the HSL is created during the process to adduction and internal rotation after dislocation.

The computed tomography (CT) images of 100 shoulders of 100 patients, with recurrent anterior dislocation of the shoulder, were investigated by Kawakami et al.,<sup>17)</sup> using an image analyzing software to determine the shoulder position when a HSL is created. They created three-dimensional surface bone models of the scapula and humerus separately; the humerus was then moved such that the longitudinal axis of the HSL and the anterior glenoid rim fit each other. Subsequently, the arm positions were measured three-dimensionally. The average arm position in which a HSL was created was demonstrated to be 74° of abduction, 27° of external rotation, and 3° of horizontal adduction. If the HSL is created at the time of dislocation, the dislocation position should be the same as this position. However, their data showed that the arm position in which the HSL had been created was not the so-called dislocation position (abduction and maximum external rotation), but at a much lower angle of abduction and external rotation. There are two possibilities to interpret these results. One is that the dislocation occurs in lower angle of abduction and external rotation position. Another possibility is that the HSL is created not at the time of dislocation, but a little after the dislocation. Further studies are needed to clarify this point.

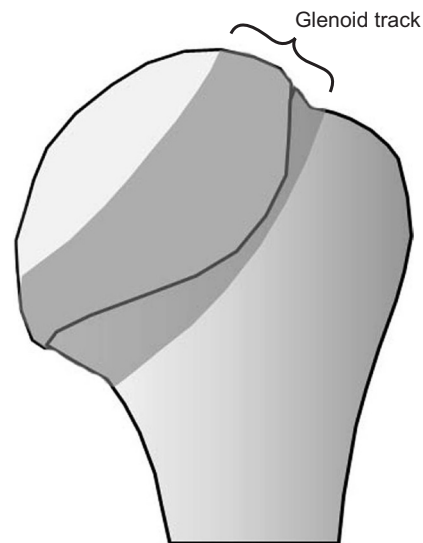
### LOCATION AND SIZE OF THE GLENOID AND HUMERAL OSSEOUS DEFECTS

It is generally thought that a glenoid osseous defect occurs anteroinferiorly from surgical or radiological findings. However, recent studies<sup>18-21)</sup> have found that the glenoid defect was located anteriorly rather than anteroinferiorly. Both Griffith et al.<sup>18)</sup> and, more recently, Saito et al.<sup>19)</sup> described the glenoid osseous defect as being located anteriorly at approximately the three o'clock position in the right shoulder. However, since the glenoid inclines anteriorly in the sagittal plane relative to the trunk, the true location of the glenoid defect is anteroinferior, relative to the scapula.

The location of HSLs was quantitatively measured on CT images by Saito et al.<sup>19)</sup> Their data showed that the HSL existed in the area between 0 and 24 mm from the top of the humeral head; the inferior portion of the HSL overlaps the bare area when it extends beyond 19 mm from the top of the humeral head. The HSL was oriented toward 6:46 at the top and 8:56 at the bottom of the lesion, with an average orientation of 7:58 ± 0:48. The average depth of the HSL was 5.0 ± 4.0 mm.

### CRITICAL SIZE OF THE GLENOID AND HUMERAL OSSEOUS DEFECTS

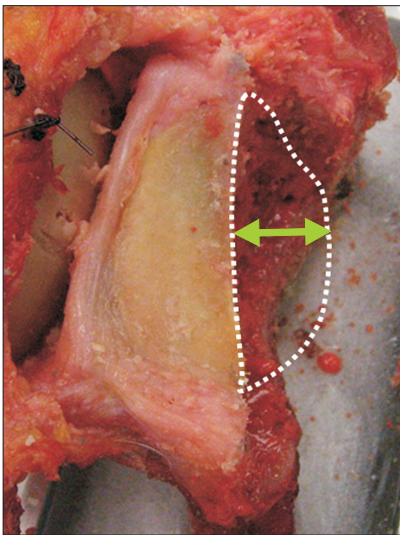
The depth,<sup>22)</sup> size,<sup>23)</sup> and volume<sup>22)</sup> of the HSL have been thought to be parameters to estimate the risk of engagement. However, they cannot be used for the evaluation of the engagement. The relative location of the HSL and the glenoid is the most important parameter. In a cadaver study, Yamamoto et al.<sup>9)</sup> demonstrated that the relative location of the HSL to the glenoid should be used. The location of the glenoid was marked on the humeral head, with the arm elevating along the end-range of glenohumeral motion. As the arm was elevated at 0°, 30°, and 60° with maximum external rotation and horizontal extension, the contact area of the glenoid shifted from inferomedial to superolateral portion of the humeral head, creating a zone of contact. The distance from the medial margin of the footprint of the rotator cuff to the medial margin of this contact area at 60° of abduction was 18.4 ± 2.5 mm, which was equivalent to 84% ± 14% of the glenoid width. They



**Fig. 1.** Glenoid track. The glenoid track is defined as a zone of contact of the glenoid on the humeral head.

defined this contact zone as the glenoid track (Fig. 1). Using this new concept, we are able to evaluate whether or not there is a risk of engagement. If the HSL remains within the glenoid track, there is no risk of engagement between the HSL and the glenoid. However, if the HSL extends medially over the glenoid track, there is a risk of engagement. Omori et al.<sup>24)</sup> measured the glenoid track in live shoulders. They demonstrated that the width of the glenoid track in live shoulders was 83% of the glenoid width at 90° of abduction, which was very close to the measurement in Yamamoto<sup>9)</sup>'s cadaveric study.

Recently, Di Giacomo et al.<sup>25)</sup> have developed a method that uses the concept of the glenoid track to determine whether the HSL will engage the glenoid rim with or without an anterior glenoid osseous defect. If the HSL engages,



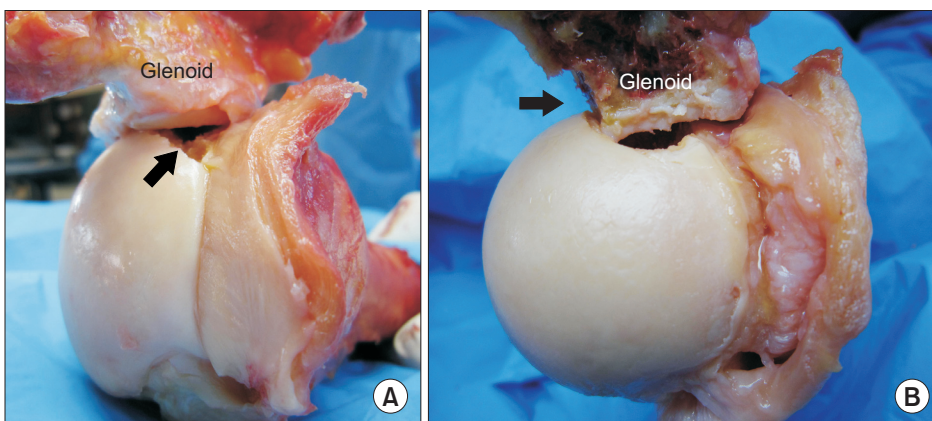
**Fig. 2.** The critical size of a glenoid osseous defect. The critical size of an anterior glenoid defect was biomechanically demonstrated to be the one with a width that was at least 25% of the glenoid width.

it is called an “off-track” HSL; if it does not engage, it is an “on-track” lesion. On the basis of this quantitative method, they have developed a treatment paradigm with specific surgical criteria for all patients with anterior instability, both with and without bipolar osseous defect. More recently, Cook et al.<sup>26)</sup> validated the on-track vs. off-track concept in anterior shoulder instability, and they concluded that osseous defect defined as on-track or off-track is a better predictor of failed arthroscopic stabilization than solely quantifying glenoid osseous defect.

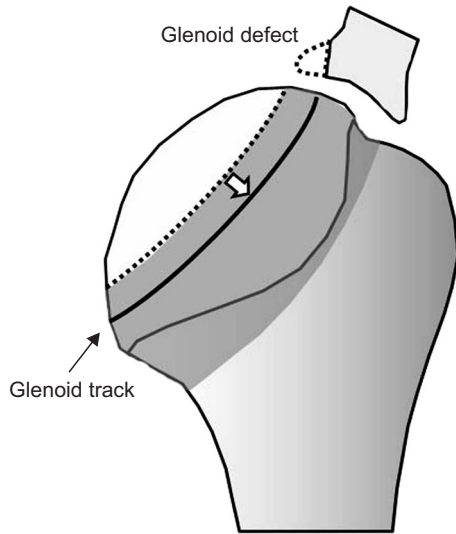
Considering the glenoid osseous defect, since the true location of the glenoid is demonstrated to be anterior, we need to re-evaluate the effect of bony defect of the glenoid on anterior shoulder stability. In a biomechanical study, Yamamoto et al.<sup>7)</sup> reported that reconstruction of the glenoid concavity might be necessary in shoulders with an anterior glenoid defect of at least 26% of the glenoid width. In their study, all the soft tissues, including the labrum and the capsule, were removed. They performed a similar biomechanical study, taking the soft tissue contribution into consideration.<sup>8)</sup> They reported that the critical size of an anterior glenoid defect was the one with a thickness that was at least 25% of the glenoid width (Fig. 2). Thus, in cases with a large glenoid defect (> 25% of the glenoid width), bone grafting is necessary as a surgical treatment.

### CONSIDERING BIPOLAR LESION TOGETHER

When we consider about the engaging of the HSL, an important point to remember is that engagement always occurs between the HSL and the glenoid rim. This means both are responsible for the engagement. In fact, the engagement is known to be observed more frequently if there is a large glenoid defect (Fig. 3).<sup>27)</sup> Therefore, when considering the critical size of the HSL, we need to consider the glenoid osseous defect as well. In a new concept proposed



**Fig. 3.** (A) Photograph of non-engagement in the cadaveric shoulder. This Hill-Sachs lesion (arrow) is small and is located within the contact area between the glenoid and humeral head. (B) Photograph of engagement. Even though the Hill-Sachs lesion is small, engagement occurs in case with a large glenoid defect (arrow).



**Fig. 4.** Glenoid track in a case with glenoid defect. In a case with glenoid defect, the width of the true glenoid track (black line) is decreased. The defect width should be subtracted from the glenoid width.

by Yamamoto et al.,<sup>9)</sup> the glenoid track enables us to take both lesions into consideration at the same time. In case of a glenoid defect, the defect width should be subtracted from 83% of the glenoid width, which is the width of the glenoid track measured in live patients (Fig. 4).

### TREATMENT STRATEGY FOR A LARGE GLENOID AND HUMERAL OSSEOUS DEFECT

Kurokawa et al.<sup>11)</sup> reported that in their series of 100

shoulders with recurrent anterior dislocation, 94 shoulders had HSL, and 7 of them (7.4%) were defined as off-track HSL. Their study showed that there are two categories of off-track HSL: the large and wide type, and the narrow but medially located type. There is a positive relationship between the sizes of the glenoid defect and HSL: the larger the glenoid defect, the larger the HSL. Thus, if we find a large glenoid osseous defect, we need to confirm whether the HSL is an on-track or off-track lesion. If the glenoid defect is less than 25%, which is biomechanically demonstrated to be a critical size,<sup>8)</sup> no treatment is required for this defect. Such cases are treated only for HSL. The Latarjet procedure or arthroscopic remplissage procedure can also be treatment options. If the Latarjet procedure is selected, we can expect to enlarge the glenoid track by bone grafting. In the arthroscopic remplissage procedure, engagement can be avoided by filling the humeral head defect with the infraspinatus tendon. If the glenoid defect is more than 25%, treatment such as bone grafting is the therapy of choice. In these cases, the Latarjet procedure is recommended, which will reconstruct the glenoid concavity, at the same time converting the HSL from an off-track lesion to an on-track lesion. If the HSL still remains off-track even after the Latarjet, then remplissage or bone graft needs to be performed in addition to the Latarjet.

### CONFLICT OF INTEREST

No potential conflict of interest relevant to this article was reported.

### REFERENCES

- Henry JH, Genung JA. Natural history of glenohumeral dislocation: revisited. *Am J Sports Med.* 1982;10(3):135-7.
- Hill HA, Sachs MD. The grooved defect of the humeral head: a frequently unrecognized complication of dislocations of the shoulder joint. *Radiology.* 1940;35(6):690-700.
- Hovelius L. Anterior dislocation of the shoulder in teenagers and young adults: five-year prognosis. *J Bone Joint Surg Am.* 1987;69(3):393-9.
- Hovelius L, Eriksson K, Fredin H, et al. Recurrences after initial dislocation of the shoulder: results of a prospective study of treatment. *J Bone Joint Surg Am.* 1983;65(3):343-9.
- Burkhart SS, Debeer JF, Tehrany AM, Parten PM. Quantifying glenoid bone loss arthroscopically in shoulder instability. *Arthroscopy.* 2002;18(5):488-91.
- Boileau P, Villalba M, Hery JY, Balg F, Ahrens P, Neyton L. Risk factors for recurrence of shoulder instability after arthroscopic Bankart repair. *J Bone Joint Surg Am.* 2006;88(8):1755-63.
- Yamamoto N, Itoi E, Abe H, et al. Effect of an anterior glenoid defect on anterior shoulder stability: a cadaveric study. *Am J Sports Med.* 2009;37(5):949-54.
- Yamamoto N, Muraki T, Sperling JW, et al. Stabilizing mechanism in bone-grafting of a large glenoid defect. *J Bone Joint Surg Am.* 2010;92(11):2059-66.
- Yamamoto N, Itoi E, Abe H, et al. Contact between the glenoid and the humeral head in abduction, external rotation, and horizontal extension: a new concept of glenoid track. *J Shoulder Elbow Surg.* 2007;16(5):649-56.

10. Saito H, Itoi E, Sugaya H, Minagawa H, Yamamoto N, Tuoheti Y. Location of the glenoid defect in shoulders with recurrent anterior dislocation. *Am J Sports Med.* 2005;33(6):889-93.
11. Kurokawa D, Yamamoto N, Nagamoto H, et al. The prevalence of a large Hill-Sachs lesion that needs to be treated. *J Shoulder Elbow Surg.* 2013;22(9):1285-9.
12. Kroner K, Lind T, Jensen J. The epidemiology of shoulder dislocations. *Arch Orthop Trauma Surg.* 1989;108(5):288-90.
13. Crichton J, Jones DR, Funk L. Mechanisms of traumatic shoulder injury in elite rugby players. *Br J Sports Med.* 2012;46(7):538-42.
14. Longo UG, Huijsmans PE, Maffulli N, Denaro V, De Beer JF. Video analysis of the mechanisms of shoulder dislocation in four elite rugby players. *J Orthop Sci.* 2011;16(4):389-97.
15. Flatow EL, Miller SR, Neer CS 2nd. Chronic anterior dislocation of the shoulder. *J Shoulder Elbow Surg.* 1993;2(1):2-10.
16. Denard PJ, Dai X, Burkhart SS. Increasing preoperative dislocations and total time of dislocation affect surgical management of anterior shoulder instability. *Int J Shoulder Surg.* 2015;9(1):1-5.
17. Kawakami J, Yamamoto N, Nagamoto H, Shiota Y, Mineta M, Itoi E. In which arm position is a Hill-Sachs lesion created? Paper presented at: 2015 Annual Meeting, American Academy of Orthopaedic Surgeons; 2015 Mar 24-28; Las Vegas, USA.
18. Griffith JF, Antonio GE, Tong CW, Ming CK. Anterior shoulder dislocation: quantification of glenoid bone loss with CT. *AJR Am J Roentgenol.* 2003;180(5):1423-30.
19. Saito H, Itoi E, Minagawa H, Yamamoto N, Tuoheti Y, Seki N. Location of the Hill-Sachs lesion in shoulders with recurrent anterior dislocation. *Arch Orthop Trauma Surg.* 2009;129(10):1327-34.
20. Stevens KJ, Preston BJ, Wallace WA, Kerslake RW. CT imaging and three-dimensional reconstructions of shoulders with anterior glenohumeral instability. *Clin Anat.* 1999;12(5):326-36.
21. Bigliani LU, Newton PM, Steinmann SP, Connor PM, McLlveen SJ. Glenoid rim lesions associated with recurrent anterior dislocation of the shoulder. *Am J Sports Med.* 1998;26(1):41-5.
22. Sommaire C, Penz C, Clavert P, Klouche S, Hardy P, Kempf JF. Recurrence after arthroscopic Bankart repair: is quantitative radiological analysis of bone loss of any predictive value? *Orthop Traumatol Surg Res.* 2012;98(5):514-9.
23. Rowe CR, Zarins B, Ciullo JV. Recurrent anterior dislocation of the shoulder after surgical repair: apparent causes of failure and treatment. *J Bone Joint Surg Am.* 1984;66(2):159-68.
24. Omori Y, Yamamoto N, Koishi H, et al. Measurement of the glenoid track in vivo as investigated by 3-dimensional motion analysis using open MRI. *Am J Sports Med.* 2014;42(6):1290-5.
25. Di Giacomo G, Itoi E, Burkhart SS. Evolving concept of bipolar bone loss and the Hill-Sachs lesion: from “engaging/non-engaging” lesion to “on-track/off-track” lesion. *Arthroscopy.* 2014;30(1):90-8.
26. Cook JB, Shaha JS, Rowles DJ, Bottoni CR, Shaha S, Tokish JM. Clinical validation of the “on-track” vs. “off-track” concept in anterior glenohumeral instability. Paper presented at: 2015 Annual Meeting, American Academy of Orthopaedic Surgeons; 2015 Mar 24-28; Las Vegas, USA.
27. Burkhart SS, De Beer JF. Traumatic glenohumeral bone defects and their relationship to failure of arthroscopic Bankart repairs: significance of the inverted-pear glenoid and the humeral engaging Hill-Sachs lesion. *Arthroscopy.* 2000;16(7):677-94.