

Crab louse

Arun Prasath Palanisamy, Kamalakannan Kutuwa Kanakaram, Sivasubramanian Vadivel, Srivenkateswaran Kothandapany

Department of Dermatology and STD, Vinayaka Mission's Medical College and Hospital, Karaikal, Puducherry, India

Access this article online

Website: www.idoj.in

DOI: 10.4103/2229-5178.164475

Quick Response Code:



Address for correspondence:

Dr. Arun Prasath Palanisamy, Department of Dermatology and STD, Vinayaka Mission's Medical College and Hospital, Karaikal - 609 609, Puducherry, India. E-mail: drmuhil_irt@yahoo.co.in

A 25-year-old married male presented with itching in the pubic area since two weeks. He gave a history of extramarital contact three weeks ago. On examination he was found to have excoriated papules in lower abdomen, pubic area and thighs. Close inspection revealed multiple brown colored nits attached to the pubic hairs. A clinical diagnosis of phthiriasis pubis was made. Other hair bearing areas including axilla, beard, mustache, eyelids and scalp were examined and were found to be free from infestation. He had no genital ulcer, urethral discharge or inguinal adenopathy. Serology for syphilis and retroviral status were non reactive. Microscopic examination of pubic hair revealed the presence of pubic louse with characteristic morphology and a blood filled esophagus indicating a recent blood meal [Figure 1].

The Crab louse or *Phthirus pubis* is a dorsoventrally flattened, wingless insect of order *Anoplura* and family *Phthiridae*. Adult louse measures about 1–2 mm with three parts namely head, thorax with three pairs of legs, and abdomen. The terminal part of each leg has claw-like appendages whose grasp is designed to match the diameter of pubic or axillary hair. The louse buries sharp mouthpiece stylets inside the pubic hair follicle to obtain a constant blood supply.^[1]

Sexual transmission is considered the most important means of crab louse transmission.^[2] However, there are documented cases of transmission from toilet seats, beds, and egg-infested loose hairs dropped by infested persons on shared objects. Treatment options include 1% permethrin rinse, 5% permethrin

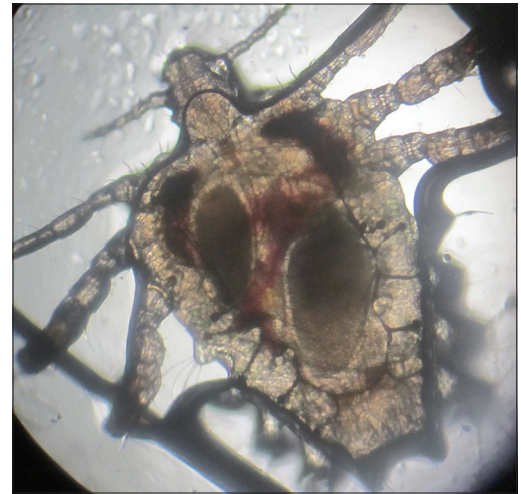


Figure 1: Crab louse with its characteristic morphology grasping the hair shaft with blood filled esophagus (40x magnification)

cream, 1% lindane shampoo, oral ivermectin. Occlusive agents like vaseline, freshly prepared fluorescein eyedrops and manual removal of nits are recommended in case the eyelashes are infested.

REFERENCES

1. Burns DA, Sims TA. A closer look at *Phthirus pubis*. *Br J Dermatol* 1988;118:497-503.
2. Munkvad IM, Klemp P. Co-existence of venereal infection and pediculosis pubis. *Acta Derm Venereol* 1982;62:366-7.

Cite this article as: Palanisamy AP, Kanakaram KK, Vadivel S, Kothandapany S. Crab louse. *Indian Dermatol Online J* 2015;6:375.

Source of Support: Nil, **Conflict of Interest:** None declared.