

## Case report

# Left gonadal vein thrombosis in a patient with COVID-19-associated coagulopathy

Maedeh Veyseh,<sup>1</sup> Prateek Pophali,<sup>1</sup> Apoorva Jayarangaiah,<sup>2</sup> Abhishek Kumar<sup>2,3</sup>

<sup>1</sup>Medicine, Jacobi Medical Center, Bronx, New York, USA  
<sup>2</sup>Hematology and Oncology, Jacobi Medical Center, Bronx, New York, USA

<sup>3</sup>Hematology and Oncology, Yeshiva University Albert Einstein College of Medicine, Bronx, New York, USA

**Correspondence to**  
 Dr Abhishek Kumar;  
 kumara20@nychhc.org

Accepted 24 August 2020

## SUMMARY

COVID-19 disease is a viral illness that predominantly causes pneumonia and severe acute respiratory distress syndrome. The endothelial injury and hypercoagulability secondary to the inflammatory response predisposes severely ill patients to venous thromboembolism. The exact mechanism of hypercoagulability is still under investigation, but it is known to be associated with poor prognosis. The most common thrombotic complication reported among these patients is pulmonary embolism. To our knowledge, gonadal vein thrombosis is an uncommon phenomenon that has not been reported in the setting of COVID-19-associated coagulopathy. We report an unusual case of ovarian vein thrombosis and pulmonary embolism associated with COVID-19 presenting with abdominal pain. To our knowledge, this is the first reported case of COVID-19 with absent respiratory symptoms and presentation with venous thrombosis in an unusual location.

## BACKGROUND

Since the emergence of SARS-CoV-2 in December 2019, the world has faced an unprecedented public health crisis due to its high rate of transmission and the broad spectrum of the disease severity. The manifestation of the disease ranges from asymptomatic carriers to severe acute respiratory distress syndrome requiring mechanical ventilation and intensive care unit (ICU) admission. The severe cases are more prone to arterial and venous thrombosis. These thrombotic events have been related to poor prognosis and linked to unexpected cardiac deaths.<sup>1</sup>

The pathophysiology of thrombosis in COVID-19 is hypothesised to be due to a hypercoagulable state from excessive inflammation, hypoxia, immobilisation and in severe cases of disseminated intravascular coagulation.<sup>2</sup> The most common location of thrombosis is pulmonary arteries. Other reported venous thromboembolisms (VTEs) include lower extremity thrombosis and catheter-associated thrombi.<sup>3</sup>

Ovarian vein thrombosis (OVT) is a rare and potentially fatal condition of postpartum period, which can act as a source of pulmonary embolism.<sup>4,5</sup> Gonadal vein thrombosis has never been reported during this pandemic as a result of COVID-19. We present a unique case which demonstrates left gonadal vein thrombosis secondary to COVID-19 as the first presenting sign.

## CASE PRESENTATION

A 52-year-old postmenopausal woman, with no known medical history, presented to our hospital with sudden onset of severe sharp right upper quadrant abdominal pain for 2 days. She described the pain to be unrelated to food and not associated with any other gastrointestinal (GI)-related symptoms.

She denied recent fevers, cough or upper respiratory tract infection symptoms. She was afebrile (temp 97.7°F), pulse rate 93 beats/min, respiratory rate 22/min and oxygen saturation was 94% on room air, body mass index 29 kg/m<sup>2</sup>. Her physical examination on admission was notable for shallow breathing, clear lungs and non-tender abdomen.

## INVESTIGATIONS

The labs were significant for increased inflammatory markers, including ferritin (883 µg/L), C reactive protein (217 mg/L) and D-dimer was markedly elevated to 3813 ng/mL (table 1).

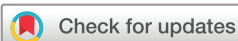Chest X-ray showed patchy peripheral densities seen in the upper lobe on the frontal view. On the lateral view there were patchy infiltrates posteriorly in the lower lobes suggestive of COVID-19.

CT of the abdomen/pelvis with contrast showed left OVT, which extended partially to the renal vein (figures 1 and 2). Additionally, there was a finding of pulmonary embolism in the posterior branch of pulmonary artery in the right lower lobe (RLL). Pulmonary windows of the CT confirmed presence of bilateral lower lobe consolidations, ground-glass opacities in the right middle lobe and foci of consolidation in the lingula suggestive of COVID-19 pneumonia. Subsequent chest CT angiography confirmed the presence of an acute RLL pulmonary artery thrombosis (figure 3). Deep vein thrombosis (DVT) studies were negative for lower extremity venous clots.

Nasopharyngeal swab confirmed the diagnosis of COVID-19. Echocardiography showed normal biventricular systolic function in the absence of right heart strain.

## DIFFERENTIAL DIAGNOSIS

To further investigate secondary causes of hypercoagulability, rheumatologic panel including antinuclear antibody-extractable nuclear antigen panel, lupus anticoagulant, protein C, protein S and antithrombin III were tested and resulted negative. Tumour markers, including carcinoembryonic antigen, carbohydrate antigen 9/19 and cancer antigen-125 were negative and the initial CT scan



© BMJ Publishing Group Limited 2020. No commercial re-use. See rights and permissions. Published by BMJ.

**To cite:** Veyseh M, Pophali P, Jayarangaiah A, et al. *BMJ Case Rep* 2020;**13**:e236786. doi:10.1136/bcr-2020-236786

**Table 1** The patient's laboratory findings on admission

Labs	On admission	Normal range
WBC	15.10	3.5–11x10 <sup>9</sup> /L
Neutrophil count	12.72	1.7–9x10 <sup>9</sup> /L
Lymphocyte count	1.39	1.2–3.5x10 <sup>9</sup> /L
PLT	467	150–440x10 <sup>9</sup> /L
PT	16.1	9.4–12.5 s
PTT	27.9	25.1–36.5 s
INR	1.4	0.8–1.1 ratio
C reactive protein	217	0–5 mg/L
Ferritin	719	12–150 µg/L
LDH	386	100–210 U/L
D-dimer	3813	0–230 ng/mL
Fibrinogen	883	200–400 mg/dL

INR, international normalised ratio; LDH, lactate dehydrogenase; PLT, platelets; PT, prothrombin time; PTT, partial thromboplastin time; WBC, white blood cells.

of chest/abdomen/pelvis was without any evidence of malignancy. COVID-19 was deemed to be the provoking cause of the thrombosis.

**TREATMENT**

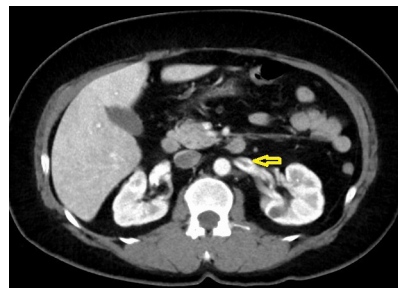The patient was started on therapeutic low molecular weight heparin (enoxaparin) 1 mg/kg two times per day, which resulted in significant improvement of the abdominal pain few hours after the first dose. She remained afebrile, denied any cough or shortness of breath, and oxygen saturation remained stable on room air. She was discharged after 3 days of hospitalisation on apixaban 10 mg two times per day for a week, followed by 5 mg two times per day for 3 months.

**OUTCOME AND FOLLOW-UP**

During follow-up after a month, the patient reported mild abdominal pain, but remained afebrile and without any respiratory symptoms. She denied any bleeding complication. A repeat CT of the abdomen and pelvis showed resolution of thrombosis. D-dimer at the follow-up visit was 234 ng/mL.

**DISCUSSION**

The COVID-19 pandemic caused by the SARS-CoV-2 has affected millions of people worldwide. While a majority of the people affected by the virus remain asymptomatic, most patients admitted to the hospital present with severe respiratory illness. The most extensive published case series from China and New



**Figure 2** Axial view of thrombosis in the left gonadal vein with extension to the left renal vein.

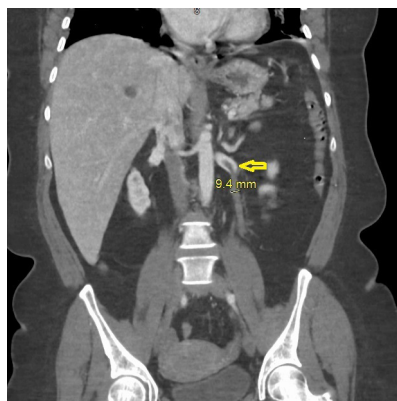
York report that the majority of patients present with fever, cough, fatigue and GI symptoms.<sup>6,7</sup> Nearly 20% of these patients present with severe coagulation abnormalities. But rarely, VTE may be the initial presenting feature in patients with SARS-CoV-2 infection.<sup>8</sup> Concomitant VTE, a potential cause of unexplained deaths, has been frequently reported in COVID-19 cases.<sup>8,9</sup> Our patient was distinctive in terms of presentation as she lacked the common respiratory symptoms, rather acute venous thrombosis in an unusual location prompted the diagnosis of COVID-19.

Virchow's triad defined as blood stasis, endothelial injury and a hypercoagulable state leads to the pathogenesis of thrombosis.<sup>10</sup> Patients with COVID-19 usually present with dehydration and prolonged bed rest, which are risk factors for blood stasis.<sup>11</sup> SARS-CoV-2 infects ACE 2 receptors, which is present on multiple organs, including the endothelial cells. In a recent study on postmortem autopsies, there was evidence of endothelitis caused by either direct viral invasion of the endothelial cells or endothelial injury derived from the inflammatory response. This possibly explains why patients with endothelial dysfunction due to pre-existing conditions are more prone to organ failure secondary to microthrombi and present with a more severe form of the illness.<sup>12</sup> Also, the COVID-19 infection can cause a severe inflammatory response, which results in the release of cytokines such as interleukin 6, tumour necrosis factor-alpha.<sup>13</sup> These cytokines stimulate the activation of the coagulation cascade and increase the risk of VTE.<sup>14</sup> Other proposed pathophysiology behind an increased propensity to thrombosis is the finding of antiphospholipid antibodies, which can transiently arise in patients with critical illness and various infections and potentially contribute to a hypercoagulable state.<sup>15,16</sup>

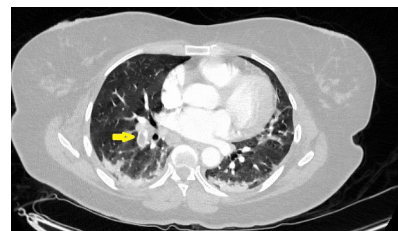
Based on the available literature, most thrombotic events in COVID-19, including pulmonary embolism or DVTs, develop in critically ill patients with severe pulmonary disease.<sup>2,17,18</sup>

Our case was unique as she had no respiratory symptoms and an otherwise uncomplicated clinical course; however, she still presented with a thrombotic complication in an unusual site.

OVT is a rare entity that is most commonly seen in the postpartum period. Other causes of OVT include pelvic



**Figure 1** Coronal view of thrombosis in the left gonadal vein with extension to the left renal vein.



**Figure 3** Acute right lower lobe pulmonary embolism—mild bilateral lower lobe consolidations suggestive of COVID-19 pneumonia.

inflammatory disease, recent gynaecological or abdominal surgery, hypercoagulable state and underlying malignancy.<sup>5</sup> An underlying hypercoagulable state has been reported in 50% of the cases with OVT.<sup>19</sup> Regardless of the aetiology, right-sided OVT accounts for 70%–90% of the cases. It can likely be related to dextrotorsion of the uterus that compresses the right ovarian vein, antegrade flow and relatively more incompetent valves of the right ovarian vein.<sup>20</sup> The most common symptoms are fever (80%) and right-sided pelvic pain (55%).<sup>21</sup> Our patient was unusual as she did not have a fever on presentation, and the venous thrombosis was on the left side. This condition can be fatal due to the serious life-threatening complication from thrombus extension into the systemic veins and subsequent pulmonary artery embolisation. The incidence of OVT complicated by pulmonary embolism is reported to be approximately 25%.<sup>22</sup> Our case was diagnosed with OVT and subsequent pulmonary embolism. It is unclear if the pulmonary embolus occurred secondary to embolisation of ovarian thrombosis or a primary thrombus as a result of hypercoagulability state due to COVID-19, specifically in the absence of lower extremity DVT. The treatment for OVT is anticoagulation for 3–6 months. However, no clear guideline is available about the duration of therapy, and non-vitamin K antagonist oral anticoagulants have not yet been studied in such cases.<sup>5 20</sup>

The only widely available treatment in COVID-19-associated coagulopathy is prophylactic dose of low molecular weight heparin, which should be considered in all patients (including non-critically ill) who require hospital admission for COVID-19 infection.<sup>23</sup>

Use of higher-intensity, non-standard anticoagulation currently lacks efficacious evidence in COVID-19.<sup>10</sup> A study by Klok *et al*<sup>2</sup> showed a 31% incidence of thrombotic complications in ICU patients with COVID-19 infection despite being on prophylactic anticoagulation. Considering this remarkably high incidence of VTE, it is suggested to increase the intensity of anticoagulation despite the lack of randomised evidence to support the practice. Current evidence suggests D-dimer, an indicator of fibrin breakdown, can be used to assess severity of clot burden and guide initiation and monitoring of therapy.<sup>1 24</sup>

In summary, we present an interesting case with an unusual presentation of COVID-19 who presented with abdominal pain and no significant respiratory symptoms and was diagnosed with thrombosis of the left ovarian vein. Our case emphasises the high risk of coagulopathy in COVID-19 cases, even without a severe systemic infection. Evaluation and risk stratification for thrombosis with coagulation markers and D-dimer should be incorporated in the management of COVID-19.<sup>25</sup>

### Learning points

- ▶ This is the first case report of ovarian vein thrombosis secondary to COVID-19-associated coagulopathy (CAC).
- ▶ CAC can present with thromboembolic complications even in the absence of typical respiratory symptoms.
- ▶ CAC is associated with poor prognosis and prompts prophylactic anticoagulation in all patients who require hospitalisation.
- ▶ Coagulopathy is independently indicative of severe illness even in the absence of lung involvement. Prothrombin time/partial thromboplastin time/international normalised ratio, fibrinogen and D-dimer should be monitored in all patients with COVID-19 requiring hospitalisation.

**Contributors** Supervised and reviewed by AK. Patient was under the care of MV. Report was written by MV, AJ and PP.

**Funding** The authors have not declared a specific grant for this research from any funding agency in the public, commercial or not-for-profit sectors.

**Competing interests** None declared.

**Patient consent for publication** Obtained.

**Provenance and peer review** Not commissioned; externally peer reviewed.

This article is made freely available for use in accordance with BMJ's website terms and conditions for the duration of the covid-19 pandemic or until otherwise determined by BMJ. You may use, download and print the article for any lawful, non-commercial purpose (including text and data mining) provided that all copyright notices and trade marks are retained.

### REFERENCES

- 1 Tang N, Li D, Wang X, *et al*. Abnormal coagulation parameters are associated with poor prognosis in patients with novel coronavirus pneumonia. *J Thromb Haemost* 2020;18:844–7.
- 2 Klok FA, Kruip MJHA, van der Meer NJM, *et al*. Incidence of thrombotic complications in critically ill ICU patients with COVID-19. *Thromb Res* 2020;191:145–7.
- 3 Klok FA, Kruip MJHA, van der Meer NJM, *et al*. Confirmation of the high cumulative incidence of thrombotic complications in critically ill ICU patients with COVID-19: an updated analysis. *Thromb Res* 2020;191:148–50.
- 4 Wysokinska EM, Hodge D, McBane RD, *et al*. Ovarian vein thrombosis: incidence of recurrent venous thromboembolism and survival. *Thromb Haemost* 2006;96:126–31.
- 5 Heavrin BS, Wrenn K. Ovarian vein thrombosis: a rare cause of abdominal pain outside the peripartum period. *J Emerg Med* 2008;34:67–9.
- 6 Goyal P, Choi JJ, Pinheiro LC, *et al*. Clinical characteristics of Covid-19 in New York City. *N Engl J Med* 2020;382:2372–4.
- 7 Guan W-J, Zhong N-S. Clinical characteristics of Covid-19 in China. reply. *N Engl J Med* 2020;382:1861–2.
- 8 Zhai Z, Li C, Chen Y, *et al*. Prevention and treatment of venous thromboembolism associated with coronavirus disease 2019 infection: a consensus statement before guidelines. *Thromb Haemost* 2020;120:937–48.
- 9 Chen N, Zhou M, Dong X, *et al*. Epidemiological and clinical characteristics of 99 cases of 2019 novel coronavirus pneumonia in Wuhan, China: a descriptive study. *Lancet* 2020;395:507–13.
- 10 Bikdeli B, Madhavan MV, Jimenez D, *et al*. COVID-19 and thrombotic or thromboembolic disease: implications for prevention, antithrombotic therapy, and follow-up: JACC state-of-the-art review. *J Am Coll Cardiol* 2020;75:2950–73.
- 11 Zhou B, She J, Wang Y, *et al*. Venous thrombosis and arteriosclerosis obliterans of lower extremities in a very severe patient with 2019 novel coronavirus disease: a case report. *J Thromb Thrombolysis* 2020;50:229–32.
- 12 Varga Z, Flammer AJ, Steiger P, *et al*. Endothelial cell infection and endotheliitis in COVID-19. *Lancet* 2020;395:1417–8.
- 13 Qin C, Zhou L, Hu Z, *et al*. Dysregulation of immune response in patients with coronavirus 2019 (COVID-19) in Wuhan, China. *Clin Infect Dis* 2020;71:ciaa248:762–8.
- 14 Levi M, van der Poll T, Büller HR. Bidirectional relation between inflammation and coagulation. *Circulation* 2004;109:2698–704.
- 15 Harzallah I, Debliguis A, Drénou B. Lupus anticoagulant is frequent in patients with Covid-19. *J Thromb Haemost* 2020;18:2064–5.
- 16 Shoenfeld Y, Blank M, Cervera R, *et al*. Infectious origin of the antiphospholipid syndrome. *Ann Rheum Dis* 2006;65:2–6.
- 17 Cui S, Chen S, Li X, *et al*. Prevalence of venous thromboembolism in patients with severe novel coronavirus pneumonia. *J Thromb Haemost* 2020;18:1421–4.
- 18 Helms J, Tacquard C, Severac F, *et al*. High risk of thrombosis in patients with severe SARS-CoV-2 infection: a multicenter prospective cohort study. *Intensive Care Med* 2020;46:1089–98.
- 19 Ortín X, Ugarriza A, Espax RM, *et al*. Postpartum ovarian vein thrombosis. *Thromb Haemost* 2005;93:1004–5.
- 20 Dessole S, Capobianco G, Arru A, *et al*. Postpartum ovarian vein thrombosis: an unpredictable event: two case reports and review of the literature. *Arch Gynecol Obstet* 2003;267:242–6.
- 21 Prieto-Nieto MI, Perez-Robledo JP, Rodriguez-Montes JA, *et al*. Acute appendicitis-like symptoms as initial presentation of ovarian vein thrombosis. *Ann Vasc Surg* 2004;18:481–3.
- 22 Harris K, Mehta S, Iskhakov E, *et al*. Ovarian vein thrombosis in the nonpregnant woman: an overlooked diagnosis. *Ther Adv Hematol* 2012;3:325–8.
- 23 Thachil J, Tang N, Gando S, *et al*. ISTH interim guidance on recognition and management of coagulopathy in COVID-19. *J Thromb Haemost* 2020;18:1023–6.
- 24 Zhou F, Yu T, Du R, *et al*. Clinical course and risk factors for mortality of adult inpatients with COVID-19 in Wuhan, China: a retrospective cohort study. *Lancet* 2020;395:1054–62.
- 25 Lippi G, Favaloro EJ. D-Dimer is associated with severity of coronavirus disease 2019: a pooled analysis. *Thromb Haemost* 2020;120:876–8.

Copyright 2020 BMJ Publishing Group. All rights reserved. For permission to reuse any of this content visit <https://www.bmj.com/company/products-services/rights-and-licensing/permissions/>  
BMJ Case Report Fellows may re-use this article for personal use and teaching without any further permission.

Become a Fellow of BMJ Case Reports today and you can:

- ▶ Submit as many cases as you like
- ▶ Enjoy fast sympathetic peer review and rapid publication of accepted articles
- ▶ Access all the published articles
- ▶ Re-use any of the published material for personal use and teaching without further permission

### **Customer Service**

If you have any further queries about your subscription, please contact our customer services team on +44 (0) 207111 1105 or via email at [support@bmj.com](mailto:support@bmj.com).

Visit [casereports.bmj.com](http://casereports.bmj.com) for more articles like this and to become a Fellow