



Yellow nail syndrome with massive chylothorax after esophagectomy: A case report

Takumi Fukaya^a, Hajime Kasai^{b,c,*}, Mikihiro Saito^b, Yuika Sasatani^{b,d}, Takashi Urushibara^b, Seiichiro Sakao^c

^a Department of Medicine, School of Medicine, Chiba University, Chiba, 260-8670, Japan

^b Department of Respiratory Medicine, Kimitsu Chuo Hospital, Kisarazu, 292-8535, Japan

^c Department of Respiratory, Graduate School of Medicine, Chiba University, Chiba, 260-8670, Japan

^d Department of Respiratory Medicine, Mito Medical Center, Mito, 310-0015, Japan

ARTICLE INFO

Keywords:

Yellow nail syndrome
Thoracic surgery
Conservative treatment
Pleural effusion
Chylothorax

ABSTRACT

Yellow nail syndrome (YNS) is a rare condition characterized by the triad of yellow nails, lymphedema, and respiratory manifestations. Diuretics and thoracic drainage are often not effective in YNS, and the most effective treatments are pleurodesis and decortication/pleurectomy. A 66-year-old man was admitted to our hospital for YNS after esophagectomy with gastric tube reconstruction for esophageal cancer. The patient presented with yellow nails and lymphedema. Chest X-rays and computed tomography showed massive pleural effusions and ascites that were both chylous. The patient was considered to have YNS that became apparent after surgery. He recovered with diuretics and a low-fat diet without pleurodesis and decortication/pleurectomy. Thoracic surgery can exacerbate the functional impairment of lymphatic drainage in patients with asymptomatic and undiagnosed YNS, and can lead to further development of YNS-related clinical symptoms. Despite relatively massive chylothorax following thoracic surgery, chylothorax related to YNS could be successfully controlled with conservative treatment without pleurodesis and decortication/pleurectomy.

1. Introduction

Yellow nail syndrome (YNS) is a rare condition characterized by the triad of yellow nails, lymphedema, and respiratory manifestations [1]. The treatment for YNS has not been established, although some treatments such as oral administration of vitamin E for yellow nails and decortication/pleurectomy or pleurodesis for pleural effusion can be effective. Although the etiology of YNS remains unknown, lymphatic impairment is often involved [2]. Only a few cases of YNS that became apparent after surgery have been reported; however, neither the clinical features nor the course were clear in those cases [3–6]. Herein, we present a case of YNS that presented as massive chylothorax and chylous ascites after esophagectomy, and was resolved using conservative treatment without pleurodesis or the need for surgery.

2. Case presentation

A 66-year-old man was referred to our department with pleural effusion and dyspnea. He had Parkinson's disease and dementia and had

been treated with levodopa and pramipexole. Two months prior, he had undergone esophagectomy with gastric tube reconstruction for esophageal cancer. Three weeks after the surgery, a cough and edema in the lower limbs appeared. Furosemide at a daily dose of 10 mg was administered by the department of general surgery.

The patient was admitted four days after the first visit to our department for treatment of the pleural effusion. Upon admission, the patient's weight was 65 kg and his height was 168 cm. His vital signs were as follows: blood pressure, 100/83 mm Hg; pulse rate, 85 beats/min; pulse oximetry, 95% in room air; body temperature, 37.2 °C. Physical examination showed diminished breath sounds in the right middle and lower lung fields, significant edema in the lower extremities, and yellow discoloration of the fingernails (Fig. 1). Laboratory examinations showed low albumin levels (3.3 g/dL; Table 1). Chest X-ray and computed tomography (CT) showed bilateral pleural effusions (Fig. 2A–E) and CT also showed a large amount of ascites (Fig. 3A and B).

The patient underwent thoracentesis for a right pleural effusion, and 200 mL of the pleural effusion was aspirated. The appearance of the

* Corresponding author. Department of Respiratory, Graduate School of Medicine, Chiba University, Chiba, 260-8670, Japan.

E-mail address: daikasai6075@yahoo.co.jp (H. Kasai).

<https://doi.org/10.1016/j.rmcr.2021.101448>

Received 6 December 2020; Received in revised form 22 May 2021; Accepted 29 May 2021

Available online 12 June 2021

2213-0071/© 2021 The Author(s).

Published by Elsevier Ltd.

This is an open access article under the CC BY-NC-ND license

(<http://creativecommons.org/licenses/by-nc-nd/4.0/>).

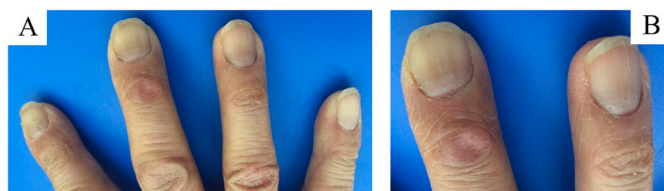

Fig. 1. (A) The nail color of the patient's right hand was yellow upon admission. (B) An enlarged view of the third and fourth fingers of the patient's right hand demonstrates the characteristic yellow coloration of YNS. (For interpretation of the references to color in this figure legend, the reader is referred to the Web version of this article.)

pleural effusion was milky (Fig. 2F) and laboratory examination revealed that it was chylothorax (triglyceride concentration, 579 mg/dL), lymphocyte-predominant, and transudative (Table 1). Bacterial culture and cytological examination of the pleural effusion were negative for bacterial infection and malignancy. Bilateral thoracentesis and abdominal paracentesis were performed. The left pleural effusion and ascites were chylous, similar to the right pleural effusion (Fig. 3C).

Initially, administration of diuretics and a low-fat diet were planned during hospitalization; however, the patient was discharged two days after admission due to restlessness. After discharge, the dosage of furosemide was increased to 20 mg per day, and a low-fat diet was continued. A week after discharge, right thoracentesis was performed again and aspirated 1500 mL of the pleural effusion. Furosemide was discontinued due to dehydration. The pleural effusion subsequently decreased gradually without the need for additional thoracentesis, and two months after discharge, the low-fat diet was discontinued. Four months after discharge, the pleural effusion and ascites disappeared; the

nail discoloration and lymphedema also resolved (Fig. 4). No medication was required and there was no recurrence of YNS-related symptoms.

3. Discussion

There were two notable clinical findings in this case. First, surgical invasion for esophageal cancer can exacerbate the functional impairment of lymphatic drainage in patients with asymptomatic and undiagnosed YNS, and can lead to the development of YNS-related clinical symptoms. Second, YNS after thoracic surgery can resolve with conservative treatment alone, even in cases with massive chylothorax, chylous ascites, and systemic edemas.

Thoracic surgery, including esophagectomy, can trigger YNS symptoms. In patients with YNS, the functional impairment of lymphatic drainage can be associated with lymphedema, pleural effusion, or nail discoloration [2]. The conditions associated with YNS, including lymphatic impairment, can constitute secondary insults causing functionally anomalous lymphatics, presenting clinically as intrathoracic findings, nail changes, and/or edema [5,7]. Another trigger that causes functionally anomalous lymphatics to manifest clinically as YNS may be the traumatic disruption of lymphatic vessels [5]. Intraoperative damage to the thoracic duct or other lymphatic tributaries may overwhelm the lymphatic network, causing accumulation of chyle in the pleural space where it manifests as chylothorax, while in the lower extremity soft tissues it manifests as yellow nails [5].

The cause of previously reported cases of pleural effusion after thoracic surgery could be related to YNS. The four previously reported cases of postoperative YNS all followed cardiac surgery: three were coronary artery bypass graft surgeries and one was a mitral valve replacement (Table 2) [3–6]. The age of the patients was 60 years or older in all but one case. Conservative treatment such as diuretics and a

Table 1
Laboratory data upon admission.

Complete blood count			Blood chemistry			Plural effusion (Right)		
White blood cell count	4800	/μL	Aspartate aminotransferase	17	U/L	White blood cell count	600	/μL
Neutrophil	78.6	%	Alanine aminotransferase	9	U/L	Neutrophil	6.1	%
Eosinophil	0.6	%	Lactate dehydrogenase	205	U/L	Eosinophil	2.0	%
Monocyte	9.5	%	Alkaline phosphatase	207	U/L	Lymphocyte	90.8	%
Lymphocyte	10.8	%	γ-glutamyltransferase	13	U/L	Total protein	2.1	g/dL
Red blood cell count	409 × 10 ⁴	/μL	Total protein	5.8	g/dL	Albumin	1.5	g/dL
Hemoglobin	13.1	g/dL	Albumin	3.3	g/dL	Triglyceride	579	mg/dL
Hematocrit	40.2	%	Urea nitrogen	24.5	mg/dL	Lactate dehydrogenase	91	U/L
Platelet count	18.0 × 10 ⁴	/μL	Creatinine	0.90	mg/dL	Glucose	133	mg/dL
			Sodium	141	mmol/L	Carcinoembryonic antigen	0.6	ng/mL
Immune serum			Potassium	4.1	mmol/L	Hyaluronic acid	5100	ng/mL
C-reactive protein	0.66	mg/dL	Chlorine	100	mmol/L	Adenosine deaminase	5.8	U/L
Brain natriuretic peptide	58.7	pg/dL						
Carcinoembryonic antigen	0.8	ng/mL						
Cytokeratin 19 fragment	1.22	ng/mL						
Pro-gastrin-releasing peptide	20.3	pg/dL						

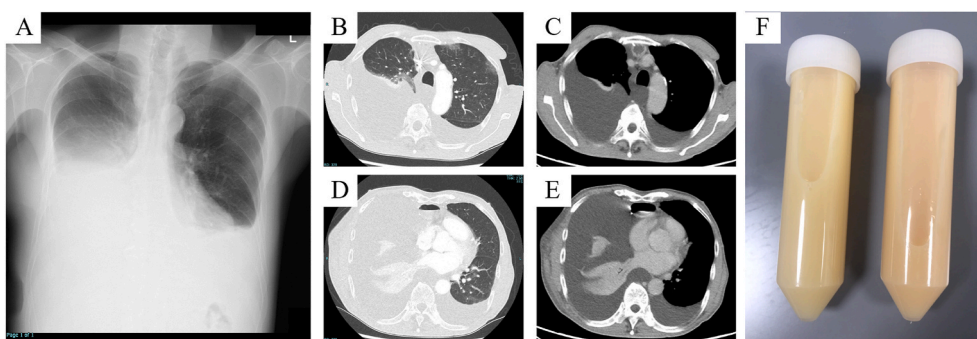


Fig. 2. (A) Chest X-ray upon admission reveals bilateral pleural effusions. (B–E) Chest computed tomography reveals bilateral pleural effusions and ascites. Additionally, edema is visible in the right chest wall. (F) The pleural effusion aspirated through thoracentesis upon admission demonstrates chylothorax.

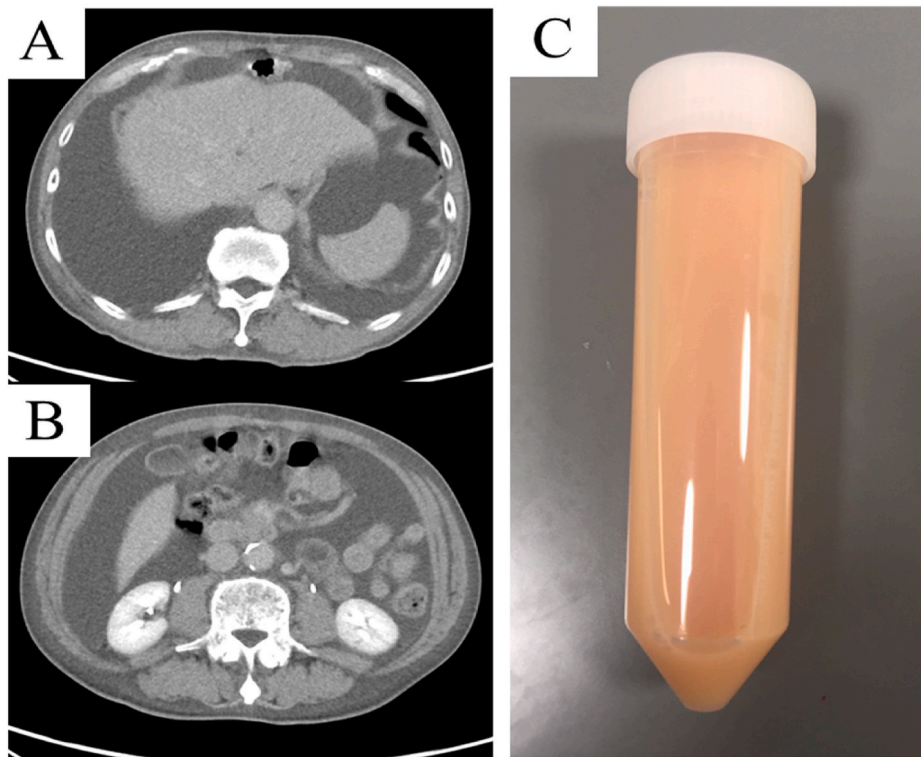


Fig. 3. (A–B) Abdominal computed tomography reveals ascites. (C) Ascites aspirated through abdominocentesis upon admission demonstrates chylous ascites.

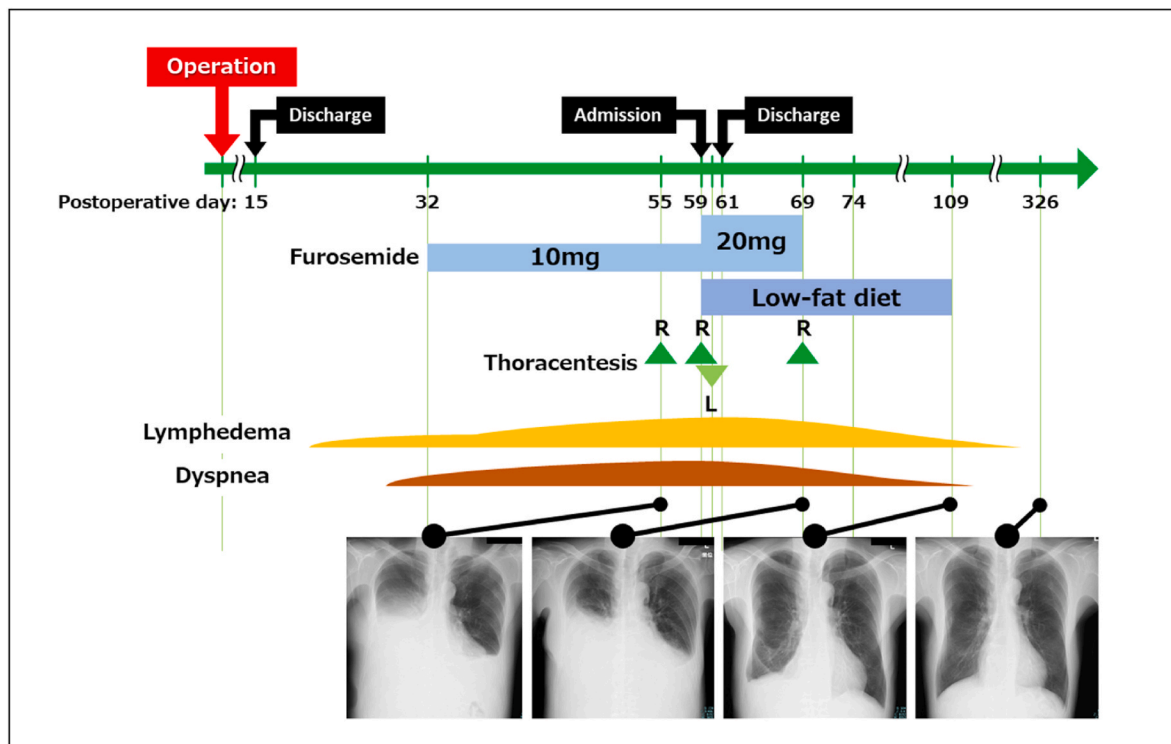


Fig. 4. A timeline demonstrating the clinical course and chest X-ray.

low-fat diet failed in three of the four cases, and pleurodesis was subsequently performed [3,5,6]. In the case that resolved with conservative treatment, oral vitamin E and diuretics were administered [4]. In our case, chylothorax, chylous ascites, and yellow nails appeared after esophagectomy. The case in this report suggests that all intrathoracic

procedures, not only cardiac surgery, may make YNS apparent.

In this case, other than thoracic surgery, injury to the thoracic duct and albumin loss may be the cause of the chylothorax; however, either of these on their own do not explain other presented symptoms, such as yellow nails and lymphedema. Since lymphangiography was not

Table 2
Previously reported cases of yellow nail syndrome after thoracic surgery.

Report	Year	Age	Sex	Underlying disease	Operation	Symptoms	Treatment
Banta DP et al.	2009	80	Male	triple vessel coronary artery disease, diabetes, emphysema	coronary artery bypass graft surgery	yellow nails, right pleural effusion, lower extremity edema, pneumonia	vitamin E, diuretics, antibiotics, thoracentesis, pleurodesis
Waliyany S et al.	2018	62	Male	four-vessel coronary artery disease	coronary artery bypass graft surgery	yellow nails, left chylothorax	low-fat diet, octreotide, thoracic drainage, pleurodesis
Omori T et al.	2018	76	Male	coronary artery disease	coronary artery bypass graft surgery	yellow nails, bilateral pleural effusion, leg edema	vitamin E, diuretics
Sarmast H et al.	2019	39	Female	mitral valve stenosis	mitral valve replacement	yellow nails, leg edema, left chylothorax, sinusitis	diuretics, low-fat diet, octreotide, physical therapy, thoracic drainage, vitamin E, pleurodesis
Present case	2020	66	Male	esophageal cancer	subtotal esophagectomy and gastric tube reconstruction	yellow nails, systemic edema, chylothorax, ascites	diuretics, low-fat diet

performed, the possibility of thoracic duct injury cannot be excluded. However, the chylous ascites and lymphedema that was observed with chylothorax cannot be explained exclusively by the leakage of lymph fluid due to only thoracic duct injury. While thoracic duct ligation is a treatment for chylothorax due to overt thoracic duct injury, it may exacerbate the symptoms in YNS due to the presence of lymphatic perfusion disorders. The edema observed in this case may be explained by albumin loss due to chylothorax. Nonetheless, the decrease in albumin was mild and when combined with the finding of yellow nails it is considered to possibly be lymphedema rather than albumin loss. From the above, this case was considered to involve asymptomatic and undiagnosed lymphatic dysfunction of YNS that became apparent after increased lymphatic perfusion due to surgical invasion and consequent damage to the small lymphatic vessels.

The preoperative diagnosis of YNS can be challenging because symptoms such as yellow nails and lymphedema can be mild or may not manifest before surgery. Patients with YNS have an increased risk of recurrent respiratory infections, and thoracic duct ligation can exacerbate their condition by increasing the risk of pleural effusion due to YNS-associated lymphatic impairment. In this case, the yellow nails disappeared along with the chylothorax, which suggests that the symptoms of YNS could have been undetectable before surgery. Therefore, preoperative diagnosis could be difficult as any preexisting yellowing of the nails or lymphedema could be mild. Because YNS could recur due to infection or other diseases, successful diagnosis will lead to an assessment of the risk for future recurrence. Therefore, it may be useful to inspect the patient's nails to check for the characteristic nail discoloration before surgery and when pleural effusion appears after surgery, which will lead to the diagnosis of YNS.

Although YNS treatment is not codified [2], even large amounts of chylothorax after surgery may be controlled with conservative treatment. The pleural effusions associated with YNS are often intractable; water deprivation or dietary restriction and the administration of diuretic drugs are not effective [8]. Additionally, therapeutic thoracentesis is usually not effective due to recurrence [9]. The indwelling pleural catheter (IPC) may be useful in the management of recurrent malignant pleural effusions [10]. However, IPC can be associated with a risk of complications such as pleural infection, nutrient loss, and immunological impairment [11]. Because chylous pleural effusions are richer in protein and lipid than malignant pleural effusions, the use of IPC for chylothorax may exacerbate nutrient loss. Therefore, IPC may not be the ideal treatment for chylothorax. In refractory cases, pleurodesis and decortication/pleurectomy could be the most effective treatment [9]. However, pleurodesis has the disadvantage of risking irreversible pleural adhesion and decortication/pleurectomy may be highly invasive for patients. In our patient, IPC and pleurodesis were not performed because it was difficult to continue hospitalization due to delirium, in addition to the above reasons. Our case resolved with diuretics and a low-fat diet, despite respiratory failure due to massive chylothorax and systemic edema. YNS can be controlled with conservative treatment even if a relatively large amount of chylothorax exists;

therefore, continuing conservative treatment in postoperative YNS can be an alternative if the respiratory condition allows.

4. Conclusions

Here, we presented a case of YNS that was definitively diagnosed after thoracic surgery that included esophagectomy. If chylothorax is observed after thoracic surgery, YNS can be considered as a differential diagnosis. Continuing conservative treatment can be considered even if the patient with YNS has a large pleural effusion.

Funding

This case report did not receive any specific grant from funding agencies in the public, commercial, or not-for-profit sectors.

Declarations of interest

None.

Acknowledgements

We would like to thank Editage (www.editage.com) for English language editing.

References

- [1] E. Hiller, E.C. Rosenow 3rd, A.M. Olsen, Pulmonary manifestations of the yellow nail syndrome, *Chest* 61 (1972) 452–458, <https://doi.org/10.1378/chest.61.5.452>, 1972/05/01.
- [2] S. Vignes, R. Baran, Yellow nail syndrome: a review, *Orphanet J. Rare Dis.* 12 (2017), <https://doi.org/10.1186/s13023-017-0594-4>, 42. 2017/03/01.
- [3] D.P. Banta, N. Dandamudi, H.J. Parekh, et al., Yellow nail syndrome following thoracic surgery: a new association? *J. Postgrad. Med.* 55 (2009) 270–271, <https://doi.org/10.4103/0022-3859.58931>, 2010/01/20.
- [4] T. Omori, R. Okamoto, H. Fujimoto, et al., Yellow nail syndrome complicating coronary artery bypass graft surgery, *Circ. J. : official journal of the Japanese Circulation Society* 82 (2018) 2678–2679, <https://doi.org/10.1253/circj.CJ-18-0154>, 2018/03/16.
- [5] S. Waliyany, J. Chandler, D. Hovsepian, et al., Yellow nail syndrome with chylothorax after coronary artery bypass grafting, *J. Cardiothorac. Surg.* 13 (2018), <https://doi.org/10.1186/s13019-018-0784-8>, 93. 2018/09/12.
- [6] H. Sarmast, A. Takriti, Yellow nail syndrome resulting from cardiac mitral valve replacement, *J. Cardiothorac. Surg.* 14 (2019), <https://doi.org/10.1186/s13019-019-0903-1>, 72. 2019/04/12.
- [7] R.H. Bull, D.A. Fenton, P.S. Mortimer, Lymphatic function in the yellow nail syndrome, *Br. J. Dermatol.* 134 (1996) 307–312, 1996/02/01.
- [8] T. Yamagishi, N. Hatanaka, H. Kamemura, et al., Idiopathic yellow nail syndrome successfully treated with OK-432, *Intern. Med.* 46 (2007) 1127–1130, <https://doi.org/10.2169/internalmedicine.46.0022>, 2007/07/20.

- [9] L. Valdes, J.T. Huggins, F. Gude, et al., Characteristics of patients with yellow nail syndrome and pleural effusion, *Respirology* 19 (2014) 985–992, <https://doi.org/10.1111/resp.12357>, 2014/08/16.
- [10] R. Bhatnagar, N.A. Maskell, Indwelling pleural catheters. *Respiration, international review of thoracic diseases* 88 (2014) 74–85, <https://doi.org/10.1159/000360769>, 2014/05/24.
- [11] M.M. Lui, R. Thomas, Y.C. Lee, Complications of indwelling pleural catheter use and their management, *BMJ Open Respir Res* 3 (2016), <https://doi.org/10.1136/bmjresp-2015-000123> e000123. 2016/02/13.