



CASE REPORT

REVISED Bispectral index detects intraoperative cerebral ischaemia during balloon assisted cerebral aneurysm coiling [v2; ref status: indexed, <http://f1000r.es/2xs>]

Zoe Harclerode¹, John Andrzejowski¹, Stuart Coley², Richard Dyde²

¹Department of Anaesthesia, Royal Hallamshire Hospital, Sheffield, S10 2JF, UK

²Department of Radiology, Royal Hallamshire Hospital, Sheffield, S10 2JF, UK

v2 First published: 28 Oct 2013, 2:225 (doi: [10.12688/f1000research.2-225.v1](https://doi.org/10.12688/f1000research.2-225.v1))
 Latest published: 13 Feb 2014, 2:225 (doi: [10.12688/f1000research.2-225.v2](https://doi.org/10.12688/f1000research.2-225.v2))

Abstract

Bispectral index (BIS) is a monitoring modality designed and used for monitoring depth of anaesthesia. We wish to report a case where BIS monitoring may have alerted us to a potential adverse neurological event during angiographic coiling of a cerebral aneurysm.

Open Peer Review

Referee Status:

| | Invited Referees | | |
|---|------------------|------------|------------|
| | 1 | 2 | 3 |
| REVISED version 2 published 13 Feb 2014 | | report | report |
| version 1 published 28 Oct 2013 | report | report | report |

- 1 **Ehab Farag**, The Cleveland Clinic Foundation USA
- 2 **Luzius A Steiner**, University Hospital Basel Switzerland
- 3 **Mark Coburn**, University Hospital RWTH Aachen Germany

Discuss this article

Comments (0)

Corresponding author: John Andrzejowski (john.andrzejowski@sth.nhs.uk)

How to cite this article: Harclerode Z, Andrzejowski J, Coley S and Dyde R. **Bispectral index detects intraoperative cerebral ischaemia during balloon assisted cerebral aneurysm coiling [v2; ref status: indexed, <http://f1000r.es/2xs>]** *F1000Research* 2014, **2**:225 (doi: [10.12688/f1000research.2-225.v2](https://doi.org/10.12688/f1000research.2-225.v2))

Copyright: © 2014 Harclerode Z *et al.* This is an open access article distributed under the terms of the [Creative Commons Attribution Licence](#), which permits unrestricted use, distribution, and reproduction in any medium, provided the original work is properly cited. Data associated with the article are available under the terms of the [Creative Commons Zero "No rights reserved" data waiver](#) (CC0 1.0 Public domain dedication).

Grant information: The author(s) declared that no grants were involved in supporting this work.

Competing interests: No competing interests were disclosed.

First published: 28 Oct 2013, **2**:225 (doi: [10.12688/f1000research.2-225.v1](https://doi.org/10.12688/f1000research.2-225.v1))

First indexed: 19 Feb 2014, **2**:225 (doi: [10.12688/f1000research.2-225.v2](https://doi.org/10.12688/f1000research.2-225.v2))

REVISED Amendments from Version 1

In our revised case report we have made it clearer that following balloon occlusion of the MCA, the BIS numbers dropped after a delay of about 30 seconds taking another minute to reach their nadir. We have pointed out in Figure 2 that there was no EMG interference during the case and that no medications such as muscle relaxants can explain why the BIS dropped repeatedly in this clinical scenario. We have made it clearer that BIS is not a substitute for full EEG monitoring and that BIS values are not guaranteed to change during periods of cerebral ischaemia since this monitor was never designed for this purpose. We have explained why some types of ischaemia might not affect the Bispectral index. We postulate that the BIS values dropped as a result of cerebral hypo-perfusion each time the balloon occluded flow in the MCA, we have however adapted our discussion to read that this is just our opinion based on the clinical scenario and cannot be conclusively proven.

See referee reports

Case

Bispectral index (BIS) is a monitoring modality designed and used for monitoring depth of anaesthesia. However, it may also have other advantages in detecting intracranial haemodynamic events¹⁻³. We wish to report a case where BIS monitoring may have alerted us to a potential adverse neurological event during angiographic coiling of a cerebral aneurysm.

A 56 year old, right handed male was listed for coiling of an unruptured intracranial aneurysm. The aneurysm was discovered as an incidental finding on a CT scan of the head performed for the investigation of a previous episode of confusion. Cerebral angiography demonstrated an approximately 12mm wide necked aneurysm at the termination of the intracranial segment of the left internal carotid artery (ICA) (Figure 1). The patient's past medical history included hypertension and heavy smoking and he had a BMI of 32.

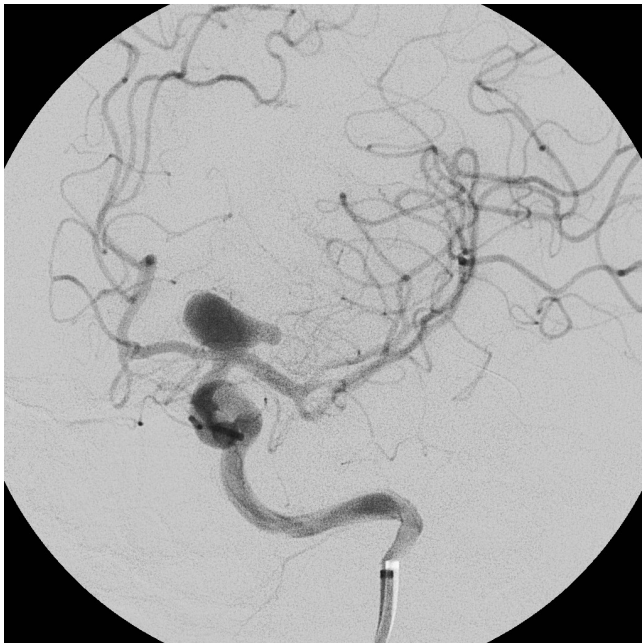

Figure 1. Cerebral angiography demonstrated a wide necked aneurysm at the termination of the ICA.

A small premedication dose of 2mg intravenous midazolam was given whilst an arterial line was inserted to allow continuous invasive intra-arterial blood pressure monitoring. Standard AAGBI monitoring was supplemented with BIS (Aspect Medical Systems, Newton MA, USA) that was positioned over the forehead and left temporal area before induction. An infusion of TCI (target controlled infusion) remifentanyl was then commenced with an effect site (Cet) of 2ng/ml increasing to 4ng/ml before induction, which consisted of 140mg propofol, with rocuronium 60mg given to facilitate tracheal intubation.

Anaesthesia was maintained with sevoflurane (end tidal concentration 1.2–1.4) and TCI remifentanyl continued at Cet of 4ng/ml, targeting a BIS range of 40–55. A metaraminol infusion was used to maintain a systolic blood pressure between 110–130mmHg. End tidal CO₂ was maintained in the range of 4.5–5.1kPa.

Coiling was performed with vascular access obtained via a right femoral arterial puncture. Using a guide catheter placed in the extra-cranial segment of the left ICA, a balloon catheter was navigated into the intracranial circulation. The inflatable/deflatable 4mm balloon was positioned across the neck of the aneurysm and during inflation there was simultaneous occlusion of the neck of the aneurysm and the proximal segment of the left middle cerebral artery (MCA). The balloon was intermittently inflated across the neck of the aneurysm to prevent coil prolapse during placement of 11 platinum microcoils into the aneurysm. Each inflation lasted in the order of 30–120 seconds. An intravenous bolus of 5000 units of Heparin was given to minimize the risk of thromboembolism associated with the endovascular devices.

The photograph of the intraoperative BIS trend (Figure 2) shows that each time the balloon was inflated, after an initial 30–40 second delay (the monitor was set to a 30 second smoothing interval), the

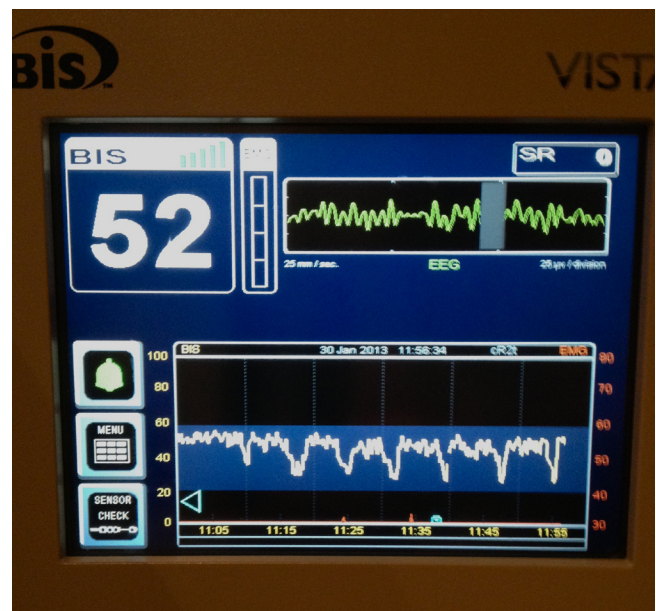


Figure 2. Photograph demonstrating repeated falls in BIS value with each balloon inflation, with rapid recovery to pre-inflation value upon deflation.

BIS value fell to a value of approximately 25 over a 60 second period. Upon balloon deflation, BIS seemed to return more rapidly to its pre-inflation value. The red right hand scale in [Figure 2](#) shows that there was no EMG interference that could have contributed to these changes, nor had there been any coincidental haemodynamic variation. No muscle relaxants or drugs other than those outlined above, had been administered. The anaesthetic team alerted the neuro-radiologists to these changes. They were able to limit the duration of subsequent balloon inflations resulting in demonstrably shorter subsequent BIS falls as seen in [Figure 2](#).

Post procedure, the patient was woken up and on return to the ward had a GCS of 15 with no neurological deficit. He was discharged home after 48 hours and has recovered well at home with no problems.

Discussion

This case illustrates a sudden, reversible and repeated decrease in intraoperative Bispectral Index (BIS) values during a balloon coiling of an intracerebral aneurysm. One possible explanation is that the monitor detected repeated periods of cerebral hypoperfusion. An abrupt decrease in BIS values not associated with changes in anaesthetic technique or haemodynamics may alert the anaesthetist to such an event. In this case there was no change in blood pressure, there had been no drugs administered such as muscle relaxants and there was no recorded EMG interference. Early communication with the surgeon or interventionist in such cases could potentially avoid procedure related neurological injury.

There have been previous case reports of sudden decreases in BIS value during other neurosurgical and neuro-radiological interventions. These include rupture of cerebral aneurysms during coiling¹, embolization of arterio-venous malformations² and intraventricular haemorrhage during third ventriculostomy³. Rapid increases in intracranial pressure and vasospasm have been postulated as possible causes for the decrease in BIS values.

The aneurysm in this case was on the ICA at the termination of the vessel. The angiographic balloon was placed via the ICA into the proximal MCA. Balloon inflation with simultaneous occlusion of the distal ICA and proximal middle cerebral arteries is more hazardous than the same procedure confined to the ICA as complete occlusion of the carotid tip prevents collateral flow from the contralateral circulation to the MCA (via the circle of Willis). Repeated balloon inflation within a vessel may lead to platelet aggregation or vessel wall injury with subsequent neurological injury. However, in this case the repeated acute change in the BIS values with rapid

return to baseline values, suggests a haemodynamic, rather than a thromboembolic, insult to the distal circulation.

BIS has a limited ability to detect ischaemia since, similarly to Near Infra Red Spectroscopy (NIRS), in its usual montage it only monitors a *frontal lobe*. It cannot be compared to a traditional 16 channel EEG that monitors the whole brain, and should not be considered as a standard of care for detecting cerebral ischaemia.

In this patient, the BIS sensor was positioned to primarily monitor the cerebral hemisphere undergoing intervention. BIS has not been developed for the purpose of detecting cerebral ischaemia, nor is it guaranteed to do so. Studies investigating the effects of cerebral ischaemia (such as during carotid endarterectomy) on BIS have been contradictory with some demonstrating a correlation with ischaemia whilst others shown none^{4,5}. This apparent inconsistency is at least partially explained by distal collateral circulation being able to compensate for some causes of more proximal cerebral ischaemia. Subtle ischaemia is also unlikely to be picked up using a unilateral BIS montage. The advent of a bilateral BIS sensor for general anaesthesia⁶ may shed more light on these discrepancies and allow more subtle changes to be detected since they could potentially result in left to right hemispheric BIS differences.

Not all balloon assisted neuro-radiological procedures will result in potential ischaemia, however those involving vascular territories with poor collateral circulation might benefit from the use of BIS (ideally in a bilateral array) as a tool to detect early and potentially avoidable adverse neurological events.

Consent

Written informed consent for publication of their clinical details and clinical images was obtained from the patient.

Author contributions

JA and ZH conceived the idea. SC and RD were the neuro-radiologists involved with the case in question.

ZH prepared the first draft of the manuscript, with all authors contributing to revisions of the draft and all authors have agreed to the final content.

Competing interests

No competing interests were disclosed.

Grant information

The author(s) declared that no grants were involved in supporting this work.

References

- Prabhakar H, Ali Z, Rath GP, *et al.*: **Zero bispectral index during coil embolization of an intracranial aneurysm.** *Anesth Analg.* 2007; **105**(3): 887–8. [PubMed Abstract](#) | [Publisher Full Text](#)
- Unnikrishnan KP, Sinha PK, Sriganesh K, *et al.*: **Case report: alterations in bispectral index following absolute alcohol embolization in a patient with intracranial arteriovenous malformation.** *Can J Anaesth.* 2007; **54**(11): 908–11. [PubMed Abstract](#) | [Publisher Full Text](#)
- Eapen G, Andrzejowski J: **Sudden decrease of Bispectral index during**

- endoscopic neurosurgery.** *J Neurosurg Anesthesiol.* 2009; **21**: 274–82.
4. Estruch-Pérez MJ, Ausina-Aguilar A, Barberá-Alacreu M, *et al.*: **Bispectral index changes in carotid surgery.** *Ann Vasc Surg.* 2010; **24**(3): 393–9.
[PubMed Abstract](#) | [Publisher Full Text](#)
 5. Bonhomme V, Desiron Q, Lemineur T, *et al.*: **Bispectral index profile during carotid cross clamping.** *J Neurosurg Anesthesiol.* 2007; **19**(1): 49–55.
[PubMed Abstract](#) | [Publisher Full Text](#)
 6. Smith M, Wiles M, Andrzejowski J: **Interhemispheric EEG variability measured using a bilateral Bispectral Index (BIS) sensor.** *J Neurosurg Anesthesiol.* 2012; **24**: 244.

Open Peer Review

Current Referee Status:



Version 2

Referee Report 25 June 2014

doi:10.5256/f1000research.3808.r5230



Mark Coburn

Department of Anesthesiology, University Hospital RWTH Aachen, Aachen, Germany

I approve of the revisions the authors have made.

I have read this submission. I believe that I have an appropriate level of expertise to confirm that it is of an acceptable scientific standard.

Competing Interests: No competing interests were disclosed.

Referee Report 19 February 2014

doi:10.5256/f1000research.3808.r3669



Luzius A Steiner

Department of Anaesthesia, University Hospital Basel, Basel, Switzerland

Thank you for revising your manuscript. In this revised form I do not have any further reservations.

I have read this submission. I believe that I have an appropriate level of expertise to confirm that it is of an acceptable scientific standard.

Competing Interests: Speaker honoraria and travel expenses from Covidien.

Version 1

Referee Report 30 January 2014

doi:10.5256/f1000research.2735.r2943



Mark Coburn

Department of Anesthesiology, University Hospital RWTH Aachen, Aachen, Germany

The conclusions which the authors draw from this case report are far too strong and need to be adapted.

I have read this submission. I believe that I have an appropriate level of expertise to confirm that it is of an acceptable scientific standard, however I have significant reservations, as outlined above.

Competing Interests: No competing interests were disclosed.

Referee Report 27 December 2013

doi:10.5256/f1000research.2735.r2216



Luzius A Steiner

Department of Anaesthesia, University Hospital Basel, Basel, Switzerland

This is an interesting case report. However, the discussion is somewhat superficial. I have two comments:

1. Please make it clear that the sensitivity to detect cerebral ischemia by EEG is not perfect and that the BIS monitor has not been developed for this purpose. Please explain why you think that an ischemic event would lead to a decrease in the BIS value from approximately 50 to 25 in your case (but not in all cases e.g. your references).
2. What is the temporal relationship between the balloon inflation and the BIS value. You state that it "fell to approximately 25 over a 60 second period". Theoretically, I would expect some delay before the BIS reacts (already because it samples over 15 or 30 seconds to calculate the BIS value; which sampling interval did you use?). Is there an alternative explanation you could offer (e.g. did you check the EMG value)? Did you administer neuromuscular blockers or other drugs prior to balloon inflation, is it possible that you recorded an artifact of some type? Please expand your case description and the discussion.

I have read this submission. I believe that I have an appropriate level of expertise to confirm that it is of an acceptable scientific standard, however I have significant reservations, as outlined above.

Competing Interests: No competing interests were disclosed.

Referee Report 05 November 2013

doi:10.5256/f1000research.2735.r2214



Ehab Farag

Department of General Anesthesiology and Outcomes Research, The Cleveland Clinic Foundation, Cleveland, OH, USA

The authors should mention that BIS has a very limited ability to detect ischemia as it only monitors the frontal lobe. Therefore it cannot be compared to traditional 16 channels EEG or NIRS to detect cerebral ischemia. This case should not be used as standard for care for using BIS as a monitor for cerebral ischemia.

I have read this submission. I believe that I have an appropriate level of expertise to confirm that it is of an acceptable scientific standard, however I have significant reservations, as outlined above.

Competing Interests: No competing interests were disclosed.

Author Response (*Member of the F1000 Faculty*) 13 Nov 2013

John Andrzejowski, Department of Anaesthesia, Royal Hallamshire Hospital, UK

I agree with Dr Farag's comments. I would be happy to change the discussion to read:

BIS has a limited ability to detect ischemia since, similarly to Near Infra Red Spectroscopy (NIRS), in its usual montage it only monitors a frontal lobe. It cannot be compared to a traditional 16 channel EEG that monitors the whole brain, and should not be considered as a standard of care for detecting cerebral ischaemia.

In this patient, the BIS sensor was positioned to primarily monitor the cerebral hemisphere undergoing intervention.

Studies investigating the effects of cerebral ischaemia (such as during carotid endarterectomy) on BIS have been contradictory with some demonstrating a correlation with ischaemia whilst others show none^{4,5}. The advent of a bilateral BIS sensor for general anaesthesia⁶ may shed more light on these discrepancies and allow more subtle ischaemic changes (possibly resulting in left to right BIS differences) to be detected.

Competing Interests: one of the authors of the article