


Parenteral hydroxocobalamin dose intensification in five patients with different types of early onset intracellular cobalamin defects: Clinical and biochemical responses

Emmanuel Scalais¹  | Elise Osterheld^{1,2} | Christine Geron² | Charlotte Pierron² | Ronit Chafai² | Vincent Schlessler³ | Patricia Borde⁴ | Luc Regal⁸ | Hilde Laeremans⁵ | Koen L. I. van Gassen⁶ | L. Bert van den Heuvel⁷ | Linda De Meirleir^{8†}

¹Pediatric Neurology, Centre Hospitalier de Luxembourg, Luxembourg

²Department of Pediatrics, Centre Hospitalier de Luxembourg, Luxembourg

³Laboratoire de Chimie et Hématologie, Centre Hospitalier de Luxembourg, Luxembourg

⁴Service de Biochimie, Laboratoire National de Santé, Dudelange, Luxembourg

⁵Laboratoire de Pédiatrie, ULB, Brussels, Belgium

⁶Department of Genetics, UMC, Utrecht, The Netherlands

⁷Department of Genetics, Radboud University Medical Center, Nijmegen, The Netherlands

⁸Pediatric Neurology and Metabolism, UZ-VUB, Vrije Universiteit Brussels, Brussels, Belgium

Correspondence

Emmanuel Scalais, Centre Hospitalier de Luxembourg, 4 Rue Barblé, L-1210, Luxembourg.
Email: emmanuel.scalais@gmail.com, scalais.emmanuel@chl.lu

Communicating Editor: Manuel Schiff

Abstract

Intracellular cobalamin metabolism (ICM) defects can be present as autosomal recessive or X-linked disorders. Parenteral hydroxocobalamin (P-OHCbl) is the mainstay of therapy, but the optimal dose has not been determined. Despite early treatment, long-term complications may develop. We have analyzed the biochemical and clinical responses in five patients with early onset of different types of ICM defects (cblC: patients 1-3; cblA: patient 4; cblX: patient 5) following daily P-OHCbl dose intensification (DI). In patient 4, P-OHCbl was started at age 10 years and in patient 5 at age 5 years. OHCbl was formulated at either, 5, 25, or 50 mg/mL. P-OHCbl was intravenously or subcutaneously (SQ) delivered, subsequently by placement of a SQ injection port except in patient 4. In all patients, homocysteine and methylmalonic acid levels, demonstrated an excellent response to various P-OHCbl doses. After age 36 months, patients 1-3 had a close to normal neurological examination with lower range developmental quotient. In patient 3, moderate visual impairment was present. Patient 4, at age 10 years, had normal renal, visual and cognitive function. In cblX patient 5, epilepsy was better controlled. In conclusion, P-OHCbl-DI caused an excellent control of metabolites in all patients. In the three cblC patients, comparison with patients, usually harboring identical genotype and similar metabolic profile, was suggestive of a positive effect, in favor of clinical efficacy. With P-OHCbl-DI, CblA patient has been placed into a lower risk to develop renal and optic impairment. In cblX patient, lower P-OHCbl doses were administrated to improve tolerability.

KEYWORDS

early onset cobalamin metabolism defects, hemolytic-uremic syndrome, homocysteine, methylmalonic aciduria, methylmalonic aciduria with homocystinuria, parenteral hydroxocobalamin dose intensification, subcutaneous injection port

[†]Prof. Linda De Meirleir passed away on October 31, 2018.

This work was presented by E.S. at the ICIEM in Rio in 09.2017, which was sponsored by Shire Company.

This is an open access article under the terms of the Creative Commons Attribution License, which permits use, distribution and reproduction in any medium, provided the original work is properly cited.

© 2019 The Authors. *Journal of Inherited Metabolic Disease* published by John Wiley & Sons Ltd on behalf of SSIEM.

1 | INTRODUCTION

Autosomal recessive disorders of intracellular cobalamin metabolism (ICM), designated as cblA-cblJ,¹ can give rise, either to a deficiency of methylmalonyl-CoA mutase (cblA, cblB, and cblD variant 2) resulting in isolated methylmalonic aciduria, or to a deficiency of methionine synthase (cblD variant 1, cblE, and cblG) resulting in isolated homocystinuria or to both, (cblC, classic cblD, cblF, and cblJ), resulting in combined methylmalonic aciduria and homocystinuria. Cobalamin C (cblC) defect is the most common subgroup of inborn errors in ICM.

The spectrum of this disorder extends from fetal to adulthood period, with perinatal, early onset (EO) infantile presentation before 1 year of age, childhood (CO) (after the first year of age), adolescent and adult onset. The EO is the most frequently recognized. Infrequently (10%-20%), at initial presentation, Cbl C patients presented a hemolytic-uremic syndrome (HUS).^{2,3} In the Caucasian population, the cblC variant c.271dupA, p.(Arg91fs), accounts for 42% of mutant alleles.⁴ In Europeans, both variants c.271dupA and c.331C>T, in the homozygous or compound heterozygous state, were primarily observed in EO cases.³⁻⁵ Genotype has been reported as very predictive of visual impairment, homozygous c.271dupA p.(Arg91fs) patients being severely and universally affected.⁶ P-OHCbl is the mainstay of therapy.^{2,7} In a few patients, with sub-optimal metabolic control, P-OHCbl dose escalation has been tried^{8,9} in order to improve long-term outcome. In cblA defect, caused by a pathogenic MMAA variant,¹⁰ chronic renal disease (CRD) may constitute long-term sequelae, despite OHCbl therapy^{11,12} and rarely, mild optic nerve atrophy.¹³ Therapy involves OHCbl.¹⁴ cblX defect, an X-linked ICM disorder, with methylmalonic acidemia and homocystinemia, is caused by a pathogenic HCFC1 variant, resulting in transcriptional dysregulation involving many genes. Despite representing a broader neurodevelopmental phenotype, severe MMACHC down-regulation has been observed in cblX patients.¹⁵ The aim of this study was to evaluate the clinical and biochemical response of P-OHCbl-DI in patients with different types of EO ICM defects, including cblC, cblA, and cblX.

2 | PATIENTS AND METHODS

In five patients, with EO of different ICM defects (cblC: patients 1, 2, 3; cblA: patient 4; cblX: patient 5), clinical and biochemical responses were evaluated following daily P-OHCbl-DI. OHCbl was formulated at either, 5, 25, or 50 mg/mL. P-OHCbl doses were intravenously (IV) or subcutaneously (SQ) delivered, subsequently by placement of a subcutaneous injection port (i-Port Advance TM) to

minimize cutaneous punctures except in patient 4. Neuropsychologic development was assessed by using ET 6-6-R¹⁶ in cblC patients, and WISC-IV (verbal scale) in cblA patient. In all patients, brain MRI was performed as well as in cblC patients 1 and 3, optical coherence tomography (OCT). All procedures followed were in accordance with the Helsinki Declaration of 1975.

3 | PATIENT 1 AND 2

Since birth, patients 1 and 2, twin girls, presented anorexia, lethargy, failure to thrive, neutropenia (240 and 370 G/L, normal >1500) and nystagmus. On admission, at age 3 weeks, both plasma total homocysteine (tHcy) and urinary methylmalonic acid (uMMA) values were elevated. Subsequently, both infants were treated (day one) with P-OHCbl (0.31 mg/kg/day) supplemented with oral betaine (100 mg/kg/day), folinic acid (5 mg/day), and oral L-carnitine (50 mg/kg/day), which was followed by clinical improvement. The biomarker response, at onset and following P-OHCbl-DI, is represented in Figure 1A-F. Molecular analysis revealed homozygosity for the c.271dupA (p. Arg91fs) variant. Twin zygosity DNA testing confirmed monozygotic twins. At age 32 months, in both patients, no abnormal eye movements, such as nystagmus, were observed, except in patient 1, mild intermittent, small ocular jerks. Daily P-OHCbl dose was 2.40 mg/kg. In both siblings, the neurological examination was normal except for hypotonia. Patient 1 walked independently at age 20 months and patient 2 at age 25 months. At age 3 years, both infants could pronounce three-word sentences in two languages and use two personal pronouns. Both patients could build a tower of more than six blocks, master her pincer grasp with right-hand preference and making circular and both horizontal and vertical line with three-digital grasp in patient 1 and palmar grasp in patient 2. Results of developmental, ophthalmologic and MRI evaluations are shown in Table 1.

4 | PATIENT 3

At age 3 weeks, cblC patient 3, a boy, presented anorexia and peri-orificial dermatitis. He was admitted at age 27 days with multi-organ failure and metabolic acidosis (anion gap: 21 mmol/L, normal 8-16). He had a HUS, characterized by the triad²² of hemolytic anemia (8.0 g/dL, normal >10), uremia (80-117 mg/dL, normal <50) and thrombocytopenia (10 G/L, normal >230). On blood smear, schizocytes (2%) as well as neutropenia (620 G/L, normal >1500) were found. Following a high tHcy level, (at day 2), IV OHCbl (4.1 mg/kg/day) was administered, supplemented with oral

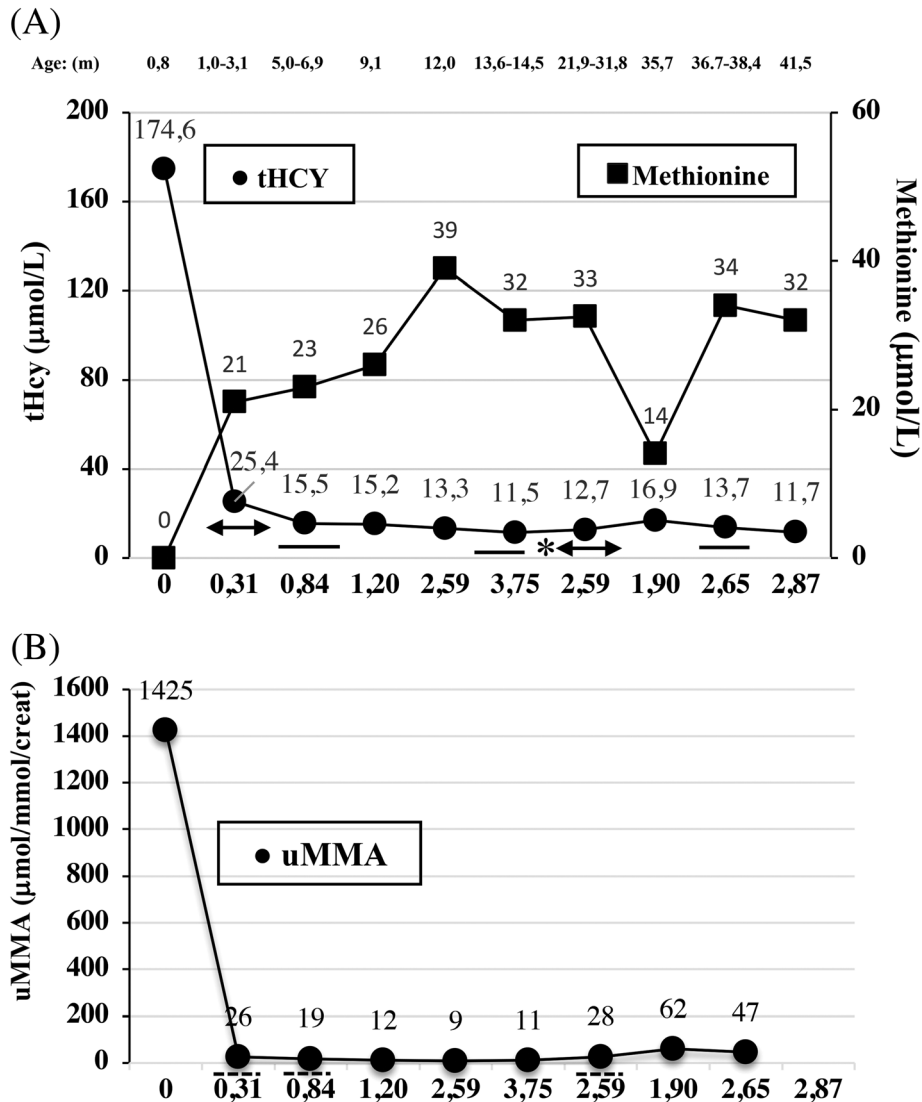
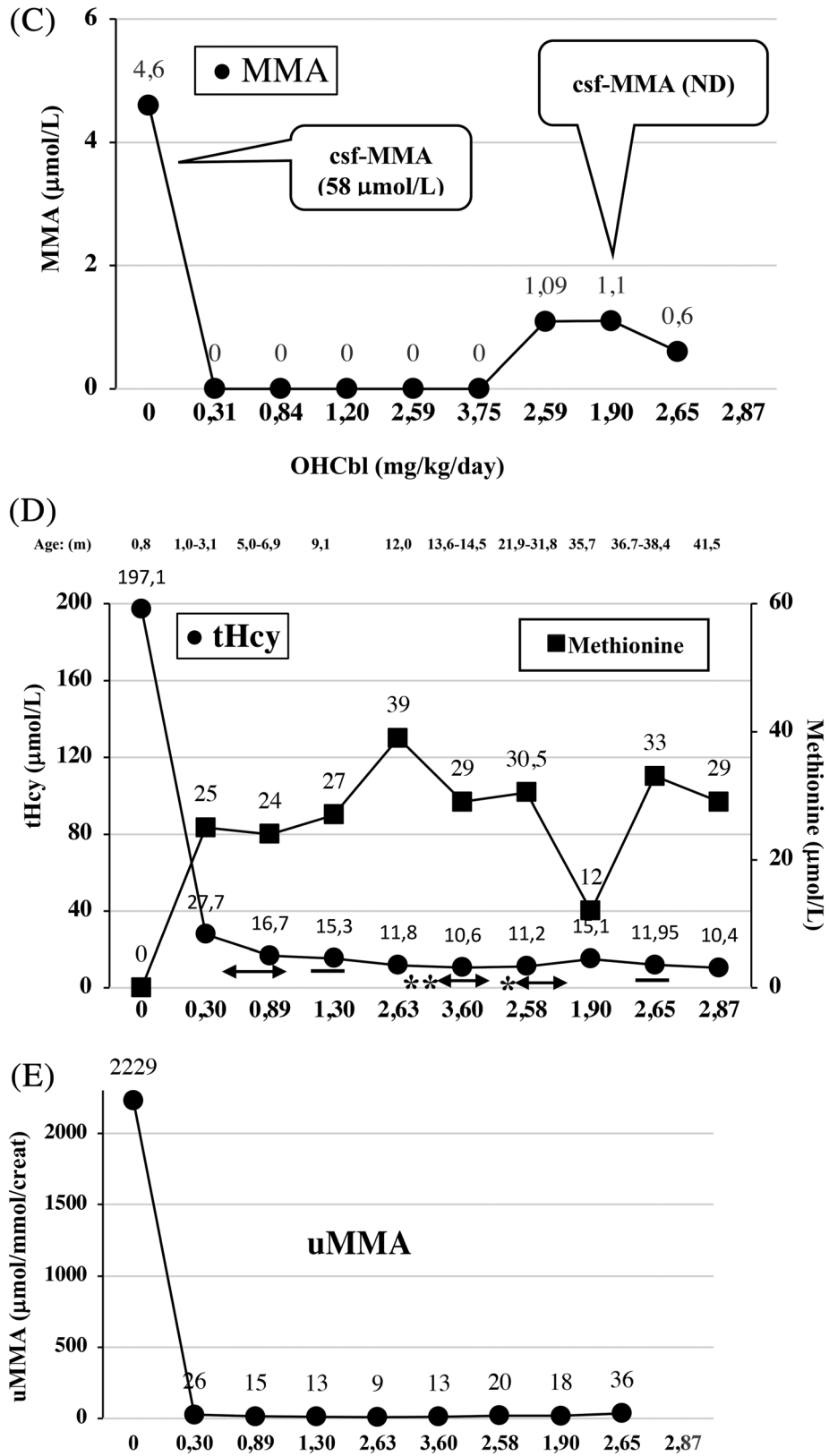


FIGURE 1 OHcbl dose reduction of tHcy, MMA, uMMA and csf-MMA values and increase in methionine levels. Normal levels: tHcy <10.0 μmol/L, methionine 10-40 μmol/L, uMMA <17 μmol/mmol/creat, MMA, and csf-MMA 0 μmol/L). cblC patients 1 and 2: A and D, tHcy (black line and double arrow) levels were obtained as mean between (n = 4) age 1.0 and 3.1 months; (n = 2) age 5.0 and 6.9 months; (n = 2), 13.6 and 14.5 months; (n = 3) age 21.9 and 31.8 months; (n = 2) age 36.7 and 38.4 months). The significance has been determined by unpaired *t* test (***P* = .01, **P* < .05) for plasma homocysteine levels (double arrow) and is referring to the previous values (double arrow). B and E, uMMA (dotted line) levels were obtained as mean (n = 4) between age 1.0 and 3.1 months; (n = 2) between age 5.0 and 6.9 months; (n = 2) between age 21.9 and 31.8 months). C and F, MMA, initial csf-MMA and at age 35.7 months. cblC patient 3: G, tHcy (both horizontal black line and double arrow) levels were obtained as mean between (n = 2) age 4.8 and 5.1 months; (n = 7) age 6.9 and 18.4 months; (n = 4) age 21.2 and 38.8 months). Vertical black arrow: (at age 6.2 months) double dose during 48 hours. The significance has been determined by unpaired *t* test (**P* < .05) for tHcy (horizontal double arrow) and is referring to the previous values (horizontal double arrow). (H) uMMA (n = 6) and MMA (n = 5) (horizontal dotted line) levels were obtained as mean between age 6.9 and 18.4 months. Initial csf-MMA levels. cblA patient 4: (I) uMMA (n = 7) (dotted line) levels were obtained as mean between age 6.9 and 18.4 months (range: 77-2542). cbl X patient 5: J, dotted line: oral OHcbl *: P-OHcbl (5 mg twice a week = 0.07 mg/kg/day) black vertical arrow: no OHcbl during 7 days. Abbreviations are as follows: m: months; yrs: years; tHcy: plasma total homocysteine; (u) (csf) MMA: (urinary) (cerebro-spinal fluid) methylmalonic acid; ND: not detected; IV-OHcbl: intravenous hydroxocobalamin, S/Q-OHcbl: subcutaneous hydroxocobalamin (formulated at 5 mg/mL and 25 mg/mL); i-port: subcutaneous injection port (i-port advance TM) (formulated at 25 mg/mL and/or 50 mg/mL). OHcbl blood levels: (dose of 2.41 mg/kg/day: 17.5×10^6 pg/mL in cblC patient 1 and 17.0×10^6 pg/mL in cblC patient 2); (dose of 2.98 mg/kg/day: 11.0×10^6 pg/mL in cblC patient 3); (dose of 0.88 mg/kg/day: 4.80×10^6 pg/mL in cblA patient 4); (dose of 0.21 mg/kg: 3.40×10^6 pg/mL in cblX patient 5) (normal <1999 pg/mL)

betaine (150-200 mg/kg/24 hours) and both IV folinic acid (5 mg) and L-carnitine (100 mg/kg). In spite of infrequently used,²³ oral methionine dose was initially started at

33 mg/kg/day and interrupted at age 10 months. The biomarker response at onset and following P-OHcbl-DI is reported in Figure 1G,H. Molecular analysis revealed the

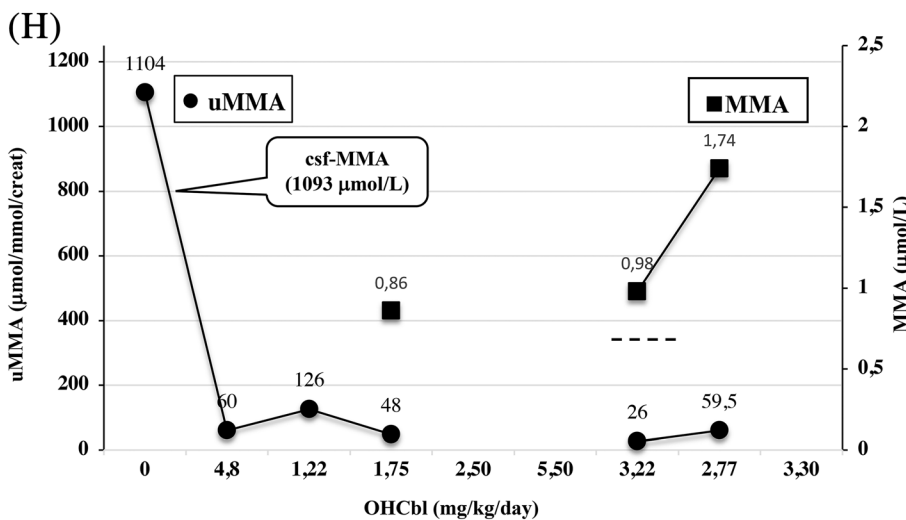
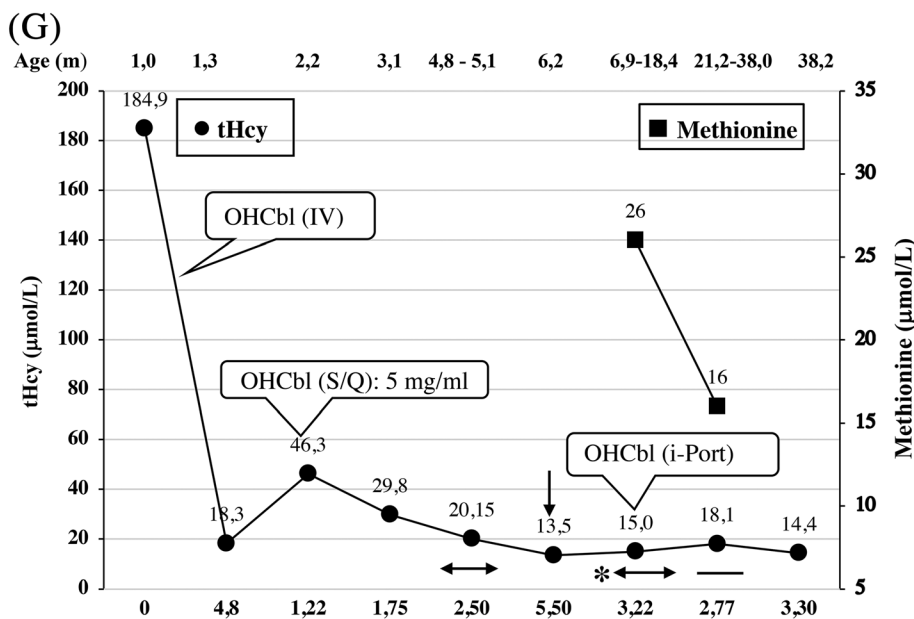
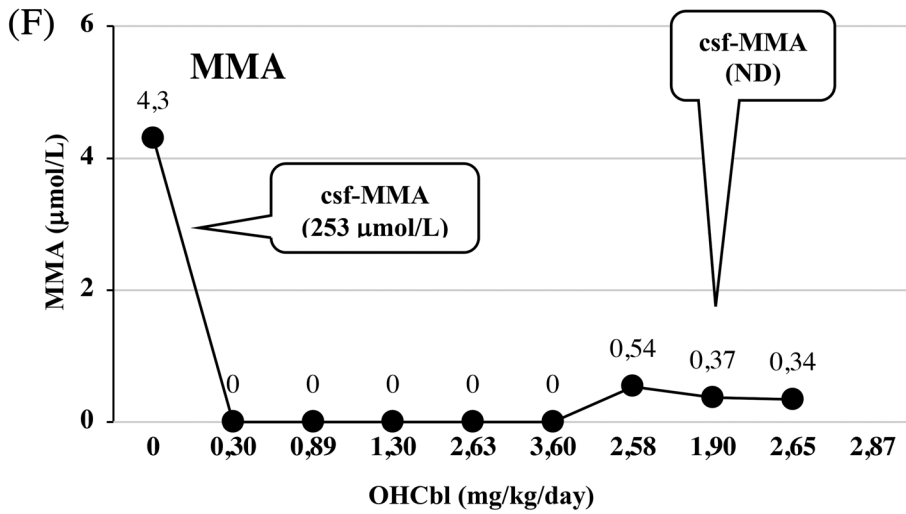
FIGURE 1 Continued



homozygous c.271dupA (p.Arg91fs) variant. Progressively, multi-organ failure resolved. At age 5 months, he had cholangitis (total biliary acid levels 20.5 µmol/L, normal <10). P-OHCbl doses were increased from a mean value of 2.50 to

3.20 mg/kg/day resulting in normal total plasma biliary acid levels at age 22 months (3.3 µmol/L, normal <10). Despite moderate visual impairment with right head tilt and nystagmus, visual performance improved both in the ability to fix and

FIGURE 1 Continued



follow. He walked independently at age 20 months. At age 24 months, he could speak several words in two languages and use onomatopoeia and gestural support (bye, bravo, pointer

finger such as designate familiar objects). Results of developmental, ophthalmologic, and MRI evaluations are shown in Table 1.

FIGURE 1 Continued

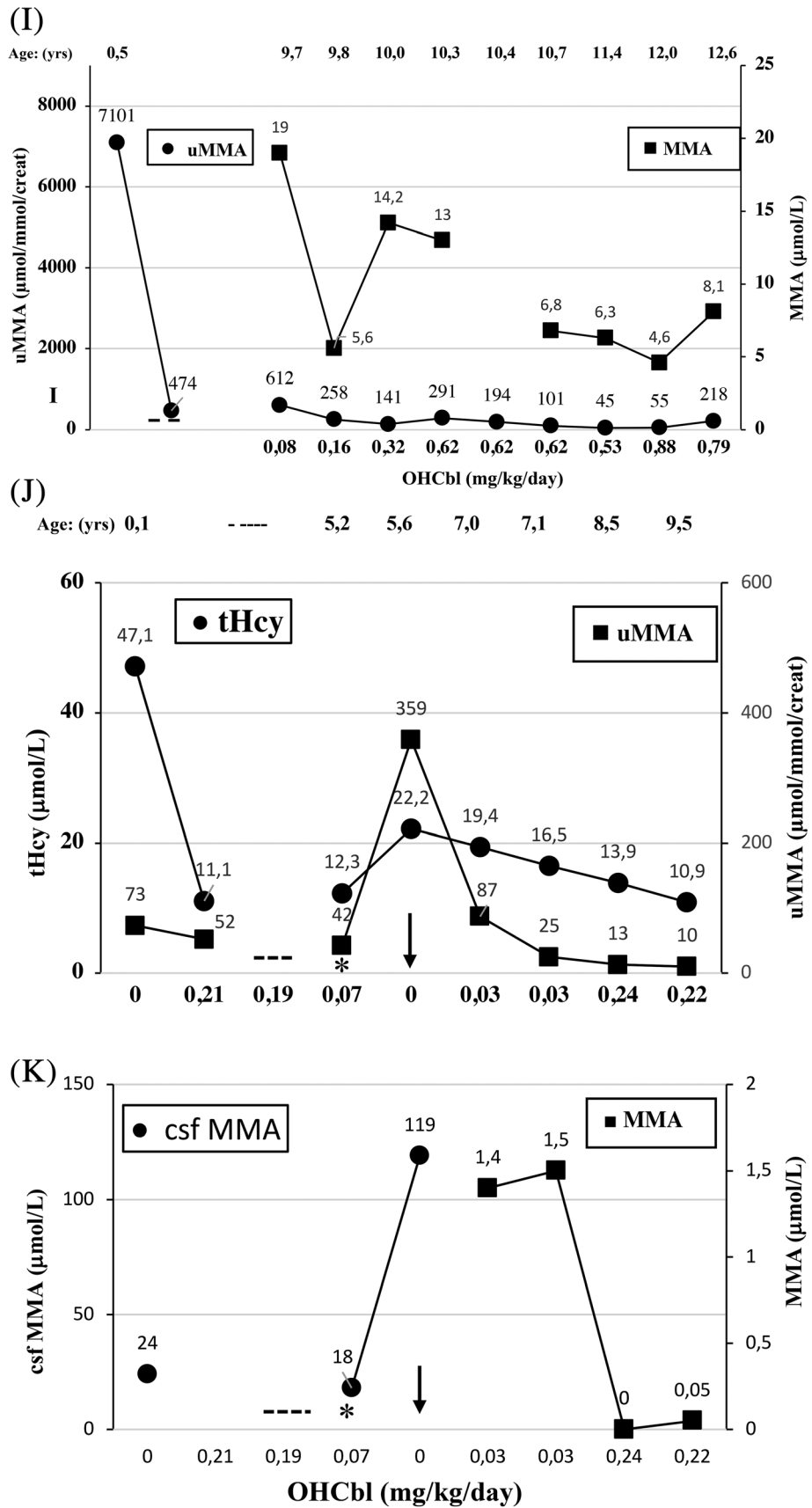


TABLE 1 Characteristics of reported EO cblC patients and the three EO cblC studied patients with usually identical genotype and similar metabolic profile

Age of onset (wk)	Visual function (at most recent exam)					Neuropsychological test: ^a DQ, ^b VABS, ^c WAIS-III, ^d ET 6-6-R							References				
	tHcy	Neur	N	ONP/A	PR	Acuity	MRI (age at study time)	cDNA	GM	FM/DLS	Communication	Cognitive		Social	Behav		
40*	EP, hy, μ	+	+	+	+	+	↓	Thinned CC-WM-GM- ↑T2-WM, VM, ↑T2-BG (27 mo)	NR	^b 37 ± 17***	53 ± 29	45 ± 18	b < p1	b < p1	b < p1	b < p1	Anderson et al ¹⁷
2	186		+/+	-	-	↓	↓	Thinned WM, moVM	c.271dupA/c.271dupA	↓	↓	↓	↓	↓	↓	↓	Autistic Sharma et al ¹⁹
NBS	hy	+	+/-	+	+	FAF		Thinned CC-WM (pv) (81 mo)	c.271dupA/c.271dupA	^b 25	20	33	48	31			Weisfeld-Adams et al ²⁰
NBS	hy	+	+/+	+	+	CSM		↑T2WM (pa) (49 mo)	c.271dupA/c.271dupA	97	105	72	97	91			
NBS	hy, μ	+	NR	NR	NR	NR		NP	c.271dupA/c.271dupA	72	85	85	79	77			
NBS	hy	+	**	-	-	FAF		NP	c.271dupA/c.271dupA	90	75	75	82	78			
NR	NR	E	+/+	+	+	Fx		miA (cerebrum, cerebellum)	c.271dupA/c.271dupA				P:49				Bellerose et al ²¹
4	203	hy	-	-	-	Fx		Thinned CC-WM	c.271dupA/c.271dupA	^b p3	p2	p3	p4	p1			
6	NR	μ , E	+/+	+	+	LP		Thinned CC-WM	c.271dupA/c.271dupA	^b < p1	< p1	< p1	< p1	< p1			
3	40-110	E, hy	BEM	+	+	CuSuM		ND	c.271dupA/c.271dupA	↓(severe)	↓(severe)	↓(severe)	↓	↓			Ku et al ³
1 ^s	60-100	DD	BEM	-	-	CSM		ND	c.271dupA/c.271dupA	↓(mild)	↓(mild)	↓(mild)					
3	174.6	hy	-	-	-	CSM		↑T2WM (3 wk), NI ⁺ (36 mo)	c.271dupA/c.271dupA	^d 63	83	83	66-83	83	NI		This study
3	197.1	hy	-	-	-	CSM		↑T2WM (3 wk), NI ⁺ (36 mo)	c.271dupA/c.271dupA	63	83	83	66-83	83	NI		
4	184.9	-	-	-	-	CuSuM ⁺⁺		↑T2WM, VM (2 mo) thinned CC-WM, ↓VM (18 mo), My	c.271dupA/c.271dupA	87-100	87-100	87	87	87	NI		

Note. *: homocystine levels (normal 0 μ mol/L); **: macular lesion; ***: mean \pm SD; +: except mild ↑T2 periventricular parietal region; ++: electroretinogram; ↓: scotopic and photopic response and optical coherence tomography (OCT); thin intra-retinal cysts and irregularity of photoreceptors (both performed at age 27 months and stable at age 36 months); ↑T2: increase signal intensity in T2 sequence; \ddagger : OCT performed at age 3^{2/12} years; mild reduction of the external nuclear layer in the parafoveal region; \$: mother treated with P-OHCbl at her third trimester.

Abbreviations: BG, basal ganglia; CC, corpus callosum; CSM, central/steady/maintained vision; CuSuM, central, unsteady, unimpaired vision; E, epilepsy; EP, extra-pyramidal signs (progressive choreo-athetosis); FAF, fixates and follows; Fx, fixates; GM, gray matter; Hcy, homocystine levels (normal <10.0 μ mol/L); hy, hypotonia; LP, light perception; miA, mild atrophy; moVM, moderate ventriculomegaly; My, gain in myelination; mo, months; μ , microcephaly; Neur, neurological status; N, nystagmus; NBS, newborn screening; NI, normal; NP, not performed; ONP/A, optic nerve pallor/atrophy; PR, pigmentary retinitis; (pv) (pa), (periventricular) (periaxial); < p, less than percentile; WM: white matter; wk, week.

^aDQ: developmental quotient; GM: gross motor; FM: fine motor.

^bVABS: Vineland Adaptive Behavior Scale; DLS: daily live scale; Ction: communication; Social: socialization; Behav: adaptive behavior index.

^cWAIS-III: Wechsler Adult Intelligence Scale-III; V: verbal IQ; P: performance IQ.

^dET 6-6-R: assessment of a developmental status for children from 6 months to 6 years-revision.

5 | PATIENT 4

Patient 4, a boy, was born at term from non-consanguineous parents. He started to walk at age 18 months and speak sentences at 2½ years. Before admission, he was diagnosed as hypotonic with poor head control. At age 6 months, he showed metabolic acidosis with hyperketonemia. uMMA levels were markedly increased. Molecular analysis revealed a compound heterozygous variant in MMAA gene located on chromosome region 4q31.21, c.439+4_439+7del, p.? inherited from the mother and c.593_596del, (p. Thr198fs) inherited from the father. Initially, he was treated with dietary protein restriction supplemented with oral OHCbl (1 mg). He had several episodes of metabolic acidosis during intercurrent febrile infections. At age 9 years, daily P-OHCbl was initiated. The biomarker response, at onset, at age 9 years, and following P-OHCbl-DI is reported in Figure 1I. At age 10 years, his physical and neurological examination was normal. Ophthalmological examination was normal including eye fundus and visual field as well as his renal function. Performed at age 11½ years, both brain MRI and MR spectroscopy were normal. Cognitive level was also normal at age 8 years (WISC-IV: verbal scale 99).

6 | PATIENT 5

Patient 5, a boy, previously reported,²⁴ showed, at age 10 days, refractory seizures and high CSF glycine mimicking non-ketotic hyperglycinemia. Both urinary methylmalonic acid and plasma homocysteine were elevated. At age 5 years, he was diagnosed to be affected by the cblX defect. He resulted to carry a variant, in the global transcriptional coregulator, *HCFCl*. A hemizygous variant, c.2728A>G, (p. Lys910Glu) was also detected in *ATRX*. Clinically, this patient was characterized by severe developmental disability and intractable epilepsy. P-OHCbl (0.53 mg/kg/week) produced seizure and or involuntary movement exacerbation, despite metabolic improvement. However, macrocytosis was not corrected (mean corpuscular volume [MCV] 103.2 μ^3 , normal 76-91). At age 7 years, following a very slow increase in P-OHCbl doses, as shown in Figure 1J,K, a better improvement in seizure control was obtained, but not in neurological development. Macrocytosis, although less marked, was still present (MCV 99.5 μ^3 vs 105.4 and 106.6, normal 76-91) suggesting that his P-OHCbl dose was not yet sufficient.

7 | DISCUSSION

The three cblC patients harbor the most frequent variant which is, in the Caucasian population, c.271dupA (p.Arg91fs), located in

the MMACHC gene. Being homozygous, they belong to the EO with the highest risk to develop maculopathy, progressive retinopathy and cognitive delay.^{6,25,26} Usually, well treated infants, maintained, on follow-up, moderately elevated plasma tHcy levels (20-80 $\mu\text{mol/L}$) as well uMMA (10-100 $\mu\text{mol/mmol/Cr}$).¹ In contrast, in the three cblC patients, P-OHCbl-DI produced excellent biochemical responses such as lower range plasma tHcy and higher methionine values (Figure 1A,D,G) as well as low uMMA, csf-MMA and MMA levels (Figure 1B,C,E,F,H). Compared to cblC patients 1 and 2, cblC patient 3, initially required higher OHCbl doses, to control plasma tHcy values. This discrepancy could be related to disease severity, including HUS, multi-organ failure, metabolic acidosis and poor perfusion. Not surprisingly, before hospital discharge, at age 2.2 months, P-OHCbl, being formulated at 5 mg/mL, had to be temporally administrated at lower dose (1.22 mg/kg), which raised plasma tHcy and urinary MMA levels (Figure 1G,H). Subsequently, by using P-OHCBL-DI (2.50 mg/kg), formulated at 25 mg/mL and 50 mg/mL, plasma tHcy and uMMA levels decreased to lower values. At age 6.2 months, cblC patient 3 received, following medical order misinterpreted, double P-OHCbl dose (5.50 mg/kg/day), for 48 hours. Subsequently, plasma tHcy dropped from 22.5 to 13.5 $\mu\text{mol/L}$ (Figure 1G). However, how can we assume that such as P-OHCbl-DI could have had therapeutic effects on the three cblC patients? Although, the three cblC patients were promptly treated with P-OHCbl-DI, they were initially already symptomatic and EO CblC defect presents both developmental and degenerative features. Therefore, it was not surprising to have observed some degree of developmental and ocular manifestations in the three cblC patients. Our study was limited by the small number of patients who could not be randomized to different treatment doses. However, we found indirect evidence for the efficacy of higher doses of OHCbl. Following P-OHCbl-DI, nystagmus disappeared in cblC patients 1 and 2 and visual behavior significantly improved in cblC patient 3 with no sign of ocular disease progression at age 3 years. Compared to previous studies (Table 1), most of the EO cblC patients, usually harboring a homozygous c.271dupA (p.Arg91fs), with high initial tHcy (>60 $\mu\text{mol/L}$) or high homocysteine (>30 $\mu\text{mol/L}$) levels and treated at onset with low P-OHCbl dose, have prominent developmental delay, autistic features, pigmentary retinitis, optic atrophy, marked MRI abnormalities (ventriculomegaly, WM atrophy) and persistent moderately elevated plasma tHcy levels.¹⁷⁻²¹ Importantly, homozygous c.271dupA patients with, at onset, low plasma tHcy (<60 $\mu\text{mol/L}$) or homocysteine (<30 $\mu\text{mol/L}$), may have a better prognosis.²⁷

Similarly, the response of HUS to higher-doses of OHCbl in two CO cblC siblings has been specified.²⁸ These siblings required a serum cobalamin concentration of approximately 1×10^6 pg/mL to obtain clinical and biochemical responses. In another study,⁸ an EO cblC patient, with PR and mild developmental delay received,

at 1-month interval, an increasing dose regimen (0.35 mg/kg). This strategy resulted in an 80% and 55% reduction of plasma MMA and tHcy, respectively. Five other EO cblC patients,⁹ aged between 5 and 14 years, received also high P-OHCbl doses (0.1 mg/kg/day to 0.35 mg/kg/day), leading in patient 1 and patient 2 to reduction of tHcy (30% and 17%).

In the cblA patient, the c.439+4_439+7del p (?) variant inherited from the mother was predicted to delete the canonical splice site of exon 2.²⁹ Being at risk, before P-OHCbl-DI, to develop later mild optic neuropathy and/or CRD, because of previous uMMA levels above the approximate threshold of 2000 $\mu\text{mol}/\text{mmol}/\text{creatinine}$,^{12,13} the cblA patient 4 had normal visual and renal function on early follow up. The cblX patient responded biochemically and clinically only after slowly increasing the P-OHCbl dose and eventually achieved better seizure control. The poor clinical outcome could be related mainly to the HCFC1 variant, being a transcription factor involving many genes, and to a lesser extend to the ATRX variant.

In conclusion, this study showed an excellent biochemical response in all patients, and without significant side effects. Among the metabolic biomarkers, plasma tHcy was the most sensitive one. OHCbl dose-response relationship was only observed with plasma tHcy levels. Sustained absolute normal biomarker values were not obtained. In comparison with EO cblC patients usually harboring identical genotype and similar metabolic profile, we observed a better than expected outcome in the three cblC patients, suggestive of a positive effect of P-OHCbl-DI in favor of clinical efficacy, in particular, in view of the absence of progressive retinopathy, a more favorable cognitive outcome and improved brain myelination. With P-OHCbl-DI, CblA patient has been placed into a lower risk to develop CRD and or mild optic atrophy. In cblX patient, very slowly progressive increase in P-OHCbl dose was necessary to improve clinical tolerability and control seizures. Nevertheless, long-term follow-up of both cblC and cblA patients as well as larger population are needed to confirm this potential efficacy of P-OHCbl-DI. High-dose of P-OHCbl was also easier to administer to the child when P-OHCbl was formulated at 50 mg/mL and delivered by a SQ injection port.

ACKNOWLEDGMENTS

This work was made with the intense and fruitful collaboration with Prof. Linda De Meirleir who passed away on October 31, 2018. The authors are most grateful to the parents for their collaboration on this report, to Frederic Mataigne for brain MRI description, to Sandra Cardillo and Irina Balikova for ophthalmological investigations, to Georges Gilson for blood cobalamin levels measurement, and to Heather Cattell for revising this article.

CONFLICT OF INTEREST

None declared.

AUTHOR CONTRIBUTIONS

E.S. wrote the article, supervised the findings of this work, devised the project, and the main conceptual ideas. L.D.M. and L.R. supervised the metabolic evolution and worked on the article and revised the article. C.G. and C.P. evaluated the children initially and revised the article. R.C. and E.O. revised the article. H.L., P.B., and V.S. performed the biochemical analysis. K.L.I.v.G. and L.P.W.J.v.d.H. performed molecular analysis. All authors discussed the results and contributed to the final article.

ORCID

Emmanuel Scalais  <https://orcid.org/0000-0002-3326-4470>

REFERENCES

1. Sloan JL, Carrillo N, Adams D, Venditti CP. Disorders of intracellular cobalamin metabolism. *GeneReviews [Internet]*. 2018.
2. Huemer M, Diodato D, Schwahn B, et al. Guidelines for diagnosis and management of the cobalamin-related remethylation disorders cblC, cblD, cblE, cblF, cblG, cblJ and MTHFR deficiency. *J Inherit Metab Dis*. 2017;40:21-48.
3. Nogueira C, Aiello C, Cerone R, et al. Spectrum of MMACHC mutations in Italian and Portuguese patients with combined methylmalonic aciduria and homocystinuria, cblC type. *Mol Genet Metab*. 2008;93:475-480.
4. Lerner-Ellis JP, Anastasio N, Liu J, et al. Spectrum of mutations in MMACHC, allelic expression, and evidence for genotype-phenotype correlations. *Hum Mutat*. 2009;30:1072-1081.
5. Lerner-Ellis JP, Tirone JC, Pawelek PD, et al. Identification of the gene responsible for methylmalonic aciduria and homocystinuria, cblC type. *Nat Genet*. 2006;38:93-100.
6. Brooks BP, Thompson AH, Sloan JL, et al. Ophthalmic manifestations and long-term visual outcomes in patients with cobalamin C deficiency. *Ophthalmology*. 2016;123:571-582.
7. Rosenblatt DS, Aspler AL, Shevell MI, Pletcher BA, Fenton WA, Seashore MR. Clinical heterogeneity and prognosis in combined methylmalonic aciduria and homocystinuria (cblC). *J Inherit Metab Dis*. 1997;20:528-538.
8. Carrillo-Carrasco N, Sloan J, Valle D, Hamosh A, Venditti CP. Hydroxocobalamin dose escalation improves metabolic control in cblC. *J Inherit Metab Dis*. 2009;32:728-731.
9. Matos IV, Castejon E, Meavilla S, et al. Clinical and biochemical outcome after hydroxocobalamin dose escalation in a series of patients with cobalamin C deficiency. *Mol Genet Metab*. 2013; 109:360-365.
10. Dobson CM, Wai T, Leclerc D, et al. Identification of the gene responsible for the cblB complementation group of vitamin B12-dependent methylmalonic aciduria. *Hum Mol Genet*. 2002; 11:3361-3369.

11. Haarmann A, Mayr M, Kolker S, et al. Renal involvement in a patient with cobalamin A type (cblA) methylmalonic aciduria: a 42-year follow-up. *Mol Genet Metab.* 2013;110:472-476.
12. Horster F, Baumgartner MR, Viardot C, et al. Long-term outcome in methylmalonic acidurias is influenced by the underlying defect (mut0, mut-, cblA, cblB). *Pediatr Res.* 2007;62:225-230.
13. Ku CA, Ng JK, Karr DJ, et al. Spectrum of ocular manifestations in cobalamin C and cobalamin A types of methylmalonic acidemia. *Ophthalmic Genet.* 2016;37:404-414.
14. Baumgartner MR, Horster F, Dionisi-Vici C, et al. Proposed guidelines for the diagnosis and management of methylmalonic and propionic acidemia. *Orphanet J Rare Dis.* 2014;9:130.
15. Yu HC, Sloan JL, Scharer G, et al. An X-linked cobalamin disorder caused by mutations in transcriptional coregulator HCFC1. *Am J Hum Genet.* 2013;93:506-514.
16. Petermann F, Macha T. *Entwicklungstest für Kinder von 6 Monaten bis 6 Jahren Revision (ET 6-6-R)*. Frankfurt am Main: P. Assessment; 2013.
17. Andersson HC, Marble M, Shapira E. Long-term outcome in treated combined methylmalonic acidemia and homocystinuria. *Genet Med.* 1999;1:146-150.
18. Enns GM, Barkovich AJ, Rosenblatt DS, et al. Progressive neurological deterioration and MRI changes in cblC methylmalonic acidemia treated with hydroxocobalamin. *J Inher Metab Dis.* 1999;22:599-607.
19. Sharma AP, Greenberg CR, Prasad AN, Prasad C. Hemolytic uremic syndrome (HUS) secondary to cobalamin C (cblC) disorder. *Pediatr Nephrol.* 2007;22:2097-2103.
20. Weisfeld-Adams JD, Bender HA, Miley-Akerstedt A, et al. Neurologic and neurodevelopmental phenotypes in young children with early-treated combined methylmalonic acidemia and homocystinuria, cobalamin C type. *Mol Genet Metab.* 2013;110:241-247.
21. Bellerose J, Neugnot-Cerioli M, Bedard K, et al. A highly diverse portrait: heterogeneity of neuropsychological profiles in cblC defect. *JIMD Rep.* 2016;29:19-32.
22. Beck BB, van Spronsen F, Diepstra A, Berger RM, Komhoff M. Renal thrombotic microangiopathy in patients with cblC defect: review of an under-recognized entity. *Pediatr Nephrol.* 2017;32:733-741.
23. Smith SE, Kinney HC, Swoboda KJ, Levy HL. Subacute combined degeneration of the spinal cord in cblC disorder despite treatment with B12. *Mol Genet Metab.* 2006;88:138-145.
24. Scalais E, Osterheld E, Weitzel C, et al. X-linked cobalamin disorder (HCFC1) mimicking nonketotic hyperglycinemia with increased both cerebrospinal fluid glycine and methylmalonic acid. *Pediatr Neurol.* 2017;71:65-69.
25. Gizicki R, Robert MC, Gomez-Lopez L, et al. Long-term visual outcome of methylmalonic aciduria and homocystinuria, cobalamin C type. *Ophthalmology.* 2014;121:381-386.
26. Weisfeld-Adams JD, McCourt EA, Diaz GA, Oliver SC. Ocular disease in the cobalamin C defect: a review of the literature and a suggested framework for clinical surveillance. *Mol Genet Metab.* 2015;114:537-546.
27. Menni F, Testa S, Guez S, Chiarelli G, Alberti L, Esposito S. Neonatal atypical hemolytic uremic syndrome due to methylmalonic aciduria and homocystinuria. *Pediatr Nephrol.* 2012;27:1401-1405.
28. Van Hove JL, Van Damme-Lombaerts R, Grunewald S, et al. Cobalamin disorder Cbl-C presenting with late-onset thrombotic microangiopathy. *Am J Med Genet.* 2002;111:195-201.
29. Lerner-Ellis JP, Dobson CM, Wai T, et al. Mutations in the MMAA gene in patients with the cblA disorder of vitamin B12 metabolism. *Hum Mutat.* 2004;24:509-516.

How to cite this article: Scalais E, Osterheld E, Geron C, et al. Parenteral hydroxocobalamin dose intensification in five patients with different types of early onset intracellular cobalamin defects: Clinical and biochemical responses. *JIMD Reports.* 2019;49:70–79. <https://doi.org/10.1002/jmd2.12055>