



Persistent idiopathic facial pain treated with botulinum toxin and pulsed radiofrequency of infraorbital nerve – a case report

Prasanna Vadhanan^{1,2}

¹Department of Anaesthesiology, Vinayaka Missions Medical College, Vinayaka Missions Research Foundation, Karaikal, Puducherry, India

²Vairam Multispeciality Hospitals, Mayiladuthurai, India

Persistent idiopathic facial pain is a rare and difficult condition to treat. Several pharmacological, non-pharmacological, and invasive treatment options have been used, with varying results. We report the case of a patient with intractable persistent idiopathic facial pain who responded favorably to a combination of botulinum toxin injections and pulsed radiofrequency treatment of the infraorbital nerve.

Keywords: Botulinum Toxin; Orofacial Pain; Pulsed Radiofrequency Treatment.



This is an Open Access article distributed under the terms of the Creative Commons Attribution Non-Commercial License (<http://creativecommons.org/licenses/by-nc/4.0/>) which permits unrestricted non-commercial use, distribution, and reproduction in any medium, provided the original work is properly cited.



INTRODUCTION

Persistent idiopathic facial pain (PIFP), previously known as atypical facial pain is an underdiagnosed cause of orofacial pain often mistook for trigeminal neuralgia [1]. According to the International Classification of Headache Disorders (3rd edition) classification (ICHD 3), it is defined as a recurring pain lasting more than 2 h daily for more than 3 months without any clinical neurological deficit and having poorly localized, dull aching, or nagging quality [2]. Neuropathic elements are believed to be involved, at least in some patients [3]. Treatment is often unsatisfactory, and typically invasive interventions are not considered effective. This report describes the case of a patient with PIFP who experienced significant pain relief after botulinum toxin injections over painful areas along with pulsed radiofrequency

(PRF) treatment of the infraorbital nerve.

CASE REPORT

A 52-year-old woman with persistent facial pain for the past 1 year over her left maxillary region localized over the lateral incisor and extending across the face (Fig 1A) presented to our pain clinic. The pain was described as continuous, gnawing, and sometimes associated with the sensation of pins and needles. She rated the pain intensity as 8/10 on a visual analog scale (VAS). The pain persisted most of the day and interfered with her sleep. There were no specific aggravating or relieving factors. She had undergone two dental extractions for pain, and glycerol neurolysis of the left Gasserian ganglion was performed by a neurologist who diagnosed her condition as trigeminal neuralgia. However, the

Received: November 11, 2021 • Revised: December 31, 2021 • Accepted: January 4, 2022

Corresponding Author: Prasanna Vadhanan, MD, Dip. Pain Management. Department of Anaesthesiology, Vinayaka Missions Medical College, Vinayaka Missions Research foundation, Karaikal, Puducherry, Consultant Anesthesiologist, Vairam Multispeciality Hospitals, Mayiladuthurai, India
Tel: +919486489690 E-mail: vadhanan.prasanna@gmail.com, prasanna12778@vmmckkl.edu.in

Copyright© 2022 Journal of Dental Anesthesia and Pain Medicine

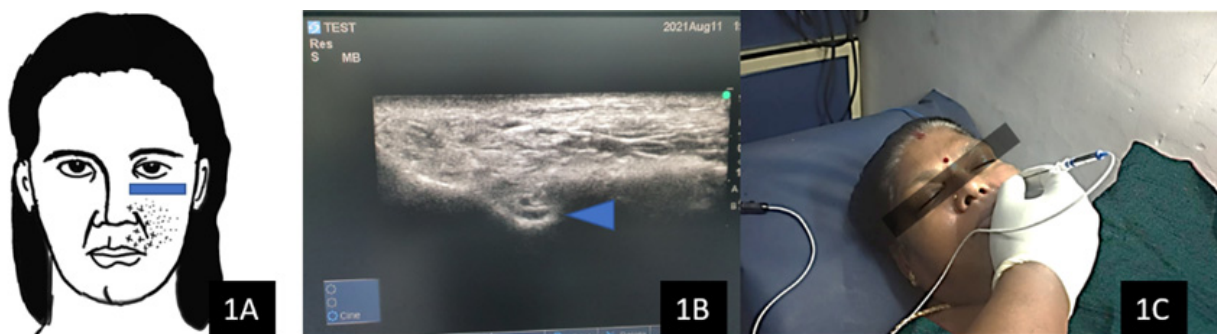


Fig. 1. (A) Area of initial pain (crosses) and radiation (dots); the box represents ultrasound probe position. (B) Ultrasound image showing the infraorbital foramen and artery (arrowhead). (C) Pulsed radiofrequency needle in place.

patient's pain did not subside and affected her daily activities and sleep. She underwent sphenopalatine ganglion radiofrequency (RF) ablation, but it did not produce appreciable pain relief. She reported transient pain relief after an infraorbital nerve (ION) block performed by a dental surgeon. She was prescribed various medications, including amitriptyline, gabapentin, duloxetine, carbamazepine, phenytoin, benzodiazepines, and tramadol, often in maximum tolerated doses, but they were ineffective. She underwent a psychiatric consultation and was prescribed quetiapine. Magnetic resonance imaging of the brain and computed tomography scans of the paranasal sinuses, facial bones, and teeth were unremarkable. She had no other comorbidities and had a cheerful demeanor despite her debilitating pain. Her height and weight were 160 cm and 75 kg, respectively. On examination, the patient reported subtle hyperalgesia and allodynia over her upper left lateral lip, corresponding to the left canine, compared to the right side (Fig. 1A). Occasional muscle twitching of the area over the levator labii superioris alaeque nasi was noted, which was noticed by the patient and her husband as well. A diagnosis of PIFP was made based on the patient's clinical symptoms and lack of response to other treatment modalities.

Local infiltration of 1% lignocaine was performed over the root of the lateral incisor intraorally and over the painful areas extraorally, which produced appreciable pain relief for over 2 h. She was administered botulinum toxin injections and PRF to the left ION.

The procedures were performed on an outpatient basis.

Botulinum toxin A (BTX A, Lanzhou Biotechnology Development Co. Ltd., Gansu, China) injection was administered at 10 sites: three intraorally over the root of the left upper gingiva and seven subcutaneously over the painful areas (5 units on each site, total of 50 units). Subsequently, ultrasound-guided PRF treatment of the left ION was performed. A linear high-frequency probe (Sonosite Inc., Washington, USA) was placed transversally below the inferior orbital margin, and the infraorbital foramen was identified (Fig. 1B). A 10-cm long RF needle (Halyard, Avanos Medical Inc., Georgia, USA) with a 5-mm active tip was introduced in an out-of-plane approach. Sensory stimulation at 0.3 V (50 Hz) elicited mild paresthesia over the painful regions. PRF treatment was performed (45V, 42°C, 120 s) using an RF generator (Diros Owl, Ontario, Canada) (Fig. 1C) followed by an injection of 1 ml of 0.5% bupivacaine and 20 mg triamcinolone. She was advised to continue oral gabapentin 300 mg twice daily and amitriptyline 25 mg once daily. Paracetamol 500 mg two times daily orally for 5 days was recommended for postprocedural pain.

The patient was followed up at 2, 4, and 8 weeks after the procedure. At 2 weeks, she had modest pain relief (VAS 7/10); the twitching seen over the lateral nasal area had disappeared completely. The sensation of touch was preserved. At 4 weeks, she had significant pain relief (VAS 5/10) and was sleeping comfortably. At 8 weeks, she reported additional pain relief (VAS 3/10) and was able to resume her normal activities. She described her pain as "mild and manageable" and that she felt "better

than ever”.

DISCUSSION

Persistent idiopathic facial pain is a rare condition with an incidence of 4.4 per 100,000 patient-years [4] and a female preponderance. It is a significantly painful condition with a mean pain intensity of 7 out of 10 on VAS, and most patients report constant pain [5]. Often a diagnosis of exclusion, the differential diagnoses include chronic myofascial pain, pre- or atypical trigeminal neuralgia, orofacial/facial migraine, and atypical trigeminal autonomic cephalgia [6]. While the absence of sensory abnormalities is considered a diagnostic criterion for PIFP according to ICHD 3 classification, quantitative sensory testing often reveals sensory abnormalities [5]. Furthermore, the recent International Classification of Orofacial Pain (ICOP) included mild somatosensory abnormalities in PIFP [7]. Various pharmacological (tricyclic antidepressants, duloxetine, and venlafaxine) and non-pharmacological (biofeedback, cognitive-behavioral therapy, relaxation techniques, and psychotherapy) treatments have been suggested. Minimally invasive and surgical interventions have been attempted, including gasserian/sphenopalatine ganglion alcohol/RF neurolysis, microvascular decompression, posterior fossa exploration, nucleus caudalis dorsal entry zone lesioning, high-frequency repetitive transcranial magnetic stimulation of the right secondary somatosensory cortex, and gamma knife surgery [8]. The evidence level was low for most of the treatment options.

Our patient had subtle allodynia in the painful areas. The presence of allodynia has been shown to predict a positive response to botulinum toxin injections in patients with migraine [9]. PRF treatment of the ION was offered based on the pain relief experienced by the patient following the ION block. The mechanism of action of botulinum toxin in neuropathic pain is multifactorial, inhibiting the release of nociceptive agents, such as

substance P and calcitonin gene-related peptide (CGRP) from nerve endings and dorsal root ganglion, inhibition of sodium channels, anti-inflammatory actions, and central and peripheral sensitization [10]. Botulinum toxin has been used successfully in various orofacial pain conditions, such as trigeminal neuralgia [11], non-odontogenic facial pain, including atypical facial pain [12], and atypical odontalgia [13]. The exact mechanism of PRF treatment is unknown, but it is believed to act by neuromodulation and changes in the neuronal structure without causing significant structural damage [14]. PRF has been used successfully in various orofacial pain conditions, such as trigeminal neuralgia and glossopharyngeal neuralgia. Based on a recent systematic review, a combination of conventional RF ablation and PRF seems to offer maximum benefit in facial pain [15].

A combination of RF energy neuromodulation and the chemical effects of botulinum toxin might work synergistically to achieve maximum pain relief. While PRF might produce neuromodulation, botulinum toxin acts by preventing the release of various neurotransmitters, demonstrating both peripheral and central actions. The procedure is cost-effective and can be performed as an office procedure.

This report has some limitations. First, the follow-up period was short (8 weeks). Second, triamcinolone was injected after PRF treatment, which might have confounded the efficacy of PRF. However, since the effect of perineural steroid wanes after a few weeks, it may have had no analgesic benefit. Moreover, the patient experienced sustained pain relief at 8 weeks.

In conclusion, this report described the successful combined use of botulinum toxin and PRF treatment for intractable PIFP. Further research on this method will yield interesting results in the management of facial pain. This modality might be a cost-effective outpatient intervention for managing persistent idiopathic facial pain.

AUTHOR ORCID*s*

Prasanna Vadhanan: <https://orcid.org/0000-0001-6060-3880>

AUTHOR CONTRIBUTIONS

Prasanna Vadhanan: Data curation, Investigation, Writing - original draft, Writing - review & editing

NOTE: The patient's informed written consent was obtained for publishing this manuscript. The Institutional Ethics Committee of Vinayaka Missions Medical College, Karaikal, India approved this study. (IRB number: IEC/2021/11/Anaes/CR01).

FUNDING: The author declares no funding for this study.

CONFLICT OF INTEREST: The author has no conflicts of interest.

REFERENCES

1. Gerwin R. Chronic facial pain: trigeminal neuralgia, persistent idiopathic facial pain, and myofascial pain syndrome-an evidence-based narrative review and etiological hypothesis. *Int J Environ Res Public Health* 2020; 17: 7012.
2. Gobel H. 13.12 Persistent idiopathic facial pain (PIFP). ICHD-3. Available from <https://ichd-3.org/13-painful-cranial-neuropathies-and-other-facial-pains/13-12-central-neuropathic-pain/>.
3. Sukenaga N, Matsuki Y, Maeda L, Nagai T, Hashimoto K, Takao Y et al. Neuropathic characteristics in patients with persistent idiopathic facial pain. *J Pain Res* 2019; 12: 2801-5.
4. Koopman JS, Dieleman JP, Huygen FJ. Incidence of facial pain in the general population. *Pain* 2009; 147: 122-7.
5. Maarbjerg S, Wolfram F, Heinskou TB, RoCHAT P, Gozalov A, Brennum J et al. Persistent idiopathic facial pain - a prospective systematic study of clinical characteristics and neuroanatomical findings at 3.0 Tesla MRI. *Cephalalgia* 2017; 37: 1231-40.
6. Benoliel R, Gaul C. Persistent idiopathic facial pain. *Cephalalgia* 2017; 37: 680-91.
7. International classification of orofacial pain, 1st edition (ICOP). *Cephalalgia* 2020; 40: 129-221.
8. Rahimpour S, Lad SP. Surgical options for atypical facial pain syndromes. *Neurosurg Clin N Am* 2016; 27: 365-70.
9. Young WB, Ivan Lopez J, Rothrock JF, Orejudos A, Manack Adams A, Lipton RB, et al. Effects of onabotulinumtoxinA treatment in patients with and without allodynia: results of the COMPEL study. *J Headache Pain* 2019; 20: 10.
10. Park J, Park HJ. Botulinum toxin for the treatment of neuropathic pain. *Toxins* 2017; 9: 260.
11. Rubis A, Juodzbaly G. The use of botulinum toxin A in the management of trigeminal neuralgia: a systematic literature review. *J Oral Maxillofac Res* 2020 Jun 30; 11: e2.
12. Kim SY, Kim YK, Yun PY, Bae JH. Treatment of non-odontogenic orofacial pain using botulinum toxin-A: a retrospective case series study. *Maxillofac Plast Reconstr Surg* 2018; 40: 21.
13. García-Sáez R, Gutiérrez-Viedma Á, González-García N, Gómez-Mayordomo V, Porta-Etessam J, Cuadrado ML. OnabotulinumtoxinA injections for atypical odontalgia: an open-label study on nine patients. *J Pain Res* 2018; 11: 1583-8.
14. Huang X, Ma Y, Wang W, Guo Y, Xu B, Ma K. Efficacy and safety of pulsed radiofrequency modulation of thoracic dorsal root ganglion or intercostal nerve on postherpetic neuralgia in aged patients: a retrospective study. *BMC Neurol* 2021; 21: 233.
15. Orhurhu V, Khan F, Quispe RC, Huang L, Urits I, Jones M, et al. Use of radiofrequency ablation for the management of facial pain: a systematic review. *Pain Physician* 2020; 23: 559-80.