



Received: 2015.05.03
Accepted: 2015.07.15
Published: 2016.02.22

Authors' Contribution:

- A** Study Design
- B** Data Collection
- C** Statistical Analysis
- D** Data Interpretation
- E** Manuscript Preparation
- F** Literature Search
- G** Funds Collection

Deep Vein Thrombosis of the Left Lower Limb in a 12 Year-Old Female Child with Ulcerative Colitis – Case Report

Elżbieta Krzesiek^{1ABCDE}, Urszula Zaleska-Dorobisz^{2BCD}, Barbara Iwańczak^{2ADE}, Andrzej T. Dorobisz^{3BD}

¹ Department of Pediatrics, Gastroenterology and Nutrition, Medical University, Wrocław, Poland

² Department of Radiology, Medical University, Wrocław, Poland

³ Department of Vascular, General and Transplant Surgery, Medical University, Wrocław, Poland

Author's address: Elżbieta Krzesiek, Department of Pediatrics, Gastroenterology and Nutrition, Medical University, Wrocław, Poland, e-mail: ellak@op.pl

Background:

Inflammatory bowel disease includes ulcerative colitis and Crohn's disease.

Case Report:

This case report presents a patient with ulcerative colitis, with thrombotic complication of the left common iliac vein that occurred at the age of 11, two years after diagnosis. After a year of anticoagulation and compression therapy, although exacerbations of underlying disease occurred in the first 6 months of treatment, there was no recurrence of deep venous thrombosis, partial recanalization within affected venous system has been achieved and the patient is in remission of ulcerative colitis for the last six months.

Conclusions:

In children, thromboembolic complications occur about 7 times less often than in adults, but increases in the case of hospitalized children. In children with IBD this complication can occur independently of disease activity even in patients with any other risk factors.

MeSH Keywords:

Colitis, Ulcerative • Only Child • Venous Thrombosis

PDF file:

<http://www.polradiol.com/abstract/index/idArt/894529>

Summary

Background

Inflammatory bowel disease (IBD), which includes ulcerative colitis and Crohn's disease, is a chronic disease of the gastrointestinal tract that can also be accompanied by extra-intestinal manifestations. One of them is thrombosis. In patients with IBD, thrombosis occurs three times more frequently and affects younger people than in the general population [1–3]. Thromboembolic complications are especially common in patients with exacerbation of the underlying disease, frequent relapses and extended inflammatory lesions in a significant part of the intestine (pancolitis) in the case of UC, and colonic involvement in the case of CD. A genetic susceptibility (the presence of factor V Leiden, Prothrombin Gene Mutation G20210A, congenital deficiencies of anticoagulant proteins) is an important risk factor of thrombosis. In the case of IBD patients a number of external factors such as: long immobilization, infections, dehydration, malnutrition, anemia, recent surgeries, central venous catheters,

hyperhomocysteinemia, hormonal contraception, smoking, obesity, malignancy, can promote thromboembolism. In 1/3 of IBD patients thrombosis can appear in the remission phase, reflecting the prothrombotic tendency in these diseases, regardless of their inflammatory activity [1,4–6].

In children, thromboembolic complications occur about 7 times less often than in adults (0.7–1.4/100000), but increase to 5.3/100000 in the case of hospitalized children. In children with IBD, thromboembolic complications are also rare (1.3–3.3%), while in the adult population with IBD it is assessed at 1–10%, and even at 41% in postmortem studies [3,6].

Case Report

A 12-year-old female child had normal psychomotor development without any medical history. She was admitted to

our clinic at the age of 9 due to the presence of blood in the stools and was diagnosed with UC according to the Porto Criteria. In colonoscopy, inflammation involved the entire colon (pancolitis). Afterwards, she was hospitalized several times due to exacerbations of the underlying disease. The course of the disease was severe, required periodic administration of corticosteroids and immunosuppressive treatment (azathioprine). In addition, intolerance to mesalazine was observed.

At the age of 11, there appeared pain in the left lower limb and left groin, and swelling of the lower left limb with impaired mobility. The consulting vascular surgeon diagnosed deep vein thrombosis of the left lower limb and prescribed subcutaneous low molecular weight heparin (LMWH) at a dose of 0.3 mL sc twice daily and advised the use of compression stockings and referred the patient to our Clinic. At that time she was treated with 10 mg/d of prednisone and 2 mg/kg/d of azathioprine. On arrival, her general physical condition was moderate, she reported pain in the left groin on palpation, physical examination revealed: swelling of the lower left limb, poorly palpable femoral, popliteal, posterior tibial arterial pulse, tachycardia, dry mucosa and tenderness in the left iliac fossa. Laboratory tests revealed elevated markers of inflammation (ESR 85/h, CRP 71.7 mg%, seromucoid 2.46 g/L, platelets count 434 K/UL), severe anemia (Hb 7.6 g%) and significantly elevated D-dimer concentration – 2618 ng/mL (N <500). Disease activity assessed using PUCAI scale was 35 points.

In search of the cause of abnormal blood clotting the following tests were performed: protein C-activity: 131% (N: 70-140), protein S-free fraction: 108.4% (N: 60-115), lupus anticoagulant: 0.88 (negative), von Willebrand factor (activity): 175.66% [N: 45-150] and (antigen): 147.10% (N: 50-150), factor V: 97.98% (N: 62-139), factor VIII: 539, 68% (N: 50-150), factor XI: 239.37% (N: 65-150), anti β 2-glikoprotein antibodies: IgG 3.24 RU/mL (negative) and IgM 7.29 RU/mL (negative), antithrombin III: 109.9% (N: 85-115), fibrinogen 2.8 g/L (N: 2-4.5). anticardiolipin antibodies: IgG – 29.82 GPL (>20 positive) IgM – 8.15 MPL (<10 negative). Genetic tests performed using PCR technique in search of the mutations in three following genes gave the results: factor V Leiden genotype G1691A: G/G (normal result); factor II G20210A genotype G/G (normal result); MTHFR C677T genotype: C/C (normal result), which allowed to exclude the genetic risk of thrombosis.

Based on Doppler examination, thrombosis of the left common iliac vein and femoral vein was detected. Within the vascular lumen of the left femoral vein, a heterogeneous hypoechogenic material, 1.4 cm in width was shown (Figure 1). MR angiography confirmed the presence of the left external iliac vein and left femoral vein thrombosis with features of fresh thrombus formation, with high signal from methemoglobin. In addition, vessels of the collateral circulation formed by ascending lumbar veins and left ovarian vein union were found. No pathological masses compressing iliac veins and predisposing to thrombosis were found in the pelvic area (Figures 2-4).

At the beginning the patient had fever, complained of pain in the left lower limb and abdominal pain. She had 4 stools

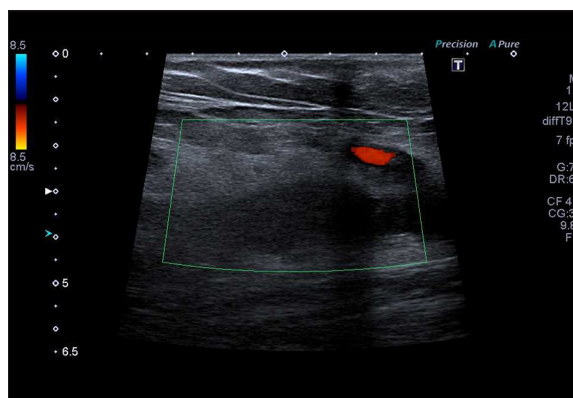

Figure 1. Doppler examination: thrombosis of the left common iliac vein.

per day with blood. After 5 days of hospitalization fever subsided and the swelling and pain of the left lower limb decreased. The stools (one to two per day) were of normal consistency, with a small amount of blood. The patient was allowed to move. Due to reported headaches she was consulted by a neurologist, who found no pathology in either neurological examination or MRI of the head. Ultrasound study of the heart did not reveal any pathology. In control laboratory tests, markers of inflammation were absent, D-dimer level decreased and blood morphology improved. LMWH dose was reduced to 0.3 mL sc once a day. Value of the PUCAI scale was 10 points.

After a month in the control Doppler examination the features of chronic thrombosis (heterogeneous, hyperechogenic clot filling the vessel lumen) of the iliac vein, left femoral vein, left saphenous vein with symptoms of partial recanalization were revealed (Power Doppler registered a turbulent venous flow in the perimural part of the femoral and saphenous veins) (Figure 5).

Successive exacerbation of UC occurred after 6 months after the thrombosis incident during reduction of the prednisone dosage. At rest she did not complain of lower extremity pain, but after longer walks she reported numbness. Power Doppler sonography revealed the left common iliac vein with a diameter of 1 cm filled with a heterogeneous thrombus of mixed echogenicity, with reduced flow was assessed (Figure 6).

Afterwards, the disease, controlled one year after the thrombotic incident, was low. She reported a few-week history of redness of the lower limbs when standing for a longer time, which relieved after a few steps. The Doppler examination showed further recanalization and improvement in efficiency of the deep venous system of the left lower limb.

Taking into account clinical remission, low inflammatory markers, negative lupus anticoagulant and exclusion of the diagnosis of hereditary thrombophilia, LMWH treatment was ceased and only a compression therapy and prophylactic anticoagulation in any prothrombotic situation (pregnancy, immobilization, surgery) was sustained.

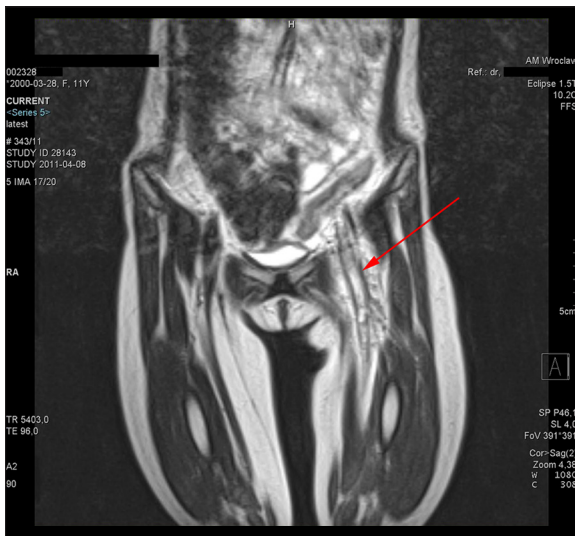


Figure 2. MR angiography: thrombosis of the left external iliac vein and left femoral vein.

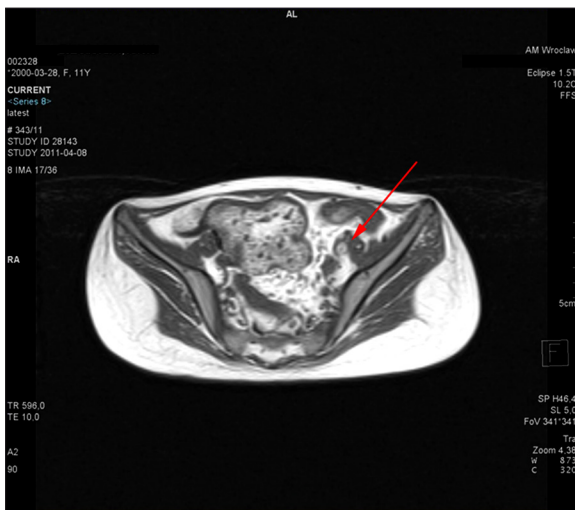


Figure 3. MR angiography: thrombosis of the left external iliac vein.

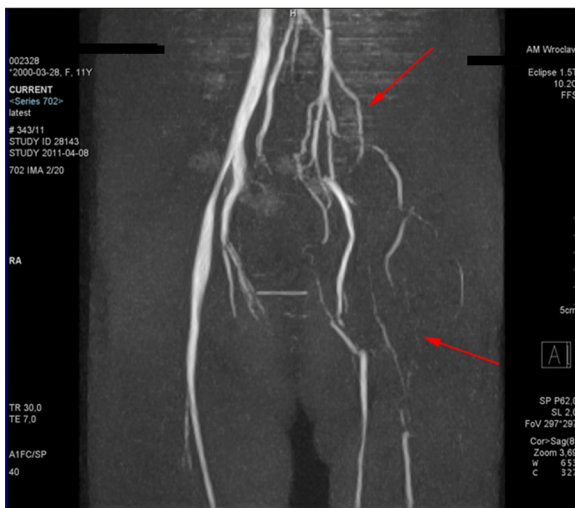

Figure 4. MR angiography: vessels of the collateral circulation formed by ascending lumbar veins and left ovarian vein union.

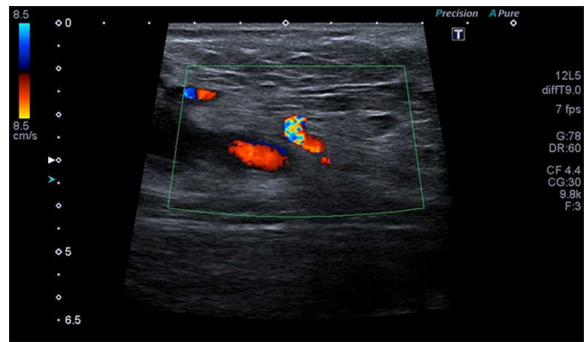


Figure 5. Control Doppler examination after 1 month: the features of chronic thrombosis (heterogenous, hyperechogenic clot filling the vessel lumen) with symptoms of partial recanalization.

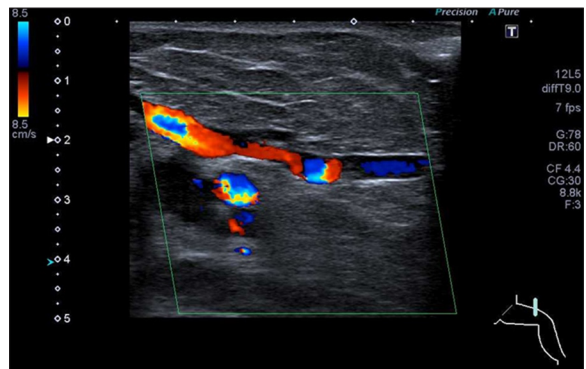


Figure 6. Control Power Doppler sonography after 6 months: the left common iliac vein with diameter of 1 cm filled with heterogeneous thrombus of mixed echogenicity, with reduced flow-symptom of recanalization

Discussion

Thrombosis as a complication of inflammatory bowel disease can affect both the arterial and the venous system. However, venous thrombosis is encountered more frequently (about 75%). In adults, the most common locations are the deep veins of the lower limbs and pulmonary embolism. In children, the location may be atypical, as illustrated by case studies of pediatric patients: extremely rare hepatic vein thrombosis (Budd-Chiari syndrome), isolated iliac vein thrombosis, or more common splenic vein thrombosis or cerebral vessel thrombosis [1,5–10].

Venous thrombosis in the course of inflammatory bowel disease affects patients of all ages independently of the activity of the disease, even in patients with any other risk factors, apart from IBD. The girl presented in this report was 11 years old at the time of the thrombotic incident and she was suffering from ulcerative colitis for 2 years and inflammatory lesions involved the entire colon. The disease activity at the onset of the complication was 35 points according to PUCAI, which corresponds to moderate exacerbation. Based on a genetic assay, no increased risk of congenital thrombosis was found. Beyond slight thrombocytosis, elevated concentrations of factor VIII, factor XI and high d-dimers, fibrinogen, protein C and S, antithrombin III were within normal limits. Aside from the underlying disease, other treatment factors could be prothrombotic such

as a severe course of the disease, pancolitis, therefore (as in most pediatric patients) inflammatory bowel disease itself.

Doppler ultrasonography is usually a sufficient method for diagnosing and monitoring the course of peripheral venous thrombosis. It is necessary to extend the diagnostics by MR angiography when the pathology involves the veins of the pelvis and abdomen. Ultrasonography of the abdomen and pelvis and Venous Doppler Ultrasound of the left lower limb allowed evaluation of thrombosis progression in control examinations. Subsequent ultrasound examinations showed gradual partial recanalization of venous thrombosis and development of collateral circulation.

In therapy, in addition to treatment of the underlying disease, concomitant infections, dehydration, malnutrition and vitamin deficiency, the leading role is played by antithrombotic therapy and prevention of thrombosis.

Unrecognized and untreated deep vein thrombosis may be complicated by death due to pulmonary thrombosis, postthrombotic syndrome and carries the risk of recurrent thrombosis. According to the updated in 2012 Polish Guidelines for Prevention and Treatment of Venous Thromboembolism Diseases, pharmacological treatment should be applied immediately after the diagnosis, unless there are contraindications to anticoagulation. The initial treatment is used parenterally: low molecular weight heparin (LMWH) or unfractionated heparin iv or sc (UFH) or fondaparinux. In patients with no contraindications to such a treatment, it is recommended to include vitamin K

antagonists (VKA) on the 1st or 2nd day of treatment and after ≥ 5 days (if INR > 2 for 2 consecutive days) while parenteral treatment is discontinued. With contraindications to VKA, parenteral treatment is continued. Typically, the treatment is long-term (up to 3 months), and in selected cases chronic (> 3 months), e.g. if central venous catheter has to be kept in the presence of thrombosis of the upper limb if lower limb thrombosis or pulmonary embolism is accompanied by active cancer or in idiopathic proximal lower limb thrombosis with low or moderate risk of bleeding [10–12].

Conclusions

In adult patients, in whom the risk of thrombosis and its recurrence is higher (from 13 to 30%), thromboprophylaxis is recommended during ulcerative colitis flare-ups, and periods of immobilization, but due to a significant risk of bleeding – initially it should be a compression therapy. Pharmacotherapy is to be considered on the basis of assessment of potential risks in comparison to potential benefits. In children, guidelines of thromboprophylaxis are not defined, but routine administration of heparin is not recommended [6,8,13]. In the case of our patient, anticoagulation was used for 12 months, without any recurrence of thrombosis, even though during the first 6 months after the thrombotic incident she developed recurrent and sometimes severe relapses of ulcerative colitis. The patient will require chronic compression therapy (about 2 years) and prevention of thrombosis in potentially prothrombotic situations.

References:

- Danese S, Papa A, Saibeni S et al: Inflammation and coagulation in IBD: the clot thickens. *Am J Gastroenterol*, 2007; 102: 174–86
- Murthy SK, Nguyen GC: Venous thromboembolism in inflammatory bowel disease: an epidemiological review. *Am J Gastroenterol*, 2011; 106: 713–18
- Zitomersky NL, Verhave M, Trenor CC: Thrombosis and inflammatory bowel disease: a call for improved awareness and prevention. *Inflamm Bowel Dis*, 2011; 17: 458–70
- Freeman HJ: Venous thromboembolism with inflammatory bowel disease. *World J Gastroenterol*, 2008; 14: 991–93
- Grainje MJ, West J, Card TR: Venous thromboembolism during active disease and remission in inflammatory bowel disease: a cohort study. *Lancet*, 2010; 375: 657–63
- Lazzerini M, Bramuzzo M, Mashio M et al: Thromboembolism in pediatric inflammatory bowel disease – systematic review. *Inflamm Bowel Dis*, 2011; 17: 2174–83
- Baysoy G, Daar G, Demir H et al: Internal iliac vein thrombosis in pediatric Crohn's disease. *J Crohn Colitis*, 2011; 5: 57–59
- Iwańczak B, Krzesiek E, Zaleska-Dorobisz U: Izolowana zakrzepica żyły śledzionowej u 11-letniej dziewczynki chorującej na przewlekłe zapalenie trzustki i wrzodziejące zapalenie jelita grubego. *Przeгляд Gastroenterologiczny*, 2009; 4(4): 211–14 [in Polish]
- Socha P, Ryżko J, Janczyk W et al: Hepatic vein thrombosis as a complication of ulcerative colitis in an 12-year-old patient. *Dig Dis Sci*, 2007; 52: 1293–98
- Radoń-Proskura J, Malinowska A, Irga-Jaworska N: Zakrzepica – narastający problem w praktyce pediatrycznej. *Standardy Medyczne/Pediatrics*, 2014; 11: 497–504 [in Polish]
- Polskie Wytyczne Profilaktyki i Leczenia Żyłnej Choroby Zakrzepowo-Zatorowej. Aktualizacja 2012. *Medycyna Praktyczna wydanie specjalne*, 2012 [in Polish]
- Halbrook A, Schulman S, Witt DM et al: Evidence-based management of anticoagulant therapy: Antithrombotic therapy and prevention of thrombosis, 9th ed: American College of Chest Physicians Evidence-Based Clinical Practice Guidelines. *Chest*, 2012; 141(2 Suppl.): e152S–84S
- Turner D, Travis S, Griffiths AM et al: Consensus for managing acute severe ulcerative colitis in children: a systematic review and joint statement from ECCO, ESPGHAN, and the Porto IBD Working Group of ESPGHAN. *Am J Gastroenterol*, 2011; 106: 574–88