

Effect of botulinum toxin in stellate ganglion for craniofacial hyperhidrosis: a case report

Journal of International Medical Research

49(3) 1–7

© The Author(s) 2021

Article reuse guidelines:

sagepub.com/journals-permissions

DOI: 10.1177/03000605211004213

journals.sagepub.com/home/imr



Jung Hyun Park¹, Rip Kim¹, Sang Hoon Na¹
and So Young Kwon² 

Abstract

Craniofacial hyperhidrosis causes sweating of the face and scalp due to excessive action of the sweat glands and manifests when patients become tense/nervous or develop an elevated body temperature. If noninvasive treatments are ineffective, invasive treatments such as a sympathetic block and resection are considered. A 32-year-old woman with no specific medical history was referred for uncontrolled craniofacial hyperhidrosis that included excessive sweating and hot flushing. Physical examination showed profuse sweating, and infrared thermography showed higher temperature in the neck and face than in the trunk. The patient underwent several stellate ganglion blocks, and her symptoms improved; however, the treatment effect was temporary. Botulinum toxin was then injected into the stellate ganglion. At the time of this writing, her sweating had been reduced for about 6 months and she was continuing to undergo follow-up. Craniofacial hyperhidrosis is a clinical condition in which patients experience excessive sweating of their faces and heads. It is less common than palmar and plantar hyperhidrosis. Botulinum toxin injection into the stellate ganglion is simple and safe and produces longer-lasting effects than other treatments, such as endoscopic sympathectomy and a single nerve block.

Keywords

Craniofacial hyperhidrosis, stellate ganglion block, botulinum toxin, pulsed radiofrequency, treatment efficacy, case report

Date received: 24 February 2021; accepted: 26 February 2021

¹Department of Anesthesiology and Pain Medicine, Incheon St. Mary's Hospital, The Catholic University of Korea, Incheon, Korea

²Department of Anesthesiology and Pain Medicine, St. Vincent's Hospital, The Catholic University of Korea, Suwon, Korea

Corresponding author:

So Young Kwon, Department of Anesthesiology and Pain Medicine, St. Vincent's Hospital, College of Medicine, The Catholic University of Korea, #93, Chi-Dong, Paldal-Ku, Suwon 442-723, Republic of Korea.

Email: so-young@catholic.ac.kr



Introduction

Hyperhidrosis is a disease that affects about 3% of the general population.¹ About one-fifth of affected patients experience facial sweating. Hyperhidrosis is more common in men than in women.² Primary hyperhidrosis occurs within families and is a heritable disorder with no other known risk factors.^{2,3} Secondary hyperhidrosis is caused by medical conditions or medications. Craniofacial hyperhidrosis (CFH) causes emotional and social problems in affected patients. The initial treatment of hyperhidrosis is symptomatic, such as antiperspirants or anticholinergics. Axillary and palmar hyperhidrosis can be treated surgically, such as by endoscopic thoracic sympathectomy; however, a thoracic sympathetic ganglion block is less effective for CFH. Although a stellate ganglion block (SGB) is used as a nonsurgical treatment of CFH, a disadvantage is that it must be performed several times because the effect is not long-lasting.

Botulinum toxin (BT) prevents the secretion of acetylcholine from cholinergic nerve endings and has been used to treat post-stroke dystonia. Based on this mechanism, BT is often used in sympathetic ganglion blocks because the presynaptic fibers of the sympathetic ganglia are cholinergic.³ Several studies have demonstrated continued effectiveness of BT injections as sympathetic blocks.^{4,5} Studies have also shown that direct administration of BT to the sweating site is effective in patients with hyperhidrosis;^{6,7} however, no studies have shown the effect of BT injection into the stellate sympathetic ganglion. We herein report a case in which BT was injected into the stellate ganglion of a patient with CFH, achieving a long-term antiperspirant effect.

Case presentation

A 32-year-old woman was referred from the rheumatology department because of a

5-year history of hyperhidrosis. The patient reported that she wore several handkerchiefs every day and sweated so profusely that her entire underwear was wet. The symptoms of hyperhidrosis were particularly severe on her face and scalp. The patient's symptoms had a sudden onset 5 years previously. She reported that she always carried a handheld fan, used more than five towels to wipe her sweat even in winter, and carried extra clothes for changing. Her makeup was easily removed by the sweat, and she had difficulties at work and in everyday life. She had no specific medical, family, or psychosocial history associated with hyperhidrosis. Several tests were conducted to determine the cause of the hyperhidrosis, but no disease with a potential to cause secondary hyperhidrosis was found, such as infection, endocrine disorders, drug use, or cancer. Physical examination showed no abnormalities with the exception of profuse sweating. Infrared thermography showed a higher temperature in the neck and face than in the trunk (Figure 1).

The patient was already using glycopyrrolate cream, but she had experienced no improvement in her symptoms, and our hospital did not have an oral glycopyrrolate drug; therefore, we chose conservative care. In addition, ultrasound-guided SGBs were performed several times a week using local anesthetics. Although some improvement was seen after the SGBs, the duration of symptom relief was not long. Therefore, we decided to perform pulsed radiofrequency.

The patient's symptoms of sweating improved for more than 7 months after the pulsed radiofrequency treatment. However, the sweating recurred thereafter with even greater severity, and we decided to administer BT. The patient was placed in the supine position on the operating table. A sterilized drape was used to ensure safety. The needle tip was placed in the stellate

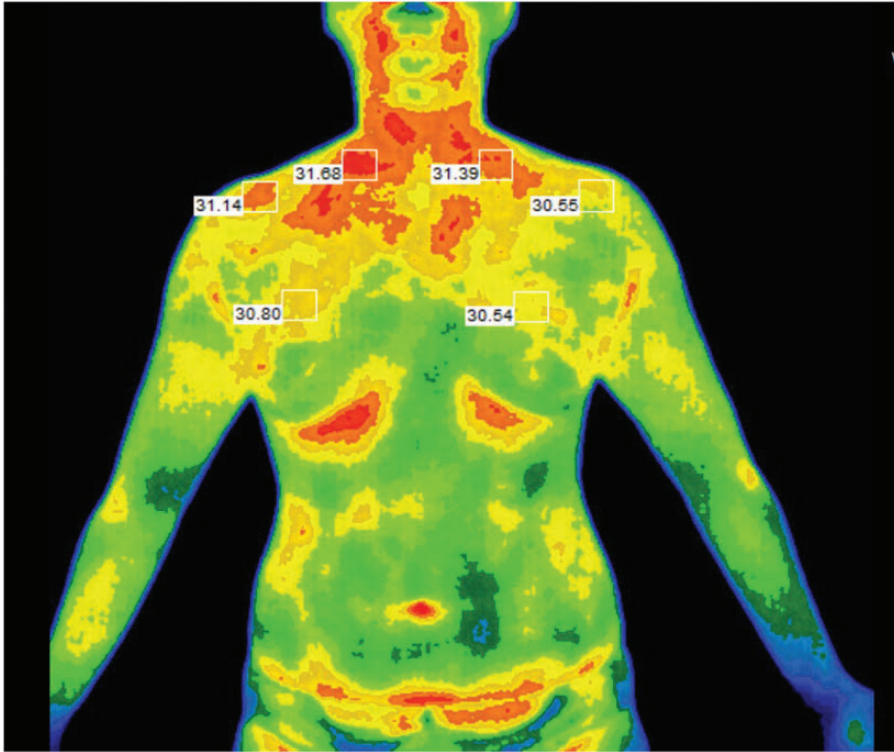


Figure 1. Infrared thermography at the time of the first visit. There was no difference in temperature on either side of the patient's body, including the face; however, the body temperature on the neck and face was higher than that on the trunk.

ganglion under ultrasound guidance (Figure 2), and the position was confirmed by a C-arm imaging device (Figure 3). The patient wore radiation safety glasses to protect her eyes. BOTOX® (Allergan plc, Dublin, Ireland) was used as the BT. We mixed 100 IU of BT with 2 mL of lidocaine and 8 mL of normal saline and injected 5 mL of the mixture into each side. At the time of this writing, her sweating had been reduced for about 6 months, and she has reported no adverse effects during that period.

Discussion

CFH is an uncommon clinical condition in which patients experience excessive

sweating of the face and head.⁸ CFH adversely affects the patient's quality of life more than hyperhidrosis at other sites. This detrimental effect is related more to mental stress than physical illness.⁹ The etiology of CFH is not clearly understood, but it involves a disorder in sudomotor regulation.¹⁰ According to the examination findings of skin biopsy specimens from patients with hyperhidrosis, eccrine glands can be either histologically normal or hyperactive.¹¹ Before diagnosing primary hyperhidrosis, it is necessary to examine the patient's history of menopause, diabetes, and endocrine disorders. Hyperhidrosis can also be caused by cholinesterase inhibitors, selective serotonin reuptake inhibitors, opioids, tumor necrosis factor-alpha

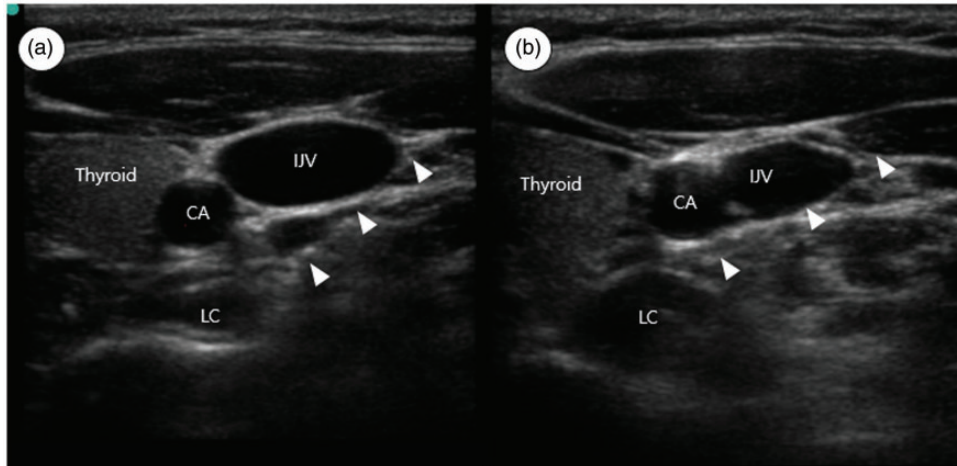


Figure 2. Ultrasound imaging at the time of botulinum toxin injection. The needle path is toward the fascia on the longus colli muscle. (a) Immediately below the left C6 anterior tubercle level. (b) Right C7 root level. CA, carotid artery; LC, longus colli muscle; IJV, internal jugular vein. The white arrowheads indicate the needle.

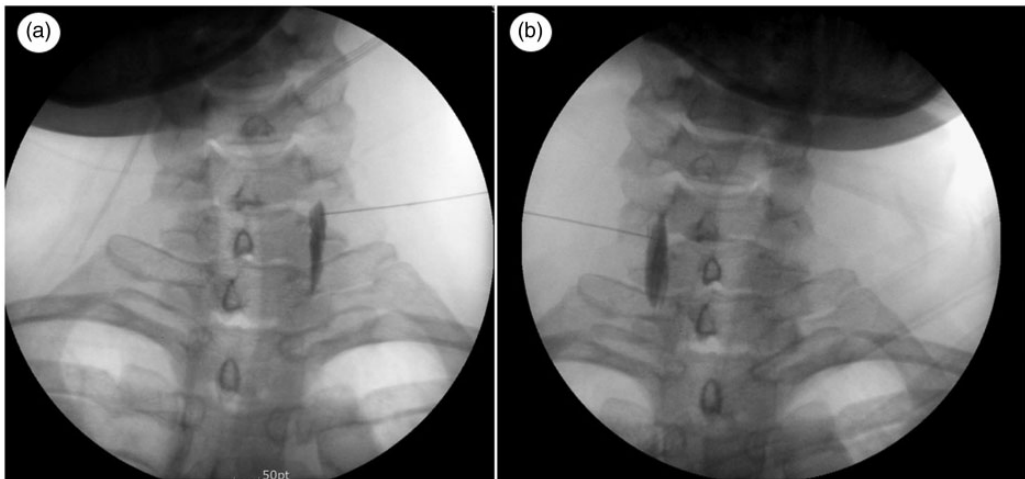


Figure 3. Radiographic imaging at the time of botulinum toxin injection. Anteroposterior view of the needle positions and the spreading of contrast material. The contrast material is spread along the longus colli muscle. (a) Left longus colli muscle. (b) Right longus colli muscle.

inhibitors, and tricyclic antidepressants; therefore, the use of these drugs must also be assessed.¹²

In general, when a patient is diagnosed with hyperhidrosis, topical agents or glycopyrrolate are tried first; surgical treatment

is considered when symptomatic treatment is ineffective.^{13,14} Antimuscarinic agents such as oxybutynin hydrochloride are also effective in the treatment of hyperhidrosis.¹⁵ However, oxybutynin hydrochloride has not been approved by the Ministry of

Food and Drug Safety for patients with hyperhidrosis. Intradermal BT and minimally invasive endoscopic sympathectomy were recently suggested as potential treatment methods.^{8,16-18} However, our patient strongly wished to avoid surgical treatment and we therefore only used nonsurgical treatment methods.

Several reports have indicated that SGB is effective for CFH.^{1,17} The stellate ganglion is anatomically associated with the lower sympathetic ganglion located at the bottom of the four sympathetic ganglia (superior, middle, intermediate, and inferior) in the cervical region. In 70% to 80% of the population, the first sympathetic ganglion of the thoracic vertebrae and the lower sympathetic ganglion of the cervical vertebrae form a complex called the stellate ganglion, which has a shape resembling a star. SGB is a type of sympathetic nerve block that obtains a therapeutic effect by blocking the stellate ganglion (one of the cervical sympathetic ganglia) with local anesthetics. Therefore, the SGB is a complex sympathetic ganglion block that can be termed a lower cervical sympathetic ganglion block or upper thoracic sympathetic ganglion block.²⁰

The mechanism of SGB for hyperhidrosis is thought to mainly involve a decrease in sweating function by vasodilation and sympathetic blockage of the stellate ganglion dominant site.²¹ Adverse events can be technical, infectious, or pharmacological.¹⁹ Among these, intra-arterial injection into the vertebral artery or carotid artery can lead to serious complications such as seizures.

The SGB is performed under ultrasound guidance or using a blind technique at the level of the sixth cervical vertebra. Many structures below this level must be avoided, such as the vertebral artery and lung; therefore, the needle tip may not reach the correct anatomical stellate ganglion. In addition, the disease severity and treatment

effectiveness are related to the continuity of treatment. Although the complications of pulsed radiofrequency are minor and the procedure has a long-term nerve blocking effect, it is only effective when the needles are close to the nerve or ganglion. This needle position can lead to complications such as vertebral artery damage or pneumothorax. However, an advantage of BT is that the drug acts directly on the stellate ganglion because it is injected as a mixture with other agents, similar to a local anesthetic injection.

BT itself can induce some adverse effects. Commonly reported adverse effects include swelling or pain at the injection site, itching, and muscle weakness. In addition, recent studies have revealed systemic adverse effects of BT. Many studies have reported that BT trafficking is not limited to neuromuscular junctions but is related to internalization of toxins by spinal cord motor neurons and fast axonal retrograde transportation.²² The resulting systemic adverse effects include anaphylaxis, dysphagia, and respiratory insufficiency. However, these systemic adverse effects are only observed in patients who receive high doses or have poor systemic conditions.

Many reports on the effects of BT in patients with hyperhidrosis have been published, but most of them describe use of the intradermal approach. Although some papers have reported the effect of injecting BT into peripheral nerves,²³ no reports have described injection of BT into the sympathetic ganglion for the treatment of hyperhidrosis.

Conclusion

CFH is an uncommon clinical condition in which patients experience excessive sweating on the face and head. BT injection into the stellate ganglion is simple, safe, and effective; therefore, this technique can be used as an alternative treatment for

uncontrolled CFH. In the present case, we attained a good outcome after injecting BT into the stellate ganglion in a patient with CFH who refused surgical treatment. Accumulation of additional cases and longer-term follow-up are needed to confirm these findings.

The main limitation of this study is that the patient's sweating condition could not be evaluated through objective tests or questionnaires to assess the improvement in sweat secretion after the procedure.²⁴ However, treatment of hyperhidrosis by injection of BT into the stellate ganglion has been presented as a new alternative to the treatment of CFH.

Ethics statement

The patient provided verbal informed consent for publication of this case. This case report was approved by the Institutional Ethics Committee of St. Vincent's Hospital, Republic of Korea (approval no. VC20ZISA0108). This study has been reported according to the CARE Guidelines established by the EQUATOR Network.

Declaration of conflicting interest

The authors declare that there is no conflict of interest.

Funding

This research received no specific grant from any funding agency in the public, commercial, or not-for-profit sectors.

ORCID iD

So Young Kwon  <https://orcid.org/0000-0003-0249-4190>

References

- Hornberger J, Grimes K, Naumann M, et al. Recognition, diagnosis, and treatment of primary focal hyperhidrosis. *J Am Acad Dermatol* 2004; 51: 274–286.
- Strutton DR, Kowalski JW, Glaser DA, et al. US prevalence of hyperhidrosis and impact on individuals with axillary hyperhidrosis: results from a national survey. *J Am Acad Dermatol* 2004; 51: 241–248.
- Lee Y, Lee CJ, Choi E, et al. Lumbar sympathetic block with botulinum toxin type a and type b for the complex regional pain syndrome. *Toxins (Basel)* 2018; 10: 164.
- Kim HJ, Seo K, Yum KW, et al. Effects of botulinum toxin type A on the superior cervical ganglia in rabbits. *Auton Neurosci* 2002; 102: 8–12.
- Lim SJ, Park HJ, Lee SH, et al. Ganglion impar block with botulinum toxin type a for chronic perineal pain - a case report. *Korean J Pain* 2010; 23: 65–69.
- Baumann L, Slezinger A, Halem M, et al. Double-blind, randomized, placebo-controlled pilot study of the safety and efficacy of Myobloc (botulinum toxin type B) for the treatment of palmar hyperhidrosis. *Dermatol Surg* 2005; 31: 263–270.
- Karlqvist M, Rosell K, Rystedt A, et al. Botulinum toxin B in the treatment of craniofacial hyperhidrosis. *J Eur Acad Dermatol Venereol* 2014; 28: 1313–1317.
- Lin TS and Chou MC. Needlescopic thoracic sympathetic block by clipping for craniofacial hyperhidrosis: an analysis of 28 cases. *Surg Endosc* 2002; 16: 1055–1058.
- Lin TS and Fang HY. Transthoracic endoscopic sympathectomy for craniofacial hyperhidrosis: analysis of 46 cases. *J Laparoendosc Adv Surg Tech A* 2000; 10: 243–247.
- Eisenach JH, Atkinson JL and Fealey RD. Hyperhidrosis: evolving therapies for a well-established phenomenon. *Mayo Clin Proc* 2005; 80: 657–666.
- Bovell DL, Clunes MT, Elder HY, et al. Ultrastructure of the hyperhidrotic eccrine sweat gland. *Br J Dermatol* 2001; 145: 298–301.
- Ikediyobi O, Chen YC and Shinkai K. Familial secondary hyperhidrosis associated with tumor necrosis factor-alpha inhibitor treatment. *JAAD Case Rep* 2015; 1: 418–420.
- Han JW, Kim JJ, Jeong SC, et al. Sympathotomy for severe compensatory hyperhidrosis in the trunk due to traumatic

- cervical spinal cord injury. *J Thorac Dis* 2020; 12: 1115–1117.
14. Moon DH, Kang DY, Kim DW, et al. Early results of new endoscopic thoracic sympathectomy for craniofacial hyperhidrosis. *J Thorac Dis* 2018; 10: 3627–3631.
 15. Wolosker N, Faustino CB, Silva MFA, et al. Current treatment options for craniofacial hyperhidrosis. *J Vasc Bras* 2020; 19: e20190152.
 16. Trindade De Almeida AR, Marques E, De Almeida J, et al. Pilot study comparing the diffusion of two formulations of botulinum toxin type A in patients with forehead hyperhidrosis. *Dermatol Surg* 2007; 33: S37–S43.
 17. Kinkelin I, Hund M, Naumann M, et al. Effective treatment of frontal hyperhidrosis with botulinum toxin A. *Br J Dermatol* 2000; 143: 824–827.
 18. Kim DY, Paik HC and Lee DY. Comparative analysis of T2 selective division of rami-communicantes (ramicotomy) with T2 sympathetic clipping in the treatment of craniofacial hyperhidrosis. *Eur J Cardiothorac Surg* 2004; 26: 396–400.
 19. Sankstone A and Cornbleet T. Facial hyperhidrosis interruption with stellate ganglion block. *JAMA* 1962; 179: 571.
 20. Elias M. Cervical sympathetic and stellate ganglion blocks. *Pain Physician* 2000; 3: 294–304.
 21. Liao CD, Tsao JY, Liou TH, et al. Efficacy of noninvasive stellate ganglion blockade performed using physical agent modalities in patients with sympathetic hyperactivity-associated disorders: a systematic review and meta-analysis. *PLoS One* 2016; 11: e0167476.
 22. Rstani L, Giribaldi F, Manich M, et al. Botulinum neurotoxin A and E undergo retrograde axonal transport in primary motor neuron. *PLoS Pathog* 2012; 8: e1003087.
 23. De Quintana-Sancho A and Conde Calvo MT. Treatment of palmar hyperhidrosis by peripheral nerve block at the wrist with botulinum toxin. *Actas Dermosifiliogr* 2017; 108: 947–949.
 24. McConaghy JR and Fosselman D. Hyperhidrosis: management options. *Am Fam Physician* 2018; 97: 729–734.