



Contents lists available at ScienceDirect

Trauma Case Reports

journal homepage: www.elsevier.com/locate/tcr



Case Report

Chronic leg swelling and palpitation as a late complication of post-traumatic arteriovenous fistula: A case report

Mehmet Kalender*, Ahmet Nihat Baysal, Mustafa Dagli, Hayat Gokmengil

Cardiovascular Surgery Department, Konya Education and Research Hospital, Konya, Turkey

ARTICLE INFO

Article history:

Accepted 20 March 2016

Available online 14 April 2016

Keywords:

Cardiovascular disease

Trauma

Arteriovenous fistula

Lower extremity

ABSTRACT

Introduction: Chronic post-traumatic arteriovenous fistula (AVF) is a late complication of vascular injury and can be presented with symptoms of congestive heart failure, venous hypertension and distal ischaemia. We present an unusual case of chronic leg swelling in adult caused by post-traumatic AVF.

Case presentation: A 52 year old white-male patient complained of palpitation, pain and swollen right leg. Arterial pulses distally from the groin were present. His medical history revealed him to have sustained gunshot injury of the left thigh 5 years before. Angiography showed a large AVF between superficial femoral artery and femoral vein. The patient underwent surgical repair of AVF with ligation of AVF between superficial femoral artery under spinal anaesthesia. Completion angiography confirmed AVF exclusion. Leg swelling healed within a month.

Conclusion: Post-traumatic fistula should be obliterated as soon as possible. Untreated fistula results in complications including renin-mediated hypertension and high-output heart failure, venous and/or arterial insufficiency.

© 2016 The Authors. Published by Elsevier Ltd. This is an open access article under the CC BY-NC-ND license (<http://creativecommons.org/licenses/by-nc-nd/4.0/>).

Introduction

Post-traumatic pseudoaneurysms and arterio-venous fistula (AVF) are infrequently seen in the civilian health care system. AVFs are associated with bone fractures, penetrating or high-injury blunt trauma, sport activities and less frequently, after orthopedic injuries [1].

* Corresponding author at: Haci Saban Mah, Yeni yol Cad, Konya Egitim ve Arastirma Hastanesi yeni bina, Kalp damar cerrahisi klinigi, Meram, Konya, Turkey. Tel.: +90 505 4424786.

E-mail addresses: ka97084@yahoo.com (M. Kalender), anbaysal@hotmail.com (A.N. Baysal), drmustafaaa@hotmail.com (M. Dagli), hayatgokmengil@yahoo.com (H. Gokmengil)

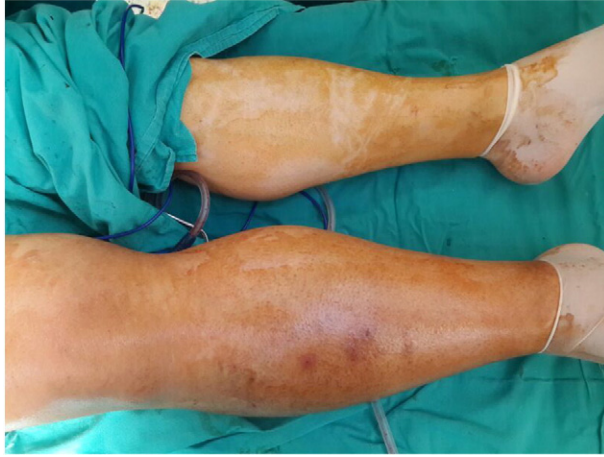


Fig. 1. Preoperative condition of lower extremity. Patient's lower extremity had diameter difference due to increased venous inflow and venous insufficiency.

Treatment options are endovascular intervention, artery ligation or reconstruction, external compression, coil embolisation, or echo-guided thrombin injection [2–4]. The endovascular repair enables a less traumatic anatomic reconstruction of such lesions. Open surgery is obligatory and safe method in cases with endovascular approach is impossible. The present case represents an unusual clinical presentation of a large chronic right groin AVF 5 years after a gunshot wound and demonstrates the successful use surgical repair this complex long-standing traumatic AVF.

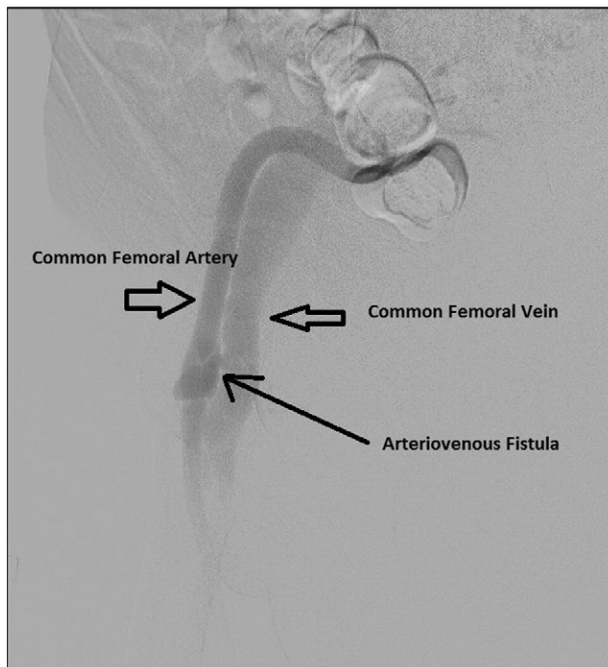


Fig. 2. Angiography revealing arteriovenous fistula. Traumatic arteriovenous fistula presented between common femoral artery and common femoral vein. Both vascular structures are aneurysmatic.

Case presentation

A 52 year old white-male patient complained of palpitation, pain and swollen right leg. He had suffered from a penetrating gunshot injury in the right thigh 5 years ago. Traumatic arteriovenous fistula detected 3 years ago and he had received no treatment because of his choice. In the last two months, his symptoms consisted of palpitation, leg pain and swelling had become exaggerated. His physical examination revealed increased diameter of the right lower extremity (Fig. 1), thrill on the right femoral region and distal pulses were present. Duplex scan examination revealed the presence of a psuedoaneurysm, concomitant AVF arterial flow in venous structures. Digital subtraction angiography revealed arteriovenous fistula between common femoral artery and common femoral vein (Fig. 2). Common femoral artery was aneurysmatic and arteries' flow distal to fistula had decreased velocity.

Surgery was performed with an incision on the medial side of the right thigh under spinal anesthesia. The wound was deepened and fistula was found between the femoral artery and vein (Fig. 3). With occlusion of the proximal and distal ends of the vessels, the artery and vein were separated and the fistula was closed with 5–0 Prolene sutures and haemoclips. The aneurysmal dilatation of the femoral vein was left alone. The postoperative course was very smooth and the patient's symptom became much improved (Fig. 4).

Discussion

With a low-velocity trauma from a knife or small-caliber missile is a major cause of acquired AVF. Robbs et al. reported gunshot wounds accounted for 26% of 202 traumatic AVFs whereas stab wounds accounted for 63% [5].

The most common anatomic site of traumatic AVFs is the arteries of the neck (the most common individual vessels involved in AVF are the carotid artery and jugular vein) and thoracic outlet (54%). AVFs in the upper (22%) and lower limbs (20%) are less common AVFs of the vessels of the abdomen and thorax constitute

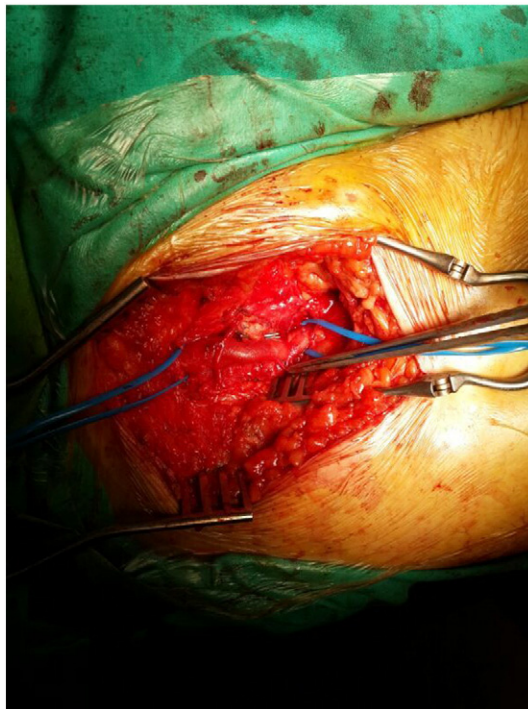


Fig. 3. Exposure of arteriovenous fistula. Intraoperative view of arteriovenous fistula.

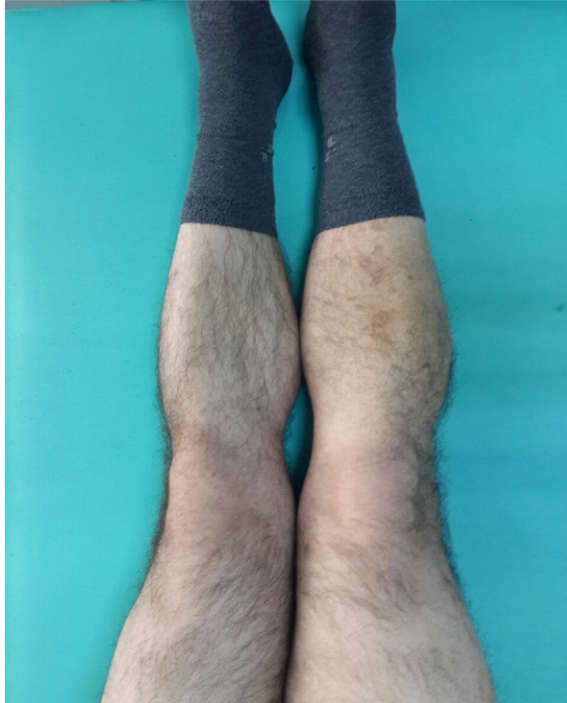

Fig. 4. Postoperative condition of lower extremity. Postoperative control examination on first month.

only 4% of fistulas [5]. Aortocaval fistulas and AVFs involving the iliac, renal, superior mesenteric, splenic, and hepatic arteries also have been reported, but are rare [6,7]. In our case patient had lower limb AVF due to small-caliber gunshot wound.

Increased shear force from shunt flow in the artery proximal to the fistula will stimulate secretion of endothelium-derived relaxation factor, which results in vasodilatation by its action on arterial wall smooth muscle. Longstanding increased blood flow will increase the diameter of the vessel and enhance fracture of the elastic fibers, which further dilates the vessel and increases shunt flow [8]. With the enlarging left-to-right shunt, chronic volume overload of the heart leads to remodeling, ventricular dilatation and heart failure [9]. In this case patient had increased diameter of effected vessels but echocardiography revealed normal findings.

Duplex ultrasonography represents the only noninvasive diagnostic method with some utility in the diagnosis of traumatic AVFs. Though digital subtraction arteriography remains the gold standard for diagnosing AVF, recently introduced less invasive tools such as MDCT and MRA provide quick but also accurate diagnosis.

Treatment options of traumatic AVFs are divided into two

1. Invasive approach: direct ligation of the injured vessel or reconstruction of the vessel wall [1]
2. Less invasive approach: direct or transfemoral embolisation with coils, closure with transluminal temporary occlusion of the pseudoaneurysm neck or balloon embolisation and direct thrombin injection [1].

In this particular case we preferred direct vision and surgical repair of AVF due to its diameter and neighborhood to deep vessels. Also patient's condition was stable.

Conclusion

Post-traumatic fistula should be obliterated as soon as possible. Untreated fistula results in complications including renin-mediated hypertension and high-output heart failure, venous and/or arterial insufficiency.

Consent

Written informed consent was obtained from the patient for publication of this case report and accompanying images. A copy of the written consent is available for review by the Editor-in-Chief of this journal.

Conflict of interests

The author(s) declare that they have no competing interests.

Authors' contributions

HG and MD analysed and interpreted the patient data regarding the traumatic arteriovenous fistula. MK and ANB were major contributors in writing the manuscript. All authors read and approved the final manuscript.

Acknowledgement

None.

References

- [1] R. Spirito, P. Trabattoni, G. Pompilio, S. Zoli, M. Agrifoglio, P. Biglioli, Endovascular treatment of a post-traumatic tibial pseudoaneurysm and arteriovenous fistula: case report and review of the literature, *J. Vasc. Surg.* 45 (2007) 1076–1079.
- [2] H. Edwards, E. Martin, R. Nowygrad, Nonoperative management of a traumatic peroneal artery false aneurysm, *J. Trauma* 22 (1982) 323–326.
- [3] S.M. Hertz, B.J. Brener, Ultrasound-guided pseudoaneurysm compression: efficacy after coronary stenting and angioplasty, *J. Vasc. Surg.* 26 (1997) 913–916.
- [4] S.S. Kang, N. Labropoulos, M.A. Mansour, M. Michelini, D. Filiung, M.P. Baubly, et al., Expanded indications for ultrasound-guided thrombin injection of pseudoaneurysms, *J. Vasc. Surg.* 31 (2000) 289–298.
- [5] J.V. Robbs, A.A. Carrim, A.M. Kadwa, M. Mars, Traumatic arteriovenous fistula: experience with 202 patients, *Br. J. Surg.* 81 (1994) 1296.
- [6] D.C. Brewster, R.P. Cambria, A.C. Moncure, R.C. Darling, G.M. LaMuraglia, S.C. Geller, W.M. Abbott, Aortocaval and iliac arteriovenous fistulas: recognition and treatment, *J. Vasc. Surg.* 13 (1991) 253.
- [7] M.S. Saunders, A. Riberi, E.A. Massullo, Delayed traumatic superior mesenteric arteriovenous fistula after a stab wound: case report, *J. Trauma* 32 (1992) 101.
- [8] O. Hartung, S. Garcia, Y.S. Alimi, C. Juhan, Extensive arterial aneurysm developing after surgical closure of long-standing post-traumatic popliteal arteriovenous fistula, *J. Vasc. Surg.* 39 (2004) 889–892.
- [9] C.F. Weng, J. Wei, Y.T. Lee, S.H. Sue, Y.C. Chuang, C.Y. Chang, K.C. Lee, High-output heart failure resulting from an obscure traumatic arteriovenous fistula, *J. Chin. Med. Assoc.* 71 (8) (2008 Aug) 428–430.