

Two successful insertions of peripherally inserted central catheters in a patient with persistent left superior vena cava

A case report

Junren Kang, MM, Bing Liu, RN, Wenyan Sun, RN*

Abstract

Rationale: Peripherally inserted central catheters (PICC), normally located at the lower 1/3rd of the superior vena cava (SVC) and cavo-atrial junction, are commonly used in cancer patients. Persistent left superior vena cava (PLSVC) is a vascular anomaly, in patients with which seldom research was reported about PICC implanted. After obtaining written informed consent, we present a case where two successful insertions of PICC were performed in a 50-year-old female patient with PLSVC and right SVC.

Patients concerns: The patient had ovarian cancer and was admitted for chemotherapy using PICC.

Diagnoses: Ovarian cancer and PLSVC.

Interventions and Outcomes: Following insertion of PICC in PLSVC, thrombosis developed. PICC was removed after routine anticoagulation therapy. Owing to tumor recurrence, a second PICC was inserted in the right SVC without any complications.

Lessons: PICC insertion in PLSVC for chemotherapy may be associated with an increased risk of deep venous thrombosis of the upper extremity. A right catheter insertion in patient with PLSVC was preferred.

Abbreviations: DVT = deep vein thrombosis, PICC = peripherally inserted central venous catheter, PLSVC = persistent left superior vena cava, SVC = superior vena cava.

Keywords: deep vein thrombosis, peripherally inserted central venous catheter, persistent left superior vena cava, superior vena cava

1. Introduction

Peripherally inserted central catheter (PICC), located at the lower 1/3rd of the superior vena cava (SVC) and cavo-atrial junction, is commonly used in cancer patients.^[1,2] Malpositioned catheters are associated with increased complications.^[3] Persistent left superior vena cava (PLSVC), a vascular anomaly, has an incidence rate of 2%.^[4] The implantable cardioverter-defibrillator may be implanted in a patient with PLSVC; however, use of

PICCs in PLSVC has seldom been reported in the literature.^[5] In this report, we present a case of two successful insertions of PICC in a patient with PLSVC and right SVC, which has not been previously reported, to the best of our knowledge.

2. Case presentation

A 50-year-old female patient with ovarian cancer was admitted to our hospital for ovarian resection, double accessory resection, and lymph node dissection. On November 22, 2013, PICC was inserted for chemotherapy. Prior to catheter insertion, a comprehensive assessment of the blood vessels, laboratory indicators, and initial medical history was performed. A 4-Fr PICC was inserted into the left upper extremity by a qualified PICC nurse. The process of catheterization was smooth, and the length of the catheter was 42 cm. Radiograph showed that the tip of the catheter was located at the PLSVC (Fig. 1). On November 28, color ultrasound, performed owing to pain in the upper limb, revealed development of thrombosis in the brachial vein. Thereafter, routine anticoagulation therapy was administered.^[6] Four months later, PICC was removed after the chemotherapy.

On March 12, 2015, PICC catheterization was advised for chemotherapy because of recurrence of the tumor. As catheterization was performed in the left upper arm the first time, the PICC nurses conducted a comprehensive assessment of the veins in the patient's right upper extremity. Venous thrombosis in the veins of the upper extremity and subclavian veins were not detected on ultrasonography. PICC was inserted into the basilic vein on the right side. Real-time ultrasound obtained during the placement of the catheter to the anticipated length showed that the catheter tip was located in the

Editor: N/A.

Informed consent was obtained from the patient for publication of this case report and accompanying images.

The authors have no conflicts of interests to disclose.

Department of Clinical Nutrition, Peking Union Medical College Hospital, Chinese Academy of Medical Sciences and Peking Union Medical College, Beijing, China.

* Correspondence: Wenyan Sun, Department of Clinical Nutrition, Peking Union Medical College Hospital, Chinese Academy of Medical Sciences and Peking Union Medical College, 1# Shuai Fu Yuan, Dongcheng District, Beijing 100730, China (e-mail: sunwenyan@pumch.cn).

Copyright © 2019 the Author(s). Published by Wolters Kluwer Health, Inc. This is an open access article distributed under the terms of the Creative Commons Attribution-Non Commercial-No Derivatives License 4.0 (CCBY-NC-ND), where it is permissible to download and share the work provided it is properly cited. The work cannot be changed in any way or used commercially without permission from the journal.

How to cite this article: Kang J, Liu B, Sun W. Two successful insertions of peripherally inserted central catheters in a patient with persistent left superior vena cava. *Medicine* 2019;98:33(e16988).

Received: 24 January 2019 / Received in final form: 27 June 2019 / Accepted: 7 August 2019

<http://dx.doi.org/10.1097/MD.00000000000016988>

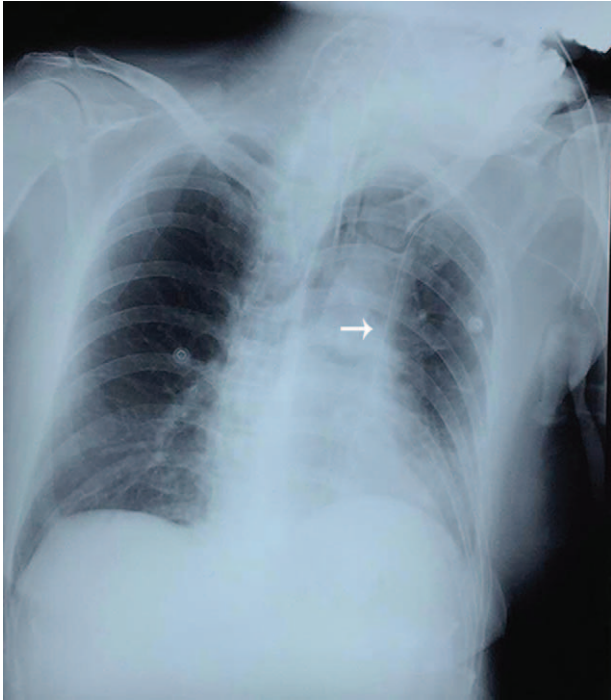


Figure 1. Chest radiograph demonstrating peripherally inserted central venous catheter located in persistent left superior vena cava (white arrow).

internal jugular vein. The PICC nurse retreated the catheter by about 10 cm and reinserted it into the blood vessel while flushing with normal saline. Chest radiography revealed the tip of the catheter at the cavo-atrial junction of the right side (Fig. 2). The PICC was removed on July 7, 2015 without any complications.

3. Discussion

In our case, PLSVC was first discovered after PICC insertion, which was consistent with previous literature. Six days after catheter insertion, upper extremity deep venous thrombosis developed in the brachial vein; hence, anticoagulation therapy was administered, and PICC was continued until the chemotherapy was completed four months later.^[6] There were many risk factors for PICC-related deep venous thrombosis in the upper extremity.^[7,8] Catheter in PLSVC may be one of the factors because of abnormal anatomical and hemodynamic conditions.

In our case, the second PICC was located in the right SVC. PLSVC with absent right SVC has been reported with an incidence of 0.09% to 0.13%^[4] and venous access should be limited to the left side in such patients.^[9] PICC in PLSVC may be safely used for chemotherapy as reported in a previous paper^[10]; however, catheter insertion in the right extremity was preferred in the patient with PLSVC. In view of the small sample size, angiography might be performed before chemotherapy with catheters in PLSVC.

In conclusion, PICC inserted in patients with PLSVC, might be associated with an increased risk of deep venous thrombosis in the upper extremity. A right catheter insertion in patients with PLSVC was preferred.

Acknowledgment

The authors thank the patient for permitting us to report this case.

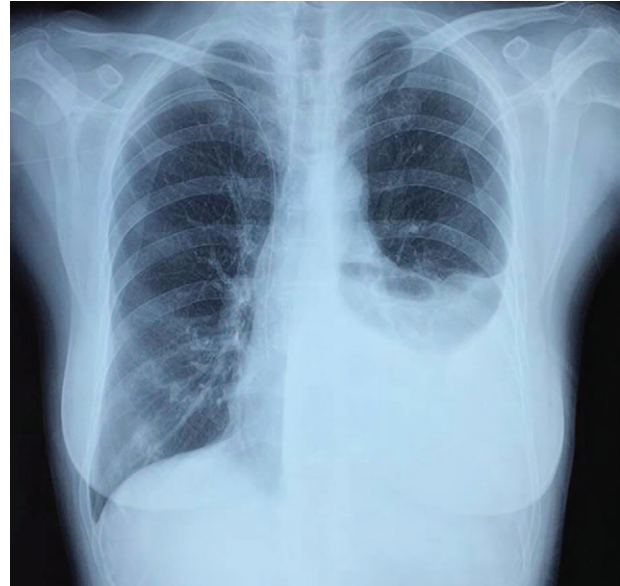


Figure 2. Chest X ray demonstrating peripherally inserted central venous catheter tip located in cavo-atrial junction.

Author contributions

Conceptualization: Junren Kang, Wenyan Sun.

Data curation: Junren Kang, Bing Liu, Wenyan Sun.

Formal analysis: Junren Kang, Wenyan Sun.

Investigation: Junren Kang, Bing Liu, Wenyan Sun.

Methodology: Junren Kang, Bing Liu, Wenyan Sun.

Project administration: Junren Kang, Wenyan Sun.

Resources: Wenyan Sun.

Supervision: Wenyan Sun.

Writing – original draft: Junren Kang.

Writing – review & editing: Wenyan Sun.

References

- [1] Kang J, Chen W, Sun W, et al. Peripherally inserted central catheter-related complications in cancer patients: a prospective study of over 50,000 catheter days. *J Vasc Access* 2017;18:153–7.
- [2] Liu B, Sun W, Wang K. A successful insertion of PICC in patient with cardiac angiosarcoma and neoplasty of right atrium and pacemaker: a case report. *Medicine (Baltimore)* 2017;96:e9225.
- [3] Wang K, Sun W, Shi X. Upper extremity deep vein thrombosis after migration of peripherally inserted central catheter (PICC): a case report. *Medicine (Baltimore)* 2017;96:e9222.
- [4] Sheikh AS, Mazhar S. Persistent left superior vena cava with absent right superior vena cava: review of the literature and clinical implications. *Echocardiography* 2014;31:674–9.
- [5] Kumar V, Yoshida N, Yamada T. Successful implantable cardioverter-defibrillator implantation through a communicating branch of the persistent left superior vena cava. *J Arrhythm* 2015;31:331–2.
- [6] Kearon C, Akl EA, Ornella J, et al. Antithrombotic therapy for VTE disease: CHEST guideline and expert panel report. *Chest* 2016;149:315–52.
- [7] Kang J, Sun W, Li H, et al. Peripherally inserted central catheter-related vein thrombosis in breast cancer patients. *J Vasc Access* 2016;17:67–71.
- [8] Chopra V, Kaatz S, Conlon A, et al. The Michigan Risk Score to predict peripherally inserted central catheter-associated thrombosis. *J Thromb Haemost* 2017;15:1951–62.
- [9] Patel Y, Gupta R. Persistent left superior vena cava with absent right superior vena cava. *Methodist Debakey Cardiovasc J* 2018;14:232–5.
- [10] Bader M, Bromley P, Jester I, et al. Central venous catheters in the left-sided superior vena cava: clinical implications. *J Pediatr Surg* 2013;48:400–3.