

Case Report

Pure Transitional Cell Carcinoma of the Ovary Presenting as Bilateral Complex Cystic Masses in a Premenopausal Woman – Case Report and Review of Literature

Garima Yadav, Vrushi Solanki, Jyotsna Naresh Bharti¹, Sushma Bharti¹, Pratibha Singh, Meenakshi Gothwal

Departments of Obstetrics and Gynaecology and ¹Pathology, All India Institute of Medical Sciences, Jodhpur, Rajasthan, India

ABSTRACT

The understanding of ovarian malignancy pathogenesis has greatly increased with identification of varied genomic mutation profiles, which directs the clinical behavior of the tumors. The present case describes the rare subtype of pure transitional cell carcinoma which is no more included in the newer World Health Organization (WHO) classification as the WHO labels it as a type of high-grade serous ovarian cancer with transitional cell differentiation, although in our case no serous component was identified. Hence, with revised classification of ovarian malignancies, it is important to report all rare subtypes in order to understand their biology and behavior.

KEYWORDS: High-grade serous ovarian cancer, malignant Brenner tumor, pure transitional cell carcinoma

INTRODUCTION

Ovarian cancer is the most lethal gynecological malignancy associated with a late diagnosis due to the absence of effective screening tests. Depending on the histopathological features, the World Health Organization (WHO) (2004) classifies Brenner tumors of the ovary as benign, borderline, or malignant.^[1] Brenner tumors comprise <5% of all epithelial ovarian malignancies, and most of the Brenner tumors are benign. Malignant Brenner comprises only 2% of all Brenner tumors of the ovary. Pure transitional cell carcinoma (TCC) was first defined by Austin and Norris in 1987 when they reported a subset of ovarian tumors with histologic features similar to those seen in a malignant Brenner tumor, but the tumors lacked the associated benign, borderline, or proliferative Brenner tumor component and prominent stromal calcification.^[2] Thus, these tumors were called as pure TCCs. Austin and Norris concluded that ovarian TCC arises directly from the pluripotential surface epithelial cells with urothelial potential, rather than from a benign or proliferative Brenner tumor precursor, and the mode of spread also simulates TCC of the bladder. The true incidence of TCC of the ovary still remains unknown, but TCC of the ovary has gross morphologic features similar to TCC of the bladder, and it was proposed that since this subset behaves

more aggressively than malignant Brenner tumors, they should be identified as a separate entity of epithelial ovarian cancers (EOCs). Although the recent WHO 2014 classification of EOCs does not identify TCC of the ovary as a separate entity and suggests that in the absence of Brenner component, one must think of high-grade serous tumor with transitional cell differentiation.^[3]

CASE REPORT

A 45-year-old female, P3003, presented to us with complaints of a lump in the abdomen for 5 months. The patient had no menstrual abnormalities and had no significant past medical, surgical, or family history. Abdominal examination revealed a lump corresponding to 26-week gravid uterus size, and it was firm in consistency with irregular margins and predominantly cystic components. It had restricted mobility and was

Address for correspondence: Dr. Garima Yadav,

Department of Obstetrics and Gynaecology, Room No. 3089, Medical College Block, All India Institute of Medical Sciences, Basni Industrial Area, Phase 2, Jodhpur - 342 005, Rajasthan, India.

E-mail: garimapunein@gmail.com

This is an open access journal, and articles are distributed under the terms of the Creative Commons Attribution-NonCommercial-ShareAlike 4.0 License, which allows others to remix, tweak, and build upon the work non-commercially, as long as appropriate credit is given and the new creations are licensed under the identical terms.

For reprints contact: reprints@medknow.com

How to cite this article: Yadav G, Solanki V, Bharti JN, Bharti S, Singh P, Gothwal M. Pure transitional cell carcinoma of the ovary presenting as bilateral complex cystic masses in a premenopausal woman – Case report and review of literature. J Mid-life Health 2019;10:156-9.

Access this article online

Quick Response Code:



Website: www.jmidlifehealth.org

DOI: 10.4103/jmh.JMH_66_19

nontender. Vaginal examination confirmed the presence of an abdominopelvic mass which was felt through all the fornices while pouch of Douglas and rectal fossa were free with no nodularity.

Since clinical examination revealed an operable mass, the patient was planned for an exploratory laparotomy. She was advised routine preoperative investigations along with tumor markers, namely CA-125, CEA, and CA-19-9, and abdominopelvic computed tomography (CT) scan was advised. All her routine blood investigations were normal along with a normal chest X-ray. Her CA-125 levels were raised to 620 IU/L, whereas rest of the tumor markers were normal. CT scan was suggestive of a large septated cystic lesion in the left adnexa with a few irregular solid foci along with thick homogeneously enhancing septa with strong blood flow. The right ovary was not separately visualized, the uterus was found to be enlarged with multiple small fibroids, and rest of the upper abdominal organs were reported to be normal. There were no ascites and no retroperitoneal lymphadenopathy. Based on raised CA-125 and a complex cystic lesion on imaging, provisional diagnosis of a malignant left adnexal mass was made, and the patient was taken up for a staging laparotomy. Intraoperatively, two large multilobulated masses were seen arising from both the ovaries. Both the masses appeared prominently cystic with bosselated surface and no capsular excrescences. The right ovarian mass measured around 12 cm × 12 cm × 6 cm, and the left ovarian mass measured around 22 cm × 17 cm × 14 cm. The uterus was of 12-week size with cut section showing myohyperplasia and multiple intramural fibroids [Figures 1 and 2]. There were minimal ascites; hence, peritoneal washings were collected and sent for cytological evaluation. Both the ovarian masses were then removed intact followed by thorough visual and haptic examination of all abdominal organs, omentum, and peritoneal surfaces. Total abdominal hysterectomy with bilateral salpingo-oophorectomy was performed followed by total omentectomy and removal of bilateral pelvic lymph nodes. There was no evidence of any extraovarian and extrapelvic disease on gross inspection, and hence, multiple peritoneal samplings were taken.

Her fluid cell cytology showed no malignant cells. Histopathology was suggestive of bilateral ovarian pure TCC as there was no evidence of any benign, borderline, or malignant Brenner component, neither was there any serous component identified [Figure 3a and b]. There was endometrial hyperplasia along with myometrial adenomyosis and leiomyomatosis in the uterus. Immunohistochemistry was done to confirm the diagnosis, and the tumor cells showed nuclear positivity for WT1, cytoplasmic positivity for CK-7 [Figure 3c and d], and membrane positivity for Ber-EP4.

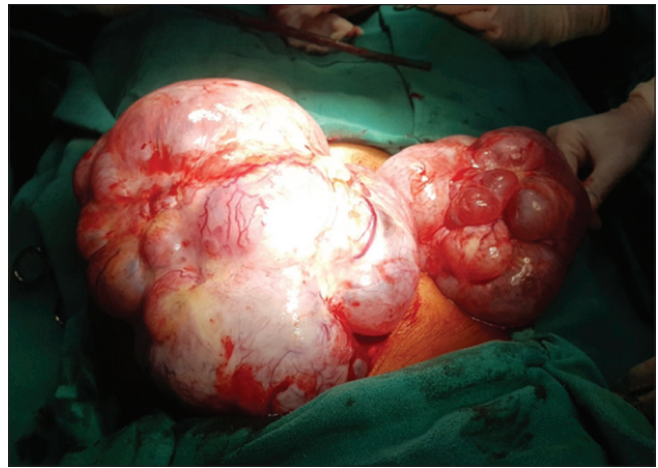

Figure 1: Bilateral ovarian masses with bosselated surface and increased surface vascularity

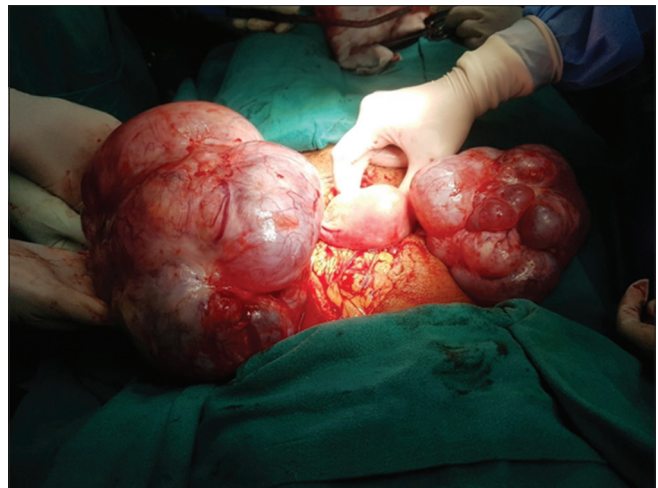

Figure 2: Bilateral ovarian masses with enlarged uterus due to multiple fibroids

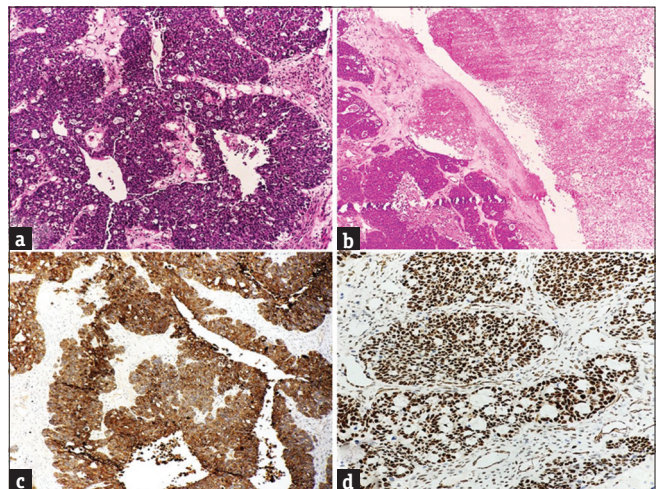


Figure 3: (a and b) Cyst wall and papillae lined by atypical urothelial cells with high-grade features. The bands of epithelium are multilayered and contain intraepithelial microspaces. Large areas of tumor necrosis seen (H and E, ×40). (c and d) The tumor cells show cytoplasmic positivity for CK 7 and nuclear positivity for WT1 (IHC, ×40)

Following histopathological diagnosis of pure TCC, the patient was started on platinum-based chemotherapy and is doing well in the follow-up visits.

DISCUSSION

As described in detail by Eichhorn and Young, ovarian TCC typically shows undulating, diffuse, insular, and trabecular growth patterns along with majority of the cases showing cystic spaces of varying sizes and blunt papillae. The tumor cell nuclei are oblong or round, often exhibiting nucleoli or longitudinal grooves. The cytoplasm is often pale and granular and can rarely be clear or eosinophilic.^[4]

The mean age of presentation is 59 years, and most of the women are postmenopausal, similar to other epithelial ovarian malignancies. Similarly, CA-125 is a clinically useful serum marker for diagnosing tumor progression and recurrence in ovarian TCC.^[5]

The immunophenotype of TCC of the ovary is similar to that of other surface carcinomas of the ovary but differs from that of TCC of the bladder.^[6] Ovarian TCCs are negative for CK-20, thrombomodulin, and uroplakin III, which are the antigens that are detected in bladder TCCs.^[3,4] Unlike bladder TCCs, ovarian TCCs are often positive for vimentin, CA-125, and Wilms' tumor protein (WT1).^[4] Furthermore, almost all of the ovarian TCCs marked strongly for estrogen receptors, a characteristic that may help to differentiate these lesions from papillary urothelial carcinoma metastatic to the ovary.^[7] In another study, researchers reported that overexpression of C-erbB3 was a common event in TCC of the ovary.^[8]

TCC of the ovary is reported to be sensitive to cisplatin-based chemotherapy and has a better prognosis than other types of common epithelial tumors of the ovary.^[9,10] Optimal surgical resectability followed by cisplatin-based chemotherapy might contribute to the survival benefit.^[11,12] The WHO in the year 2014 revised the EOC classification and divided EOC into Type 1 and Type 2 tumors, wherein Type 1 tumors typically develop from premalignant or borderline lesions in a manner common to many other epithelial cancers and comprise low-grade serous, clear-cell, mucinous, and transitional cell (Brenner) subtypes. These tumors although display frequent oncogenic alterations are otherwise genomically stable and p53 wild type. These tumors typically present as large, unilateral, and cystic neoplasms that grow in an indolent fashion, and when confined to the ovary, they have an excellent prognosis.^[13] By contrast, the Type 2 category is marked by a far more aggressive tumor with p53 mutations and genomic instability. High-grade serous ovarian

cancers (HGSOCs) are now classified as Type 2 ovarian tumors as clinically they differ from Type 1 in terms of rapid growth, early dissemination, and poor overall survival.

In certain cases, HGSOC may present with areas displaying a solid growth pattern that simulates the appearance of endometrioid or TCC. Although morphologically distinct, these tumors show an immunoreactivity identical to typical HGSOC and are thus not considered as a separate entity. Hence, as clinicians, we must also try and keep up with the molecular advancements in the disease pathology of ovarian malignancies and look for histopathological evidence for differentiating Type 1 from Type 2 tumors.

Declaration of patient consent

The authors certify that they have obtained all appropriate patient consent forms. In the form the patient(s) has/have given his/her/their consent for his/her/their images and other clinical information to be reported in the journal. The patients understand that their names and initials will not be published and due efforts will be made to conceal their identity, but anonymity cannot be guaranteed.

Financial support and sponsorship

Nil.

Conflicts of interest

There are no conflicts of interest.

REFERENCES

1. World Health Organization. Classification of Tumours, Pathology and Genetics of Tumours of the Breast and Female Genital Organs. Lyon: IARC Press; 2003. p. 140-3.
2. Austin RM, Norris HJ. Malignant Brenner tumor and transitional cell carcinoma of the ovary: A comparison. *Int J Gynecol Pathol* 1987;6:29-39.
3. Kurman RJ, Cerhanjiu ML, Herrington CS, Young RH, editors. WHO Classification of Tumours of Female Reproductive Organs. Lyon: IARC; 2014.
4. Eichhorn JH, Young RH. Transitional cell carcinoma of the ovary: A morphologic study of 100 cases with emphasis on differential diagnosis. *Am J Surg Pathol* 2004;28:453-63.
5. Ayhan A, Tuncer ZS, Saracç E, Ayhan A. Transitional cell carcinoma of the ovary. *Int J Gynecol Cancer* 1996;6:183-5.
6. Silva EG, Robey-Cafferty SS, Smith TL, Gershenson DM. Ovarian carcinomas with transitional cell carcinoma pattern. *Am J Clin Pathol* 1990;93:457-65.
7. Croft PR, Lathrop SL, Feddersen RM, Joste NE. Estrogen receptor expression in papillary urothelial carcinoma of the bladder and ovarian transitional cell carcinoma. *Arch Pathol Lab Med* 2005;129:194-9.
8. Shen K, Lang J, Guo L. Overexpression of C-erbB3 in transitional cell carcinoma of the ovary. *Zhonghua Fu Chan Ke Za Zhi* 1995;30:658-61.
9. Sweeten KM, Gershenson DM, Burke TW, Morris M, Levenback C, Silva EG. Salvage chemotherapy for refractory

- transitional cell carcinoma of the ovary (TCC). *Gynecol Oncol* 1995;59:211-5.
10. Gershenson DM, Silva EG, Mitchell MF, Atkinson EN, Wharton JT. Transitional cell carcinoma of the ovary: A matched control study of advanced-stage patients treated with cisplatin-based chemotherapy. *Am J Obstet Gynecol* 1993;168:1178-85.
 11. Kommoss F, Kommoss S, Schmidt D, Trunk MJ, Pfisterer J, du Bois A. Survival benefit for patients with advanced-stage transitional cell carcinomas vs. Other subtypes of ovarian carcinoma after chemotherapy with platinum and paclitaxel. *Gynecol Oncol* 2005;97:195-9.
 12. Hollingsworth HC, Steinberg SM, Silverberg SG, Merino MJ. Advanced stage transitional cell carcinoma of the ovary. *Hum Pathol* 1996;27:1267-72.
 13. Kurman RJ, Shih IeM. The dualistic model of ovarian carcinogenesis: Revisited, revised, and expanded. *Am J Pathol* 2016;186:733-47.