

# Rheumatologic emergencies

Luis Arturo Gutiérrez-González<sup>1</sup>

Received: 7 May 2015 / Revised: 7 June 2015 / Accepted: 8 June 2015 / Published online: 24 June 2015  
© International League of Associations for Rheumatology (ILAR) 2015

**Abstract** Rheumatological conditions can sometimes present as emergencies. These can occur due to the disease process or infection; contrary to what many people think, rheumatologic emergencies like a pain, rheumatic crisis, or attack gout do not compromise the patient's life. This article mentioned only true emergencies: catastrophic antiphospholipid syndrome (cAPS), kidney-lung syndrome, central nervous system (CNS) vasculitis, anti-Ro syndrome (neonatal lupus), and macrophage activation syndrome (MAS). The management of above emergencies includes critical care, immunosuppression when indicated, and use of a diagnostic flowchart as well as fast laboratory profile for making decisions. Anticoagulants have to be used in the management of antiphospholipid syndrome. A good understanding of these conditions is of paramount importance for proper management.

**Keywords** Arthritis · Diagnostic tests · General · Methodology · Rheumatic diseases · SLE · Vasculitis

## Introduction

According to the American Medical Association (AMA), emergencies are defined as those situations that place the life of the patient or an organ function in immediate danger. The World Health Organization (WHO) says that emergency refers to a case where failure to provide care may lead to the death of the patient in a matter of minutes and the administration of

first aid—by anyone person—is vitally important [1]. In contrast, the concept of emergency according to AMA is any condition that in the opinion of the patient, his/her family, or whoever is responsible requires immediate health care; however, the disease may be slow in evolution and not necessarily lethal but should be taken care of within maximum 6 h to prevent major complications [1, 2].

It is important to clarify some concepts since, contrary to what many people think, rheumatologic emergencies like septic arthritis, lower back pain, gout attack, systemic lupus erythematosus (SLE) flare-ups (except those affecting vital organs), and cervical pain is not a real emergency. The true emergencies are those that are life threatening for the patient with mortality rates of around 50 % (Table 1), even when timely intervention is provided.

## Catastrophic antiphospholipid syndrome

The term catastrophic antiphospholipid syndrome (cAPS) represents a rapidly evolving severe form of APS that leads to multiple organ failure [3]. Currently, this entity is also called “Asherson’s syndrome” [4, 5]. Patients with cAPS share common traits: clinical evidence of multiple organ involvement (three or more organs) and anatomopathological evidence of multiple small diameter blood vessels; a minority also presents thrombosis of large diameter blood vessels, in addition to the presence of antiphospholipid antibodies (APA), usually observed at high titers (Table 2).

This entity represents less than 1 % of all patients with APS; the majority (>90 %) are primary APS while the rest have concomitant autoimmune disease (secondary APS), including SLE, Sjögren syndrome, systemic sclerosis, rheumatoid arthritis (RA), lupus-like disease, and a small percentage of ulcerative rectal colitis (URC).

✉ Luis Arturo Gutiérrez-González  
luiskakuro@gmail.com

<sup>1</sup> Rheumatology Department, Hospital Universitario de Caracas, HUC-UCV, Caracas 1020, DC, Venezuela

**Table 1** Classification of rheumatologic emergencies

- Catastrophic antiphospholipid syndrome (cAPS)
- Kidney-lung syndrome
- Central nervous system (CNS) vasculitis
- Anti-Ro syndrome (neonatal lupus)
- Macrophage activation syndrome (MAS)
- Scleroderma renal crisis
- Septic arthritis and
- Atlantoaxial subluxation

The clinical evidence of vascular occlusion is confirmed with imaging techniques: CT scan (angio-CT), duplex arterial and venous ultrasound, nuclear magnetic resonance (angio-NMR), and arteriography [6]. Whenever this entity is suspected, it is important to order a complete renal function test since the kidney is one of the primary organs to be compromised, observing 50 % rise in plasma creatinine, severe systemic hypertension (>180/100 mm Hg), and/or proteinuria (>500 mg/24 h).

This disease may be suspected usually in young female patients with severe systemic involvement, Venereal Disease Research Laboratory (VDRL) (+), thrombocytopenia, pancytopenia, hemolytic anemia—frequently with COOMBS (+). The peripheral blood smear (PBS) is critical to reveal a small number of fragmented blood cells (schistocytes), typical of macroangiopathic hemolysis. Tp/TpT show extended clotting

**Table 2** Criteria for catastrophic APS**Definite cAPS**

- Evidence of vessel occlusion or occlusive impact on >3 organs, systems, and/or tissues<sup>a</sup>
- Simultaneous or <1 week event occurrence
- Anatomopathological confirmation of small-diameter vessel occlusion, at least in one organ or tissue<sup>b</sup>
- Persistent presence of antiphospholipid antibodies (APA/lupus anticoagulant)  $\neq$  6 weeks<sup>c</sup>

**Probable cAPS**

- Two or more organs or systems affected
- Occurrence of two events in less than 1 week and the third prior to week 4
- The four criteria, except for absence of separate lab confirmation of at least 6 weeks due to early patient death.

<sup>a</sup> Usually clinical evidence of vascular occlusion, confirmed by imaging techniques if appropriate. Renal involvement is defined as a 50 % rise in plasma creatinine, severe systemic hypertension (>180/100 mm Hg), and/or proteinuria (>500 mg/24 h)

<sup>b</sup> The anatomopathological confirmation is done based on signs of thrombosis, though occasionally vasculitis may be present

<sup>c</sup> If the patient had not been previously diagnosed with APS, the lab confirmation requires the presence of antiphospholipid antibodies detected on two or more separate occasions, at least 6 weeks apart (not necessarily at the time of the thrombotic accident), in accordance with the criteria for definite APS

times, but remember that clotting times are extended in vitro, while in vivo there is increased coagulation and hence the occurrence of thrombocytopenia [4, 5].

### Organ system involvement in cAPS

There is multiple organ involvement with the development of thrombi at the level of the renal artery trunk or branches, the intrarenal arteries or arterioles, glomerular capillaries, and renal veins, with a distinct prevalence of small vessel occlusion (thrombotic microangiopathy). Lung involvement from adult respiratory distress syndrome (ARDS) is sometimes accompanied by intra-alveolar hemorrhage, pulmonary embolism, or pulmonary artery thrombosis (Table 3).

The most feared complication is related to the CNS and the development of cerebral infarction. Depending on the area affected, this may give rise to seizures (temporal involvement). The most frequent manifestation of the peripheral nervous system is mononeuritis multiplex [5, 6].

In terms of the GI tract, acute abdominal pain and/or abdominal distention may be confounding factors for the treating physician, leading to emergency surgical interventions called blank laparotomies (absence of findings). Patients with cAPS may also present esophageal perforation, ischemic colitis, and liver and spleen infarctions. Male patients may present with testicular infarct with severe scrotal pain and inflammation, and even necrosis of the prostate has been identified, that mimics an acute prostatitis in males and ovarian infarct in females.

### cAPS treatment

Due to the complications of a severely ill patient, the support measures offered at the ICU are critical to control the underlying disease. The multidisciplinary management in the ICU includes the establishment of a central venous access, arterial line, ventilation support, blood pressure monitoring, fluid therapy, and controlling hydroelectrolytic imbalance [6, 7].

If multiple organ failure is suspected as a result of cAPS, anticoagulant therapy must be initiated, whether with a

**Table 3** Organ system involvement in cAPS

Renal	78 %
Pulmonary	66 %
CNS	56 %
Cutaneous	50 %
Gastrointestinal	38 %
Hepatic	34 %
Adrenal	13 %
Urogenital	6 %

5000 U bolus of nonfractionated heparin, followed by a continuous infusion of 1500 U/h with close aPTT monitoring. When the clinical course of the disease is satisfactory and the patient tolerates oral administration, coumarinic agents (sodium warfarin) should be started up to an INR >3 and ≤4.5. The use of low molecular weight heparin such as enoxaparin is quite effective as well, at a dose of 1 mg/kg/day.

Concomitant glucocorticoid (GC) therapy shall be started with anticoagulation. The recommendation is to start glucocorticoid pulse therapy with methylprednisolone (because it is the most potent and does not have a hepatic first-pass effect) at a dose of 15–20 mg/day for 3–5 days and reduce the GC to a maintenance dose: 1–2 mg/kg/dose of methylprednisolone divided into three doses per day (TID). If the patient fails to respond, gamma globulin 400 mg/kg/day for 5 days (average dose 25–30 g/day) is added, and the recommended infusion rate is 0.5 ml/kg/h. This regime is repeated once a month, once the patient is out of danger. The use of cyclophosphamide (CYC)-type cytostatic agents is recommended, at a dose of 0.5–1 g/m<sup>2</sup> SC, always combined with gamma globulin for patients failing to respond to GC therapy [8].

For severely ill patients failing to respond to gamma globulin and CYC, the recommendation is to proceed to plasmapheresis for three to five continuous days, 100–150 ml/min [8, 9].

### Pulmonary-renal syndrome

The term “pulmonary-renal syndrome” was originally described by Goodpasture in 1919 and is used to describe the development of renal failure associated to respiratory distress, characterized by rapidly progressing glomerulonephritis (RPGN) and diffuse alveolar bleeding (DAB) secondary to an autoimmune process [10].

From the pathophysiological point of view, the systemic inflammation of the small vessels results in vasculitis of the arteriols, capillaries, and venules, accompanied by necrosis, infiltration of the vascular walls with the resulting extravasation of erythrocytes into the lung alveolus. Histologically, lung biopsies show capillaritis, and the renal biopsies show glomerular disruption, fibrinoid necrosis, and crescent formation [10, 11]. Due to vascular wall damage, there is extravasation of immune cells and fibrin in Bowman’s space, with the subsequent obliteration and renal function decline [10, 11].

From the immunopathological perspective, three entities have been described: antibody mediated (type 1), immune complex mediated (type 2), and pauci-immune (type 3). Type 1 is related to antiglomerular basal membrane antibodies (anti-GBM), type 2 is related to SLE, and type 3 to vasculitis associated with neutrophil cytoplasmic antibodies (ANCA) [11, 12].

The most frequent causes of pulmonary-renal syndrome (PRS) in adults are vasculitis associated with neutrophil cytoplasmic antibodies (ANCA) in 56–77.5 % of the cases,

followed by antiglomerular basement membrane antibody (anti-GBM Ab), representing 12.5–17.5 % of the patients. Some of the less frequent causes (<10 %) are double positive disease, APS-associated vasculitis, SLE-associated vasculitis, and IgA vasculitis (Purpura Henoch-Schönlein). Other less frequent, nonautoimmune etiology causes should be ruled out (Table 4).

### Double positive disease in PRS

There is a subgroup among the PRS patients with both groups of antibodies present: ANCA and anti-MBG [11]. The medical literature describes 5–14 % with ANCA (+) and detectable anti-GBM levels; another subgroup has 30–43 % anti-GBM with ANCA (+). The prevailing antigen in

**Table 4** Causes of nonautoimmune PRS

1. Cardiovascular disease:
  - Congestive heart failure (CHF)
  - Valve disease
  - Atrial tumors
2. Renal injury with pulmonary edema
3. Hemostatic abnormalities:
  - Thrombocytopenia
  - Uremia
  - Anticoagulants, thrombotic, platelet or thrombolytic agents
  - Disseminated intravascular coagulation
4. Barotrauma
5. Infections:
  - Leptospirosis
  - Staphylococcus aureus*
  - Legionella pneumophila*
  - Hantavirus
  - Malaria
6. Embolic events:
  - Cholesterol embolism syndrome
  - Fatty embolism
  - Thromboembolic disease
7. Malignant hypertension with renal and heart failure
8. Malignancy:
  - Primary lung tumor
  - Metastatic
9. Toxins:
  - Paraquat intoxication
  - Solvents
  - Cannabis (marihuana)
  - “Crack” cocaine
10. Idiopathic hemosiderosis
11. Lymph-angioliomatosis
12. Pulmonary capillary hemangiomas

ANCA-associated PRS is myeloperoxidase (MPO) with positive ANCA in 82 %.

One of the biomarkers identified in PRS to predict the risk of death is MPO. MPO together with age (older) and the need for hemodialysis are associated to a shorter survival [9–11]. As is the case with any autoimmune disease, particularly when early intervention may be life saving in real emergencies, there is no time to wait for the immunerheumatologic profile results, and much less to wait for results of the renal biopsy or the fibrobronchoscopic bronchoalveolar lavage.

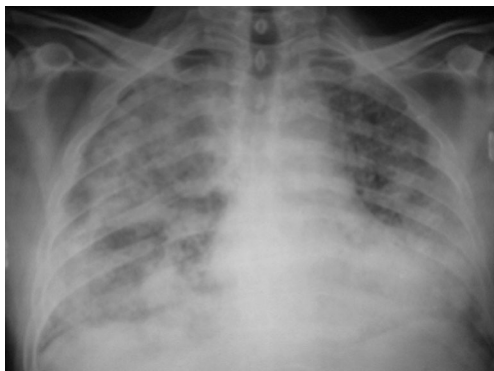A simple chest X-ray is very sensitive but not specific for diagnosing PRS. Less than 13 % of the patients with diffuse alveolar hemorrhage do not show evidence of the typical patchy shading, and this is due to the fact that this is a very dynamic process and opacities change rapidly (Fig. 1). Something that may help is that PRS patients do not have pleural effusion, so if the X-ray indicates the presence of pleural effusion, the PRS is not autoimmune and may probably be due to congestive heart failure or fluid overload [11–13].

Transthoracic echocardiography may assist in the diagnosis of cardiogenic pulmonary edema. High-resolution CT is superior to the conventional chest X-ray to identify localized ground glass opacity or more confluent zones (Fig. 2).

In terms of a simple urinalysis, a reagent strip may reveal hematuria and proteinuria (active sediment). When blood cell casts are evidenced under the microscope, SLE should be ruled out, while the presence of renal tubular cells, hyaline casts, or epithelial cell and mixed casts requires ruling out sepsis. In PRS, hematuria is usually microscopic with dimorphic erythrocytes (suggestive of a glomerular source of bleeding).

### PRS treatment

There is no doubt that glucocorticoid therapy continues to be the battle horse for the treatment of vasculitis and in particular PRS vasculitis. Pulse dosing continues to give the best results, and the drug of choice is methylprednisolone 15–20 mg/day for three to five continuous days, followed by the maintenance dose of 1–2 mg/kg/dose (divided into three doses), with



**Fig. 1** Chest X-ray in PRS. Patchy opacities

concomitant use of CYC-type cytostatic agents at a dose of 0.5–1 g/m<sup>2</sup> SC [14].

Recent studies have shown that in anti-GBM-associated PRS, apheresis for 14 continuous days 100–150 ml/min or until the anti-GBM antibodies are removed reduces the mortality and the rate of relapses (as shown in the PEXIVAS trial). In contrast, in ANCA (+)-associated PRS, using biological therapies such as anti-CD20 (rituximab) at a dose of 350 mg m<sup>2</sup> SC × four doses per week has resulted in positive outcomes [15, 16].

It is important to emphasize that the relapse rate in this patients ranges from 27 to 35 %, and hence, immunosuppressive therapy shall be maintained. The most commonly used agents are metotrexate, azathioprine, and mycophenolate mofetil [14].

### CNS vasculitis

The term vasculitis refers to the inflammation of the blood vessels, including arteries and veins, regardless of diameter. It results in tissue damage from ischemia and the subsequent activation of the inflammatory cascade that leads to blood vessel occlusion and necrosis [17, 18]. The cause is the direct effect of the antigen-antibody complex that triggers an inflammatory cascade mostly mediated by cytokines Th1 [17, 19].

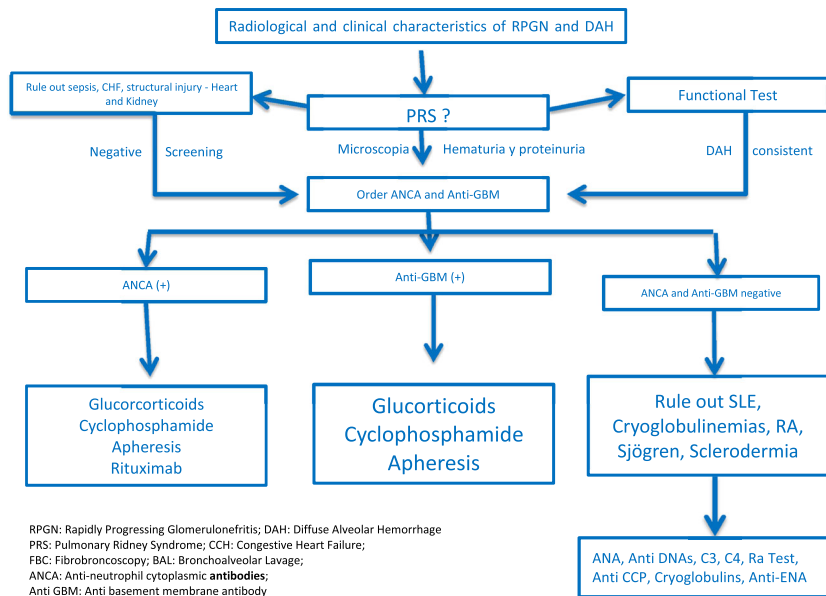
The rheumatic diseases with manifestations of central and peripheral nervous system vasculitis are classified as follows:

1. Connective tissue diseases: systemic lupus erythematosus, scleroderma, rheumatoid arthritis, Sjögren syndrome, mixed diseases of the connective tissue, and Behçet's disease.
2. Systemic necrotizing vasculitis: polyarteritis nodosa, Churg-Strauss syndrome, microscopic polyangiitis, Kawasaki disease.
3. Systemic granulomatous vasculitis: Wegener's granulomatosis, lymphomatoid granulomatosis, and lethal midline granuloma.

### Diagnostic approach for CNS vasculitis

If a cerebral vasculitis of autoimmune origin is suspected, there has to be first a pretest verification: predominantly females, young, no previous history of cardiovascular disease, focal or multiple lesions evidenced in a brain MRI or CT [17]. Always rule out any infectious etiology through a cerebrospinal fluid (CSF) analysis showing pleocytosis with a prevalence of plasmacytoid cells and in lesser numbers polymorphonuclear (PMN). It is important to know the level of proteins in the CSF since a cyto-protein disassociation (i.e., CSF

**Fig. 2** Diagnostic-therapeutic algorithm in PRS. *RPGN* rapidly progressing glomerulonephritis, *DAH* diffuse alveolar hemorrhage, *PRS* pulmonary-renal syndrome, *CCH* congestive heart failure, *FBC* fibrobroncoscopy, *BAL* bronchoalveolar lavage, *ANCA* antineutrophil cytoplasmic antibodies, *anti-GBM* antibasement membrane antibody



pleocytosis with no evidence of elevated proteins or with a very discrete rise) may suggest an autoimmune process. In contrast, an albumin-cytological disassociation suggests a polyradiculoneuritic process such as multiple sclerosis or Guillain-Barre. Infections and neoplastic lesions may also be ruled out via the CSF [16–19].

CT and MRI imaging studies are very helpful during the first hours of evolution of the condition; it has been said that there are some lesions suggestive of vasculitis, including a disrupted white-grey matter connectivity, parenchymal punctiform lesions, or multiple focal lesions [17].

Cerebral angiography helps to identify segmented stenosis of the intracranial vessels; the leptomeningeal and/or cerebral parenchyma biopsy to show the presence of vascular inflammation and rule out other diagnosis is seldom used anymore because it is a challenging procedure with low sensitivity [19] (Table 5).

Diagnostic images such as the brain MRI are sensitive but not specific because of the nature of the lesions that share multiple characteristics with many focal white matter lesions of different vascular origin. The same happens with the presence of cortical atrophy and even with atrophy of the corpus callosum observed in certain autoimmune diseases such as multiple sclerosis [17, 19, 20].

The advent of single-photon emission computed tomography (SPECT) has been most helpful to assess the regional cerebral flow and to detect functional disorders in those areas of MRI-identified lesions to be able to link those lesions to neurological and extra-neurological manifestations (large vessel inflammation in Takayasu’s disease), also be observed a unique brain ischemic lesion like at Neuro-Behcet’s (Fig. 3). SPECT has enabled before and after treatment follow-up of autoimmune diseases [16, 19, 21].

**Anti-Ro syndrome (neonatal lupus)**

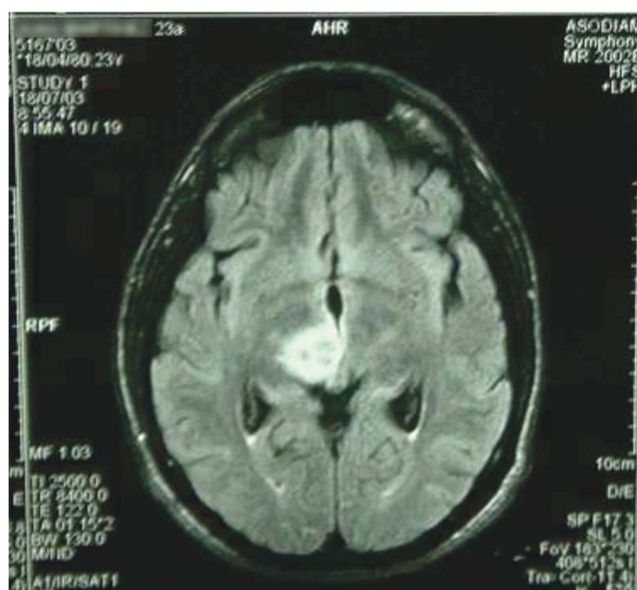Neonatal lupus erythematosus is considered a model for passive acquisition of autoimmune disease, characterized by the transplacental passage of the maternal anti-SSA/Ro and anti-SSB/Lato the fetus. The typical clinical traits of the neonatal anti-Ro syndrome are transient eruption, congenital heart block, hepatobiliary dysfunction, hematological and neurological dysfunction, in addition to pulmonary abnormalities [22].

The anti-Ro syndrome presents after week 16 and more often around week 30 of pregnancy. The incidence is 1:15, 000 life births, and left untreated, the in utero mortality is of 23 %, while at 1 year of age is 54 % [23, 24]. The clinical

**Table 5** Diagnostic approach to CNS vasculitis

	Acute phase reactants	VSG/PCR	Pulses	Recurrent ulcerations	Antibodies
Wegener	↑↑↑		Normal	(-)	ANCAc
Behçet	↑↑↑		Normal	(-)	(-) <sup>a</sup>
LES	↑↑		Normal	(+/-)	ANA, anti-dsDNA
Sjögren	↑		Normal	(-)	Anti-Ro/anti-LA
Takayasu	↑↑↑		≠	(+)	(-)

<sup>a</sup> Not associated to antibody but to the histocompatibility antigen HLA B-51



**Fig. 3** Single ischemic MRI lesion in a patient with Neuro-Behçet

presentation in the fetus and the newborn is bradycardia. At birth, there is evidence of skin lesions—annular erythema (desquamative annular plaques) affecting the body as a whole—in 15–25 % of the cases, rather than the typical SLE malar erythema. The liver injury is usually asymptomatic and results in elevated transaminases and even cholestatic hyperbilirubinemia. Follow-up studies have indicated that the autoimmune disease no longer persists once the patient reaches adolescence and adulthood [22, 24].

## Treatment

This pathology should be suspected in all reproductive age patients when anti-Ro and anti-LA antibodies are present. Monthly evaluations shall be recommended early in pregnancy with the participation of the obstetrician gynecologist. Close attention shall be paid to any rhythm changes during the biophysical profile evaluation, and a treatment change is in order as soon as an in utero bradycardia is detected. If the mother was under steroid therapy, the recommendation is to initiate fluorinated glucocorticoids such as oral dexametasonone 4–6 mg OD, because the fluorinated halogenated agents cross the placenta [25]. As soon as the baby is born, the newborn shall be admitted to the neonatal intensive care unit for co-management with pediatric cardiology (permanent or temporary pacemaker).

## Macrophage activation syndrome

Macrophage activation syndrome (MAS) is beyond doubt the most feared rheumatologic emergency with a mortality close

to 70 %, though often under diagnosed (30 % post mortem). MAS is defined as an acute clinical and severe presentation of liver failure, consumption coagulopathy, and encephalopathy, associated with bone marrow-activated macrophages with signs of hemophagocytosis [26].

The clinical presentation is characterized by extended fever  $>39$  °C (for at least 7 days), internal bleeding—melena—CNS alterations expressed as somnolence, rash, and cutaneous erythema, jaundice, and lymphadenopathies. Hepatosplenomegaly is frequently present (Table 6). MAS has been described in autoimmune disease including SLE, idiopathic juvenile arthritis, still disease of the adult, polyarteritis nodosa, and Kawasaki disease [27].

From the perspective of immunopathology, reactive histiocytosis are nonmalignant and uncontrolled activation and proliferation processes of macrophages—histiocytes, leading to hypercytokinemia. Recent flow cytometry analyses have reported a defect in the natural killer (NK) cells functioning with low levels of perforin expression [27]. Macrophage activation may be triggered by infections (Epstein Barr virus, HIV), drugs (aspirin, antiretroviral drugs, sulphazalacine, corticosteroids, azathioprine, and even post anti-TNF $\alpha$  therapy).

## MAS therapy

The treatment protocol includes support therapy: ICU surveillance and continuous monitoring, establishment of hydroelectrolytic balance, fresh frozen plasma transfusions, pancultures, and antibiotic therapy when the activation is due to infection. Treatment should be initiated early on to prevent damage of the organs involved. Based on the presence of inhibitory activity in the blood of these patients, plasmapheresis was the initial treatment; however, the improvement was transient as was the case with splenectomy [28, 29]. The

**Table 6** MAS diagnostic criteria

Clinical criteria	
Fever ( $38.5$ °C peaks, for at least 7 days)	
Splenomegaly	
Lymphadenopathies	
Laboratory criteria	
Cytopenia	
Hb $<9$ gr/dl	
Platelets $<100,000$ mm <sup>3</sup>	
Neutrophils $<1000$ mm <sup>3</sup>	
Hypertriglyceridemia $>265$ mg/dl	
Hypofibrinogenemia $<150$ mg/l	
Hyperferritinemia $>500$ mcg/l	
Low or absent NK cell activity	

effectiveness of intravenous immunoglobulin (IVIG) has been modest, and recommendation is to use only after the eighth week (earlier use is contraindicated). The IVIG dose is 500 mg/kg, once per month [28, 30].

The treatment of choice is still intravenous or oral cyclosporine at a dose of 3–5 mg/kg/day. It is associated to steroid therapy from the start or 24 h after if there is no improvement and until the biological parameters are normalized. The response to cyclosporine A is due to a selective suppression of T lymphocytes, inhibiting cytokine production [27, 29].

The allogeneic transplant of hematopoietic cells (HCT) seems to offer the best overall cure rate for MAS, though the effectiveness and safety of the new biologic therapies are yet to be validated: anti-IL 1 (canakinumab), anti-CD25 (daclizumab), and anti-IL 6 (tocilizumab) [31–33].

### Final considerations

GCs continue to be the drugs of choice in the treatment of autoimmune diseases following their discovery in the 1950s. Several action mechanisms have been described, whereby GCs inhibit inflammation and stabilize the lysosomes, decreasing phagocytosis and opsonization [34]. However, several of the action mechanisms attributed to these molecules are observed in the long term (genomic mechanisms leading to the transcription of an antiinflammatory gene). Nonetheless, there is a nongenomic mechanism that accounts for their notable effectiveness in controlling a vasculitis or SLE crisis. Such nongenomic mechanism includes the antagonism of the C-Jun N-terminal kinases (JNKs) signal pathway-dependent transcription factors and the subsequent block of the JNK signal activation cascade via the inhibition of phosphorylation in serine 63/73 by the glucocorticoid RG31 receptor [34, 35].

Due to the fact that the immunoregulatory profile and biopsies (skin, kidney, and alveolar, inter alia) are critical to establish the diagnosis of autoimmune diseases, but their processing and results may sometimes take >10 days—particularly the results of the antiphospholipid antibodies (AAF) that must be verified to prevent false positives, especially when infections are present—sepsis—(>6 weeks), the use of easy-to-process laboratory tests (Fast Lab) is a must and is very helpful though not confirmatory. These include acute phase reactants, globular sedimentation rate, and C-reactive protein (VSG/PCR), C3 and C4 complement levels (evaluating the alternate and the classical pathway simultaneously); rheumatoid factor (Ra Test—using nephelometry to get the results in less than 2 h), and evidently the standard nontreponemal serum test to detect syphilis (VDRL). VDRL uses a phospholipid compound of cardiolipin-cholesterol-leucine as the antigen substrate that helps to make a fast decision while the rest of the immune rheumatologic profile is available.

### Miscellaneous

A special consideration must have three pathologies that even though there is high mortality, they can become very disabling and occur up to 15 % of cases in our rheumatology patients: scleroderma renal crisis, septic arthritis, and atlantoaxial subluxation. *Scleroderma renal crisis*: This form of renal involvement in scleroderma is characterized by

- The acute onset of renal failure.
- The abrupt onset of moderate to marked hypertension (although some patients remain normotensive).
- A urine sediment that is usually normal or reveals only mild proteinuria with few cells or casts [36].

Blood pressure control with angiotensin-converting enzyme (ACE) inhibitors with gradual reduction of malignant hypertension is the cornerstone of treatment. Other agents such as calcium channel-blocking agents may be added. Renal dialysis may even be required. It is important that the blood pressure be lowered gradually (i.e., avoid use of intravenous nitroprusside or labetalol) and do not let the patient develop hypovolemia [37].

*Acute bacterial arthritis*, or “septic arthritis,” is a rheumatologic emergency. Bacterial replication in the joint and the ensuing inflammatory process can lead to rapid local joint destruction and may be accompanied by systemic infection. The clinician’s prompt recognition of the infected joint and implementation of appropriately targeted therapy is therefore critical to limit the morbidity and mortality associated with these infections [38].

Abnormal joint architecture is the most important risk factor for septic arthritis as seen in patients with rheumatoid arthritis (RA), crystal-induced, and Charcot’s arthropathy. One hypothesis to explain the increased risk is that patients with RA may have reduced bactericidal activity of synovial fluid and defective phagocytosis by polymorphonuclear cells. The diagnosis of bacterial arthritis should be considered in any patient with acute monoarticular or oligoarticular arthritis. A widely accepted case definition for bacterial septic arthritis was proposed by Newman and requires one of four points to be met: (1) isolation of an organism from an affected joint, (2) isolation of an organism from another source with a concomitant swollen, hot joint, (3) clinical features and turbid joint fluid in the presence of previous antibiotic therapy, and (4) histologic or radiologic evidence consistent with septic arthritis.

Removal of bacteria and inflammatory debris from the joint is an essential component of the management of infectious arthritis. Closed needle aspiration has historically been the method used in less severe cases and in distal, smaller joints. It is less invasive than surgical drainage and may be associated with faster functional recovery, but it has not been associated with shorter length of stay or decreased mortality [39].

The choice of antibiotic is determined by the isolation of the pathogen and antibiotic sensitivity; some guidelines recommend parenteral therapy for 2 weeks followed by 4 weeks of oral therapy. *Staphylococcus aureus* infection and gram-negative septic arthritis requires 4 weeks of parenteral therapy [40]. If the gram-negative organism is susceptible to fluoroquinolones, oral therapy with ciprofloxacin or levofloxacin can be considered as an alternative to IV during the latter half of the treatment course due to the high bioavailability of these agents [38, 40].

*Atlantoaxial subluxation (ATS)*, the most common presenting symptom for patients with ATS is the pain. This can be either a vague neck pain or a headache. However, this pain is an extremely nonspecific finding, and these patients will require further evaluation to determine its source. The proximity of the spinal cord and vascular supply to the posterior elements can lead to additional severe effects such as myelopathy or vascular occlusion [40].

Neurologic manifestations include clumsiness, lack of coordination, abnormal gait, difficulty walking, neurogenic bladder, torticollis, easy fatigability, neck pain, limited neck mobility, sensory deficits, upper motor neuron signs (hyperreflexia, spasticity, clonus, Babinski sign), paraplegia, hemiplegia, and quadriplegia. Any patient with risk factors for development of ATS (rheumatoid arthritis, Down syndrome, congenital scoliosis, osteogenesis imperfecta, ankylosing spondylitis, neurofibromatosis) merits urgent radiographic and surgical evaluation [41].

### Take home message

- Unusual (difficult) cases—targeted questioning: the personal and/or family history of autoimmunity is extremely relevant, as well as the use of oral contraceptives, past history of arterial or venous thrombosis, purpura, rheumatoid arthritis, lupus, abortions, and gangrenous ulcers.
- Always check the skin for lesions like livedo reticularis, Raynaud, nail pitting, Grotton papules, alopecia, splinter hemorrhage, malar rash, and photosensitivity.
- Use of paraclinical tests (Fast Lab): VSG, PCR, fibrinogen, procalcitonine, VDRL, C3, C4, Ra Test, COOMBS.
- Do not postpone glucocorticoids and immunosuppressors because of concomitant infections (keep in mind that the patient is hospitalized, monitored and severely ill)

**Disclosures** None.

### References

1. Moskop JC, Sklar DP, Geiderman JM, Scheers RM, Bookman KJ (2008) Emergency department crowding, part 1—concept, causes, and moral consequences. *Ann Emerg Med* 53(5):605–611
2. LaCalle E, Rabin E (2010) Frequent users of emergency departments: the myths, the data, and the policy implications. *Ann Emerg Med* 19:1010
3. Asherson RA (1992) The catastrophic antiphospholipid antibody syndrome. *J Rheumatol* 19:508–512
4. Erkan D, Asherson RA, Espinosa G, Cervera R, Font J, Piette JC et al (2003) The long-term outcome of catastrophic antiphospholipid syndrome survivors. *Ann Rheum Dis* 62:530–533
5. Cervera R, Bucciarelli S, Espinosa G, Gómez-Puerta JA, Ramos-Casals M, Shoenfeld Y, Piette J-C, Asherson RA (2007) Catastrophic antiphospholipid syndrome: lessons from the “CAPS Registry”. *Ann NY Acad Sci* 1108:448–456
6. Bucciarelli S, Espinosa G, Cervera R, Erkan D, Gómez-Puerta JA, Ramos-Casals M et al (2006) For the CAPS Registry Project Group (European Forum on Antiphospholipid Antibodies). Mortality in the catastrophic antiphospholipid syndrome. Causes of death and prognostic factors in a series of 250 patients. *Arthritis Rheum* 54: 2568–2576
7. Gutierrez-Gonzalez LA Síndrome anti-fosfolípido catastrófico. A propósito de un caso. *Archivosdel CNER*. Caracas, DC [update Oct 2007; cited april 2013]. Available from: <http://cner.org.ve/pdf/caso1-2007.pdf>
8. Ortega-Hernandez OD, Agmon-Levin N, Blank NA, Asherson RA, Shoenfeld Y (2009) The physiopathology of the catastrophic antiphospholipid (Asherson’s) syndrome: compelling evidence. *J Autoimmun* 32(1):1–6
9. Shapira I, Andrade D, Allen SL, Salmon JE (2012) Briefreport: induction of sustained remission in recurrent catastrophic antiphospholipid syndrome via inhibition of terminal complement with eculizumab. *Arthritis Rheum* 64(8):2719–2723
10. West SC, Arulkumaran N, Philip W (2013) Ind, Pusey CD. Pulmonary-renal syndrome: a life threatening but treatable condition. *Postgrad Med J* 89:274–283
11. Lee RW, D’Cruz DP (2010) Pulmonary renal vasculitis syndromes. *Autoimmun Rev* 9:657–660
12. Booth AD, Almond MK, Burns A et al (2003) Outcome of ANCA-associated renal vasculitis: a 5-year retrospective study. *Am J Kidney Dis* 41:776–784
13. Bagshaw SM, Langenberg C, Wan L et al (2007) A systematic review of urinary findings in experimental septic acute renal failure. *Crit Care Med* 35:1592–1598
14. Jones RB, Tervaert JW, Hauser T et al (2010) Rituximab versus cyclophosphamide in ANCA-associated renal vasculitis. *N Engl J Med* 363(3):211–220
15. Jayne DR, Gaskin G, Rasmussen N et al (2007) Randomized trial of plasma exchange or high-dosage methylprednisolone as adjunctive therapy for severe renal vasculitis. *J Am Soc Nephrol* 18:2180–2188
16. Plasma exchange and glucocorticoid dosing in the treatment of ANCA-associated vasculitis: a multicentre randomised controlled trial—PEXIVAS 2010; <http://www.bctu.bham.ac.uk/pexivas>
17. Salvarani C, Brown RD Jr, Calamia KT, Christianson TJ, Huston J 3rd, Meschia JF et al (2008) Primary CNS vasculitis with spinal cord involvement. *Neurology* 70(24 Pt 2):2394–2400
18. Scolding NJ, Jayne DR, Zajicek JP, Meyer PAR, Wraight EP, Lockwood CM (1997) The syndrome of cerebral vasculitis: recognition, diagnosis and management. *QJM* 90:61–73
19. Oku K, Atsumi S, Furukawa (2003) Cerebral imaging by magnetic resonance imaging and single photon emission computed tomography in systemic lupus erythematosus with central nervous system involvement. *Rheumatology* 42:773–777



20. Jennings J, Sundgren P et al (2004) Value of MRI of the brain in patients with systemic lupus erythematosus and neurologic disturbance. *Neuroradiology* 46:15–21
21. Nuñez-Sotelo CM, Gutiérrez-Gonzalez LA, Rodriguez MA (2012) Rapid, complete and sustained response to corticosteroids and pulse cyclophosphamide therapy in a patient with behçet and central nervous disease. *Maedica* 7(4):348–351
22. Tincani A, Rebaioli CB, Taglietti M, Shoenfeld Y (2006) Heart involvement in systemic lupus erythematosus, antiphospholipid syndrome and neonatal lupus. *Rheumatology* 45:8–13
23. Buyon JP, Waltock J, Kleinman C, Copel J (1995) In utero identification and therapy of congenital heart block. *Lupus* 4:116–121
24. Friedman DM, Rupel A, Buyon JP (2007) Epidemiology, etiology, detection, and treatment of autoantibody-associated congenital heart block in neonatal lupus. *Curr Rheumatol Rep* 9:101–108
25. Brucato A, Frassi M, Franceschini F, Cimaz R, Faden D, Pisoni MP et al (2001) Risk of congenital complete heart block in newborns of mothers with anti-Ro/SSA antibodies detected by counter immunoelectrophoresis: a prospective study of 100 women. *Arthritis Rheum* 44:1832–1835
26. Janka GE (2007) Haemophagocytic syndromes. *Blood Rev* 21: 245–253
27. Grom AA, Mellins ED (2010) Macrophage activation syndrome: advances towards understanding pathogenesis. *Curr Opin Rheumatol* 22:561
28. Ravelli A, De Benedetti F, Viola S, Martini A (1996) Macrophage activation syndrome in systemic juvenile rheumatoid arthritis successfully treated with cyclosporine. *J Pediatr* 128:275–278
29. Billiau AD, Roskams T, Van Damme-Lombaerts R et al (2005) Macrophage activation syndrome: characteristic findings on liver biopsy illustrating the key role of activated, IFN-gamma-producing lymphocytes and IL-6- and TNF-alpha-producing macrophages. *Blood* 105:1648
30. Tristano AG, Casanova-Escalona L, Torres A, Rodriguez MA (2003) Macrophage activation syndrome in a patient with systemic onset rheumatoid arthritis: rescue with intravenous immunoglobulin therapy. *J Clin Rheumatol* 9(4):253–258
31. Ruperto N, Brunner HI, Quartier P et al (2012) Two randomized trials of canakinumab in systemic juvenile idiopathic arthritis. *N Engl J Med* 367:2396–2406
32. De Benedetti F, Brunner HI, Ruperto N et al (2012) Randomized trial of tocilizumab in systemic juvenile idiopathic arthritis. *N Engl J Med* 367:2385–2395
33. Christy Sandborg MD, Elizabeth D, Mellins MD (2012) A new era in the treatment of systemic juvenile idiopathic arthritis. *N Engl J Med* 367:2439–2440
34. Stocklin E, Wissler M, Gouilleux F, Groner B (1996) Functional interactions between Stat5 and the glucocorticoid receptor. *Nature* 383:726–728
35. Adcock IM (2000) Molecular mechanisms of glucocorticosteroid actions. *Pulm Pharmacol Ther* 13:115–126
36. Steen VD (2003) Scleroderma renal crisis. *Rheum Dis Clin North Am* 29:315–333
37. Walker JG, Ahem MJ, Smith MD et al (2003) Scleroderma renal crisis: poor outcome despite aggressive antihypertensive treatment. *Intern Med J* 33:216–220
38. Ross JJ (2005) Septic arthritis. *Infect Dis Clin North Am* 19:799–817
39. Stengel D, Bauwens K, Sehoul J et al (2001) Systematic review and meta-analysis of antibiotic therapy for bone and joint infections. *Lancet Infect Dis* 1:175–188
40. Clark CR, Goetz DD, Menezes AH (1989) Arthrodesis of the cervical spine in rheumatoid arthritis. *J Bone Joint Surg Am* 71(3): 381–392
41. Babic-Nagic D, Potocki K, Curkovic B (1999) Clinical and radiological features of atlantoaxial joints in rheumatoid arthritis. *Z Rheumatol* 58(4):196–200